

Retained wooden foreign body in the orbit

Sagili Chandrasekhara Reddy

Department of Ophthalmology, Rangaraya Medical College,
Kakinada, Andhra Pradesh, India

Correspondence to: Prof. Sagili Chandrasekhara Reddy,
Department of Ophthalmology, Faculty of Medicine &
Health Sciences, University Sultan Zainal Abidin, Kota
campus, Jalan Mahmud, 20400 Kuala Terengganu,
Terengganu, Malaysia. profscreddy@gmail.com

Received: 2012-10-19 Accepted: 2013-02-20

DOI:10.3980/j.issn.2222-3959.2013.02.29

Reddy SC. Retained wooden foreign body in the orbit. *Int J Ophthalmol* 2013;6(2):255-258

Dear Sir,

I am writing to you to present three unusual cases of wooden foreign bodies in the orbit, as such cases are rarely seen in practice and they pose a diagnostic and management challenge to ophthalmologists. A detailed history and examination of the eye, diagnostic imaging investigations, surgical removal of wooden foreign body from the orbit combined with aggressive medical therapy will preserve/improve vision and lessen ocular morbidity.

Case 1: A 25 years old man, came to the emergency department of the Teaching Government General Hospital at 6.30 pm with complaint of injury to the right eye with a piece of bamboo stick. He sustained injury 6 hours back during a quarrel with another person in the village. The bamboo stick broke during an attempt to remove the stick by the relatives. Following the injury, he had pain in the eye and swelling of eyelids in right eye.

Right eye: Streaks of clotted blood were present below the lower lid. Upper eyelid was oedematous, covering the globe completely. A bamboo stick, penetrating into the lower orbit from the nasal side, was seen in between the two eyelids (Figure 1A). On lifting the upper eyelid, the bulbar conjunctiva was found to be oedematous in the temporal quadrants. Lower lid margin was covered by the bamboo stick. The globe was displaced upwards without any perforation (Figure 1B). Cornea, anterior chamber, iris, pupil and lens were normal. Vision could not be tested accurately; it was counting fingers 2 M in right eye. Left eye was normal. The patient was explained about the condition of right eye and was admitted in the eye ward.

On the next day, the bamboo stick (foreign body) was removed from the right orbit under general anaesthesia.

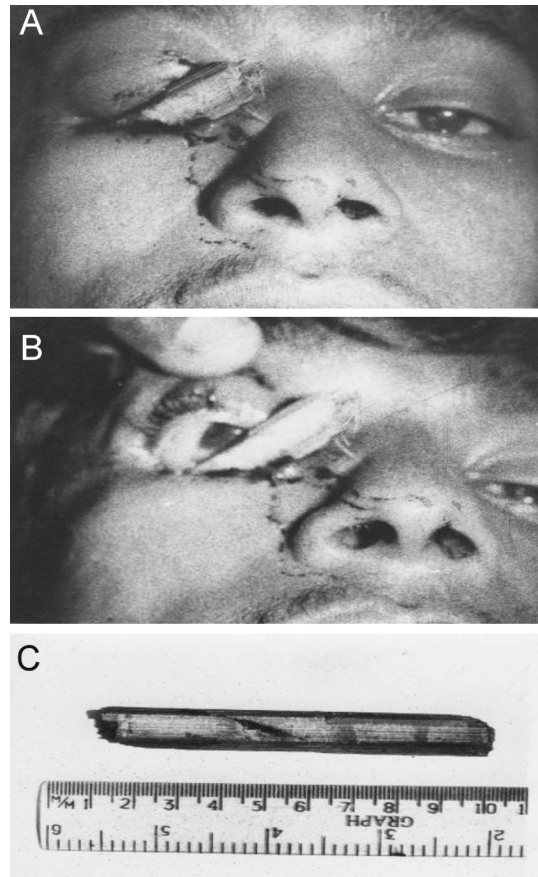


Figure 1 A: showing the bamboo stick lying in between the two eyelids in right eye; B: showing the right globe displaced upwards; C: the removed bamboo stick.

Intra-operatively, it was found to be directed downwards towards the floor of orbit. After some manipulation, the bamboo stick was removed. Soon after the removal of bamboo stick, the globe came to normal position. A lacerated wound of conjunctiva (15mm size) was noted in the lower fornix at the entry wound site. A thorough irrigation of wound area was done with gentamycin solution. On further exploration, no pieces of foreign body were found in the orbit. The conjunctival wound was sutured with 8-0 vicryl; gentamycin eye ointment was put and eye was patched. The removed wooden foreign body measured 92mm × 13mm × 6mm in size (Figure 1C).

Postoperatively, patient was treated with I.V. Ciprofloxacin 200mg bd for two days followed by oral Ciprofloxacin 500mg bd for five days, Tab, Ibuprofen 200mg tds, Tab. Vitamin C 500mg daily and topical gentamycin ointment tds in right eye. The eye patch was removed on the next day morning. There was no diplopia. Vision was 6/9 in both eyes.

Retained wooden foreign body in the orbit

Both eyes were orthophoric and ocular movements were normal. Pupil was normal size and briskly reacting to light. Fundus was normal. X-ray orbits did not show any fracture of right orbital bones. Patient was discharged on gentamycin eye drops tds in right eye. In the first follow up visit after two weeks, vision improved to 6/6 in both eyes with +0.50×180° glasses; ocular movements were normal in the right eye. Gentamycin eye drops were stopped. He was followed up once in two months for 6 months. At the last follow up, vision, ocular movements, anterior segment and fundus were normal in the right eye.

Case 2: A 8 years old boy attended the eye clinic with history of injury to right eye of ten days duration, due to fall in the field on the wooden stump of red gram crop. There was bleeding followed by swelling and redness in right eye. There was no diminution of vision in right eye. He was given intramuscular injections, tablets and eye ointment by a private practitioner in the village. Swelling of the eye subsided in few days time, but the upper lid was covering the globe and child could not open the eye. He experienced something pricking sensation in the upper part of right eye.

Right eye: upper lid was oedematous, completely covering the eyeball and child was not able to open the eye. There was a horizontal notch in the upper eyelid and a prominence was noted in the medial 1/3 of upper eyelid (Figure 2A). On palpation, a hard mass was felt under the upper lid which was slightly mobile. On lifting the upper lid, a lacerated injury of conjunctiva was noted, above the upper tarsal margin extending upwards. Eye ball was normal. Vision was 6/6. Fundus was normal. Left eye: vision, anterior segment and fundus were normal.

X-ray orbits did not show any foreign body or fracture of right orbital bones. The diagnosis of retained foreign body in the upper part of right orbit was made and the child was admitted to the eye ward. He was treated with I.V. Ciprofloxacin 100mg bd, Tab. Ibuprofen 100mg tds, and gentamycin eye ointment tds in right eye. On third day, the child was able to open the right eye little bit. Under general anesthesia, the conjunctival wound in the upper fornix was explored and the wooden foreign body was removed. A thorough irrigation of the wound area was done with gentamycin solution. On further exploration, no pieces of foreign body were found. The conjunctiva was sutured with 8-0 vicryl. Gentamycin eye ointment was put and eye was patched. The removed wooden foreign body measured 26mm×8mm×5mm in size (Figure 2B).

Postoperatively, I.V. ciprofloxacin was continued for another two days; then replaced with oral ciprofloxacin 250mg bd for another three days. The eye patch was removed on the next day morning. The ptosis improved and patient could open the right eye and see the objects well. Patient was discharged on gentamycin eye drops tds in right eye. He was followed up at

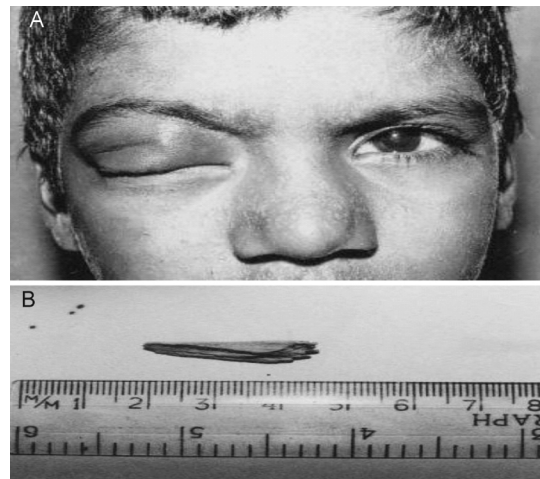


Figure 2 A: showing the complete ptosis of right upper lid; B: removed wooden foreign body.

three weeks interval for the next two months. During the follow up, moderate ptosis was noted in right eye, vision and ocular movements were normal. Gentamycin eye drops were stopped. He was advised to come for follow up once in three months, and surgical correction of ptosis if necessary. Unfortunately, the patient defaulted follow up.

Case 3: A 7 years old boy attended the eye clinic with complaint of injury to left eye with a tree branch of one day duration, while playing with children, followed by pain and watering of eye. There was bleeding from the eye immediately. He was given analgesics and antibiotic eye ointment by the practitioner in the village.

Left eye: Streaks of clotted blood were present on the nose. Vision was 6/12. There was mild edema of lower eyelid. Conjunctiva was diffusely congested. Chemosis was present on the nasal side. Subconjunctival haemorrhage was present in the lower temporal quadrant. A black spot was noted in the lower fornix on the temporal side (Figure 3A). On palpation of lower eyelid, a hard mass could be felt near the orbital margin. Anterior segment and fundus were normal. Right eye: Vision was 6/9; anterior segment and fundus were normal. X-ray orbits did not show any foreign body or fracture of left orbital bones. The diagnosis of retained wooden foreign body in the lower part of left orbit was made and the child was admitted to the eye ward.

On the next day, under general anaesthesia, exploration of the conjunctiva over the black spot in left eye was done and wooden foreign body was removed from the lower fornix. A thorough irrigation of the wound area was done with gentamycin solution. On further exploration, no pieces of foreign body were found. Conjunctival wound was sutured with 8-0 vicryl. Gentamycin eye ointment was put and eye was patched. The removed wooden foreign body measured 26mm×5mm×4mm in size (Figure 3B).

The eye patch was removed on the next day morning. Postoperatively, he was given I.V. Ciprofloxacin 100mg bd

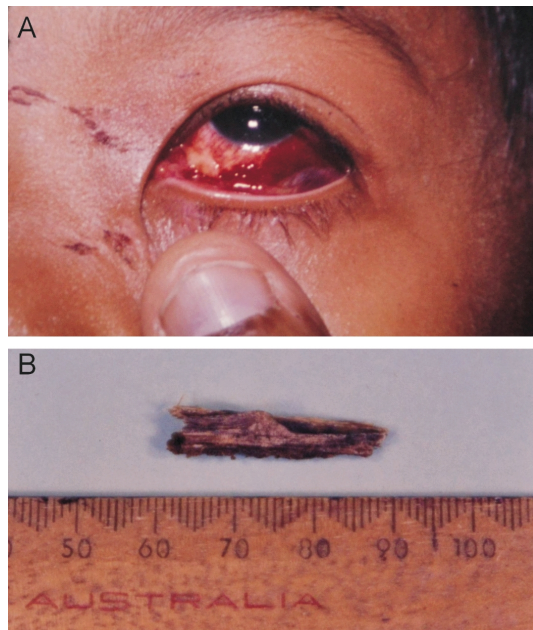

Figure 3 A: showing the subconjunctival haemorrhage in the lower temporal quadrant and the black spot; B: the removed wooden foreign body.

for two days followed by oral ciprofloxacin 100mg bd, along with gentamycin eye ointment tds in left eye. The oedema of lower lid and chemosis of conjunctiva in the lower fornix disappeared on third post operative day. His ocular movements were normal. Vision was 6/9 in both eyes. Oral antibiotic was stopped after five days. He was discharged on gentamycin eye drops tds in left eye He was followed up at three weeks interval for two months. Subconjunctival haemorrhage disappeared in the first follow up visit. Gentamycin eye drops were stopped. In the second follow up visit, his best corrected vision ($-0.50 \times 180^\circ$) was 6/6 in both eyes. He was further followed up once in two months for six months. At the last follow up, vision and ocular movements were normal in left eye.

The clinical features and various complications in patients with retained wooden foreign bodies have been reported from different countries^[1-8]. Retained wooden foreign bodies in the orbit may remain quiescent for a considerable length of time (days or months or years) without causing troublesome symptoms or signs before presenting with delayed onset of complications such as orbital cellulitis, abscess, granuloma, and chronic draining sinus^[9].

The clinical features depend on the mode of injury, size of foreign body, and time of presentation after injury. The symptoms and signs include swelling of the lids, ptosis, loss of movements and loss of vision^[7], swelling upper lid and sinus with purulent discharge; sinus in lower lid with purulent discharge after few weeks of injury^[8], esotropia orbital abscess, optic atrophy and mass in medial canthus^[6], proptosis and after many years discharging sinus^[3], orbital cellulitis^[4]. The associated wound may be small and self

sealing. Therefore, there is recurrence of symptoms, especially if there is a discharging sinus and granuloma, the possibility of retained foreign body should be considered^[5].

In a review of 23 intraorbital wooden foreign body injuries, Shelsta *et al*^[11] reported the age of patients ranged from 2 to 52 years; and the types of wood were pencil (39%), tree branch/plant matter (35%), and other treated wood (26%). The site of foreign body found within the orbit was superior (26%), medial 30%, inferior (26%), posterior (9%), and lateral (4%). The site of penetration of foreign body was in the conjunctiva (53%), notably without presence of eyelid laceration, emphasizing the need to check the conjunctiva and fornices closely. The preliminary radiographic interpretation for wooden foreign body was definite in 61%, possible in 22%, and absent in 13%.

Plain X-ray has no role in the diagnosis of intraorbital wooden foreign body since wood is not seen with this modality due to its radiolucent property. B-scan ultrasonography has a very limited role because it often requires expertise and does not image orbital apex with reliability^[10]. The MRI scan is better at demonstrating wooden foreign bodies because this technique depends on the density of protons in the tissues and their different relaxation times. These properties of wood are dissimilar enough from those of the soft tissue to allow differentiation^[11]. The CT scan findings of wooden foreign bodies may over time may be different in appearance. In the first few days (acute stage), the density of wooden material is low and thus may be mistaken as air bubbles. After a week (subacute stage), wood assumes a moderate density and may be difficult to distinguish from surrounding orbital fat. In the chronic stage (few weeks/months), the density of wood becomes higher than that of orbital fat. It appears as a homogenous mass surrounding the dens wooden foreign body, with a density similar to the adjacent extraocular muscle^[12].

In this series, there was definite history of injury with wooden stick in all three cases. The wooden foreign body was visible in one case, and was palpable under the lid in other two cases. Therefore, CT scan investigation was not done to localize the foreign body.

Wood and bamboo, with their porous consistency and organic nature, provide a good medium for microbial agents. Infection resulting from retained intraorbital or bamboo foreign material may lead to complications such as orbital cellulitis^[4,9], optic nerve injury and atrophy^[6-8], inferior ophthalmic vein thrombosis and impending cavernous sinus thrombosis^[9], granuloma^[5,8], infection, injury to extraocular muscle, adhesions of periocular tissues^[6], and chronic draining fistula through the palpebral skin^[8].

In this series, the wounds healed well following the removal of wooden foreign body without complications in two cases,

but there was mild ptosis in one case which could be due to injury of levator palpebrae superioris muscle by the wooden foreign body. The vision improved to normal in two cases with correction of glasses. In the other case, vision was normal at presentation as well as postoperatively.

The wooden foreign body has been reported to remain in the orbit for a varying latent period of time *viz*: 6 weeks^[7], 6 months^[5], 18 months^[3], or even 3 years^[6] following the eye injury, before it was diagnosed. However, complications as mentioned above have been reported in some cases.

Wooden foreign bodies fragment easily during surgical removal leaving behind splinters. Therefore, exploration of the wound for any small pieces, careful debridement of necrotic tissue, and copious irrigation of the wound with antibiotic solution are advised. Because of chances of infection are high, intra venous broad spectrum antibiotics should be given post operatively in all these cases. Shelsta *et al*^[1] recommended the use of combination of cefotaxime/ceftazidine and vancomycin which has good blood brain barrier penetration in these patients, because of the proximity of central nervous system and the possibility of occult intracranial penetration. Occasionally, the left over pieces of wood can cause inflammation even after long quiescent period. It is important to remember the possibility of wooden foreign body in the orbit, if the orbital injuries do not heal as expected or if the trauma history is not reliable.

REFERENCES

1 Shelsta HN, Bilyk JR, Rubin PA, Penne RB, Carrasco JR. Wooden

intraorbital foreign body injuries: clinical characteristics and outcomes of 23 patients. *Ophthalm Plast Reconstr Surg* 2010;26(4):238–244

2 Shinder R, Gutman J, Gunasekera CD, Connor M, Nakra T. Occult Orbital Organic Foreign Body. *Ophthalm Plast Reconstr Surg* 2011;27(6):463–464

3 John SS, Rehman TA, John D, Raju RS. Missed diagnosis of a wooden intra orbital foreign body. *Indian J Ophthalmol* 2008;56(4):322–324

4 Lakshmanan A, Bala S, Belfer KF. Intraorbital organic foreign body—a diagnostic challenge. *Orbit* 2008;27(2):131–133

5 Banerjee A, Das A, Agarwal PK, Banerjee AR. Late spontaneous extrusion of a wooden foreign body. *Indian J Ophthalmol* 2003;51(1):83–84

6 Lee JA, Lee HY. A case of retained wooden foreign body in orbit. *Korean J Ophthalmol* 2002;16(2):114–118

7 Kumar D, Saxena S, Goel U. Retained wooden foreign bodies in the orbit: A case report. *Indian J Ophthalmol* 1995;43(4):195–196.

8 Agarwal PK, Kumar H, Srinivasa PK. Unusual orbital foreign bodies. *Indian J Ophthalmol* 1993;41(3):125–127

9 Goldberg MF, Paton D. Ocular emergencies. In: Paymen GA, Sanders DR, Goldberg MF (eds). *Principle and practice of Ophthalmology*; Philadelphia, WB Saunders, 1980: p 2466

10 Lagalla R, Manfre L, Carona A, Bencivinni F, Duranti C, Ponte F Plain film, CT and MRI sensibility in the evaluation of intraorbital foreign bodies in an in vitro model of the orbit in pig eyes. *Eur Radiol* 2000;10(8):1338–1341

11 Green BF, Kraft SP, Carter KD, Buncie JR, Nerad JA, Armstrong D. Intraorbital wood: detection by magnetic resonance imaging. *Ophthalmology* 1990;97(5):608–611

12 Boncouer–Martel MP, Adenis JP, Rulfi JY, Robert PY, Dupuy JP, Maubon A. CT appearances of chronically retained wooden intraorbital foreign bodies. *Neuroradiology* 2001;43(2):165–168