

# Comparison of trabeculectomy and trabeculectomy with amniotic membrane transplantation in the same patient with bilateral glaucoma

*Qing-Shan Ji, Bing Qi, Lian Liu, Wei Lao, Zhi-Hao Yang, Gui-Fang Wang, Guo-Cheng Yu, Jing-Xiang Zhong*

**Foundation items:** 2011 Guangdong Province Natural Science Fund, China (No.S2011010004186); National Basic Research Program of China (973 program, 2011CB707501) Department of Ophthalmology, the First Affiliated Hospital of Jinan University, Guangzhou 510632, Guangdong Province, China

**Co-first authors:** Qing-Shan Ji and Bing Qi

**Correspondence to:** Jing-Xiang Zhong. Department of Ophthalmology, the First Affiliated Hospital of Jinan University, Guangzhou 510632, Guangdong Province, China. zjx85221206@126.com

Received: 2013-03-26

Accepted: 2013-07-24

## Abstract

• **AIM:** To observe effects of trabeculectomy with amniotic membrane transplantation (AMT) in controlling postoperative intraocular pressure (IOP) in patients with medically uncontrolled glaucoma.

• **METHODS:** This study included adult patients with requiring bilateral glaucoma surgery. Each patient underwent trabeculectomy (Non-AMT group) in one eye and with AMT (AMT group) in the other eye according to randomized principle. Success was defined as intraocular pressure (IOP) <21mmHg without any anti-glaucoma medications at 24 months follow-up. The two groups were compared in terms of IOP, complications and success rate.

• **RESULTS:** Thirty-four eyes of 17 patients were investigated in this study. There was no statistically significant difference in pre-operative IOP between the two groups. The mean IOP was lower in AMT group compared with Non-AMT group on follow up months 12, 18, and 24. Postoperative complications were more frequent in Non-AMT group (35.3%, 6/17) compared with AMT group (5.9%, 1/17). The success rate of surgery was 88.2% (15/17) in Non-AMT group and 100% (17/17) in AMT group.

• **CONCLUSION:** Trabeculectomy with AMT is an effective procedure to reduce IOP and complications, thereby improving surgical success rates.

• **KEYWORDS:** trabeculectomy; amniotic membrane transplantation; glaucoma

**DOI:10.3980/j.issn.2222-3959.2013.04.07**

Ji QS, Qi B, Liu L, Lao W, Yang ZH, Wang GF, Yu GC, Zhong JX. Comparison of trabeculectomy and trabeculectomy with amniotic membrane transplantation in the same patient with bilateral glaucoma. *Int J Ophthalmol* 2013;6(4):448-451

## INTRODUCTION

Trabeculectomy is the most commonly used glaucoma surgical procedure for lowering IOP by providing an artificial drainage pathway from the anterior chamber to the subconjunctival space. However, the success rate of this surgery has been limited by postoperative fibroblast proliferation and scarring of the filtering bleb<sup>[1]</sup>. Numerous adjunctive modifications, such as antimetabolites, Beta radiation, anti-VEGF agents, have been developed to avoid occurring scar of the filtering bleb<sup>[2-9]</sup>. Antimetabolites, such as 5-fluorouracil and mitomycin C (MMC), have been commonly used adjunctively to prevent scar formation, and improved the success rate of trabeculectomy. But they have been associated with an increased incidence of postoperative complications, such as ischemic bleb, hypotony, and endophthalmitis<sup>[10]</sup>. Beta radiation was reported to induce severe complications including ocular irritation, scleral atrophy, neovascularization, persistent scleral ulcer, ptosis, symblepharon and iris atrophy<sup>[11]</sup>.

Amniotic membrane transplantation (AMT) was initially used in the treatment of ocular surface disorders. It promotes epithelialization by serving as a scaffold and a suitable basement membrane for epithelial cells to grow on as well as inhibits fibrosis by down regulating transforming growth factor- $\beta$  signaling and myofibroblast differentiation<sup>[12,13]</sup>. Based on these properties, AMT has been used in glaucoma-filtering surgery to prevent subconjunctival fibrosis. A number of studies have noted that IOP is better controlled with trabeculectomy when combined with amniotic membrane<sup>[14-16]</sup>. However, Eliezer *et al*<sup>[17]</sup> showed that the success rate of trabeculectomy with AMT is similar

to that of trabeculectomy without antifibrotics. Until now, there are few comparative studies of the surgical results of trabeculectomy with or without AMT. In this study, we compared the results of trabeculectomy with AMT in the different eyes of the same patient. The study was to limit the influence of individual variations in fibrotic response.

**SUBJECTS AND METHODS**

**Subjects** Patients with bilateral glaucoma underwent standard trabeculectomy in one eye and combined with AMT in the other eye, according to a prospective and randomized design. Eligible patients were at least 18 years of age and presented with medically uncontrolled glaucoma requiring bilateral surgery for IOP reduction. We excluded patients with history of active uveitis; any ocular abnormality that would influence accurate IOP assessment; refractory glaucoma and secondary glaucoma. The study and data collection were carried out with approval from the Ethics Committee. Informed consent was obtained from all patients prior to surgery.

**Methods**

**Preoperative preparation and surgical procedures**

Patient's preoperative data were collected, including demographics, ocular history, visual acuity, tonometry, slit-lamp biomicroscopy, and ophthalmoscopy. Randomisation of surgical procedures was achieved by opening an envelope in which the procedure (trabeculectomy or with AMT) that would be performed to the first eye was stated, thereby determining the procedure in the other eye. All patients were subjected to a standard trabeculectomy mainly as described by Wang *et al* [18]. In summary; a conjunctival flap was created at the base of the limbus. The size of the scleral flap was 3mm x3mm, one-half of the scleral thickness. The anterior chamber was punctured by a 15° knife. Next, excising the trabecular meshwork (1mmx1.5mm) and iris, two scleral flap sutures (10-0 nylon) were made. Finally the conjunctiva was sutured with 8-0 Vicryl sutures. In AMT group, amniotic membranes were placed under the scleral flap and affixed with four 10-0 nylon sutures.

**Postoperative care and follow -up** Post-operatively, Tobramycin Dexamethasone and levofloxacin eye drop were prescribed four times daily for 2 weeks. No systemic or topical anti-glaucoma medication was given. Postoperative examinations were performed on days 1, 3 and 7 and months 1, 3, 6, 12, 18, and 24; Best-corrected visual acuity, IOP, morphology of the filtering bleb, complications, using anti-glaucoma drugs were recorded at each visit. Surgical success was defined as IOP<21mmHg without any anti-glaucoma medications at any stage of the follow-up.

**Statistical Analysis** All statistical analysis was performed using SPSS version 16 (SPSS Inc., Chicago, IL, USA). The independent-sample *t*-test was used to compare the values between the 2 groups. The Fisher's exact test was used to

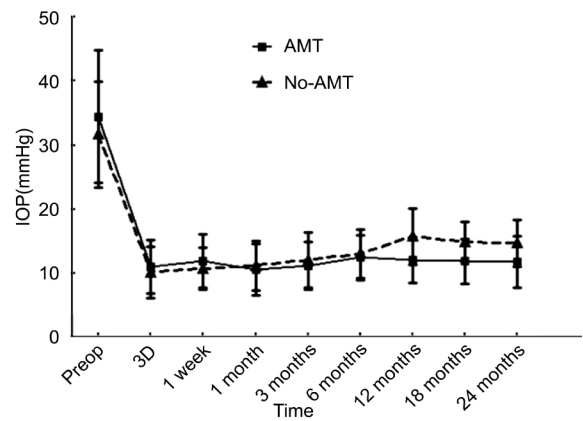


Figure 1 Pre- and post-operative IOP.

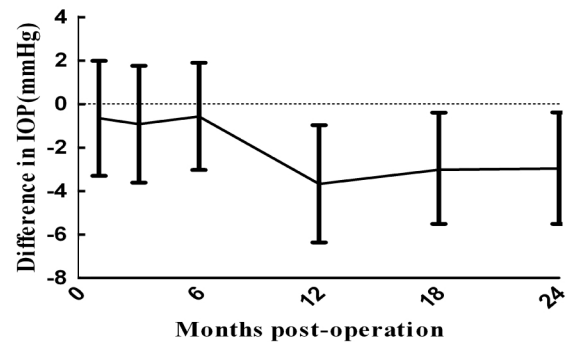


Figure 2 Time trend of the average difference in IOP between AMT and Non-AMT groups from 1 month after surgery to 24 months.

analyze complications and surgery success rate of two groups. *P* < 0.05 was considered as statistically significant in all tests.

**RESULTS**

Thirty-four eyes of 17 patients with bilateral glaucoma were investigated in this study. Ten patients had chronic angle-closure glaucoma; 7 cases had primary open angle glaucoma (POAG). They comprised 10 males and 7 females with mean age 61.6 (±13.4) years. Baseline glaucoma severity was similar in each eye pair, with a mean cup disk ratio ≥ 0.80 for both groups.

The mean and SD values of the IOP in the two groups all over the study period were shown in Figure 1 and Table 1. There was no significant difference between the two groups at post-operative days 3, and 7, or months 1, 3, 6 (*P* > 0.05), but there was a statistically significant difference between the two groups at 12, 18, 24 months (*P* < 0.05). Trabeculectomy with AMT groups had a significantly lower IOP compared to trabeculectomy only groups at 12, 18 and 24 months (Figure 2). Postoperative complications were more frequent in Non-AMT group (35.3%) compared with AMT group (5.9%) (Table 2). Shallow anterior chambers were noted in three cases of Non-AMT group and one case of AMT group. Choroidal detachment occurred in one case, as detected by B-ultrasound in Non-AMT group. After treatment with cycloplegics, topical and systemic steroids for 3 days, all

## Application of amniotic membrane in trabeculectomy

**Table 1 Mean and SD values of the IOP in the two groups**

Time of IOP	Non-AMT group (n=17)	AMT group (n=17)	t	P
Preoperation	31.68±8.21	34.46±10.31	0.87	0.391
IOP 3 days	10.18±4.03	11.03±4.23	-0.913	0.368
IOP 7 days	10.74±3.25	11.92±4.18	-0.85	0.374
IOP 1 month	11.24±3.86	10.58±4.01	0.926	0.362
IOP 3 months	12.11±4.31	11.18±3.65	0.75	0.471
IOP 6 months	13.06±3.82	12.49±3.51	0.454	0.653
IOP 12 months	15.76±4.40	12.09±3.60	2.663	0.012
IOP 18 months	14.89±3.40	11.86±3.49	2.26	0.031
IOP 24 months	14.71±3.61	11.75±4.01	2.765	0.009

Non-AMT group: Trabeculectomy without AMT; AMT group: Trabeculectomy with AMT.

**Table 2 Surgical complications**

Complications	Non-AMT group (n=17)	AMT group (n=17)	P
Shallow anterior chamber	3	1	
Choroidal detachment	1	0	
Encapsulated bleb	2	0	
Total	6	1	0.041

Non-AMT group: Trabeculectomy without AMT; AMT group: Trabeculectomy with AMT.

patients recovered. During follow-up examination, two cases had encapsulated bleb in Non-AMT group. After subconjunctival injection of 5-fluorouracil (5-FU), needle filtering bleb dissection, they developed a functional filtering bleb.

At 12 months follow-up, two patients from the Non-AMT group developed IOP >21mmHg and had to use topical anti-glaucoma medication. The success rate of surgery was 88.2% (15/17) in Non-AMT group and 100% (17/17) in AMT group.

### DISCUSSION

The main cause of failure following trabeculectomy is the post-operative wound healing response that leads to subconjunctival scarring at sclerostomy site [19,20]. Therefore, inhibition of scar formation during the process of wound healing should promote trabeculectomy outcomes. Antimetabolites is most commonly used to overcome the postoperative wound-healing processes. Nevertheless, these drugs can increase incidence of postoperative complications. Alternative antifibrotic agents have thus been sought.

Several investigators have explored the clinical efficacy of AM as an adjunctive therapy to improve the surgical outcome of various glaucoma procedures, including trabeculectomy [14-16,21-24]. They have showed that transplantation of AM under the scleral flap reduces the IOP and side effects in refractory glaucoma eye. However, Eliezer *et al* [17] suggested that the success rate of trabeculectomy with AMT is similar to standard trabeculectomy in POAG. The aforementioned results could be limited by lack of control group, retrospective investigation, the small size and individual variations in fibrotic response. Thus, it is difficult to determine if the amniotic membrane had any beneficial effect. We have conducted the prospective randomized study to demonstrate

the efficacy of AMT in the same patient with medically uncontrolled glaucoma.

In this study, the AMT group was shown to have a highly significant and stable IOP reduction throughout the 24-month follow-up (Figure 1, Table 1). Mean IOP values were lower from 1 to 2 years after AMT. However, The AMT group had a slightly higher level of IOP at the first six months follow-up, this was due to the fact that AM inserted under the scleral flap prevented rapid drainage of aqueous humor from the trabeculectomy site. At the 24-month review, the AMT group has better success rate than Non-AMT group. We also observed that the incidence of encapsulated blebs was lower in the AMT group than Non-AMT group. These results suggest that AM can significantly maintain a lower level IOP with fewer complications by preventing the formation of fibrotic tissue around the drainage pathway. This is consistent with previous study. Sheha *et al* [25] conducted a prospective, randomized study included 37 eyes with refractory glaucoma. In this study, 18 received 0.2mg/mL MMC under the flap for 2min while 19 received AMT, complete success was seen in 15/16 (93.7%) AMT eyes and 9/15 (60%) MMC eyes at 6 months postoperatively. The incidence of encapsulated blebs was greater in the MMC group (38.9% vs 5.3%) at 12 months postoperatively. Experimental rabbit studies also demonstrated that the AMT can reduce the number of fibroblasts at trabeculectomy sites [26,27]. However, Stavarakas *et al* [28] noted that the level of IOP control is similar between AMT and control group at 24 months follow-up. These inconsistent results may be due in part to differences in the types of glaucoma and individual variations in fibrotic response.

Besides achieving a better IOP control over a period of 2 years, the AMT group shows a few of complications. Such as hypotony, shallow anterior chamber, and choroidal detachment (Table 2). This was due to the fact that AM inserted under the scleral flap effectively prevented rapid drainage of aqueous humor from the trabeculectomy site. That also explains why the AMT group had a slightly high level of IOP compared with Non-AMT at the first six months follow-up. It has been recognized that even if trabeculectomy is performed with MMC, fibrosis could develop months later [29]. That illustrates why IOP became creeping up from 3 to 12 months postoperatively (Table 1). On the contrary, AMT group have a highly stable IOP control throughout 24 months. We suggested that AM's antifibrotic effects might extent to longer periods of postoperative, thereby increasing surgical success rates.

In conclusion, trabeculectomy with AMT is an effective procedure to maintain lower IOP, reduce complications, and improve surgical success rates.

### REFERENCES

1 Picht G, Grehn F. Classification of filtering blebs in trabeculectomy:

- biomicroscopy and functionality. *Curr Opin Ophthalmol* 1998;9(2):2-8
- 2 Chen CW, Huang HT, Bair JS, Lee CC. Trabeculectomy with simultaneous topical application of mitomycin-C in refractory glaucoma. *J Ocul Pharmacol* 1990;6(3):175-182
- 3 Khaw PT, Sherwood MB, MacKay SL, Rossi MJ, Schultz G. Five-minute treatments with fluorouracil, floxuridine, and mitomycin have long-term effects on human Tenon's capsule fibroblasts. *Arch Ophthalmol* 1992;110(8):1150-1154
- 4 Singh K, Mehta K, Shaikh NM, Tsai JC, Moster MR, Budenz DL, Greenfield DS, Chen PP, Cohen JS, Baerveldt GS, Shaikh S. Trabeculectomy with intraoperative mitomycin C versus 5-fluorouracil. Prospective randomized clinical trial. *Ophthalmology* 2000;107(12):2305-2309
- 5 Beckers HJ, Kinders KC, Webers CA. Five-year results of trabeculectomy with mitomycin C. *Graefes Arch Clin Exp Ophthalmol* 2003;41(2):106-110
- 6 Cohen LB, Graham TF, Fry WE. Beta radiation; as an adjunct to glaucoma surgery in the Negro. *Am J Ophthalmol* 1959;47(1 Part 1):54-61
- 7 Kirwan JF, Cousens S, Venter L, Cook C, Stulting A, Roux P, Murdoch I. Effect of beta radiation on success of glaucoma drainage surgery in South Africa: randomised controlled trial. *BMJ* 2006;333(7575):942
- 8 Fendi LI, Arruda GV, Costa VP, Paula JS. Meta-analysis of beta radiation augmentation for trabeculectomy—results in distinct ethnic groups. *Arq Bras Oftalmol* 2011;74(4):300-305
- 9 Memarzadeh F, Varma R, Lin LT, Parikh JG, Dustin L, Alcaraz A, Elliott D. Postoperative use of bevacizumab as an antifibrotic agent in glaucoma filtration surgery in the rabbit. *Invest Ophthalmol Vis Sci* 2009;50(7):3233-3237
- 10 Reibaldi A, Uva MG, Longo A. Nine-year follow-up of trabeculectomy with or without low-dosage mitomycin-c in primary open-angle glaucoma. *Br J Ophthalmol* 2008;92(12):1666-1670
- 11 Monteiro-Grillo I, Gaspar L, Monteiro-Grillo M, Pires F, Ribeiro da Silva JM. Postoperative irradiation of primary or recurrent pterygium: results and sequelae. *Int J Radiat Oncol Biol Phys* 2000;48(3):865-869
- 12 Shimazaki J, Yang HY, Tsubota K. Amniotic membrane transplantation for ocular surface reconstruction in patients with chemical and thermal burns. *Ophthalmology* 1997;104(12):2068-2076
- 13 Dua HS, Gomes JA, King AJ, Maharajan VS. The amniotic membrane in ophthalmology. *Surv Ophthalmol* 2004;49(1):51-77
- 14 Demir T, Turgut B, Akyol N, Ozercan I, Ulaş F, Celiker U. Effects of amniotic membrane transplantation and mitomycin C on wound healing in experimental glaucoma surgery. *Ophthalmologica* 2002;216(6):438-442
- 15 Demir T, Turgut B, Celiker U, Ozercan I, Ulaş F, Akyol N. Effects of ocreotide acetate and amniotic membrane on wound healing in experimental glaucoma surgery. *Doc Ophthalmol* 2003;107(2):87-92
- 16 Bruno CA, Eisengart JA, Radenbaugh PA, Moroi SE. Subconjunctival placement of human amniotic membrane during high risk glaucoma filtration surgery. *Ophthalmic Surg Lasers Imaging* 2006;37(3):190-197
- 17 Eliezer RN, Kasahara N, Caixeta-Umbelino C, Pinheiro RK, Mandia C Jr, Malta RF. Use of amniotic membrane in trabeculectomy for the treatment of glaucoma: a pilot study. *Arq Bras Oftalmol* 2006;69(3):309-312
- 18 Wang Y, Nie L. Use of the anterior chamber maintainer in trabeculectomy following vitrectomy. *Curr Eye Res* 2011;36(3):232-237
- 19 Suzuki R, Dickens CJ, Iwach AG, Hoskins HD Jr, Hetherington J Jr, Juster RP, Wong PC, Klufas MT, Leong CJ, Nguyen N. Long-term follow-up successful trabeculectomy with 5-fluorouracil injections. *Ophthalmology* 2002;109(10):1921-1924
- 20 The Fluorouracil Filtering Surgery Study Group. Five-year follow-up of the Fluorouracil Filtering Surgery study. *Am J Ophthalmol* 1996;121(4):349-366
- 21 Budenz DL, Barton K, Tseng SC. Amniotic membrane transplantation for repair of leaking glaucoma filtering blebs. *Am J Ophthalmol* 2000;130(5):580-588
- 22 Amini H, Kiarudi MY, Moghimi S, Fakhraie G, Amini N. Ahmed glaucoma valve with adjunctive amniotic membrane for refractory glaucoma. *J Ophthalmic Vis Res* 2010;5(3):158-161
- 23 Liu J, Sheha H, Fu Y, Liang L, Tseng SC. Update on amniotic membrane transplantation. *Expert Rev Ophthalmol* 2010;5(5):645-661
- 24 Anand A, Sheha H, Teng CC, Liebmann JM, Ritch R, Tello C. Use of amniotic membrane graft in glaucoma shunt surgery. *Ophthalmic Surg Lasers Imaging* 2011;42(3):184-189
- 25 Sheha H, Kheirkhah A, Taha H. Amniotic membrane transplantation in trabeculectomy with mitomycin C for refractory glaucoma. *J Glaucoma* 2008;17(4):303-307
- 26 Barton K, Budenz DL, Khaw PT, Tseng SC. Glaucoma filtration surgery using amniotic membrane transplantation. *Invest Ophthalmol Vis Sci* 2001;42(8):1762-1768
- 27 Zhong Y, Zhou Y, Wang K. Effect of amniotic membrane on filtering bleb after trabeculectomy in rabbit eyes. *Yan Ke Xue Bao* 2000;16(2):73-76, 83
- 28 Stavarakas P, Georgopoulos G, Milia M, Papaconstantinou D, Bafa M, Stavarakas E, Moschos M. The use of amniotic membrane in trabeculectomy for the treatment of primary open-angle glaucoma: a prospective study. *Clin Ophthalmol* 2012;6:205-212
- 29 Skuta G.L, Parrish RKII. Wound healing in glaucoma filtering surgery. *Surv Ophthalmol* 1987;32(3):149-170