

# Measurements of anterior segment parameters using three different non-contact optical devices in keratoconus patients

Ahmet Taylan Yazıcı<sup>1</sup>, Gökhan Pekel<sup>2</sup>, Ercüment Bozkurt<sup>1</sup>, Yusuf Yıldırım<sup>1</sup>, Evre Pekel<sup>1</sup>, Ahmet Demirok<sup>1</sup>, Ömer Faruk Yılmaz<sup>1</sup>

<sup>1</sup>Beyoğlu Eye Training and Research Hospital, Istanbul 34000, Turkey

<sup>2</sup>Department of Ophthalmology, Pamukkale University, Denizli 20000, Turkey

**Correspondence to:** Gökhan Pekel. Department of Ophthalmology, Pamukkale University, Denizli 20000, Turkey. gkhanpekel@yahoo.com

Received: 2012-08-15

Accepted: 2013-06-18

## Abstract

• **AIM:** To evaluate the measurements of anterior segment parameters using three different non-contact optical devices in keratoconus patients.

• **METHODS:** A hundred and one eyes of 55 keratoconus patients were enrolled in this study. The mean age was 26.2±8.9 years. The inclusion criteria were keratoconus stage I to III according to the Amsler-Krumeich keratoconus classification. All the measurements were done by the same operator, under the mesopic light condition and repeated with three different optical methods; Visante, Orbscan and Pentacam. The evaluated anterior segment parameters were anterior chamber depth (ACD), central and thinnest corneal thickness (CCT and TCT) and pupil diameter (PD).

• **RESULTS:** The mean CCT measured by Visante, Orbscan and Pentacam were as follows: 462.0±48.1µm, 463.9±60.9µm, 476.5±45.3µm, respectively ( $P=0.873$ ). The mean ACD values were 3.34±0.33mm, 3.26±0.33mm, 3.49±0.40mm, respectively ( $P=0.118$ ). The mean PD measurements were 5.11±1.14mm, 4.80±0.85mm, 3.80±1.38mm, respectively ( $P<0.001$ ). The mean TCT measurements of Visante, Orbscan and Pentacam were 437.9±48.2µm, 447.6±60.6µm and 459.9±44.0µm, respectively ( $P=0.214$ ). The Visante and Orbscan measured CCT similarly, while Pentacam measured CCT thicker than the other two. The Visante measured TCT thinner than the other two devices. In ACD measurements, Orbscan was the one giving the lowest values. PD was measured differently by the devices.

• **CONCLUSION:** Although TCT, CCT and ACD measurements acquired by Visante, Orbscan and Pentacam in keratoconus patients are similar, PD

measurements show large differences among the devices.

• **KEYWORDS:** Visante; Orbscan; Pentacam; corneal pachymetry; anterior chamber depth; pupil diameter

**DOI:10.3980/j.issn.2222-3959.2013.04.21**

Yazıcı AT, Pekel G, Bozkurt E, Yıldırım Y, Pekel E, Demirok A, Yılmaz ÖF. Measurements of anterior segment parameters using three different non-contact optical devices in keratoconus patients. *Int J Ophthalmol* 2013;6(4):521-525

## INTRODUCTION

Keratoconus is a disorder characterized by progressive corneal steepening, most typically inferior to the center of the cornea, with eventual corneal thinning, induced myopia, and both regular and irregular astigmatism<sup>[1]</sup>. In advanced cases, corneas will have a conical shape, and in most of the cases, the disease is bilateral. It classically has its onset at puberty and is progressive until the third to fourth decade of life<sup>[1]</sup>.

Using devices that reveals the fine corneal topography is a sensitive method to confirm the diagnosis of keratoconus. The developments in the corneal topographies from placido systems to slit-based systems allowed us a potential three-dimensional view of both anterior and posterior corneal surfaces<sup>[2]</sup>. Both placido disc topography and slit-scanning topography devices, although they may have false-positive and -negative results, still seem to be reliable for screening keratoconus patients<sup>[3]</sup>.

Together with the development of new treatment modalities in keratoconus, the precision in ocular measurements has gained much importance. Exact measurement of corneal thickness (CT) is crucial in follow-up of keratoconus patients. Until recently, ultrasonic biometry was the most commonly used method for anterior chamber depth (ACD) and CT measurements. In addition to the risk of creating corneal epithelial defect, great variability among the results due to indentation of the probe and off the axis measurements are the main disadvantages of this technique<sup>[4,5]</sup>. That's why non contact devices are more preferred today<sup>[6]</sup>. The Orbscan, Visante OCT and Pentacam are some of the non-contact devices for anterior segment evaluation.

## Anterior segment measurements in keratoconus

The Visante OCT (Carl Zeiss Meditec, California, USA) is a relatively new optically based method designed to evaluate especially the anterior segment structures with a high resolution. The device uses low coherence interferometer principle which works very similar to A-scan ultrasonography. It has an image acquisition time of 0.125s per cross-section for overall anterior segment examination. An already established method for anterior segment evaluation is Orbscan I/z (Bausch & Lomb, Rochester, NY, USA). It acquires over 9 000 data points in 1.5s to map the entire corneal surface. It uses two different techniques; by placido disc system anterior corneal topography is screened and an elevation map is created, and by horizontally moving camera, scanning slit images are acquired. The Pentacam (Oculus, Lynnwood, WA, USA) is another recently developed non contact optical device that uses a rotating Scheimpflug camera. The camera takes multiple slit images in 2s by rotating 180 degrees around the eye. Any involuntary movement of the eye is detected by another camera that controls centration and adjusts the examinations.

Since topography devices help us in the diagnosis, follow-up and treatment decisions in keratoconus, it is important to have a device that makes reliable and consistent measurements [7]. In the literature there are reports about comparison of the topography devices among normal subjects. But there is lack of knowledge about performances and comparisons of these diagnostic topography devices on keratoconus patients. In this study, our aim was to compare measurements of these devices in keratoconus patients and thus fill the gap in this area.

### SUBJECTS AND METHODS

**Subjects** A hundred and one eyes of 55 keratoconus patients (33 male, 22 female) were enrolled in the study. The mean age was  $26.2 \pm 8.9$  years (range 13-58 years). All measurements were done by the same operator, under the mesopic light condition and repeated with three different optical methods: Visante, Orbscan and Pentacam.

**Methods** The diagnosis of keratoconus was based on slit-lamp findings and corneal images generated by these three optical devices. The inclusion criteria were keratoconus stage I to III according to the Amsler-Krumeich keratoconus classification for all the participants. All the eyes were phakic. Patients with history of ophthalmic surgery or any significant ophthalmic disease other than keratoconus were excluded. Pellucid marginal degeneration and keratoglobus patients were also excluded.

All eyes underwent an extensive ophthalmological examination that included visual acuity measurements, manifest refraction, slit-lamp biomicroscopy, the Goldmann tonometry, and fundus examination. This study followed the tenets of the Declaration of Helsinki and informed consent was taken from all the participants after explaining the nature

**Table 1** The mean values  $\pm$  standard deviation (SD) of CCT, TCT, ACD and PD obtained by all three methods

Parameters	Visante	Orbscan	Pentacam	P
CCT ( $\mu$ m)	462.0 $\pm$ 48.1	463.9 $\pm$ 60.9	476.5 $\pm$ 45.3	0.873
TCT ( $\mu$ m)	437.9 $\pm$ 48.2	447.6 $\pm$ 60.6	459.9 $\pm$ 44.0	0.214
ACD (mm)	3.34 $\pm$ 0.33	3.26 $\pm$ 0.33	3.49 $\pm$ 0.40	0.118
PD (mm)	5.11 $\pm$ 1.14	4.80 $\pm$ 0.85	3.80 $\pm$ 1.38	<0.001

of the study.

The order of topographic measurements was set randomly. ACD is defined as the distance from the posterior surface of the cornea (endothelium) to the anterior surface of the lens surface. Pupil diameter measurements were done under the same lightening conditions.

During the examinations with the Visante OCT (Carl Zeiss Meditec), the patient was placed in front of the device and put the chin on a chin rest. After the real time image was optimally aligned the scan was performed. For alignment the optically produced corneal reflex became visible as a vertical white line along the center of the cornea. At the end, using the anterior segment images ACD and pupil diameter (PD) measurements were manually done. Central and thinnest corneal thickness (CCT and TCT) were noted from the corneal thickness map.

The Orbscan I/z (Bausch & Lomb) scanning slit imaging was performed again in the same chin rest and forehead position. The screen image of the eye was centered and aligned manually by looking at the reflection of slit-lamp light on the cornea. The patients were asked to keep the eyes open and not move. Corneal measurements in Orbscan were done with acoustic correction factor of 0.94. CCT, TCT, ACD and PD values for each patient were recorded.

The Pentacam (Oculus) was performed with the patient seated again in the same position. The patient was asked to fixate on a fixation target in the center of the camera. The real time image on the computer screen was adjusted manually by moving the pentacam in the directions indicated on the screen. As the image was aligned the scan was performed automatically in two seconds time. CCT, TCT, ACD and PD values for each patient were noted.

**Statistical Analysis** Parameters from all the three methods were assessed using SPSS 14.0 for Windows. ANOVA and *t*-test was performed to see if any difference was present between the measurements.  $P < 0.05$  was regarded as statistically significant.

### RESULTS

The highest mean CCT value was obtained with Pentacam, TCT with Pentacam, ACD with Pentacam and PD with Visante. The mean CCT, TCT, ACD and PD results are shown in Table 1. The comparison by ANOVA showed that CCT and ACD measurements did not differ statistically significantly between devices; but PD measurements differ

significantly from each other.

The mean CCT measurements of Visante and Orbscan were very similar while Pentacam measured CCT insignificantly thicker. The greatest difference was found between Visante and Pentacam which was computed to be 2.9%. When CCT measurements of Pentacam and Visante were compared, there was a difference greater than 15 $\mu$ m in 39 eyes (39%). The highest difference between these measurements was 90 $\mu$ m in one eye. The mean value of the differences between these two devices was 19 $\mu$ m; When CCT measurements of Orbscan and Visante were compared, there was a difference greater than 15 $\mu$ m in 51 eyes (51%). The highest difference between these measurements was 96 $\mu$ m in one eye. The mean value of the differences between these two devices was 22 $\mu$ m; When CCT measurements of Orbscan and Pentacam were compared, there was a difference greater than 15 $\mu$ m in 39 eyes (39%). The highest difference between these measurements was 118 $\mu$ m in one eye. The mean value of the differences between the two devices was 21 $\mu$ m.

The mean ACD measurements were similar between Visante and Orbscan, while Pentacam was the one measuring ACD insignificantly wider. The greatest difference between the mean values was 6.6% between Orbscan and Pentacam. All the three methods measured PD significantly different from each other. The highest values were obtained with Visante and the lowest ones with Pentacam.

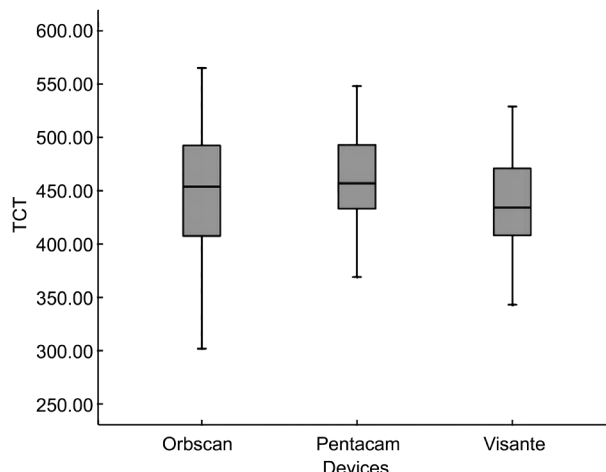
Figure 1 shows the mean TCT measurements of Visante, Orbscan and Pentacam and distribution of the measurement values.

For TCT measurements, the greatest difference was found between Visante and Pentacam which was computed to be 4.8%. Bland-Altman plots for comparison between different devices (Orbscan, Pentacam and Visante) for the TCT measurements were shown in Figure 2.

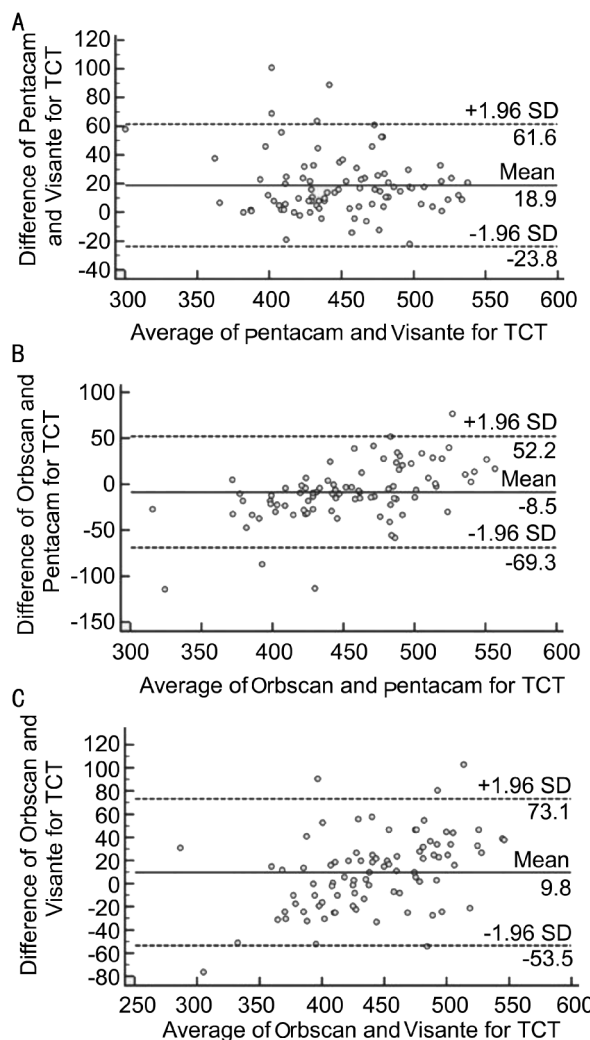
**DISCUSSION**

In the past, ultrasonic biometry was accepted as the main method in evaluating and measuring anterior segment structures. However, being a contact device it has some disadvantages that lead non contact methods (such as Orbscan, Pentacam or IOL Master) to be more preferable today. Indentation on the cornea by probe results in lower ACD values while decentralization and off the axis measurements lead to higher corneal pachymetric and variable ACD values. Also, the repeatability and reproducibility of CCT and ACD measurements using Visante, Orbscan and Pentacam are shown to be high when compared with ultrasonic biometry<sup>[8-10]</sup>.

The Visante, Orbscan and Pentacam enable detection of small changes in the topography of the corneal surface and permit detailed quantitative and qualitative analysis of the corneal shape. Corneal surface topography remains fundamental in the detection and monitoring of keratoconus,



**Figure 1 TCT measurements by Orbscan, Pentacam and Visante OCT** The plots depicting the distribution of indices for between-group comparisons, TCT: thinnest corneal thickness ( $\mu$ m).



**Figure 2 Bland –Altman plots for comparison among groups for TCT measurements ( $\mu$ m)** A: Pentacam and Visante; B: Orbscan and Pentacam; C: Orbscan and Visante.

especially for corneas with irregular astigmatism and other hard-to-treat abnormalities <sup>[11]</sup>. Besides topographical maps, it is also important to know the corneal thickness, ACD and PD in keratoconus patients for proper treatment preference.

Since keratoconus is a progressive ectasia, in which the cornea gradually protrudes and adopts a conical shape; it is very important to have methods that have high repeatability and reproducibility. And also, it is essential to get the exact knowledge about the shape and the location of the ectatic part of the cornea. The Visante, Orbscan and Pentacam meet our needs in the aspect of these factors.

As these three devices gather data from the eye using different physical and optical techniques, it might be expected that some differences could occur among measurement values. In addition to the systematic differences of the devices, we believe that the light used is also important as it behaves differently in different media. The Orbscan acquires images with visible white light, while monochromatic 475nm blue light have the same function in Pentacam and 1 310nm diode laser in Visante OCT.

In our study, the mean CCT measurements of Visante and Orbscan were very similar while Pentacam measured CCT insignificantly thicker. There was no statistically important difference among these devices in CCT measurements. In studies with healthy subjects, mean CCT values measured with Visante were ranged between 527 $\mu$ m-538 $\mu$ m, with Orbscan 530 $\mu$ m-553 $\mu$ m and with Pentacam 538 $\mu$ m-559 $\mu$ m<sup>[12-15]</sup>. Although, the study group and the methods were not identical with our study, Pentacam had measured slightly higher values similar to our results.

In our study, the mean TCT measurements of Visante, Orbscan and Pentacam were 437.9 $\pm$ 48.2 $\mu$ m, 447.6 $\pm$ 60.6 $\mu$ m and 459.9 $\pm$ 44.0 $\mu$ m, respectively ( $P=0.214$ ). Quisling *et al*<sup>[16]</sup> found that both the Pentacam and Orbscan Iiz determined similar thinnest points, but had a measurable difference in posterior elevations above the best-fit sphere, despite similar radii of curvature in keratoconus patients. Jhanji *et al*<sup>[17]</sup> reported that corneal thickness measurements were different between swept source OCT (SS-OCT) and Orbscan Iiz and concluded that SS-OCT might provide more reliable corneal measurements due to better reproducibility and faster scan speed.

It is well known that ACD changes according to the accommodative status of the eye<sup>[18]</sup>. Because there is not a system to block accommodation in Pentacam and Orbscan and a very bright white light is used in Orbscan during the measurements, a strong accommodation occurs. In Visante, there is a distant fixation target to impede the accommodation, and also the diode light does not interfere with the light of the media. But also in Visante, the vertex point is marked by the operator and the measurements are done manually. In our study all measurements were done in the same room under mesopic condition and without using any cycloplegic medication. ACD measurements were done at the corneal center (not at the thinnest point). The mean ACD results of Pentacam, Visante and Orbscan did not differ

statistically significantly from each other. However, the values of Pentacam were the highest and the values of Orbscan were the lowest. Edmonds *et al*<sup>[19]</sup> measured ACD as 3.28 $\pm$ 0.40mm with Pentacam in keratoconus patients. Dinc *et al*<sup>[20]</sup> found that the mean ACD was 2.98 $\pm$ 0.29mm, 2.93 $\pm$ 0.30mm and 2.80 $\pm$ 0.29mm with Visante OCT, Pentacam and Orbscan Iiz, respectively, in normal healthy eyes.

PD measurements were significantly different between the three devices, since these devices have different illumination means during the measurements. In addition Visante induces little accommodation which means larger pupil. In our study, the largest PD values were measured by Visante and the smallest PD by Pentacam. The large differences in mean PD values showed us that those methods are not suitable for sensitive PD measurements. Several devices are available for precise measurements of PD. Although we did not have the opportunity to use it, some reports agreed that computerized dynamic video pupillometers are considered very reliable because they take multiple measurements of the highly motile pupil during a single measurement period under standardized illumination levels<sup>[21,22]</sup>.

One of the main limitations of the study is the lack of evaluation of intra and inter-observer reproducibility of the measurements obtained with each instrument. This would have allowed a better insight in the features of each instrument. Also, the lack of comparison with US-Pachymetry was another limitation, since it is still used in many places. But, US-Pachymetry has some disadvantages including the need to anesthetize the cornea, cornea-probe contact, corneal indentation and the possible compression effect during measurement, corneal surface disturbance, which can interfere with other evaluations such as topography and wavefront acquisition, the risk for corneal epithelial damage and transmission of infections, probe misalignment or de-centering of the probe, and great measurement variations due to examiner performance.

In conclusion, although CCT, TCT and ACD measurements acquired by Visante, Orbscan and Pentacam in keratoconus patients were similar, PD measurements showed large differences among the devices. Also, we must always remember that, although the mean CCT and TCT measures were similar, when we focused the results individually, there were some great differences among these devices. So, a question arises about which device measures the most correctly for patients individually. More studies are needed to establish the comparison of the measurements of CCT, TCT, ACD and PD by different devices in keratoconus patients.

## REFERENCES

- 1 Rabinowitz YS. Keratoconus: update and new advances. *Surv Ophthalmol* 1998;42(4):297-319
- 2 Cairns G, McGehee CN. Orbscan computerized topography: attributes, applications, and limitations. *J Cataract Refract Surg* 2005;31(1):205-220

- 3 Charles N, Charles M, Croxatto JO, Charles DE, Wertheimer D. Surface and Orbscan-II slit-scanning elevation topography in circumscribed posterior keratoconus. *J Cataract Refract Surg* 2005;31(3):636-639
- 4 Marsich MW, Bullimore MA. The repeatability of corneal thickness measures. *Cornea* 2000;19(6):792-795
- 5 Miglior S, Albe E, Guareschi M, Mandelli G, Gomasasca S, Orzalesi N. Intraobserver and interobserver reproducibility in the evaluation of ultrasonic pachymetry measurements of central corneal thickness. *Br J Ophthalmol* 2004;88(2):174-177
- 6 Rainer G, Findl O, Petternel V, Kiss B, Drexler W, Skorpik C, Georgopoulos M, Schmetterer L. Central corneal thickness measurements with partial coherence interferometry, ultrasound, and the Orbscan system. *Ophthalmology* 2004;111(5):875-879
- 7 Jhanji V, Sharma N, Vajpayee RB. Management of keratoconus: current scenario. *Br J Ophthalmol* 2011;95(8):1044-1050
- 8 Lackner B, Schmidinger G, Skorpik C. Validity and repeatability of anterior chamber depth measurements with Pentacam and Orbscan. *Optom Vis Sci* 2005;82(9):858-861
- 9 Lackner B, Schmidinger G, Pieh S, Funovics MA, Skorpik C. Repeatability and reproducibility of central corneal thickness measurement with Pentacam, Orbscan and ultrasound. *Optom Vis Sci* 2005;82(10):892-899
- 10 Mohamed S, Lee GK, Rao SK, Wong AL, Cheng AC, Li EY, Chi SC, Lam DS. Repeatability and reproducibility of pachymetric mapping with Visante anterior segment-optical coherence tomography. *Invest Ophthalmol Vis Sci* 2007;48(12):5499-5504
- 11 Rabinowitz YS, McDonnell PJ. Computer-assisted corneal topography in keratoconus. *Refract Corneal Surg* 1989;5(6):400-408
- 12 Zhao PS, Wong TY, Wong WL, Saw SM, Aung T. Comparison of central corneal thickness measurements by visante anterior segment optical coherence tomography with ultrasound pachymetry. *Am J Ophthalmol* 2007;143(6):1047-1049
- 13 Li EY, Mohamed S, Leung CK, Rao SK, Cheng AC, Cheung CY, Lam DS. Agreement among 3 methods to measure corneal thickness: ultrasound pachymetry, Orbscan II, and Visante anterior segment optical coherence tomography. *Ophthalmology* 2007;114(10):1842-1847
- 14 Suzuki S, Oshika T, Oki K, Sakabe I, Iwase A, Amano S, Araie M. Corneal thickness measurements: scanning-slit corneal topography and noncontact specular microscopy versus ultrasonic pachymetry. *J Cataract Refract Surg* 2003;29(7):1313-1318
- 15 Fujioka M, Nakamura M, Tatsumi Y, Kusuhara A, Maeda H, Negi A. Comparison of Pentacam Scheimpflug Camera with ultrasound pachymetry and noncontact specular microscopy in measuring central corneal thickness. *Curr Eye Res* 2007;32(2):89-94
- 16 Quisling S, Sjoberg S, Zimmerman B, Goins K, Sutphin J. Comparison of Pentacam and Orbscan IIz on posterior curvature topography measurements in keratoconus eyes. *Ophthalmology* 2006;113(9):1629-1632
- 17 Jhanji V, Yang B, Yu M, Ye C, Leung CK. Corneal thickness and elevation measurements using swept source optical coherence tomography and slit scanning topography in normal and keratoconic eyes. *Clin Experiment Ophthalmol* 2013
- 18 Baikoff G, Lutun E, Ferraz C, Wei J. Static and dynamic analysis of the anterior segment with optical coherence tomography. *J Cataract Refract Surg* 2004;30(9):1843-1850
- 19 Edmonds CR, Wung SF, Pemberton B, Surrent S. Comparison of anterior chamber depth of normal and keratoconus eyes using Scheimpflug photography. *Eye Contact Lens* 2009;35(3):120-122
- 20 Dinc UA, Gorgun E, Oncel B, Yenerel MN, Alingil L. Assessment of anterior chamber depth using Visante optical coherence tomography, slitlamp optical coherence tomography, IOL Master, Pentacam and Orbscan IIz. *Ophthalmologica* 2010;224(6):341-346
- 21 Kohnen T, Terzi E, Bühren J, Kohnen EM. Comparison of a digital and a handheld infrared pupillometer for determining scotopic pupil diameter. *J Cataract Refract Surg* 2003;29(1):112-117
- 22 Schmitz S, Krummenauer F, Henn S, Dick HB. Comparison of three different technologies for pupil diameter measurement. *Graefes Arch Clin Exp Ophthalmol* 2003;241(6):472-477