

# Vitreo-retinal interface changes on optical coherence tomography in the fellow eyes of patients with macular hole

*Ajit Babu Majji, Jay Kumar Chhablani, Bupesh Bagga*

Smt. Kanuri Santhamma Retina Vitreous Centre, L.V. Prasad Eye Institute, Kallam Anji Reddy Campus, L.V. Prasad Marg, Banjara Hills, Hyderabad 500034, India

**Correspondence to:** Jay Kumar Chhablani. Smt. Kanuri Santhamma Retina Vitreous Centre, L.V. Prasad Eye Institute, Kallam Anji Reddy Campus, L.V. Prasad Marg, Banjara Hills, Hyderabad 500034, India. jay.chhablani@gmail.com

Received: 2012-11-09

Accepted: 2013-06-06

## Abstract

• **AIM:** To study the vitreo-retinal interface and macular changes on optical coherence tomography (OCT) in the fellow eyes of patients with macular hole.

• **METHODS:** Patients with idiopathic macular hole in one or both eyes presented to our institute between January 2003 and December 2009 were evaluated retrospectively. Demographic details, best-corrected visual acuity and vitreo-retinal interface, and macular changes of the fellow eye on OCT were studied.

• **RESULTS:** Seventy patients underwent OCT of both eyes during the study period. The average age group was 61.96 years and 35 (50%) were females. Among the fellow eyes, normal foveal contour was noted in 36 (51.4%) eyes and 34 (48.6%) eyes were observed to have vitreo-retinal interface changes. Of them, 13 (18.6%) eyes had some stage of full thickness macular hole and 21 (30.0%) eyes had interface changes. There was no statistical correlation between involved eye lesions ( $P=0.64$ ) or visual acuity ( $P=0.55$ ) as predictors of development of either fellow eye lesions or poor visual acuity.

• **CONCLUSION:** There is a significant chance of having vitreo-retinal interface findings in the fellow eyes of patients presenting with macular hole. OCT should be considered in both eyes of patients with macular hole to detect early changes in the fellow eyes, which may require an early intervention.

• **KEYWORDS:** macular hole; fellow eye; optical coherence tomography; vitreo-retinal interface

**DOI:** 10.3980/j.issn.2222-3959.2013.04.22

Majji AB, Chhablani JK, Bagga B. Vitreo-retinal interface changes on optical coherence tomography in the fellow eyes of patients with macular hole. *Int J Ophthalmol* 2013;6(4):526-530

## INTRODUCTION

Understanding the relationship of vitreo-retinal interface emerging is a very important factor in understanding the macular hole formation, especially with the introduction of optical coherence tomography (OCT) [1]. Although the pathogenesis of idiopathic macular holes was not yet clear, OCT helped in understanding the different stages of macular holes and their evolutions [2]. OCT observations made regarding development of full thickness macular holes and the changes in their fellow eye by Gaudric and co-workers provided strength to the tangential traction theory proposed by Gass as a mechanism for the development of macular hole [2-4]. Spontaneous resolution of impending macular holes by the release of vitreo macular traction demonstrated by OCT, further support tangential traction as pathogenic mechanism for the development of macular hole [5,6].

The incidence of development of full thickness macular hole in the fellow eyes of patients with full thickness macular hole in one eye was reported to vary from 1.2% to 31% [7-13]. The vitreo-retinal interface changes caught more attention after the introduction of OCT and was studied by only a few observers, reported to be present in 31.8% to 47% [6,13-16]. The purpose of the current study is to evaluate the vitreoretinal interface changes in fellow eyes of patients with macular holes and to correlate the changes on OCT with those reported in the past, to draw reasonable conclusions towards the pathogenesis of macular hole formation.

## SUBJECTS AND METHODS

**Subjects** A retrospective chart review of patients with macular hole who attended our Retina Vitreous Services, between January 2003 and December 2009 was carried out. An institutional review board and ethics committee approval was obtained to conduct the study (Ethics approval # LEC-08197). All patients with a diagnosis of macular hole in one or both eyes, with OCT done for both eyes, were included for analysis. Stratus OCT was used in all patients, as spectral domain OCT was started at our institute only from the latter half of 2009. All patients underwent simultaneous

fundus photography as well as OCT. All eyes with macular holes were evaluated with OCT 3 (Carl Zeiss Meditec, Dublin, CA). OCT 3 provides a maximum of 512 (transverse) 61 024 (axial) data points per image, acquired in 1.92s, and longitudinal/axial resolution is 10µm and transverse resolution is 20µm. All images were captured using the Macular Thickness Map protocol, which is a version of the radial lines pattern. It consists of a series of 6 to 24 equally spaced line scans through a common central axis. The diameter of the aiming circle (and thus line length) is fixed at 6mm. The number of lines is adjustable until you save the first scan in the series. This protocol is designed for the analyses that measure retinal thickness. Images were then processed using the Retinal Thickness/Volume protocol, and the software caliper was used to obtain parameters on macular defects. All six radial scans were examined to find the scan, which revealed the deepest and widest defect from which all measurements were obtained. Measurements of base diameters and depths were made to the most lateral extent of the intraretinal split. Macular holes were classified on the basis of the classification given by Gass and OCT classification by Gaudric *et al*<sup>[3]</sup> stage 1A: a central yellow macular spot and loss of foveal depression and vitreous attached over the fovea, stage 1B: yellow ring with bridging interface, loss of the foveal depression and vitreous attached over the fovea; stage 2: a small full thickness retinal hole inside the yellow ring; stage 3: diameter less than 400 micron hole with rim of elevated retina, the premacular vitreous is still attached and no Weiss ring present, and stage 4: diameter more than 400 micron hole with separation of the posterior hyaloid from the macula and optic disc.

**Methods** Demographic details including age, gender, presenting symptoms, duration of presentation, visual acuity, intraocular pressure, anterior segment and fundus findings were noted. A note of stage of macular holes in the involved and the fellow eye, as applicable, and details of vitreo-retinal interface changes including presence of epiretinal membrane, vitreomacular traction and foveal thickness were made.

Patients with idiopathic macular holes were included in the study. Patients who underwent OCT in both eyes were included in the study. Patients with significant media opacities obscuring fundus photo or OCT evaluation were excluded from the analysis. Patients with macular hole secondary to causes other than idiopathic macular holes, like traumatic macular holes or secondary macular holes secondary to diabetic macular edema, cystoid macular edema were excluded from the study. Patients with lamellar hole in the primary eye were also excluded from the study. Patients with retinal conditions other than macular hole in either eye were excluded from the study. Fellow eyes that underwent any intraocular surgery were also excluded.

**Table 1 BCVA distribution in involved and fellow eyes n(%)**

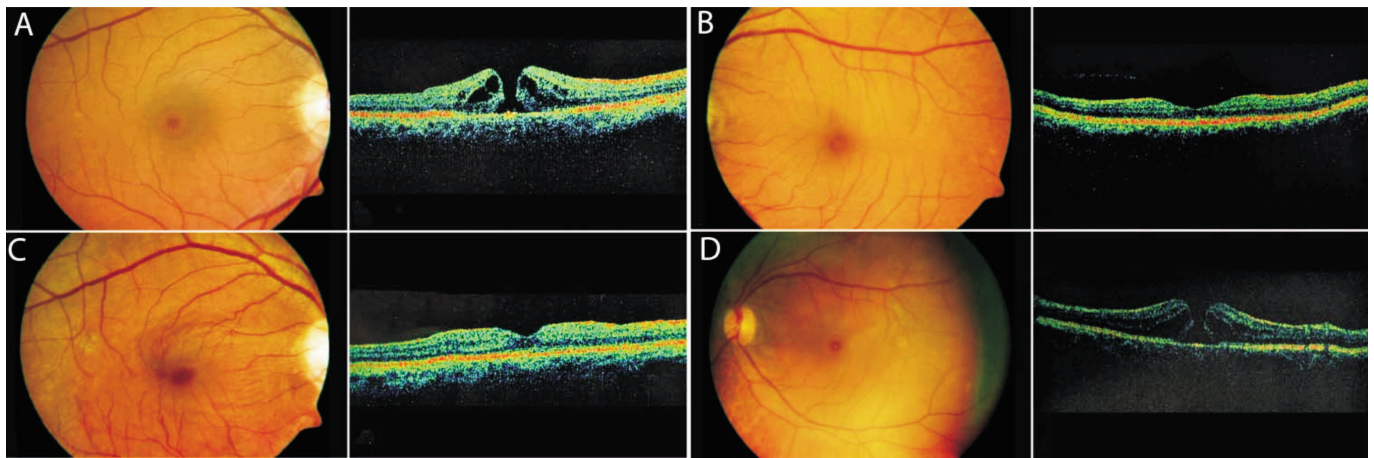
BCVA range	Involved eye	Fellow eye
20/20- 20/40	2 (2.9)	37 (52.8)
20/50-20/80	4 (5.7)	13 (18.6)
20/100-20/200	43 (61.4)	19 (27.2)
20/400 or less	21 (30.0)	1(1.4)

**Statistical Analysis** Statistical analysis was done using SPSS software. Analysis was done to evaluate whether the demographic data, involved eye visual acuity and involved eye lesions be considered significant predictors of fellow eye lesions or visual acuity. Multivariate regression analysis was performed to find the association between various factors such as age, gender, visual acuity, stage of macular hole and the base diameter of the macular hole; and vitreo-macular changes of the fellow eye.

**RESULTS**

A total of 140 eyes of 70 patients were evaluated during the study period. Average age was 61.96 years (40-80 years). Of the 70 patients, 35 (50%) were females and 35 (50%) were males. All patients were having idiopathic macular holes of different stages. The best-corrected visual acuities were better than 20/100 in only 6 (8.6%) eyes in eyes effected with macular holes, while 50 (71.4%) fellow eyes were having better than 20/100 visual acuity (Table 1). Fellow eyes with visual acuities less than 20/100 were in 28.6% patients. There was no significant correlation between age, gender, visual acuities or stage of macular hole in the involved eyes ( $P > 0.05$ , Table 1).

The macular holes in affected eyes were of stage 3 or 4 in 64 (91.4%) eyes, stage 2 in 5 (7.1%) eyes and one eye was in stage 1 (1.4%). Among the 70 fellow eyes, normal foveal contour was noted in 36 (51.4%) eyes. Thirty-four (48.6%) eyes were observed to have vitreo-retinal interface changes (macular hole & other vitreo-retinal changes), of which 13 (38.2%) eyes had some stage of full thickness macular hole and 21 (61.8%) eyes had interface changes other than macular holes. Nine (12.9%) eyes had stage 4 macular hole, 2 (2.9%) eyes had stage 3 macular hole, 2 (2.9%) eyes had stage 1 macular hole and none of the eyes had stage 2 macular holes. Associated findings in fellow eyes included vitreomacular traction 5 (7.1%) eyes, epiretinal membrane in 5 (7.1%) eyes and lamellar macular holes were noted in 4 (5.7%) eyes. Presence of posterior vitreous detachment was the only finding in 4 (5.7%) eyes. Foveal thinning (central foveal thickness less than 170 micron) was seen in 4 (5.7%) eyes. One eye had both epiretinal membrane and lamellar macular hole. There was no significant correlation between the visual acuities or stage of macular hole in the involved eye and the fellow eye lesions ( $P > 0.05$ ). Representative cases were shown in Figure 1.



**Figure 1** Fundus examination of a 58 years old lady using OCT. A: Right eye was revealed with full thickness macular hole; B: OCT of left eye showed normal foveal contour; C: At 3 years follow up, her right eye was stable with normal foveal contour; D: At 3 years follow up, her left eye developed full thickness macular hole.

A 58 years old lady presented to us with complaints of gradual progressive loss of vision in her left eye (OS) since the past 4 months. Her best-corrected visual acuity (BCVA) in the right eye (OD) was 20/80 and OS 20/400. Anterior segment examination was normal in both the eyes, except posterior chamber intraocular lens in the right eye and nuclear sclerosis and posterior subcapsular cataract in the left eye. Fundus examination of OD revealed full thickness macular hole (FTMH) (Figure 1A). OCT of the OS showed normal foveal contour (Figure 1B). The patient underwent pars plana vitrectomy (PPV) with internal limiting membrane (ILM) peeling with gas tamponade (C3F8, Octafluoropropane gas) in OD. At six months of follow up, her BCVA in the right eye was 20/40 and OS 20/400. The patient underwent phacoemulsification with intraocular lens implantation in the left eye. At 3 years follow up, her right eye was stable with normal foveal contour (Figure 1C) but OS developed FTMH (Figure 1D) and vision was 20/160. She underwent PPV, ILM peeling and fluid gas exchange. Post operatively macular hole was closed and vision recovered to 20/30. At 3 years of follow up, her BCVA was 20/20 in OD and 20/30 in OS.

## DISCUSSION

Idiopathic macular hole is usually observed in elderly individuals. Similar to previous reports, in our study, the average age was 61.96 years (40 years to 80 years) with female preponderance. Presentation of macular hole at an elderly age could be a pointer towards vitreoretinal changes as pathogenesis, as partial vitreous detachment is observed around 6<sup>th</sup> decade [17-24]. Gaudric *et al* [3] and Kumagai *et al* [15] demonstrated in fellow eyes of patients with macular hole in the initial stages of posterior vitreous detachment (PVD), the vitreous detachment beginning typically at macular hole periphery and then spreading gradually through out the entire

perifoveal macular area while remaining attached to the apex of the foveola. Gaudric *et al* [3] demonstrated central detachment of the posterior hyaloid over the posterior pole on OCT in 19 cases (31%) and a perifoveal hyaloid detachment not detected on biomicroscopy in 26 cases (42%). Kumagai *et al* [15] demonstrated deformation of fovea associated with vitreofoveal adhesions as significantly higher in fellow eyes of patients with macular hole, compared to patients with other macular pathologies. Thickened vitreous cortex and perifoveal posterior vitreous detachment were physiologic findings in older individuals. The lamellar structure of the vitreous cortex may be related to the vitreoschisis [25]. Our study showed vitreoretinal interface changes other than macular holes in 21/70 (30%) eyes. The implications are that vitreoretinal interface changes are an initiating factor for the development of macular holes.

OCT disclosed various degrees of intrafoveal split or cyst, with adherence of the posterior hyaloid to the foveal center and convex perifoveal detachment in the 4 impending macular holes reported by Gaudric *et al* [3]. Niwa *et al* [4] reported 13 eyes with full-thickness macular hole and 91 eyes with attached posterior hyaloids, 37 eyes with complete PVD. The remaining 60 fellow eyes had a vitreofoveal attachment with a perifoveal vitreous detachment. In these 60 eyes, two eyes had a stage 1B impending macular hole. In contrast, our study showed the presence of complete PVD in only 7.1% eyes. However, some form of vitreo-retinal interface changes (macular hole and other vitreo-retinal changes were observed more commonly in 34/70 (48.6%) eyes. Uchino *et al* [24] observed some stage of posterior vitreous detachment in healthy individuals up to the tune of 71% by high resolution OCT. High incidence of interface changes were observed in fellow eyes of patients with macular hole compared to other ocular pathologies by Kumagai *et al* [15]. Vitreous traction

forces resulting from perifoveal PVD with a small vitreofoveolar adhesion (500 $\mu$  or less) may cause localized cystoid foveal thickening or one of several macular hole conditions<sup>[17]</sup>. Traction associated with larger adhesion zones may cause or exacerbate a separate group of macular disorders<sup>[17]</sup>. Takahashi *et al*<sup>[22]</sup>, observed perifoveal posterior vitreous detachment with vitreofoveal adhesion in the 7 eyes, out of 7 eyes, 2 eyes (29%) with foveal splits progressed to a full-thickness macular hole, and 4 developed pseudocyst. In a study by Gupta *et al*<sup>[26]</sup>, OCT and scanning laser ophthalmoscope showed vitreoschisis in half of the eyes with macular hole and macular pucker, but much less frequently in controls, age related macular degeneration and non proliferative diabetic retinopathy patients. These findings suggest that anomalous PVD with vitreoschisis may be pathogenic in macular hole and macular pucker. All the evidence for tangential traction, warrant a longitudinal observational study to prove in this direction<sup>[25-27]</sup>. Niwa *et al*<sup>[4]</sup> reported the incidence of the change in vitreofoveal relationship was 47% and incidence of an idiopathic full-thickness macular hole was 5.2% , within a follow-up period of 24 months.

Spaide<sup>[21]</sup> showed the importance of OCT in revealing new information about the vitreoretinal relationship. Arevalo *et al*<sup>[7]</sup> shown that 27 (28.7%) of 94 clinically normal fellow eyes, OCT detected an abnormality of the vitreoretinal interface but normal foveal anatomy. They defined it as stage 0 macular hole. Chan *et al*<sup>[28]</sup> reported a macular hole-free survival at 48 months was 94% for stage 0-negative patients (67 patients), *vs* 54% for stage 0-positive patients (27 patients). We have observed that 30% of patients were having stage 0 macular hole changes in the fellow eyes. Spaide *et al*<sup>[29]</sup> in their study found that the diameter of the vitreous attachment in eyes with partial PVD correlated with induced changes in foveal anatomy. According to Ezra *et al*<sup>[9]</sup> the incidence of developing macular hole in fellow eye is 15.6%. In our study, around 24.6 % had full thickness macular hole, but more importantly, a very high percentage of patients had significant OCT changes, especially foveal thinning (central foveal thickness less than 170 micron) was observed in 4 (5.7% ) eyes. Foveal thinning is described as one of the pre-macular hole stages that needs to be focused upon during prospective observational studies<sup>[30]</sup>.

Our study had the inherent limitations of being a retrospective study. This study has been carried by OCT 3, a spectral domain OCT might have picked up more findings in the fellow eye due to its higher resolution. Except for a few patients, this study does not have long term follow-up by serial OCT, which could have added more information.

Changes of the vitreoretinal relationship should be studied in a prospective manner to know and confirm the sequential progression and changes observed during the natural course leading to hole formation.

In conclusion, our study observations indicate OCT should be done in the fellow eyes, in addition to the evaluation involved eye, as a part of work-up of patients with macular hole. Vitreoretinal interface changes are likely to be observed in high percentage of fellow eyes in patients with macular hole. Detection of early changes in fellow eyes warrants the need for closer follow-up or an early intervention. Although the OCT findings were not statistically significant either in predicting occurrence of macular hole or visual outcome, they may indicate various stages of pre- macular hole and may warrant closer follow-up. Prospective observational studies may help in defining the role of vitreoretinal changes in macular hole development.

#### REFERENCES

- 1 Gass JD. Idiopathic senile macular hole: its early stages and pathogenesis. *Arch Ophthalmol* 1988;106(5):629-639
- 2 Gass JD. Reappraisal of biomicroscopic classification of stages of development of a macular hole. *Am J Ophthalmol* 1995;119(6):752-759
- 3 Gaudric A, Haouchine B, Massin P, Paques M, Blain P, Erginay A. Macular hole formation: new data provided by optical coherence tomography. *Arch Ophthalmol* 1999;117(6):744-751
- 4 Niwa H, Terasaki H, Ito Y, Miyake Y. Macular hole development in fellow eyes of patients with unilateral macular hole. *Am J Ophthalmol* 2005;140(3):370-375
- 5 Barak Y, Sherman MP, Schaal S. Mathematical analysis of specific anatomic foveal configurations predisposing to the formation of macular holes. *Invest Ophthalmol Vis Sci* 2011;52(11):8266-8270
- 6 Haouchine B, Massin P, Tadayoni R, Erginay A, Gaudric A. Diagnosis of macular pseudoholes and lamellar macular holes by optical coherence tomography. *Am J Ophthalmol* 2004;138(5):732-739
- 7 Arevalo JF, Mendoza AJ, Velez-Vazquez W, Rodriguez FJ, Rodriguez A, Rosales-Meneses JL, Yopez JB, Ramirez E, Dessouki A, Chan CK, Mitra RA, Ramsay RC, Garcia RA, Ruiz-Moreno JM. Full-thickness macular hole after LASIK for the correction of myopia. *Ophthalmology* 2005;112(7):1207-1212
- 8 Bronstein MA, Trempe CL, Freeman HM. Fellow eyes of eyes with macular holes. *Am J Ophthalmol* 1981;92(6):757-761
- 9 Ezra E, Wells JA, Gray RH, Kinsella FM, Orr GM, Grego J, Arden GB, Gregor ZJ. Incidence of idiopathic full-thickness macular holes in fellow eyes: a 5-year prospective natural history study. *Ophthalmology* 1998;105(2):353-359
- 10 Haouchine B, Massin P, Gaudric A. Foveal pseudocyst as the first step in macular hole formation: a prospective study by optical coherence tomography. *Ophthalmology* 2001;108(1):15-22
- 11 Hee MR, Puliafito CA, Wong C, Duker JS, Reichel E, Schuman JS, Swanson EA, Fujimoto JG. Optical coherence tomography of macular holes. *Ophthalmology* 1995;102(5):748-756
- 12 Morgan CM, Schatz H. Idiopathic macular holes. *Am J Ophthalmol*

1985;99(4):437–444

13 Takahashi A, Yoshida A, Nagaoka T, Kagokawa H, Kato Y, Takamiya A, Sato E, Yokota H, Ishiko S, Hirokawa H. Macular hole formation in fellow eyes with a perifoveal posterior vitreous detachment of patients with a unilateral macular hole. *Am J Ophthalmol* 2011;151(6):981–989

14 Chew EY, Sperduto RD, Hiller R, Nowroozi L, Seigel D, Yanuzzi LA, Burton TC, Seddon JM, Gragoudas ES, Haller JA, Blair NP, Farber M. Clinical course of macular holes: the Eye Disease Case–Control Study. *Arch Ophthalmol* 1999;117(2):242–246

15 Kumagai K, Hangai M, Larson E, Ogino N. Vitreoretinal interface and foveal deformation in asymptomatic fellow eyes of patients with unilateral macular holes. *Ophthalmology* 2011;118(8):1638–1644

16 Trempe CL, Weiter JJ, Furukawa H. Fellow eyes in cases of macular hole. Biomicroscopic study of the vitreous. *Arch Ophthalmol* 1986;104(1):93–95

17 Johnson MW. Posterior vitreous detachment: evolution and complications of its early stages. *Am J Ophthalmol* 2010;149(3):371–382

18 Johnson MW, Van Newkirk MR, Meyer KA. Perifoveal vitreous detachment is the primary pathogenic event in idiopathic macular hole formation. *Arch Ophthalmol* 2001;119(2):215–222

19 Lewis ML, Cohen SM, Smiddy WE, Gass JD. Bilaterality of idiopathic macular holes. *Graefes Arch Clin Exp Ophthalmol* 1996;234(4):241–245

20 Michalewska Z, Michalewski J, Sikorski BL, Kałuzny JJ, Wojtkowski M, Adelman RA, Nawrocki J. A study of macular hole formation by serial spectral optical coherence tomography. *Clin Experiment Ophthalmol* 2009;37(4):373–383

21 Spaide RF. Measurement of the posterior precortical vitreous pocket in

fellow eyes with posterior vitreous detachment and macular holes. *Retina* 2003;23(4):481–485

22 Takahashi A, Nagaoka T, Yoshida A. Stage 1–A macular hole: a prospective spectral–domain optical coherence tomography study. *Retina* 2011;31(1):127–147

23 Takezawa M, Toyoda F, Kambara C, Yamagami H, Kakehashi A. Clarifying the mechanism of idiopathic macular hole development in fellow eyes using spectral–domain optical coherence tomography. *Clin Ophthalmol* 2011;5:101–108

24 Uchino E, Uemura A, Ohba N. Initial stages of posterior vitreous detachment in healthy eyes of older persons evaluated by optical coherence tomography. *Arch Ophthalmol* 2001;119(10):1475–1479.

25 Itakura H, Kishi S. Aging changes of vitreomacular interface. *Retina* 2011;31(7):1400–1404

26 Gupta P, Yee KM, Garcia P, Rosen RB, Parikh J, Hageman GS, Sadun AA, Sebag J. Vitreoschisis in macular diseases. *Br J Ophthalmol* 2011;95(3):376–380

27 Akiba J, Kakehashi A, Arzabe CW, Trempe CL. Fellow eyes in idiopathic macular hole cases. *Ophthalmic Surg* 1992;23(9):594–597

28 Chan A, Duker JS, Schuman JS, Fujimoto JG. Stage 0 macular holes: observations by optical coherence tomography. *Ophthalmology* 2004;111(11):2027–2032

29 Spaide RF, Wong D, Fisher Y, Goldbaum M. Correlation of vitreous attachment and foveal deformation in early macular hole states. *Am J Ophthalmol* 2002;133(2):226–229

30 Morgan CM, Schatz H. Involutional macular thinning. A pre–macular hole condition. *Ophthalmology* 1986;93(2):153–161