

How long is the interval of onsets of bilateral retinoblastoma?

Ye Zhang¹, Jian-Min Ma¹, Ning-Li Wang^{1,2}

¹Beijing Tongren Eye Center, Beijing Tongren Hospital, Capital Medical University; Beijing Ophthalmology and Visual Science Key Lab, Beijing 100730, China

²Beijing Institute of Ophthalmology, Beijing 100005, China

Correspondence to: Ning-Li Wang. No.1 Dong Jiao Min Xiang Street, Dongcheng District, Beijing 100730, China. wningli@vip.163.com

Received: 2013-07-05

Accepted: 2013-09-09

DOI:10.3980/j.issn.2222-3959.2013.06.29

Zhang Y, Ma JM, Wang NL. How long is the interval of onsets of bilateral retinoblastoma? *Int J Ophthalmol* 2013;6(6):897-899

Dear Sir,

I am Dr. Ye Zhang, from Beijing Tongren Eye Center, Beijing Tongren Hospital, Beijing, China. I write to present a case report of bilateral retinoblastoma (Rb) with 10-year-interval of onsets.

Rb is the most common malignant intraocular tumor of infancy and childhood, with the majority of cases being diagnosed before 5 years of age. It may involve in unilateral or bilateral eye. Studies showed that the interval of the onsets of bilateral Rb is always within three years. So it is very rare that in this case, the interval of onsets of two eyes is almost ten years.

A 10-year-old boy, who was admitted to the medical ward, complained of painless blurring of vision in the left eye for twenty days.

Nine years ago, when the boy is 3 months old, he was found white reflection in the right pupil while taken a picture by his parents. Diagnosis of Rb was made after examination of the right eye. Enucleation was then performed on his right eye and the pathological diagnosis was Rb postoperatively. One month after the surgery, ophthalmoscopy and computed tomography scan revealed no abnormalities of the left eye, so he was discharged and didn't receive any form of follow-up for nine years. One year ago, the boy presented decreased vision in the left eye with no obvious reasons and was diagnosed to be vitreous hemorrhage. His visual acuity increased back to 1.0 after the treatment of hemostasis drugs.

Twenty days ago, the boy had another episode of blurring vision which was more severe compared to the last time and the same diagnosis was made. However, computed tomography scan showed intraocular calcification in the left eye. After treatment of hemostasis drugs, his visual acuity recovered again. Then he was taken by his father to our hospital for a clear diagnosis. The boy has no history of any other disease. He has a family history that his mother accepted enucleation of the right eye because of Rb, when she was five years old. Physical examination was made on the boy's left eye. Visual acuity: 1.0/Jr1, IOP: 17mmHg, anterior segment examination was normal. Under general anesthesia, the Retcam3 results showed a moderate vitreous hemorrhage and a 2.5PD×3.0PD mass with a mixed 'cottage cheese' appearance in the inferonasal retina, which was 1.5PD away from the optic disc (Figure 1). Color Doppler Imaging demonstrated a 4.1mm×1.9mm×3.8mm intraocular mass and vitreous opacity in the left eye (Figure 2). Computed tomography scan revealed an intraocular calcified spot adhered to the wall of left eyeball (Figure 3). Magnetic resonance imaging (MRI) showed an intraocular mass, with a relatively low-intensity signal on T2-weighted sequences, no obvious extraocular extension (Figure 4). Diagnosis: Rb in the left eye (IRC: D). Treatments included local laser photocoagulation and systemic chemotherapy. After 6 cycles of chemotherapy and 5 times of laser photocoagulation, the tumor decreased and partly calcified (Figure 5).

Rb is the most common malignant intraocular tumor of infancy and childhood, incidence of which is about 1 in 13 500-25 000 live births^[1]. Rb may occur to any age but most of the patients are younger children, especially within two years old^[2]. According to the study of Shields, about 8.5% patients with Rb are older than five years old, and only 0.8% patients with Rb are older than fifteen years old at the first-time diagnosis^[3].

The most frequent clinical manifestations of Rb are leukocoria and strabismus^[4]. Some other signs may be observed, including iris rubeosis, hypopyon, hyphema, buphthalmia, orbital cellulitis, and exophthalmia. Some children with Rb may have no symptoms^[2]. In cases of advanced disease, vomiting and headache may represent




Figure 1 Examination of the left fundus with Retcam 3 revealing a moderate vitreous hemorrhage and a 2.5PD×3.0PD mass with a mixed ‘cottage cheese’ appearance in the inferonasal retina, which is 1.5PD away from the optic disc.

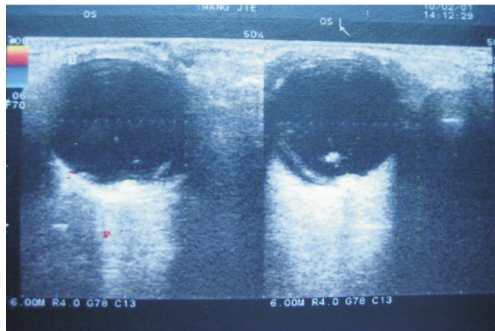


Figure 2 Color Doppler Imaging demonstrating a 4.1mm × 1.9mm×3.8mm intraocular mass in the left eye and vitreous opacity.

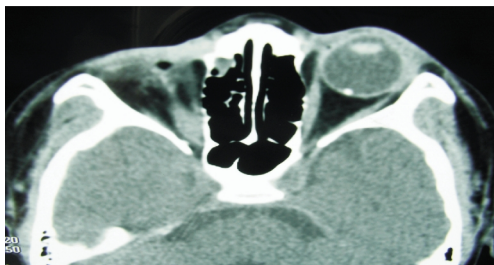


Figure 3 Computed tomography scan showing an intraocular calcified spot adhered to the wall of left eyeball.

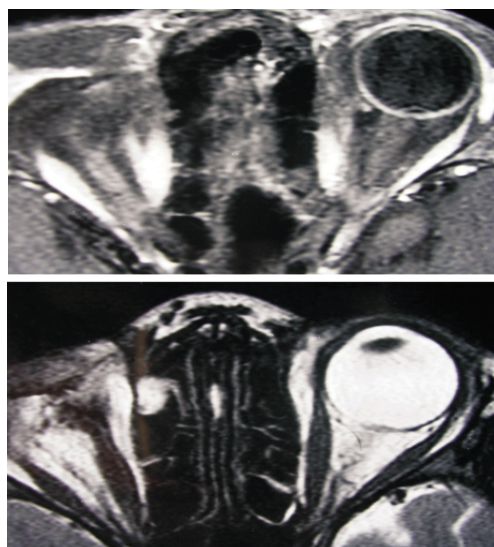


Figure 4 Magnetic resonance imaging showing an intraocular mass, with a relatively low-intensity signal on T2-weighted sequences, no obvious extraocular extension.

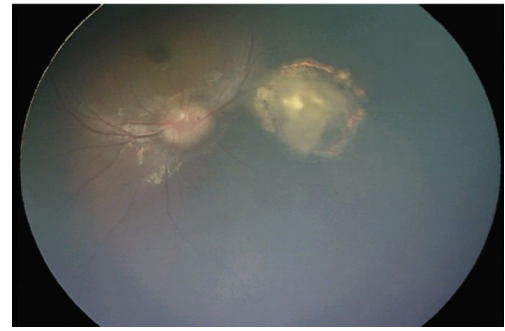


Figure 5 After 6 cycles of chemotherapy and 5 times of laser photocoagulation, the tumor decreased and partly calcified.

central nervous system involvement and bone pain may indicate bone marrow infiltration^[5].

According to studies, in patients older than five years old, besides leukocoria (50%), the most common symptoms, including decreased vision (33%), discomfort of eye (17%) and proptosis (8%), can also be seen. An interesting finding is that in older children, atypical manifestations other than leukocoria are more common than in younger children with Rb, and the results are considered statistically significant ($P=0.057$)^[5]. In older children, visual disorder, uveitis, endophthalmitis and vitreous hemorrhage are common, and those atypical manifestations carry a higher risk of death primarily due to a delay of diagnosis^[3,6]. Maybe the reason is that older children are able to express complaints like pain or decreased vision and so on.

Since leukocoria is not an exclusive symptom or sign of Rb, other diseases such as persistent hyperplastic primary vitreous (PHPV), Coat's disease, retinopathy of prematurity (ROP), should be differentiated by means of funduscopy, ultrasonography, CT and MRI^[7,8].

In this case, the manifestations of this boy were decreased vision and vitreous hemorrhage, and the diagnosis of Rb was made according to his past history, family history, fundus and other imaging results. Studies showed that in patients with bilateral Rb, the interval of the onsets of two eyes is within three years mostly^[9]. So it is very rare that the interval of onsets of two eyes is almost ten years.

Nowadays, there are two theories that have been put forward to explain the late presentation of Rb in older children or adults. One of the suggestions is that the persistence of rare embryonal retinal cells may lead to malignant transformation in later life. Another suggestion is that Rb may arise from previously undiagnosed spontaneously regressed/arrested Rb which has been reactivated^[10]. The pathogenesis of spontaneous regression of Rb has not yet been fully established, but various hypotheses have been suggested to explain its occurrence, such as tumor ischemia, different manifestations of Rb gene, the host's immunological response

and so on ^[11-13]. In this case, since there is no follow-up after the enucleation of the right eye, the entire history of the symptoms and the fundus manifestations of the patient are not available, the mechanisms of the delayed presentation is not clear.

The case of this boy with such a late presentation of bilateral Rb is considered to be rare, so we report this case hoping that it can provide clinically useful information for the future work. Also, this case reminds us that the duration of following up of patients with Rb should be prolonged.

REFERENCES

- 1 Herzog S, Lohmann DR, Buiting K, Schieler A, Horsthemke B, Rehder H, Rieder H. Marked differences in unilateral isolated retinoblastomas from young and older children studied by comparative genomic hybridization. *Hum Genet* 2001;108(2):98-104
- 2 Aerts I, Lumbroso-Le Rouic L, Gauthier-Villars M, Brisse H, Doz F, Desjardins L. Retinoblastoma. *Orphanet J Rare Dis* 2006;1:31
- 3 Shields CL, Shields JA, Shah P. Retinoblastoma in older children. *Ophthalmology* 1991;98(3):395-399
- 4 Chintagumpala M, Chevez-Barrios P, Paysse EA, Plon SE, Hurwitz R. Retinoblastoma: review of current management. *Oncologist* 2007;12(10):1237-1246
- 5 de Aguirre Neto JC, Antoneli CB, Ribeiro KB, Castilho MS, Novaes PE, Chojniak MM, Arias V. Retinoblastoma in children older than 5 years of age. *Pediatr Blood Cancer* 2007;48(3):292-295
- 6 Decaussin M, Boran MD, Salle M, Grange JD, Patricot LM, Thivolet-Bejui F. Cytological aspiration of intraocular retinoblastoma in an 11-year-old boy. *Diagn Cytopathol* 1998;19(3):190-193
- 7 Edward DP, Mafee MF, Garcia-Valenzuela E, Weiss RA. Coats' disease and persistent hyperplastic primary vitreous. Role of MR imaging and CT. *Radiol Clin North Am* 1998;36(6):1119-1131
- 8 Ge J. Ophthalmology. Beijing: People's Medical Publishing House; 2005: 319-322
- 9 Liu N, Liang B, Han P. Value of CT in the diagnosis of retinoblastoma. *Linchuang Fangshe Xue Zazhi* 2005;24(3):218-220
- 10 Park JJ, Gole GA, Finnigan S, Vandeleur K. Late presentation of a unilateral sporadic retinoblastoma in a 16-year-old girl. *Aust N Z J Ophthalmol* 1999;27(5):365-368
- 11 Sanborn GE, Augsburger JJ, Shields JA. Spontaneous regression of bilateral retinoblastoma. *Br J Ophthalmol* 1982;66(11):685-690
- 12 Sang DN, Albert DM. Recent advances in the study of retinoblastoma. In: Peyman GA, Apple DH, Sanders DR, editors. Intraocular tumors. New York: Appleton Century Crofts 1977:285-329
- 13 Yu W, Li B, Ren RJ, Sun XL, Li LQ, Gao F. Clinicopathological analysis of 31 cases of retinoblastoma with spontaneous regression. *Chin J Pract Ophthalmol* 2006;24(1):75-78