

# Fibrin glue–assisted for the treatment of corneal perforations using glycerin–cryopreserved corneal tissue

*Nuo Dong, Cheng Li, Wen-Sheng Chen, Wen-Juan Qin, Yu-Hua Xue, Hu-Ping Wu*

Affiliated Xiamen Eye Center of Xiamen University, 336 Xiahe Road, Xiamen 361001, Fujian Province, China

**Co–first authors:** Nuo Dong and Cheng Li

**Correspondence to:** Hu-ping Wu. Affiliated Xiamen Eye Center of Xiamen University, 336 Xiahe Road, Xiamen 361001, Fujian Province, China. profeye@163.com

Received: 2013-09-01

Accepted: 2013-11-25

**DOI:10.3980/j.issn.2222–3959.2014.01.11**

Dong N, Li C, Chen WS, Qin WJ, Xue YH, Wu HP. Fibrin glue–assisted for the treatment of corneal perforations using glycerin–cryopreserved corneal tissue. *Int J Ophthalmol* 2014;7(1):62–65

## Abstract

• **AIM:** To evaluate the outcomes and safety of lamellar keratoplasty (LK) assisted by fibrin glue in corneal perforations.

• **METHODS:** Six eyes of 6 patients affected by different corneal pathologies (2 posttraumatic corneal scar and 3 bacterial keratitis) underwent LK procedures by using fibrin glue. The mean corneal perforation diameter was  $1.35 \pm 0.64$ mm (range, 0.7–2.5mm), and the greatest diameter of the ulcerative stromal defect was  $2.47 \pm 0.77$ mm in average (range, 1.5–3.5mm). The donor corneal lamella diameters were 0.20–mm larger and thicker than the recipient to restore a physiologic corneal thickness and shape: mean donor diameter was  $8.34 \pm 0.28$ mm (range, 8.2–8.7mm) and mean thickness was  $352 \pm 40.27$ mm (range, 220–400mm). Mean follow–up was  $7.33 \pm 1.97$  months (range, 6–11 months). Postoperatively, the graft status, graft clarity, anterior chamber response, the visual prognosis, intraocular pressures, and postoperative complications were recorded.

• **RESULTS:** All the corneal perforations were successfully healed after the procedure. The best–corrected visual acuity (BCVA) ranged from 20/1 000 to 20/50 in their initial presentation, and from 20/100 to 20/20 in their last visit, showed increase in all the patients. No major complications such as graft dislocation and graft failure were noted. Neovascularization developed in the superficial stroma of donor graft in 1 case. High intraocular pressure developed on day 2 after surgery, while was remained in normal range after application of anti–glaucomatous eyedrops for 1 week in 1 case.

• **CONCLUSION:** Fibrin glue–assisted sutureless LK is valuable for maintaining the ocular integrity in the treatment of corneal perforations.

• **KEYWORDS:** fibrin glue corneal perforation; lamellar keratoplasty

## INTRODUCTION

Corneal perforations are ophthalmic emergencies that may result in anterior synechia of iris, endophthalmitis, macular edema, secondary glaucoma, and atrophied bulbi if it is not managed promptly and appropriately [1]. Emergent treatment on corneal perforation is always mandatory to restore the structural integrity of the cornea as soon as possible.

For corneal perforation, penetrating keratoplasty (PK) is a definitive treatment [2]. Other treatments, *e.g.* cyanoacrylate tissue adhesives, lamellar keratoplasty (LK) with suture, therapeutic bandage contact lenses, transpositional conjunctival flap, fibrin glue (FG) and FG–assisted amniotic membrane transplantation are also helpful in the healing of corneal perforations [3,5–9]. Each of these surgical options has both benefits and disadvantages.

In this study, we report here the effectiveness of FG–assisted LK in restoring anatomic integrity in several corneal perforations by using glycerin–cryopreserved corneal tissue (GCCT). This technique may be preferable for treating eyes with corneal perforations for emergencies in countries in which there is an extreme shortage of donor corneas for transplantation. Here we present our preliminary results.

## SUBJECTS AND METHODS

The Table 1 summarizes demographic data of the six patients [five men, one women; mean age  $\pm$  standard deviation (SD),  $42.17 \pm 15.96$  years] with corneal perforation enrolled in this study. All investigations were conducted in accordance with the tenets of the Declaration of Helsinki, and were approved by the Ethics Committee of Xiamen Eye Center. Institutional Review Board (IRB) approval was obtained. Clinical diagnosis of corneal perforation was based on previously reported criteria [10,11]. All the patients complained of ocular pain, photophobia, tearing and different degrees of visual loss. Corneal scraping for microbial cultures was made before surgery and definite pathogens were identified in all patients.

**Table 1 Demographic data and clinical outcomes for six consecutive patients with corneal perforations**

Case	Sex/Age	Underlying etiology	Size of perforation (mm)	Size of ulceration (mm)	Site of perforation	Preop. BCVA	Postop. BCVA	Follow-up time (month)
1	M/31	Bacterial keratitis	1.5×1.8	2.3×2.8	central	20/1000	20/100	6
2	M/39	Traumatic perforation	0.8×0.8	3.2×3.2	paracentral	20/600	20/30	7
3	F/45	Noninfectious	1.8×2.3	2.0×2.8	paracentral	20/400	20/100	6
4	M/72	Bacterial keratitis	0.9×0.9	1.7×1.7	peripheral	20/200	20/50	8
5	M/27	Penetrating injury	0.7×0.7	1.5×1.5	peripheral	20/50	20/25	11
6	M/39	Bacterial keratitis	2.5×1.5	3.4×3.5	peripheral	20/1000	20/20	6

BCVA: Best-corrected visual acuity.

All FG-Assisted LK surgeries were performed under peribulbar anesthesia by a single surgeon (Hu-Ping Wu) between July 2010 and July 2012 at the Cornea and Ocular Surface Clinic, Affiliated Xiamen Eye Center of Xiamen University. Informed consent was obtained from each patient prior to inclusion in the study. Clinic information including graft clarity, corneal neovascularization, visual prognosis, and postoperative complications were recorded after surgery.

**Donor Corneal Preparation** Donor corneas were provided by the Eye Bank of Xiamen Eye Center in accordance with the medical standard for the tissue bank. The preserved donor corneas were stored at -78°C in pure sterile glycerin. The average duration of cryopreservation before surgery use was 7.5±2.3 months.

**Surgical Procedure** Under the operating microscope, the necrotic tissue was removed by forceps and scissors and sent for cultures, and the irregular margin of recipient bed was trimmed by scissors. Based on the different sizes and shapes of recipient bed, trimmed donor cornea was performed to fit the bed on each involved eye.

The fibrin glue (RAAS Blood Products Company, Shanghai, China) was reconstituted according to the manufacturer's instructions. This glue has 2 components: sealant protein and sealant setting. A double-barrelled syringe was used to mix the 2 components without dilution. By this method, 2 components were delivered with equal volume. One drop of the fibrin glue was placed undisturbed on the donor-recipient junction for about 30s. At the end, a Seidel test was performed to check for any leakage and then bandage contact lens (0 diopters, 14.2mm CIBA Vision: Novartis, Duluth, GA, USA) was applied

**Medications and Follow-up** All 6 patients were given antibiotics before the surgery. Appropriate antibiotic agents were alternatively administered twice every hour for bacterial keratitis. And 0.3% Ofloxacin eyedrops (Santen Pharmaceutical Co, Osaka, Japan) were added 4 times every hour for the other patients.

Postoperatively, all patients were given intravenous hydrocortisone of 2mg/kg daily for 3d. Meanwhile, Tobradex eyedrops (Alcon, Fort Worth, TX, USA) were used 4 times daily and tapered when the conjunctival hyperemia disappeared.

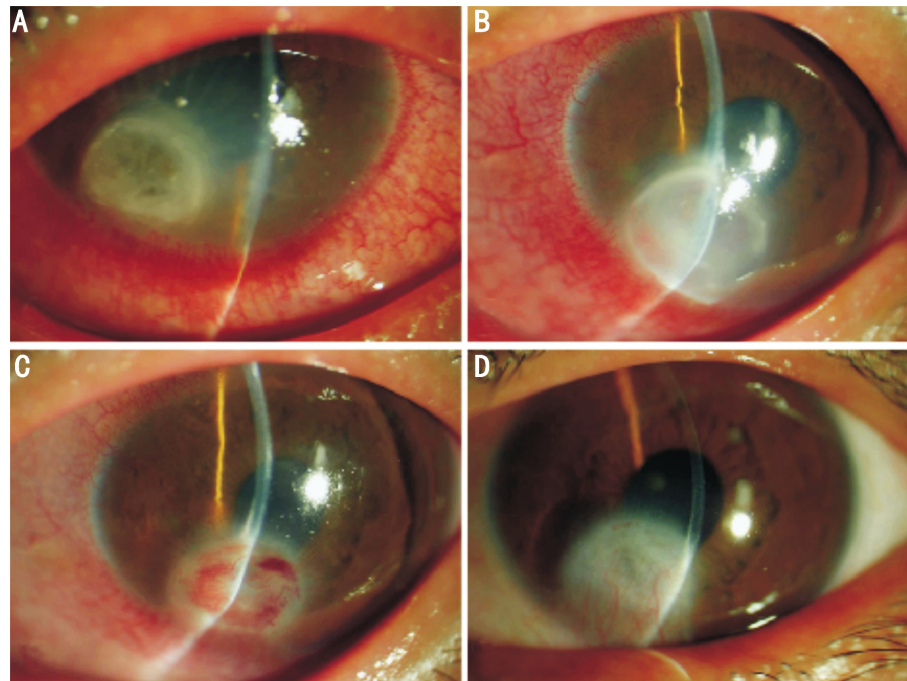
All patients were hospitalized for the first 7-10d after operation, and were followed up weekly for the first month, every 2 weeks for 2 months, monthly for a minimum of 6 months, and at different intervals thereafter.

Patients were followed up for a minimum of 3 months after surgery. At each follow-up, the anterior chamber depth, inflammatory reaction, and graft adherence were recorded. Seidel test was performed to detect leakage. Summary data were reported as means±SD.

## RESULTS

The study subjects were five men and one woman, with a mean (±SD) age of 42.17±15.96 years (range 27-72 years). Corneal perforation happened unilaterally on them (2 right eyes, 4 left eyes). The mean corneal perforation diameter was 1.35±0.64mm (range, 0.7-2.5mm), and the greatest diameter of the ulcerative stromal defect was 2.47±0.77mm in average (range, 1.5-3.5mm). The causes of corneal perforation were categorized as infectious keratopathy (patient 1, 4 and 6 with staphylococcus epidermidis), Rheumatoid arthritis-associated noninfectious corneal perforation (patient 3), and trauma (patient 2 with corneal leukoma, patient 5 with iron bar injury) (Table 1).

Flat anterior chamber without anterior synechia of iris was observed in all cases at the initial presentation to our clinic. Patient 2 had been underwent amniotic membrane transplantation (AMT), while other patients had no surgery. All patients achieved deep anterior chamber with complete donor-host apposition immediately after operation, no aqueous leakage was detected by Seidel's test and the anterior chamber depth was maintained normal during the follow-up period of 3 to 6 months. None of the patients had persistent interface fluid collections postoperatively. Reepithelization achieved within 2 weeks in all the donor grafts, and there was no epithelial defect during the follow-up period, however, none of the grafts were clear at the final follow-up. The best-corrected visual acuity (BCVA) ranged from 20/1 000 to 20/50 in their initial presentation, and from 20/100 to 20/20 in their last visit, showed increase in all the patients. No major complications such as graft dislocation and graft failure were noted. Neovascularization developed in the superficial stroma of donor graft in patient 6 on the day 4 (Figure 1). In patient 5, high intraocular



**Figure 1 Case 6** A: Corneal perforation with deep stromal ulceration was evident with a flat anterior chamber; B: Day 4 post surgery, corneal neovascularization began to grow from the limbus with and no sign of aqueous leakage; C: By the fourth postoperative week, the graft edema had completely resolved and peripheral neovascularization was especially prominent in the centre area of the graft; D: A stable corneal scar and peripheral corneal new blood vessels were observed 6 months postoperatively.

pressure developed on day 2 after surgery, while was remained in normal range after application of anti-glaucomatous eyedrops for 1 week.

## DISCUSSION

Corneal perforation constitutes an emergent situation that requires prompt and proper management of the primary diseases. Although therapeutic penetrating keratoplasty (PK) is the most definitive treatment in such cases, PK being an intraocular procedure is certainly associated with more postoperative problems, such as the high risk of complicating synechiae, glaucoma, uveitis, and eventual graft failure<sup>[12-14]</sup>. In order to avoid these complications and achieve a reasonable rate of graft clarity, Nobe *et al*<sup>[2]</sup> suggested that penetrating keratoplasty (PK) should be delayed. Presently available alternatives to acute PK include lamellar keratoplasty.

Anshu *et al*<sup>[15]</sup> performed therapeutic deep anterior lamellar keratectomy (DALK) for infections confined to the corneal stroma compared with therapeutic PK, and found that LK may be considered instead of PK yielding similar graft survival without an increased risk of disease recurrence for medically unresponsive infectious keratitis. Therefore, we believe that LK is a substitutive effective treatment in such cases to reduce the risk of graft rejection, endophthalmitis, and secondary glaucoma compared with PK<sup>[13,16]</sup>. In China, fresh corneal grafts are expensive and not always available for PK. GCCT can be conducted for a long time, and it provides greater availability of tissue for LK. In this study, GCCT has been used successfully to restore anatomic

integrity in corneal perforations, and only 1 out of 6 case developed high intraocular pressure. Without replacing the endothelial cell layer, LK may be a better option to regain functional vision in eyes with peripheral corneal perforation<sup>[17]</sup>. In this study, all cases had improved vision by 2 or more snellen lines, and 3 (50%) cases achieved BCVA between 20/40 and 20/20. Cheng *et al*<sup>[18]</sup> suggested that opacification of the stromal interface of LK can cause a reduction in visual acuity. In our study, although all the cases responded well to LK without major complications, it should be mentioned that opacification of the graft stroma was noted in all the cases at the end of the follow-up. This may be attributable to inflammation, significant injury of the corneal stroma, endothelial cell loss, and long term storage of donor tissue. In this study, we also found that the grafts did not achieve transparency which could be a problem for vision if the lesion is centrally placed near the visual axis in case 1. Further treatment by PK using fresh graft may be needed for favorable visual rehabilitation in such cases.

The 10-0 nylon suture is commonly used to fix the graft in LK. Although suture may help stabilization of the graft, it also inflicts trauma to the cornea and may increase the risk of postoperative astigmatism, epithelial in growth beneath grafts and suture infection<sup>[19]</sup>. Moreover, a prolonged operative time and technical skill are needed for effective suture placement in suturing small corneal graft. Whereas, FG showed great advantage in LK for corneal perforation, FG can hold the lamellar cap in place until the epithelium resurfaces the cornea and develop new tight junctions<sup>[19]</sup>. In

this study, we successfully performed the sutureless LK in all the cases, and slit lamp examination showed that the donor graft was firmly attached to the perforation site without loss or dislocation for at least 3 months. With the bandage contact lens on top, the graft is protected from eyelid blinking thus promotes re-epithelialization of the graft. The sufficient thickness of FG-assisted LK complex allowed complete seal of the perforated wound and prevented any leakage or outward bulging of the cornea after surgery, and we also successfully treated the patients with perforations 2mm or larger in diameter in case 6. In addition, the transplanted complex provides tissue support and facilitates ocular surface reconstruction and tissue remodeling. Since Chen *et al*<sup>[20]</sup> reported that FG has little effect against either Gram-positive or -negative bacteria *in vitro* Although in this study, none of the patients suffered with infectious keratopathy recurrence, this could be a problem given that some of the donor material was stored wet for 14d and some of the injuries were infective.

In summary, our new surgical strategy provides a promising outcome with relatively simple technique and less postoperative pain and discomfort. We introduce this new technique and highly recommend it as an alternative therapy in the management of corneal perforations not larger than 2.5mm. A limitation of this study is its small sample size and retrospective nature. Nevertheless, as a new surgery applied on corneal perforations, further study should be done to investigate other indications of this strategy, and to evaluate wound healing process during FG application, so as to validate the efficacy of this new treatment.

#### ACKNOWLEDGEMENTS

**Foundation:** Supported by National Natural Science Foundation of China (No.81100639; No.81000367); Natural Science Foundation of Fujian Province, China (No. 2012-CXB-30; No.2013-2-112); Xiamen Science and Technology Plan Projects (No.3502Z20124037; No. 2011S0589; No.3502Z20131017)

**Conflicts of Interests:** Dong N, None; Li C, None; Chen WS, None; Qin WJ, None; Xue YH, None; Wu HP, None.

#### REFERENCES

1 Xie L, Zhai H, Dong X, Shi W. Primary diseases of corneal perforation in Shandong Province, China: a 10-year retrospective study. *Am J Ophthalmol* 2008;145(4):662-666  
2 Nobe JR, Moura BT, Robin JB, Smith RE. Results of penetrating keratoplasty for the treatment of corneal perforations. *Arch Ophthalmol* 1990;108(7):939-941

3 Hirst LW, Stark WJ, Jensen AD. Tissue adhesives: new perspectives in corneal perforations. *Ophthalmic Surg* 1979;10(3):58-64  
4 Portnoy SL, Insler MS, Kaufman HE. Surgical management of corneal ulceration and perforation. *Surv Ophthalmol* 1989;34(1):47-58  
5 Leibowitz HM. Hydrophilic contact lenses in corneal disease. IV. Penetrating corneal wounds. *Arch Ophthalmol* 1972;88(6):602-606  
6 Gundersen T. Conjunctival flaps in the treatment of corneal disease with reference to a new technique of application. *AMA Arch Ophthalmol* 1958; 60(5):880-888  
7 Jhanji V, Young AL, Mehta JS, Sharma N, Agarwal T, Vajpayee RB. Management of Corneal Perforation. *Surv Ophthalmol* 2011;56(6):522-538  
8 Por YM, Tan YL, Mehta JS, Tan DT. Intracameral fibrin tissue sealant as an adjunct in tectonic lamellar keratoplasty for large corneal perforations. *Cornea* 2009;28(4):451-455  
9 Kim HK, Park HS. Fibrin glue-assisted augmented amniotic membrane transplantation for the treatment of large noninfectious corneal perforations. *Cornea* 2009;28(2):170-176  
10 Duarte MC, Kim T. Sutureless lamellar keratoplasty: a modified approach for fibrin glue application. *Cornea* 2007;26(9):1127-1128  
11 Siatiri H, Moghimi S, Malihi M, Khodabande A. Use of sealant (HFG) in corneal perforations. *Cornea* 2008;27(9):988-991  
12 Panda A, Agarwal A, Kumar S. Therapeutic keratoplasty for corneal perforation. *Cornea* 2008;27(10):1218-1219  
13 Kawashima M, Kawakita T, Den S, Tomita M, Shimazaki J. Surgical management of corneal perforation secondary to gonococcal keratoconjunctivitis. *Eye (Lond)* 2009;23(2):339-344  
14 Shi W, Liu M, Gao H, Li S, Wang T, Xie L. Penetrating keratoplasty with small-diameter and glycerin-cryopreserved grafts for eccentric corneal perforations. *Cornea* 2009;28(6):631-7.  
15 Anshu A, Parthasarathy A, Mehta JS, Htoon HM, Tan DT. Outcomes of therapeutic deep lamellar keratoplasty and penetrating keratoplasty for advanced infectious keratitis: a comparative study. *Ophthalmology* 2009; 116(4):615-623  
16 Shimmura S, Shimazaki J, Tsubota K. Therapeutic deep lamellar keratoplasty for cornea perforation. *Am J Ophthalmol* 2003;135 (6): 896-897  
17 Huang T, Wang Y, Ji J, Gao N, Chen J. Evaluation of different types of lamellar keratoplasty for treatment of peripheral corneal perforation. *Graefes Arch Clin Exp Ophthalmol* 2008;246(8):1123-1131  
18 Cheng J, Qi X, Zhao J, Zhai H, Xie L. Comparison of penetrating keratoplasty and deep lamellar keratoplasty for macular corneal dystrophy and risk factors of recurrence. *Ophthalmology* 2013;120(1):34-9  
19 Kaufman HE, Insler MS, Ibrahim-Elzembely HA, Kaufman SC. Human fibrin tissue adhesive for sutureless lamellar keratoplasty and scleral patch adhesion: a pilot study. *Ophthalmology* 2003;110(11):2168-2172  
20 Chen WL, Lin CT, Hsieh CY, Tu IH, Chen WY, Hu FR. Comparison of the bacteriostatic effects, corneal cytotoxicity, and the ability to seal corneal incisions among three different tissue adhesives. *Cornea* 2007;26 (10): 1228-1234