

Measurement of retinal thickness in macular region of high myopic eyes using spectral domain OCT

Ai-Ping Song^{1,2}, Xin-Yi Wu¹, Jian-Rong Wang², Wei Liu², Yan Sun², Tao Yu²

¹Department of Ophthalmology, Qilu Hospital Affiliated Shandong University, Jinan 250012, Shandong Province, China

²Department of Ophthalmology, Second People's Hospital, Jinan 250001, Shandong Province, China

Correspondence to: Xin-Yi Wu. Department of Ophthalmology, Qilu Hospital, Shandong University, No.107 Wenhua Xi Road, Jinan 250012, Shandong Province, China. sapwl@hotmail.com

Received: 2013-06-29

Accepted: 2013-10-16

Abstract

• **AIM:** To investigate the changes of retinal thickness in macula of high myopic eyes using spectral domain optical coherence tomography (OCT).

• **METHODS:** Middle-aged and young myopic patients were divided into three groups according to their refractive error/axial length: low and medium myopia group (LMMG), high myopia group (HMG) and super high myopia group (SHMG). Cirrus HD-OCT was used to evaluate total average macular thickness, central subfield thickness, inner/outer macular thickness and macular volume. The differences among experimental groups were analyzed by one-factor analysis of variance. Associations between macular thickness and refractive error/axial length were analyzed by Pearson correlation analysis.

• **RESULTS:** There was no significant difference in age among the three groups ($P=0.2789$). The mean refraction error in the LMMG, HMG, and SHMG groups was $-2.49 \pm 1.38D$, $-8.53 \pm 1.95D$ and $-13.88 \pm 1.76D$, respectively ($P < 0.001$). The central subfield thickness of three groups was $244.56 \pm 12.19\mu m$, $254.33 \pm 11.61\mu m$ and $261.75 \pm 11.83\mu m$, respectively, and there were statistically significance between random two groups. The total average macular thickness, inner/outer macular thickness, and macular volume decreased with increased myopia/axial length. Average foveal thickness had negative correlations with refractive error ($P < 0.001$), and positive correlations with axial length. The inferior and temporal inner macular thickness, all the quadrants of outer ring, total average macular thickness and macular volume featured positive correlations with refractive error, and negative correlations with axial length. Average foveal thickness, superior and temporal inner

macular thicknesses, and temporal outer macular thickness was lower in females compared to males.

• **CONCLUSION:** With an increase in myopia degree/axial length, the average foveal thickness increased and the inner/outer macular thickness decreased. Females featured thicker average foveal thickness, and thinner macular thickness compared to males.

• **KEYWORDS:** optical coherence tomography; retinal thickness; high myopic eyes

DOI:10.3980/j.issn.2222-3959.2014.01.23

Song AP, Wu XY, Wang JR, Liu W, Sun Y, Yu T. Measurement of retinal thickness in macular region of high myopic eyes using spectral domain OCT. *Int J Ophthalmol* 2014;7(1):122-127

INTRODUCTION

Myopia is the most common eye disorder and the complications of high myopia are contributing factors to blindness^[1,2]. The incidence of myopia has increased yearly in East Asia^[3,4]. It has been reported that the incidence of myopia in young people (15-25 years old) living in Singapore has reached up to 30% to 65%^[5]. Also Chinese adults had higher prevalence of myopia, high myopia as well as the longer axial length (AL) when compared with non-Chinese adults^[6].

Although myopia can be easily managed with an appropriate optical correction, it is a risk factor for a number of retinal pathologies and one of the major causes of visual dysfunction, especially in patients with high myopia. Previous histopathologic studies have revealed that increased sclera and retinal thinning are associated with myopia, which may be caused by increased axial length and relative enlargement of globe beyond normal dimensions. With the development of modern imaging technologies, *in vivo* measurements of retinal thickness have been made possible. Lim and colleagues^[7] reported that the average macular thickness does not change with the change of myopia degree using the first generation of optical coherence tomography (OCT1 Carl Zeiss Meditec, Dublin, CA, USA). Using the same experimental design, Wakitani and colleagues^[8] obtained the same conclusion by the second generation of optical coherence tomography (Humphrey 2000 OCT system; Carl Zeiss Meditec, Inc.). Zou and colleagues^[9] had not found the differences in retinal thickness between

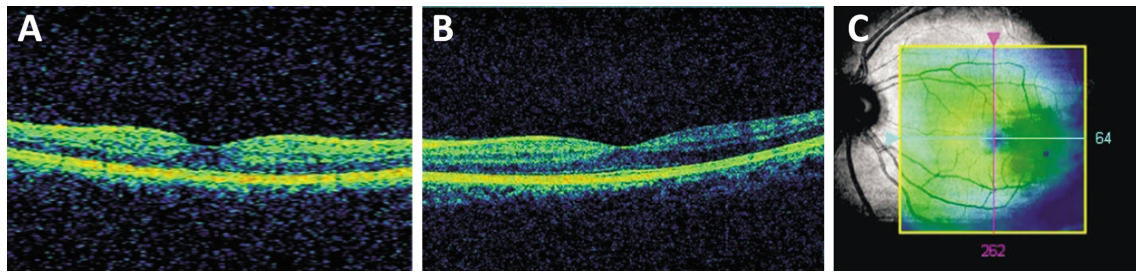


Figure 1 Cirrus HD-OCT detection ideograph A: scanning slice figures through anterior of cube. B: scanning slice figures through lateral of cube. C: scanning cube overlay figures of eyeground.

emmetropia and myopia by using a retinal thickness analyzer (RTA) (Talia Technology Ltd, Neve-Lian, Israel). The disparity may stem from the relatively low scanning resolution and small sampling density of the measuring devices used in the earlier studies. The newest group spectral domain optical coherence tomography (Cirrus HD-OCT, Carl Zeiss Meditec, Inc) can perform 27 000 scans per second, and the axial resolution is $5\mu\text{m}$. Spectral domain OCT can provide more accurate scanning, and much higher repeatability and make the detection of subtle changes in the retina of patients with myopia earlier^[10,11].

The possible retinal structural changes in individuals with high myopia without evidence of clinically overt retinal disease are known little. In the present study, we measured the retinal thickness in the macular region of myopic patients using spectral domain OCT under free living conditions, and analyzed differences among different diopter degrees and influences coming from axial length, refractive error and gender. The purpose of this study was to provide basis for defining the clinical features of high myopia and to find reliable following-up methods for high myopia.

SUBJECTS AND METHODS

Subjects Eighty-two Chinese patients who met the inclusion criteria were examined during the period from June 2012 to December 2012 in the Department of Ophthalmology, Qilu Hospital (Shandong University, Shandong, China). All subjects completed a full ophthalmic examination, including best corrected vision acuity (BCVA), refraction, intraocular pressure (IOP) measured by Goldmann applanation tonometry, gonioscope examination, visual field and dilated fundus examinations. Subjects without other eye disorders except for refraction errors and BCVA above 20/25 were included in the study. Subjects were divided into three groups according to their refractive error/ axial length: low and medium myopia group [LMMG, spherical equivalent (SE) between -0.5 and -6.0D and axial length 24-26mm, $n=26$], high myopia group (HMG, SE between -6.0 and -10.0D and axial length 26-28mm, $n=34$) and super high myopia group (SHMG, SE $\geq -10.0\text{D}$ and axial length $\geq 28\text{mm}$, $n=22$).

Subjects with clinical evidence of concurrent diseases other than refractive error, such as glaucoma, media opacity, uveitis, retinal diseases or histories of intraocular surgery,

refractive surgery, neurologic diseases, and diabetes were excluded. Subjects who met the inclusion criteria with both eyes had one eye randomly selected for OCT. This study was conducted in accordance with the ethical standards stated in the Declaration of Helsinki and approved by the Ethics Committee of Qilu Hospital, Shandong University, with informed consent obtained from all patients.

Methods

Optical coherence tomography OCT was performed with the Cirrus HD-OCT system (Carl Zeiss Meditec, Inc, Cirrus HD-OCT4000, Soft version 6.0) and macular cube 512 \times 218 protocol. This scan protocol generates a cube of data through a 6mm square grid by acquiring a series of 128 horizontal scan lines comprising 512 A-scans (Figure 1). This is defined as scans with a signal strength >6 that exhibits correct delineation of the retina layers as detected automatically by the intrinsic software segmentation algorithm and are without image artifacts caused by eye movement and papillary shadowing. All data were performed by the same operator under the same condition.

The map is composed of nine sectorial thickness measurements in three concentric circles with diameters of 1, 3 and 6mm. The area bounded by the outer (6mm) and middle (3mm) circles forms the outer ring (OR) while the area bounded by the middle (3mm) and inner circles (1mm) forms the inner ring (IR). Each ring is divided into superior, nasal, inferior and temporal quadrants. CST stands for central subfield thickness, SIM, IIM, NIM, TIM stand for superior of inner ring, inferior of inner ring, nasal of inner ring, and temporal of inner ring, respectively. SOM, IOM, NOM, TOM stand for superior of outer ring, inferior of outer ring, nasal of outer ring, and temporal of outer ring, respectively (Figure 2). Total macular thickness and macular volume over the 6mm diameter circle centered at the true fovea location were also obtained from the computational software output.

We applied light interference biomeasurement equipment (IOL Master, Carl Zeiss Meditec) to perform the AL measurement. The patients stared at an inner fixation of the instrument, and we measured AL 3 times and obtained the mean value.

Table 1 Baseline data of three diagnostic groups (mean±standard error)

	Group 1	Group 2	Group 3	P
Sample numbers	26	34	22	
Spherical equivalent diapter (D)	-2.49±1.38 (-4.80 to -0.75)	-8.53±1.95 (-6.00 to -9.75)	-13.88±1.76 (-10.75 to -17.75)	¹ <0.001
Axial length (mm)	24.39±0.75 (22.72 to 25.26)	26.73±0.97 (26.45 to 27.34)	29.98±1.08 (28.2 to 31.2)	² <0.001
Gender (M/F)	16/10	18/16	9/13	² 0.36
Ages (a)	26.62±5.38	24.33±5.70	25.82±5.68	0.2789
Intraocular pressure (mmHg)	13.5±2.2	14.1±2.5	14.0±2.2	0.5928

¹One-factor analysis of variance; ²Chi-square test.

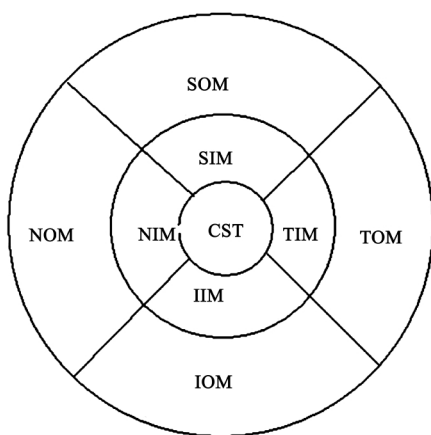


Figure 2 Topographical map of macular thickness. The diameter of three rings were respectively 1, 3 and 6mm. CST stands for central subfield thickness, SIM, IIM, NIM, TIM stand for superior of inner ring, inferior of inner ring, nasal of inner ring, and temporal of inner ring, respectively. SOM, IOM, NOM, TOM stand for superior of outer ring, inferior of outer ring, nasal of outer ring, and temporal of outer ring, respectively.

Statistical Analysis Statistical analyses were performed (SPSS version 11.5) and differences in macular measurements among the three diagnostic groups were evaluated by one-factor analysis of variance (ANOVA) followed by post-hoc test (SNK test). Association between macular measurement and refractive error and axial length were examined by linear regression analysis and expressed as the Pearson correlation coefficient. Gender differences in macular measurements were evaluated by *t*-test. A *P* value less than 0.05 was considered to be a statistically significant difference.

RESULTS

A total of 82 eyes of 82 subjects (43 males and 39 females) were enrolled. Thirteen patients were excluded because the OCT detection signal intensity was < 6. The average age of the LMMG, HMG and SHMG was 26.62±5.38, 24.33±5.70 and 25.82±5.68 old years, respectively. The spherical equivalent were from -0.75D to -17.75D (mean±standard error=-5.16±5.34) and the AL were from 22.72mm to 31.50mm (mean ± standard error=25.81 ±2.31). High correlation was found

between AL and spherical equivalent. No significant difference was found in gender distribution among the groups (*P*=0.36) (Table 1).

Total and regional macular thickness measurements in each group are summarized in Table 2. When macular thickness measurements in the LMMG group were compared with those in the HMG group, a significant decrease was observed in the IIM, TIM and all regions of outer ring. But the CST was significantly higher in the HMG group than that in the LMMG group (*P*<0.01). When macular thickness measurements in the LMMG group were compared with those in the SHMG group, significant decreases were observed in the IIM, TIM and all regions of outer ring. But the CST was significantly higher in the HMG group than that in the LMMG group (*P*<0.01). When macular thickness measurements in the HMG group were compared with those in the SHMG group, significant decreases were observed in all regions of outer ring. But the CST was significantly higher in the SHMG group compared to the HMG group (*P*<0.05).

The relationships between macular thickness measurements and refractive error and AL were analyzed by using linear regression and expressed as the Pearson correlation coefficient (Table 3) The correlation analysis indicated that there was a negative relationship between the CSF thickness and refractive error (*P*<0.001), but a positive relationship with AL. There was a positive correlation between average thickness of IR, IIM and TIM and refractive error, but a negative correlation with AL. The thickness of every quadrant of OR, average thickness of OR, average macular thickness and macular volume had a positive correlation with refractive error and negative correlation with AL.

Table 4 presents the macular measurements stratified by gender. The CST, SIM, TIM, average thickness of IR and TOM were significantly lower in females than in males.

DISCUSSION

OCT makes it possible to accurately measure retinal thickness. OCT uses laser lower coherence interference measurement and can measure tissues and distances with the resolution of ≤10µm. Currently, OCT is the best method for the measurement of retina thickness and retina nerve fiber

Table 2 Macular measurements (µm) in three diagnostic groups

	Group 1 (n=26)	Group 2 (n=34)	Group 3 (n=22)	² P	Q1	Q2	Q3
CST (µm)	244.56±12.19 (224-267)	254.33±11.61 (235-263)	261.75±11.83 (247-277)	<0.001	4.47 ^b	7.07 ^b	3.25 ^a
SIM (µm)	319.43±16.32 (284-350)	314.41±16.14 (287-345)	314.16±16.08 (287-340)	0.4148	1.68	1.59	0.07
IIM (µm)	315.56±15.84 (285-342)	308.37±12.24 (283-337)	301.25±12.09 (285-328)	0.0019	2.90 ^a	5.19 ^b	2.73
NIM (µm)	321.81±13.56 (300-349)	317.87±11.07 (300-340)	312.58±16.4 (300-336)	0.0662	1.59	3.35	2.03
TIM (µm)	308.93±14.65 (282-340)	299.62±10.29 (281-328)	296.91±11.49 (282-313)	0.0018	4.16 ^b	4.83 ^b	1.15
Average thickness of inner ring (µm)	321.83±10.98 (305.25-345.25)	315.35±9.85 (295-313.75)	313.98±11.45 (301.5-315)	0.0229	3.03 ^a	3.59 ^a	0.66
SOM (µm)	283.68±13.26 (265-321)	271.54±8.11 (260-287)	258.00±9.1 (243-279)	<0.001	5.94 ^b	11.3 ^b	6.3 ^b
IOM (µm)	272.15±11.64 (254-299)	255.91±8.61 (241-269)	240.66±7.78 (231-257)	<0.001	6.61 ^b	11.2 ^b	5.6 ^b
NOM (µm)	306.75±11.29 (289-335)	295.37±6.49 (283-312)	285.25±7.94 (281-299)	<0.001	5.51 ^b	8.81 ^b	4.48 ^b
TOM (µm)	264.75±13.41 (242-302)	252.66±9.66 (239-276)	241.33±12.57 (220-263)	<0.001	5.58 ^b	9.73 ^b	4.98 ^b
Average thickness of outer ring (µm)	281.13±10.92 (266.75-314.25)	269.75±11.8 (261.75-274.75)	245.25±11.77 (232-254)	<0.001	5.36 ^b	15.2 ^b	10.99 ^b
Total macular thickness (µm)	280.71±12.41 (269-288)	265.33±11.87 (257-274)	260.74±10.11 (250.33-267.25)	<0.001	7.19 ^b	8.39 ^b	2.04
Macular volume (mm ³)	10.01±0.6	9.56±0.4	9.51±0.56	<0.001	4.75 ^b	4.84 ^b	0.60

¹The data were mean±standard error (range); ²One-factor analysis of variance followed by post-hoc test(SNK test); Q1, Q values between low, medium myopia group and pure high myopia group; Q2, Q values between low, medium myopia group and pure super high myopia group; Q3, Q values between pure high myopia group and pure super high myopia group; ^aP<0.05; ^bP<0.01.

Table 3 Correlations between macular measurements and refractive errors and axial length

	Refractive errors		Axial length	
	r	P	r	P
CST (µm)	-0.318	<0.001	0.391	<0.001
SIM (µm)	0.118	0.165	-0.046	0.604
NIM (µm)	0.034	0.713	-0.038	0.64
IIM (µm)	0.151	0.044	-0.154	0.04
TIM (µm)	0.177	0.018	-0.151	0.044
Average thickness of inner ring (µm)	0.183	0.03	-0.172	0.02
SOM (µm)	0.403	<0.001	-0.381	<0.001
NOM (µm)	0.245	0.003	-0.272	<0.001
IOM (µm)	0.475	<0.001	-0.497	<0.001
TOM (µm)	0.546	<0.001	-0.541	<0.001
Average thickness of outer ring (µm)	0.483	<0.001	-0.483	<0.001
Total macular thickness (µm)	0.316	<0.001	-0.151	0.044
Macular volume (mm ³)	0.211	0.004	-0.208	0.006

Table 4 Gender differences in macular thickness measurement

	¹ M	¹ F	^a P
Cases	43	39	
Ages (a)	25.01±5.73	27.13±5.69	0.5180
Diopter (D)	-5.46±4.38	-4.85±4.96	0.556
Axial length(mm)	25.56±1.73	26.03±2.01	0.258
CST(µm)	258.87±13.08	246.78±14.05	0.0001
SIM(µm)	321.37±15.15	313.76±14.21	0.0218
NIM(µm)	322.18±16.43	315.73±17.2	0.0865
IIM(µm)	312.73±11.37	308.15±10.89	0.0681
TIM(µm)	305.86±16.15	298.14±15.65	0.0314
Average thickness of inner ring(µm)	317.33±16.33	308.10±17.12	0.0145
SOM(µm)	274.12±16.16	275.31±14.52	0.7277
NOM(µm)	293.12±16.13	292.38±14.34	0.8275
IOM(µm)	268.13±14.97	263.05±15.59	0.1363
TOM(µm)	262.3±16.31	255.1±14.59	0.039
Average thickness of outer ring(µm)	273.86±13.12	270.92±14.91	0.3451
Total macular thickness(µm)	274.16±13.17	273.92±14.59	0.9378
Macular volume(mm ³)	9.82±0.58	9.63±0.62	0.1556

¹The data were mean±standard error; ^at-test in independent sample.

thickness in different diopter and AL [8]. Spectral domain OCT features more rapid scanning speeds and higher scanning resolution. Compared with time domain OCT, the advantages of spectral domain OCT are mainly its super high image resolution and rapid time of image scan. Spectral domain OCT can be applied to detect all retinal diseases, and

follow up disease progression.

It has reported that the CST in normal eyes was (197.1 ± 16.4µm) as measured by a Stratus OCT [12]. Our results indicated that the CST in LMMP group, as measured by Cirrus HD-OCT, was 50µm thicker than that of Stratus OCT. The disparity comes from the different definitions of

retinal boundary. Cirrus HD-OCT measured retinal thickness as the distance between inner limiting membrane and the inner surface of retinal pigment epithelium (RPE), while the Stratus OCT measured retinal thickness as the distance between inner limiting membrane and exterior and interior segment of photoreceptor [11,13]. The thickness between the exterior and interior segments of the photoreceptor and RPE layer is 54 μm , as measured by SD-OCT [13]. Therefore there was a 50 to 60 μm difference of the mean macular thickness existed in Stratus OCT and Cirrus HD-OCT [14,15]. From the aspect of anatomy features of image, the RPE layer is much more steady than exterior and interior segments, so the results measured by Cirrus HD-OCT is more accurate and it is easier to detect small pathological changes in macular area. Grover *et al* [16] reported that the CST in 50 normal eyes was 270.2 μm when determined by a different type of spectral domain OCT instrument (Spectralis; Heidelberg Engineering, Dossenheim Germany). Although the Cirrus and Spectralis are both spectral domain OCT, the Cirrus OCT measures retinal thickness up to the outer band of the RPE, while the Spectralis OCT includes the Bruch's membrane, which likely accounts for the additional increased 20 μm .

There is still controversy regarding regional changes in macular thickness in high myopia eyes. Lam *et al* [17] investigated the relationship between myopia and macular thickness using Stratus OCT and found that no significant difference existed in the inner ring macular thickness among the groups (high myopia, low to moderate myopia and nonmyopic eyes). In contrast, Wu *et al* [18] reported that the mean retinal thickness measured by third-generation OCT in the inner and outer macular area of the high myopia group was significantly less than that in the non-myopia group. In the present study, we applied Cirrus HD-OCT to measure the retinal thickness of the macular area in myopia patients. The results indicated that with the increase of myopia and AL, the retina becomes thinner in high myopia patients. The thinner areas mainly included IIM, TIM and every quadrant of the outer ring. When the thickness of the retina decreased with increased AL, the CST increased. Possible mechanism may include the unhealthy fovea central's fixation in high myopia patients and the elongation of the photoreceptor cell outer segment [7,19]. The findings of the present study provide information to clinicians regarding the pattern of regional variations in macular thickness in patients affected by myopia.

We found that the thickness of CST, SIM, IIM, average inner macular thickness and TOM were significantly greater in the men than in the women. Previous studies regarding differences in retinal macular thickness between genders have reported inconsistent results. Studies in which the Stratus OCT instrument was used reported no significant intersex differences [20,21]. The intersex difference in the CST in our study is 12 μm , which is consistent with other studies

(12-22 μm) [17,22]. Ooto *et al* [23] reported an 8 μm larger CST in the men than in the women by using 3-D OCT-1000 but they did not include myopic subjects. The disparity may stem from the relatively low scanning resolution of the measuring devices and small sample size used in the earlier studies. Stratus OCT has an axial resolution of 10 μm and hence requires an appropriately large sample size to detect intersex differences of as small as 8 to 22 μm . We evaluated 82 subjects with a nearly even sex distribution among groups and used an SD-OCT instrument with an axial resolution of 5 μm . The decrease of thickness of the female fovea may be the reason why females are prone to suffer macular hole [24,25]. All the inner ring sectors were 5 to 7 μm thicker in men, which was somewhat comparable with the results of previous Stratus OCT studies [17,22]. The retinal thickness in the outer ring except for TOM showed a very small intersex differences. In the present study, we further clarified the influence of gender on retinal thickness in the macular area. The significance of these OCT findings may require further research.

The relationship between retinal thickness and age has been widely reported. Lam *et al* [17] performed rapid macular area scanning using Stratus OCT on 143 eyes, ages range (23-77 years old), refractive error range (+3.75 to -18.13D) and AL (21.20-31.10mm), and they did not find a relationship between retinal thickness and age. Song *et al* [26] used Cirrus HD-OCT to perform a study on 198 eyes, ages range (17-83 years old), refractive error range (+3.75-23.50D) and AL (21.52-32.51mm). The results indicated that except for the central zone, the thickness and volume of the macular area decreased with increased age. The authors speculated that this was in relation to the decreased photoreceptor cell density, ganglion cell and RPE observed *via* histology [27,28]. Due to retinal thickness of the macular area in high myopia leading to atrophy with increased age, we limited the age range in this study to exclude this confounding variable.

In myopia eyes, a decline in visual function parameters has been reported. These parameters include visual field, color vision, light sense, and contrast sensitivity [29,30]. Qin *et al* [31] investigated the variation of macular light sensitivity (MLS) in myopic Chinese adults by using MP1 microperimeter. The macular area division pattern covered by the MP1 grid was similar to the nine-part division of the (OCT) fields in the Fast Macular Thickness program (ETDRS-type; Carl Zeiss Meditec, Oberkochen, Germany). The results of the present study were compared with those in Qin WY and colleagues. The results of both Cirrus- HD OCT and MP1 examinations of the foveal macular region in low to moderate myopia patients were comparable to those of normal patients. In contrast, the foveal MLS decreased in high myopia eyes with normal corrected visual acuity, the macular thickness in the fovea increased. The results of both Cirrus-HD OCT and MP1 examinations showed significantly decreased in the

outer ring. It was predicted that the most severe retinal elongation would occur at the outer ring. Both microperimetry and OCT examinations should be performed on the same patient to optimize comparisons in future studies. OCT can provide high resolution characteristics of incised surface structures in living tissue. Therefore, we used this technology to perform imaging in the macular area of myopia patients. These measurements were akin to performing live histology assessment for pathological changes. We analyzed the change of macular thickness in high myopia. We also analyze the effect of refractive error/axial length and genders on macular thickness. The observations in the present study suggest that refractive error should be considered in the interpretation of macular thickness. Since the current normative database does not take refractive error in account, clinicians should be aware of the effect of this parameter when evaluating macular thickness in the diagnosis and monitoring of diseases such as diabetic macular edema, glaucoma, or after-cataract maculopathy.

ACKNOWLEDGEMENTS

Conflicts of Interest: Song AP, None; Wu XY, None; Wang JR, None; Liu W, None; Sun Y, None; Yu T, None.

REFERENCES

- 1 Lin HH, Xu L, Wang YX, Wang S, You QS, Jonas JB. Prevalence and progression of myopic retinopathy in Chinese adults: the Beijing Eye Study. *Ophthalmology* 2010;117(9):1763-1768
- 2 Pan CW, Ramamurthy D, Saw SM. Worldwide prevalence and risk factors for myopia. *Ophthalmic Physiol Opt* 2012;32(1):3-16
- 3 He M, Zheng Y, Xiang F. Prevalence of myopia in urban and rural children in mainland China. *Optom Vis Sci* 2009;86(1):40-44
- 4 Low W, Dirani M, Gazzard G, Chan YH, Zhou HJ, Selvaraj P, Au Eong KG, Young TL, Mitchell P, Wong TY, Saw SM. Family History, near work, outdoor activity, and myopia in Singapore Chinese preschool children. *Br J Ophthalmol* 2010; 94(8):1012-1016
- 5 Au Eong KG, Tay TH, Lim MK. Race, culture and Myopia in 110 236 young Singaporean males. *Singapore Med J* 1993;34(1):29-32
- 6 Pan CW, Zheng YF, Anuar AR. Prevalence of refractive errors in a multiethnic Asian population: the Singapore epidemiology of eye disease study. *Invest Ophthalmol Vis Sci* 2013;54(4):2590-2598
- 7 Lim MC, Hoh ST, Foster PJ, Lim TH, Chew SJ, Seah SK, Aung T. Use of optical coherence tomography to assess variations in macular retinal thickness in myopia. *Invest Ophthalmol Vis Sci* 2005;46(3):974-978
- 8 Wakitani Y, Sasoh M, Sugimoto M, Ito Y, Ido M, Uji Y. Macular thickness measurements in healthy subjects with different axial lengths using optical coherence tomography. *Retina* 2003;23(2):177-182
- 9 Zou H, Zhang X, Xu X, Yu S. Quantitative *in vivo* retinal thickness measurement in chinese healthy subjects with retinal thickness analyzer. *Invest Ophthalmol Vis Sci* 2006;47(1):341-347
- 10 Forte R, Cennamo GL, Finelli ML, de Crecchio G. Comparison of time domain Stratus OCT and spectral domain SLO/OCT for assessment of macular thickness and volume. *Eye (Lond)* 2009;23(11):2071-2078
- 11 Leung CK, Cheung CY, Weinreb RN, Lee G, Lin D, Pang CP, Lam DS. Comparison of macular thickness measurements between time domain and spectral domain optical coherence tomography. *Invest Ophthalmol Vis Sci* 2008;49(11):4893-4897
- 12 Goebel W, Franke R. Retinal thickness in diabetic retinopathy: comparison of optical coherence tomography, the retinal thickness analyzer, and fundus photography. *Retina* 2006;26(1):49-57
- 13 Chan A, Duker JS, Ishikawa H, Ko TH, Schuman JS, Fujimoto JG. Quantification of photoreceptor layer thickness in normal eyes using optical coherence tomography. *Retina* 2006;26(6):655-660
- 14 Legarreta JE, Gregori G, Punjabi OS, Knighton RW, Lalwani GA, Puliafito CA. Macular thickness measurements in normal eyes using spectral domain optical coherence tomography. *Ophthalmic Surg Lasers Imaging* 2008;39(4 Suppl): S43-49
- 15 Kakinoki M, Sawada O, Sawada T, Kawamura H, Ohji M. Comparison of macular thickness between Cirrus HD-OCT and Stratus OCT. *Ophthalmic Surg Lasers Imaging* 2009;40(2):135-140
- 16 Grover S, Murthy RK, Brar VS, Chalam KV. Normative data for macular thickness by high-definition spectral domain optical coherence tomography (Spectralis). *Am J Ophthalmol* 2009;148(2):266-271
- 17 Lam DS, Leung KS, Mohamed S, Chan WM, Palanivelu MS, Cheung CY, Li EY, Lai RY, Leung CK. Regional variations in the relationship between macular thickness measurements and myopia. *Invest Ophthalmol Vis Sci* 2007;48(1):376-382
- 18 Wu PC, Chen YJ, Chen CH, Chen YH, Shin SJ, Yang HJ, Kuo HK. Assessment of macular retinal thickness and volume in normal eyes and highly myopic eyes with third-generation optical coherence tomography. *Eye (Lond)* 2008;22(4):551-555
- 19 Liang H, Crewther DP, Crewther SG, Barila AM. A role for photoreceptor outer segments in the induction of deprivation myopia. *Vision Res* 1995;35(9):1217-1225
- 20 Wong AC, Chan CW, Hui SP. Relationship of gender, body mass index, and axial length with central retinal thickness using optical coherence tomography. *Eye (Lond)* 2005;19(3):292-297
- 21 El-Ashry M, Hegde V, James P, Pagliarini S. Analysis of macular thickness in British population using optical coherence tomography (OCT): an emphasis on interocular symmetry. *Curr Eye Res* 2008;33(8):693-699
- 22 Kelty PJ, Payne JF, Trivedi RH, Kelty J, Bowie EM, Burger BM. Macular thickness assessment in healthy eyes based on ethnicity using Stratus OCT optical coherence tomography. *Invest Ophthalmol Vis Sci* 2008;49(6):2668-2672
- 23 Ooto S, Hangai M, Sakamoto A, Tomidokoro A, Araie M, Otani T, Kishi S, Matsushita K, Maeda N, Shirakashi M, Abe H, Takeda H, Sugiyama K, Saito H, Iwase A, Yoshimura N. Three-dimensional profile of macular retinal thickness in normal Japanese eyes. *Invest Ophthalmol Vis Sci* 2010;51(1):465-473
- 24 Evans JR, Schwartz SD, McHugh JD, Thamby-Rajah Y, Hodgson SA, Wormald RP, Gregor ZJ. Systemic risk factors for idiopathic macular holes: a case-control study. *Eye (Lond)* 1998;12(Pt 2):256-259
- 25 Risk factors for idiopathic macular holes. The Eye Disease Case-Control Study Group. *Am J Ophthalmol* 1994;118(6):754-761
- 26 Song WK, Lee SC, Lee ES, Kim CY, Kim SS. Macular thickness variations with sex, age, and axial length in healthy subjects: a spectral domain-optical coherence tomography study. *Invest Ophthalmol Vis Sci* 2010;51(8):3913-3918
- 27 Panda-Jonas S, Jonas JB, Jakobczyk-Zmija M. Retinal photoreceptor density decreases with age. *Ophthalmology* 1995;102(12):1853-1859
- 28 Gao H, Hollyfield JG. Aging of the human retina. Differential loss of neurons and retinal pigment epithelial cells. *Invest Ophthalmol Vis Sci* 1992;33(1):1-17
- 29 Yamaji R, Yamasowa K, Yamaji S. The quantitative perimetry of high myopia. *Folia Ophthalmol Jpn* 1976;27:633-644
- 30 Curtin BJ. The Myopia: basic science and clinical management. Philadelphia: Harper & Row, 1985:353-357
- 31 Qin YW, Zhu MJ, Qu XM, XU GZ, Yu YF, Witt RE, Wang WJ. Regional macular light sensitivity changes in myopic Chinese adults: an MP1 study. *Invest Ophthalmol Vis Sci* 2010;51(9):4451-4457