

# Effects of Honghua preserved amniotic membrane on scar healing in experimental glaucoma surgery

Yi Shao<sup>1</sup>, Yao Yu<sup>2</sup>, Qiu-Ping Liu<sup>3</sup>, Jing-Ming Li<sup>3</sup>, Fei Dong<sup>4</sup>, Xin Huang<sup>1</sup>, Chong-Gang Pei<sup>1</sup>, Ping Tu<sup>2</sup>, Hen-Hui Li<sup>1</sup>, Gui-Ping Gao<sup>1</sup>

<sup>1</sup>Department of Ophthalmology, the First Affiliated Hospital of Nanchang University, Nanchang 330006, Jiangxi Province, China

<sup>2</sup>Department of Endocrinology, the Third Hospital of Nanchang, the Affiliated Nanchang Hospital of Southern Medical University, Nanchang 330009, Jiangxi Province, China

<sup>3</sup>Jiangxi Research Institute of Ophthalmology and Visual Sciences, Nanchang 330006, Jiangxi Province, China

<sup>4</sup>Department of Ophthalmology, University of Cincinnati, 3230 Eden Avenue, Cincinnati, OH 45267, United States

**Correspondence to:** Yi Shao. Department of Ophthalmology, the First Affiliated Hospital of Nanchang University, Nanchang 330006, Jiangxi Province, China. freebee99@163.com

Received: 2013-07-31 Accepted: 2013-12-31

## Abstract

• **AIM:** To investigate the efficacy and safety of Honghua preserved amniotic membrane (AM) for preventing scar formation of the filtering bleb in a rabbit model of glaucoma trabeculectomy surgery.

• **METHODS:** Totally 36 rabbits (36 eyes) were randomly divided into 3 groups: the experimental group (ocular trabeculectomy in combination with Honghua preserved AM transplantation), the control group (ocular trabeculectomy surgery in combination with AM implantation), and the blank group (single trabeculectomy). Clinical observations [including intraocular pressure (IOP), filtering blebs and complications], Masson – Trichrome staining, real-time quantitative reverse transcription-polymerase chain reaction (real-time PCR), Western blot were performed on different time points (D1, D7, D14, D21 and D56) after the surgery.

• **RESULTS:** After operated for 14d, there were statistically significant differences in the filtering blebs compared to the situation before operation ( $P < 0.05$ ), whereas no statistically difference on that among three groups ( $P > 0.05$ ). After 21d, the IOP of experimental group was lowest ( $P < 0.05$ ). There was significant difference between control group and blank group ( $P < 0.05$ ). On postoperative D14, the mean number of fibroblasts in the experimental group was significantly

lower ( $40.6 \pm 10.2$ ) compared to those in the control group ( $54.4 \pm 10.8$ ) and blank group ( $68.2 \pm 11.6$ ) ( $P < 0.05$ , respectively). The mean numbers of the macrophage in the experimental and control groups were respectively significantly lower versus the blank group ( $P < 0.05$ ,  $P < 0.05$ , respectively). Compared to that in blank group, the level of transforming growth factor  $-\beta$  (TGF  $-\beta$ 1) expression in sclera and conjunctival areas was reduced in the experimental and control groups on protein and mRNA level ( $P < 0.05$ ), but not significant difference between these two groups ( $P > 0.05$ ).

• **CONCLUSION:** The trabeculectomy surgery with Honghua preserved AM can control IOP, sustain the functional filtration bleb, inhibit the proliferation of fibroblasts and open the filtering pathway on the rabbit glaucoma models.

• **KEYWORDS:** amniotic membrane; trabeculectomy; Honghua injection; implant; transforming growth factor- $\beta$ ; scar formation

DOI:10.3980/j.issn.2222-3959.2014.02.07

Shao Y, Yu Y, Liu QP, Li JM, Dong F, Huang X, Pei CG, Tu P, Li HH, Gao GP. Effects of Honghua preserved amniotic membrane on scar healing in experimental glaucoma surgery. *Int J Ophthalmol* 2014;7(2):226-231

## INTRODUCTION

The scar formation is the most common problem after trabeculectomy for glaucoma, which is usually followed by the recurrence of high intraocular pressure (IOP)<sup>[1]</sup>. Inhibition of fibroblasts proliferation and maintenance of IOP are two major requirements to prevent the progression of glaucoma. Amniotic membrane (AM) transplantation is widely used in trabeculectomy for glaucoma treatment. As a modulator of trabeculectomy wound healing, amniotic membrane plays effectively role in preventing adhesion and promoting the healing of biomembrane<sup>[2,3]</sup>. But evidence shows that transforming growth factor (TGF)- $\beta$ , which can stimulate sclera fibroblast proliferation, migration and extracellular matrix production, is secreted by AM<sup>[4]</sup>. TGF- $\beta$  may be the cause of scar formation after trabeculectomy with AM transplantation. Though mitomycin C and 5-Fluorouracil are always applied intra-operatively to inhibit scar adhesion,

they may cause postoperative complications and further influence IOP and vision [5]. An alternative anti-proliferative material is under urgent need [6]. Previous studies demonstrated that the integrity of tendinous sheath was well kept and tendon healing was promoted in Honghua preserved AM by inhibiting the expression of TGF- $\beta$  [7,8]. Honghua preserved AM, as an implant in penetrating trabeculectomy, may cause a series of pathological and cytological alterations. To the best of our knowledge, there have been no reports about trabeculectomy surgery with Honghua preserved AM for glaucoma. In this study, to evaluate its histopathologic and cytokine alterations, and to provide experimental evidences for clinical application, we prospectively reviewed our results of glaucoma with trabeculectomy surgery using Honghua preserved AM in rabbit glaucoma model.

## MATERIALS AND METHODS

### Preparation of Human Amniotic Membrane and Honghua Preserved

Human AM (hAM) was obtained from a healthy human placenta after cesarean section in accordance with the tenets of the Declaration of Helsinki for research involving human subjects and with the approval from the Institutional Review Board of First Affiliated Hospital of Nanchang University (Nanchang, Jiangxi, China). The proper informed consent was obtained from all the donors. The membranes were washed with sterile phosphate-buffered saline (PBS) containing antibiotics (0.05% Tobramycin), cutted into pieces (4×3-cm<sup>2</sup>) and stored in a 1:1 mixture of DMEM and glycerol at -80°C for further use. To prepare Honghua preserved hAM, stored hAM was rethawed, washed by PBS and cut into smaller pieces (6×6-mm<sup>2</sup>). Each hAM piece was carefully placed flat on the 6-well plate and preserved in Honghua for 12h.

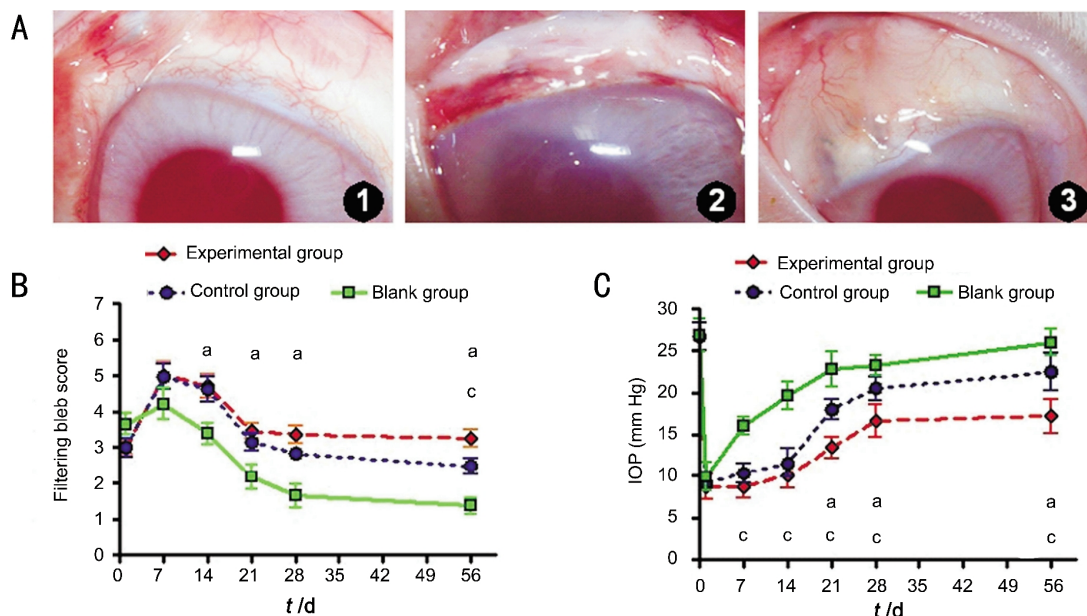
**Glaucoma Models and Groups** Thirty-six New Zealand white rabbits with the weight between 2.0 and 2.5kg (both female and male) were included in this study. The rabbits were housed in a standard animal box kept at a constant temperature of 18-25°C and with a 12h light/dark cycle with standard food and water provided. With permission from the First Affiliated Hospital of Nanchang University Animal Ethics Committee, the IOP of both eyes was recorded with a Tonocon (Topocon. Inc., Japan) after topical proparacaine 0.5% HCl anesthesia. Later, the rabbits were anesthetized with an intramuscular injection of ketamine (25 mg/kg), xylazine (2 mg/kg) and topical xylocaine before procedure. A wire lid speculum was used to separate the eyelids. The anterior chamber of the right eye was entered in the superotemporal quadrant through a long corneal tunnel using a 25-G needle as we were unable to inject the sodium hyaluronate through a smaller gauge needle, and an intracameral injection of 2.3 mg/mL sodium hyaluronate with subconjunctival dexamethasone injection was administered. The intracameral injection was repeated once a week. IOP

measurements were performed at the same time each day or week to beware of the diurnal variations in IOP. After injection, IOP was measured with a Tonocan on the 1<sup>st</sup>, 3<sup>rd</sup> and 10<sup>th</sup> days. Five days later, IOP was stable from 25 mm Hg to 35 mm Hg. Then, 36 rabbits (36 eyes) with glaucoma were randomly divided into 3 groups: the experimental group (ocular trabeculectomy in combination with Honghua preserved AM transplantation), the control group (trabeculectomy surgery and AM implantation), and the blank group (single trabeculectomy). Each group included 12 rabbits. Clinical observation (including IOP, filtering blebs and complications), hematoxylin and eosin (HE) staining, Masson-Trichrome, real-time quantitative reverse transcription-polymerase chain reaction (real-time PCR) and western blot were performed on D1, D7, D14, D28 and D56 following surgery.

**Surgery Procedure** Trabeculectomy was performed on the superior quadrant. 1/2 thickness trapezoid sclera flap was about 4×3×3mm<sup>3</sup>, routine combined trabeculectomy (about 1.5×3.0-mm<sup>2</sup> trabeculum tissues and superior iridectomy) was performed, and inclusion of the Honghua preserved AM (before Honghua preserved, 6×6-mm<sup>2</sup> size) under the scleral flap were performed in the right eyes of experimental group [9]. The conjunctival flaps were sutured using 10-0 nylon suture, subconjunctival dexamethasone (1 mL) were injected by the end of the surgery. On the control group, simple AM implant application in trabeculectomy were applied. On the blank group, no implant application in trabeculectomy were applied. All rabbits were anesthetized with intraperitoneal pentobarbital sodium (50 mg/kg) and topical 0.5% proparacaine hydrochloride. The operation site was disinfected with 0.5% povidone iodine. All surgeries were done under an operating microscope (VISU 150, Carl Zeiss, Germany) by the same investigator. After the operation, erythromycin ophthalmic ointment (Sanyi, China) was applied. In addition, norfloxacin eye drops (Wujing, China) were instilled three times a day during the week following the surgery. These operated eyes were track and followed up from post-operative D1 to D56.

**Histopathological Observation** Two rabbits at each timepoint (D1, D7, D14, D21, D28 and D56 post-operatively) underwent enucleation. The operation sites of enucleated eyes were dissected as blocks which contain the bleb, conjunctiva, tenon, and sclera. HE staining and Masson-Trichrome staining were performed to detect the number of fibroblasts and macrophages as previously reported [10].

**Western Blot Analysis** Samples of conjunctival (including conjunctival and Tenon's capsule) and sclera tissues from three groups were washed three times with sterile PBS, sliced into small pieces, and extracted in cold lysis buffer comprising 50 mmol/L Tris-Cl (pH 7.5), 150 mmol/L NaCl,



**Figure 1 Filtering bleb condition and IOP measurement in three groups after surgery** A: Filtering bleb condition at postoperative four weeks, the experimental group (A1), the control group (A2) and the blank group (A3); B: Filtering bleb score at each observation time points after operation in three groups; C: IOP measurement at each observation time points in three groups (pairwise comparison using the LSD method). <sup>a</sup> $P < 0.05$  vs blank group, <sup>c</sup> $P < 0.05$  vs control. Red: the experimental group (ocular trabeculectomy in combination with Honghua preserved AM implantation); Blue: the control group (trabeculectomy surgery and AM implantation); Green: the blank group (single trabeculectomy).

1% Nonidet P-40, 0.5% sodium deoxycholate, 0.1% sodium dodecyl sulfate (SDS), and protease and phosphatase inhibitor cocktails, and then equal amounts of protein extracts (20 g) were subjected to western blot analysis using-actin (1:10 000) and TGF- $\beta$ 1 (1:200) antibodies. The results were visualized using an enhanced chemiluminescence method<sup>[11]</sup>. Relative intensity was measured using an ImageMaster VDS (Pharmacia Biotech, San Francisco, CA, USA).

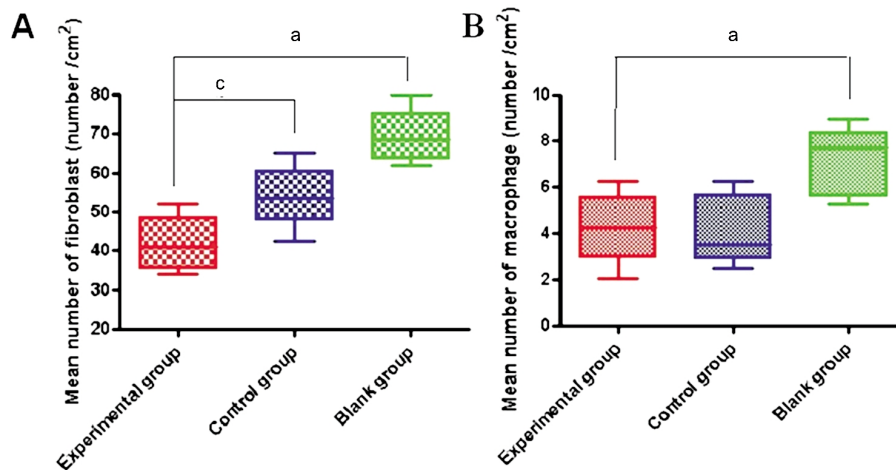
**Real-time Quantitative Reverse Transcription – polymerase Chain Reaction** Tissues were harvested from the bleb area (including conjunctiva, Tenon's capsule and sclera) at D7, D14, D21, D28 and D56 after trabeculectomy in the three groups. Real-time PCR for connective tissue growth factor (CTGF) were performed, as previously reported<sup>[12]</sup>. In brief, tissues from each time point were homogenized in 1mL extraction reagent (Trizol; Invitrogen, Wuhan Life Technology Co. Ltd, China) according to the manufacturer's suggested protocol. cDNA was synthesized using a cDNA synthesis kit (Toyobo Co. Ltd, Japan). The sequences of rabbit primers to amplify specific gene products Cdna are CTGF sense, CTGF antisense,  $\beta$ -actin sense,  $\beta$ -actin antisense. Real-time PCR was performed in a real-time PCR detection system (SLAN Hongshi Medical Technology Co. Ltd, China) using a SYBR Premix Ex Taq Kit according to the manufacturer's instructions. The results were analyzed by the comparative threshold cycle (CT) method and normalized by a housekeeping gene  $\beta$ -actin.

**Statistical Analysis** All experiments described above were repeated three times. Summary data were reported as means  $\pm$

SD. An appropriate version of the *t*-test was used to compare the group mean data, with  $P < 0.05$  considered statistically significant. Statistical analysis was performed with Prism 4.0 software (GraphPad Software, San Diego, CA, USA).

**RESULTS**

**Wound Healing and High Intraocular Pressure Analysis** In the experimental group, slight conjunctival hyperemia and edema with good conjunctival filtering bleb were seen at 7d after operation. Anterior chamber was clear without any bleeding. Fourteen days after surgery, conjunctival hyperemia was relieved by forming well established conjunctival filtering bleb. The marked inflammatory reaction was not observed after 28d (Figure 1, A1). In the control group, conjunctival filtering blebs still existed and an inflammatory reaction was observed after 28d (Figure 1, A2). But the conjunctival filtering blebs in the blank group diminished after 28d (Figure 1, A3) and showed no difference among the three groups ( $P > 0.05$ ) on postoperative D1 and D7. However, filtering bleb in blank group was narrowed obviously. After 14d, there was significant difference in bleb between the experimental and blank group ( $P < 0.05$ ), but no difference between experimental and control group ( $P > 0.05$ , Figure 1B). After 56d, the functional filter is only kept in experimental group. IOP analysis of mean IOP in the surgical eyes showed no significant difference among three groups before operation. IOP decreased after operation ( $P > 0.05$ ) in each group. Within 7d, there was no significant difference among three groups. The IOP of rabbits increased with bleb scarring



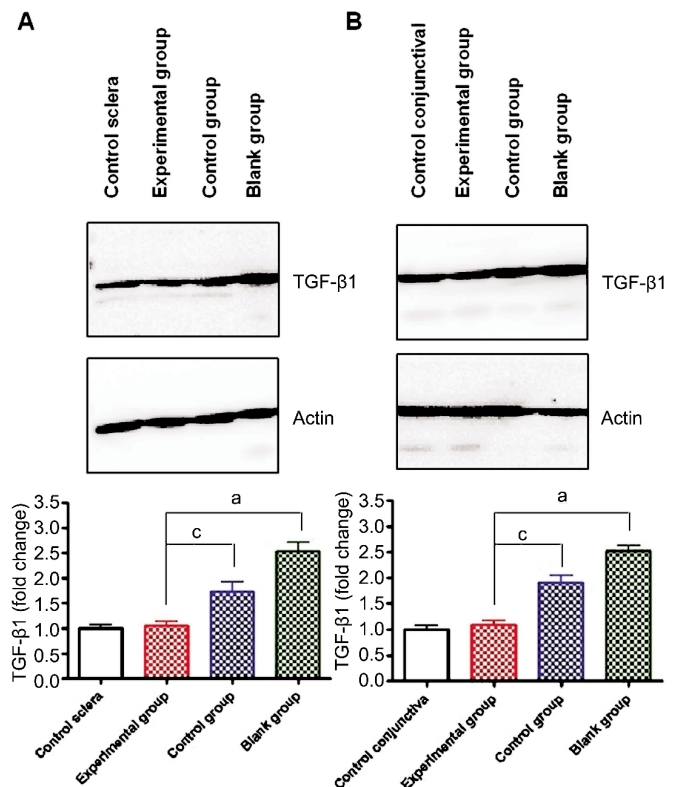
**Figure 2** Number of fibroblast (A) and macrophage (B) in surgery area in three groups on postoperative D14 <sup>a</sup> $P < 0.05$  vs blank group, <sup>c</sup> $P < 0.05$  vs control group.

formation. The IOP of experimental group was the lowest at all testing time point (D21, 28, 56) ( $P < 0.05$ ). There was also significant difference between control group and blank group ( $P < 0.05$ , Figure 1B).

**Histologic Effects** After postoperative 14 d, the mean numbers of fibroblasts in the experimental, control and blank groups were  $40.6 \pm 10.2$ ,  $54.4 \pm 10.8$  and  $68.2 \pm 11.6$ , respectively and the mean number of fibroblasts in the experimental group was significantly lowest ( $P < 0.05$ ,  $P < 0.05$ , respectively, Figure 2A). The mean numbers of macrophages in experimental, control and blank groups were  $4.5 \pm 0.7$ ,  $4.6 \pm 0.5$  and  $7.2 \pm 0.6$ , respectively. The mean numbers of the macrophage in the experimental and control groups were significantly lower than that of the blank group ( $P < 0.05$ ,  $P < 0.05$ , respectively, Figure 2B). There was no significant difference in mean macrophage number between experimental group and control group ( $P > 0.05$ , Figure 2B).

**Change of Related Proteins After Glaucoma Surgery** Western blot analysis demonstrated that the expression of TGF- $\beta$ 1 was significantly elevated after trabeculectomy in surgery area ( $P < 0.05$ ). In experimental and control group, TGF- $\beta$ 1 was significantly down-regulated in both conjunctival and scleral area. Application of Honghua preserved AM, TGF- $\beta$ 1 was reduced to the normal level in the eyes without any surgery in scleral area ( $P > 0.05$ , Figure 3A) and conjunctival area ( $P > 0.05$ , Figure 3B).

**mRNA Expression of Connective Tissue Growth Factor** Figure 4 present the mRNA level of CTGF was up-regulated and reached to the peak on D14 and then decreased till D28 and kept stable later in the experimental and blank groups, while CTGF level is not much changed after operation in the blank group. CTGF expression level is much higher in the blank group than that in other two groups. There was significant difference between experimental group and blank group ( $P < 0.05$ ) but not between experimental group and control group ( $P > 0.05$ ), Figure 4.

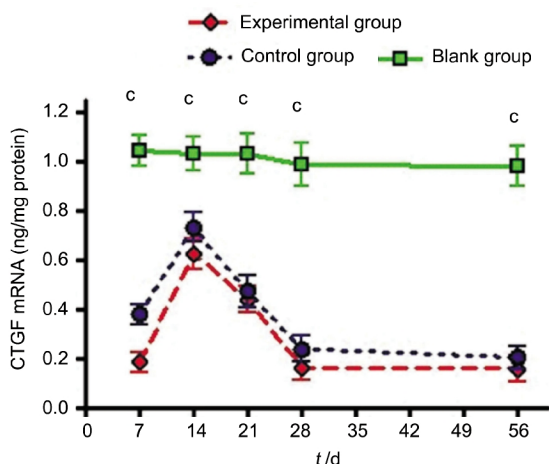


**Figure 3** Western blot analysis TGF- $\beta$ 1 in surgery area in three groups on postoperative D7 TGF- $\beta$ 1 protein was increased significantly after trabeculectomy and decreased with AM application in surgery area. TGF- $\beta$ 1 expression returned to preoperative levels after preserved AM application in sclera (A) and conjunctiva area (B). The Western blot gray value quantitative is analyzed (ImageJ software). Compared with blank group, <sup>a</sup> $P < 0.05$  vs blank group, <sup>c</sup> $P < 0.05$  vs control group.

## DISCUSSION

Glaucoma is a complex eye disease that may lead to optic atrophy and high IOP resulting in full vision loss if left untreated. Trabeculectomy is frequently used operation to lower the IOP. However, excessive subconjunctival and subsclera scarring at the filtering bleb is the most common





**Figure 4** Expression of CTGF mRNA in surgery area in three groups on postoperative D14 <sup>a</sup>*P*<0.05 vs blank group, <sup>c</sup>*P*<0.05 vs control group.

cause of failure after trabeculectomy. It is demonstrated that the proliferation of fibroblast may induce scar healing and adhesion of filtering tunnel and then future affect the formation of scar filtering bled [13]. Glucocorticosteroid, cytotoxic cytokine and grafting material are the currently used methods to prevent scar formation. The shortage is that they may delay wound healing process. To promote wound healing without scar is still the major challenge in treating glaucoma.

AM, derived from the innermost layer of the placental/fetal membrane during normal delivery, contains collagen fibers and fibroblasts. There are no vessel, nerve, and lymphatic system in AM. Experimentally, AM has been shown to promote corneal epithelial wound healing, inhibit squamous metaplasia of conjunctival epithelium and invasion of bacterium, suppress inflammation, inhibit angiogenesis [14-17]. In addition, AM has well permeability and histocompatibility to transport substances, such as urea, glucose, and NaCl [18,19]. Its capacity of wound protection and being a barrier to separate the surfaces which have potential possibility of adherence reminds us that AM may be the candidate material to reduce the formation of scar filtering bled. But the implant may also bring side effect after operation called device-induced injury which is which is considered relevant to aging and reproductive activity, for example, AM may secrete TGF-β which may be involved in scar formation

Honghua as a traditional Chinese medication drug, acts as anti-inflammatory and anti-coagulation by promoting blood circulation, moisturizing dryness, relieving pain, reducing swelling, inhibiting thrombosis and platelet aggregation and restoring menstruation [20]. Clinically, Honghua have widely been used to treat cardia and cerebral vessels diseases, hematological system diseases and wound infection. Honghua injection may reduce the scar formation and cure adult disease with fiber hyperplasy. It can also avoid second

toxic reactions occurring when using anti-proliferative agents in filtering surgery.

After evaluating the advantages of AM and Honghua, we devised a Honghua preserved AM to be used as a candidate safe and effectively antiproliferative implant for filtering surgeries for glaucoma. Although Honghua injection has not been widely used, it has been shown to contribute to tissue adhesion by reducing scar formation and nerve protection [21,22]. Our goal is to evaluate whether AM preserved in Honghua injection can prevent scar formation through inhibiting sclera valve adhesion following transplanting into sub-sclera.

Our study shows that Honghua preserved AM can facilitate rapid scarless and restore IOP after glaucoma surgery. This novel material is a safe and useful implant for animal trial, providing a distinct advantage over untreated AM. IOP control determines the success or failure of glaucoma filtration surgery. The extensive fibroblasts proliferation and scar formation together with IOP increase occurred at 21d postoperatively in blank group, but there was no obvious increase of IOP in experimental group and control group. Our experiment proved that trabeculectomy in combination with subconjunctival flap Honghua preserved AM transplantation could yield desirable IOP. The combined procedure along with Honghua AM implant appeared to be a sound method to provide adequate IOP control. The use of the Honghua AM seems to help maintain glaucoma filtering pathway.

There are three kinds of cells appeared in the surgery area: neutrophil, fibroblast and macrophage. AM and Honghua preserved AM were harvested at 2wk after surgery. Compared with that in control group during the whole procedure, the proliferation of fibroblasts was much lower in the experimental group since 2wk after surgery. It demonstrated that Honghua worked during the earlier post-operative period. The number of macrophages decreased gradually accompanied with AM digestion. At 4wk after surgery some of AM tissues were absorbed.

TGF-β1 is the representative fibrosis cytokine, which contains the rationale of scarless healing in fetus wounding. It is a key mediator of wound healing and is critically involved in postoperative scarring after glaucoma filtration surgery [23]. CTGF is a heparin-binding protein which is strongly induced by TGF-β in fibroblasts [24]. During tissue repair and early development, TGF-β expression is coordinately regulated with that of CTGF. With regard to mRNA and protein level of TGF-β1 and CTGF expression, the experimental group<control group<blank group in every time point. Honghua preserved AM could inhibit proliferative quantity of fiber tissue and relieve adhesion by inhibiting TGF-β1 levels. The differences demonstrated that Honghua preserved AM effectively prevented fibroblast proliferation and scar formation, inhibits inflammation and was more beneficial

with regard to post-operative effects.

In this study, we have found that trabeculectomy surgery with Honghua preserved AM can inhibit sub-sclera or sub-conjunctiva fibrosis by reducing TGF- $\beta$ 1. We highly recommend that the use of Honghua preserved AM during trabeculectomy surgery is an effective therapy in the management of glaucoma. In addition, TGF- $\beta$ 1 inhibitor may potentially have widespread applications in glaucoma anti-scarring therapy.

In conclusion, trabeculectomy surgery with Honghua preserved AM appears to be a safe and effective method of rapid restoring a stable IOP for glaucoma. Further studies will focus on the mechanisms of scar inhibition by TGF- $\beta$ 1 and the evaluation of the long-term recovery of this implant material by the animal experiments. The effect of a large quantity of clinical patients with glaucoma is also needed to be further evaluated.

#### ACKNOWLEDGEMENTS

**Foundations:** Supported by the National Natural Science Foundation of China (No.81160118); Clinical Medicine Research Special-purpose Foundation of China (No. L2012052); Science and Technology Foundation of Jiangxi Province (No.20111BBG70026-2); Jiangxi Province Youth Science Foundation (No.20114BAB215036); Science and Technology Platform Construction Project of Jiangxi Province (No.2013-116); Health Department Tradition Chinese Medicine Science and Technology Foundation (No. 2012A087)

**Conflicts of Interest:** Shao Y, None; Yu Y, None; Liu QP, None; Li JM, None; Dong F, None; Huang X, None; Pei CG, None; Tu P, None; Li HH, None; Gao GP, None.

#### REFERENCES

- 1 Zhong H, Sun G, Lin X, Wu K, Yu M. Evaluation of pifenidone as a new postoperative antiscarring agent in experimental glaucoma surgery. *Invest Ophthalmol Vis Sci* 2011;52(6):3136-3142
- 2 Nakamura M, Naka M, Tatsumi Y, Nagai-Kusuhara A, Kanamori A, Yamada Y, Negi A. Filtering bleb structure associated with long-term intraocular pressure control after amniotic membrane-assisted trabeculectomy. *Curr Eye Res* 2012;37(3):239-250
- 3 Sheha H, Kheirikhah A, Taha H. Amniotic membrane transplantation in trabeculectomy with mitomycin C for refractory glaucoma. *J Glaucoma* 2008;17(4):303-307
- 4 Thomas DW, O'Neill ID, Harding KG. Cutaneous wound healing: a current perspective. *J Oral Maxillofac Surg* 1995;53 (4):442-447
- 5 Freiberg FJ, Matlach J, Grehn F, Karl S, Klink T. Postoperative subconjunctival bevacizumab injection as an adjunct to 5-fluorouracil in the management of scarring after trabeculectomy. *Clin Ophthalmol* 2013; 7:1211-1217
- 6 Saeed AM. Comparative study between trabeculectomy with photodynamic therapy (BCECF-AM) and trabeculectomy with antimetabolite (MMC) in the treatment of primary open angle glaucoma. *Clin Ophthalmol* 2012;6:1651-1664
- 7 Zeng CX, Zhao PN. Effective observation on lamellar keratoplasty with fresh amniotic membrane transplantation for mooren's ulcer. *Hainan Yixue*

- 2009;20(2):21-23
- 8 Gao SZ, Yu GY, Wang XJ. Fresh human amnion promotes wound healing in diabetic patients. *Jiefangjun Huli Zazhi* 2007;24(18):10-11
- 9 Rodríguez-Agirretxe I, Vega SC, Rezola R, Vecino E, Mendicutie J, Suarez-Cortes T, Acera A. The PLGA implant as an antimetabolic delivery system after experimental trabeculectomy. *Invest Ophthalmol Vis Sci* 2013; 54(8):5227-5235
- 10 Demir T, Turgut B, Celiker U, Ozercan I, Ulas F, Akyol N. Effects of octreotide acetate and amniotic membrane on wound healing in experimental glaucoma surgery. *Doc Ophthalmol* 2003;107(2):87-92
- 11 Park HY, Kim JH, Park CK. VEGF induces TGF- $\beta$  1 expression and myofibroblast transformation after glaucoma surgery. *Am J Pathol* 2013; 182(6):2147-2154
- 12 Chen BY, Wang CY, Chen WY, Ma JX. Altered TGF- $\beta$  2 and bFGF expression in scleral desmocytes from an experimentally-induced myopia guinea pig model. *Gracfs Arch Clin Exp Ophthalmol* 2013;251 (4): 1133-1144
- 13 Li W, Che WJ, Zhang MC. Study of self-made freeze-dried bilayered fibrin-binding amniotic membrane in ocular trabeculectomy in rabbits. *Int J Ophthalmol* 2011;4 (6):582-589
- 14 Jampel HD, McGuigan LJB, Dunkelberger GR. Cellular proliferation after experimental glaucoma filtration surgery. *Arch Ophthalmol* 1988;106 (1):89-94
- 15 Kim JC, Tseng SC. Transplantation of preserved human amniotic membrane for surface reconstruction in severely damaged rabbit corneas. *Cornea* 1995;14(5):473-484
- 16 Tan Y, Qiu F, Qu Y, Li C, Shao Y, Xiao Q, Liu Z, Li W. Amniotic membrane inhibits squamous metaplasia of human conjunctival epithelium. *Am J Physiol Cell Physiol* 2011;301(1):C115-C125
- 17 Choi TH, Tseng SC. *In vivo* and *in vitro* demonstration of epithelial cell-induced myofibroblast differentiation of keratocytes and an inhibitory effect by amniotic membrane. *Cornea* 2001;20(2):197-204
- 18 Li W, He H, Kawakita T, Espana EM, Tseng SC. Amniotic membrane induces apoptosis of interferon- $\gamma$  activated macrophages *in vitro*. *Exp Eye Res* 2006;82 (2):282-292
- 19 Wei XQ, Han Y. Preparation and preservation of amniotic membrane. *Yanke Xin Jizhan* 2002;22(2):117
- 20 Jin ZD, Guan YJ, Guo JZ. Amniotic cognitive process of philosophy enlightenment. *Yixue Yu Zhixue* 1999;20(3):53-54
- 21 Nyska M, Porat S, Nyska A, Rouso M, Shoshan S. Deceased adhesion formation in flexor tendons by topical application of enriched collagen solution—a histological study. *Arch Orthop Trauma Surg* 1987;106 (3): 192-194
- 22 Zhao WH, Yu D, Wen H, Hao DM, Zhao CW. Whether amnion membrane preserved in Honghua injection can prevent tendon adhesion following transplanting into foot flexor tendon? *J Clin Rehabil Tissue Eng Res* 2010;14(5):937-940
- 23 Romano C, Price M, Bai HY, Olney JW. Neuroprotectants in Honghua: glucose attenuates retinal ischemic damage. *Invest Ophthalmol Vis Sci* 1993;34(1):72-80
- 24 Esson DW, Neelakantan A, Iyer SA, Blalock TD, Balasubramanian L, Grotendorst GR, Schultz GS, Sherwood MB. Expression of connective tissue growth factor after glaucoma filtration surgery in a rabbit model. *Invest Ophthalmol Vis Sci* 2004;45(2):485-491
- 25 Grotendorst GR, Okochi H, Hayashi N. A novel transforming growth factor- $\beta$  response element controls the expression of the connective tissue growth factor gene. *Cell Growth Differ* 1996;7(4):469-480