

# Endophthalmitis secondary to globe penetration from hydrogel scleral buckle

*Katrina A. Mears, Rachel K. Sobel, Erin M. Shriver, Elliott H. Sohn*

Department of Ophthalmology and Visual Sciences, University of Iowa Carver College of Medicine, 200 Hawkins Drive, Iowa City 52242, Iowa, USA

**Correspondence to:** Elliott H. Sohn. Department of Ophthalmology and Visual Sciences, University of Iowa Carver College of Medicine, 200 Hawkins Drive, Iowa City 52242, Iowa, USA. [elliott-sohn@uiowa.edu](mailto:elliott-sohn@uiowa.edu)

Received: 2013-11-11 Accepted: 2014-01-02

**DOI:10.3980/j.issn.2222-3959.2014.03.35**

Mears KA, Sobel RK, Shriver EM, Sohn EH. Endophthalmitis secondary to globe penetration from hydrogel scleral buckle. *Int J Ophthalmol* 2014;7(3):585-586

**Dear Sir,**

I am Dr Katrina A. Mears, from the Department of Ophthalmology and Visual Sciences, University of Iowa Carver College of Medicine, 200 Hawkins Drive, Iowa City, Iowa, USA. I wish to present a case of endophthalmitis secondary to globe penetration from a hydrogel scleral buckle which, to the best of our knowledge, is the first reported case in the literature.

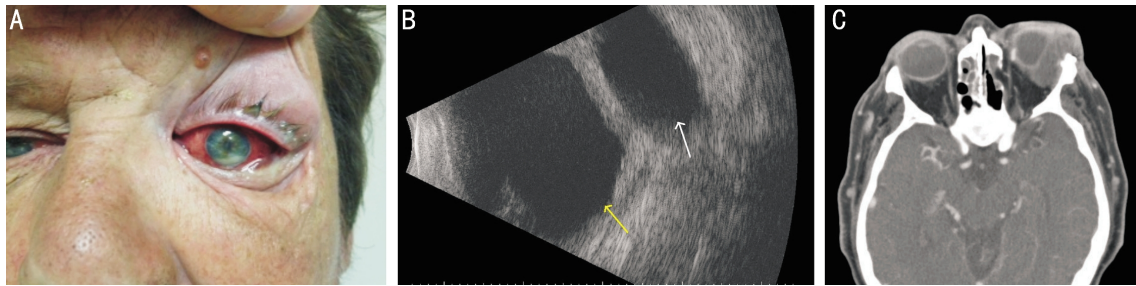
Hydrogel scleral buckles (exoplants), including MIRAgel (MIRA, Waltham, MA), are composed of hydrophilic polymers<sup>[1]</sup>. Due to its unexpected instability *in vivo* and ensuing complications due to this uncontrolled expansion, however, it was removed from the market in 1995.

A 52y old male with a history of multiple retinal detachment surgeries 25y prior and poor vision in the left eye (OS) presented to the emergency room with mild discharge OS for one month. Three days prior to presentation he noticed the discharge became purulent, however his visual acuity never changed from its poor baseline. On examination, visual acuity OS was light perception and there was a left relative afferent pupillary defect. Intraocular pressure was 17 mm Hg OD and 23 mm Hg OS. There was marked restriction of the extraocular movements OS. He had an enlarged, palpable mass with a rubber-like consistency in the superotemporal orbit adjacent to the lacrimal gland. There was significant upper lid ptosis, mild chemosis, and an elevated raised red lesion on the upper temporal conjunctiva, which appeared to communicate with the orbital lesion. There was moderate corneal edema with 2+ flare, 2+ cells, and a 1.8 mm

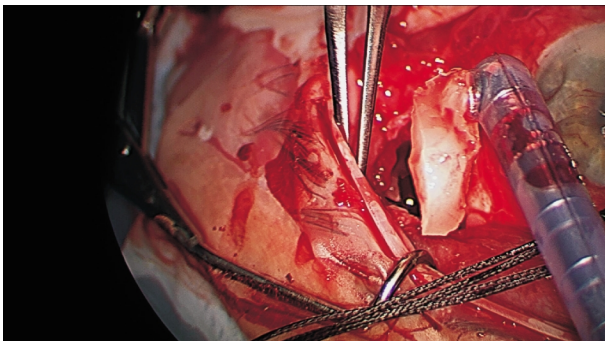
hypopyon in the anterior chamber (Figure 1A). There was no view of the fundus due to the anterior chamber findings. The patient consented to have this case report and images published.

Echography revealed vitreous debris and inferotemporal tractional membranes as well as a superotemporal extraocular hypoechoic mass indenting the globe approximately 40% of its volume (Figure 1B). Computed tomography (CT) of the orbits demonstrated a well-defined, hypointense, ovoid intraconal mass which extended posteriorly to the optic nerve. There was well-demarcated hyperintense material (presumably silicone rubber scleral buckle) encircling the globe on several cuts of the CT (Figure 1C). Due to the concern for endophthalmitis secondary to suspected erosion of the implant into the globe, the patient was taken to the operating room for exploration and removal of the implant. A 360 degree conjunctival peritomy was performed and the rectii muscles were identified. A large collection of translucent, friable, intraconal material was identified superotemporally between the lateral and superior rectus muscles. The implant was removed piecemeal using the cryoprobe to grasp fragments while on freezing mode (Figure 2). During careful removal of these fragments, it was noted that the sclera was eroded and debris containing purulent material and coagulated hemorrhage had tamponaded the wound. There was an intraoperative choroidal hemorrhage. Cultures of the purulent material revealed *Haemophilus influenzae*. On post-operative day one, the visual acuity was no light perception. The patient was placed on systemic moxifloxacin and oral prednisone post-operatively and these were tapered after a few days when the ocular infection, orbital inflammation, proptosis and discomfort improved significantly. Unfortunately due to social circumstances the patient was unable to follow-up at our center one month after his surgery.

To the best of our knowledge we are the first to report a case of endophthalmitis due to penetration of a hydrogel implant into the globe<sup>[2]</sup>. Removal of these types of implants has a variable prognosis. Reported complications include pain, discomfort caused by expansion and erosion of the buckle into the globe, hydrolysis of the buckle producing external inflammation mimicking cellulitis, migration and extrusion of the buckle, ptosis, intraocular erosion and restriction of extraocular motility causing strabismus and diplopia<sup>[2-5]</sup>.



**Figure 1 The preoperative finding** A: Preoperative photograph showing marked periorbital edema, conjunctival injection, chemosis and hypopyon; B: Echography (T2 section) of the involved eye showing the intravitreal cavity (yellow arrow) and the echolucent hydrated hydrogel implant (white arrow); C: CT on coronal section shows a left temporal encapsulated mass indenting the globe and the nasal band remnant.



**Figure 2 Intraoperative removal of the hydrogel fragments using the cryo-probe.**

Removal of MIRAgel scleral buckles is fraught with difficulty due to its gel-like consistency and friable nature of the hydrolyzed material. Patients presenting without a clear history can be challenging to diagnose and in these cases imaging can often provide crucial clues. Echography of hydrogel implants can reveal an anechoic structure indenting the globe. Hydrogel is hypodense on noncontrast CT, often with an enhancing ring peripherally (due to the fibrous encapsulation) following the administration of contrast as seen in our patient (Figure 1C). On magnetic resonance imaging, hydrogel is hyperintense on T2-weighted imaging and isointense on T1-weighted with a peripheral rim of enhancement<sup>[6]</sup>. In contrast, silicone rubber scleral buckles are hyperdense on computed tomography and display low signal

intensity on T1- and T2-weighted magnetic resonance imaging.

In a patient with a history of retinal detachment surgery before 1995 presenting with severe intraocular and orbital inflammation, hydrolyzed scleral buckle should be on the differential diagnosis and consideration should be given to its removal.

**ACKNOWLEDGEMENTS**

**Conflicts of Interest:** Mears KA, None; Sobel RK, None; Shriver EM, None; Sohn EH, None.

**REFERENCES**

- 1 Refojo MF, Leong FL. Poly (methyl acrylate-co-hydroxyethyl acrylate) hydrogel implant material of strength and softness. *J Biomed Mater Res* 1981;15(4):497-509
- 2 Kearney JJ, Lahey JM, Borirakchanyavat S, Schwartz DM, Wilson D, Tanaka SC, Robins D. Complications of hydrogel explants used in scleral buckling surgery. *Am J Ophthalmol* 2004;137(1):96-100
- 3 Chen CJ, Kosek K, Benvenuti E. Outcomes and complications of hydrogel scleral explant removal. *Ophthalmic Surg Lasers Imaging* 2012;43(5):383-387
- 4 Ozgur OK, Modjtahedi SP, Lin LK. Eyelid fistula caused by a scleral buckle. *Ophthalm Plast Reconstr Surg* 2010;26(5):369-371
- 5 Marin JF, Tolentino FI, Refojo MF, Schepens CL. Long-term complications of the MAI hydrogel intrascleral buckling implant. *Arch Ophthalmol* 1992;110(1):86-88
- 6 Ginat DT, Singh AD, Moonis G. Multimodality imaging of hydrogel scleral buckles. *Retina* 2012;32(8):1449-1452