

Flare up of rheumatoid arthritis associated with Vogt-Koyanagi-Harada syndrome treated with leflunomide

Jia Wang¹, Qi-Bing Xie², Yi Zhao², Yi Liu²

¹Department of General Medicine Center, Sichuan Provincial People's Hospital, Chengdu 610072, Sichuan Province, China

²Departments of Rheumatology and Immunology, West China Hospital, Sichuan University, Chengdu 610041, Sichuan Province, China

Correspondence to: Yi Liu. Departments of Rheumatology and Immunology, West China Hospital, Sichuan University, No. 37 Guo Xue Xiang, Chengdu 610041, Sichuan Province, China. yi2006liu@163.com

Received: 2013-12-16 Accepted: 2014-01-22

DOI:10.3980/j.issn.2222-3959.2014.05.30

Wang J, Xie QB, Zhao Y, Liu Y. Flare up of rheumatoid arthritis associated with Vogt-Koyanagi-Harada syndrome treated with leflunomide. *Int J Ophthalmol* 2014;7(5):909-911

Dear Editor,

We present a case of "Flare up of rheumatoid arthritis associated with Vogt-Koyanagi-Harada (VKH) syndrome treated with leflunomide". To our knowledge, this is the first case of uveitis and arthritis inflammation active at the same time and no treatment for this condition has been described in the literature.

Arthritis and inflammatory eye disease, relationship has been well described for decades, however, unusual association between them deserve to be explored profoundly. Inflammatory eye diseases commonly occur as extra-articular manifestations of many systemic rheumatic disorders, especially in spondyloarthropathies (SpA). In rheumatoid arthritis (RA), ocular complications mainly are keratoconjunctivitis sicca (KCS), xerostomia, scleritis, peripheral ulcerative keratitis (PUK). However, uveitis has been rarely described in RA.

A 43-year-old Chinese woman initially presented to an ophthalmologist with two-week history of bilateral blurred vision. Two weeks prior to the ocular symptoms she had complained of pain and swelling in multiple joints (symmetric proximal and distal interphalangeal, metacarpophalangeal, wrists, elbows, shoulders and the right

knee joints) with morning stiffness lasting for an hour and low-grade fever. She had a 6-year history of RA and had undergone treatment with corticosteroids, non-steroidal anti-inflammatory drugs (NSAIDs), leflunomide (LEF) and total glucosides of paeony capsules (TGPC) in her local hospital. Her past treatment history showed she suffered from methotrexate (MTX)-related gastrointestinal adverse effects. Treatment was finally discontinued over one year due to lack of symptoms. This time she took meloxicam by herself to control the pain of multiple joints without initially seeking medical help. After 2wk, she developed acute onset of bilateral decreased visual acuity, ocular discomfort, photophobia accompanied by headache, tinnitus and dizziness. She came to our ophthalmological outpatient clinic. Her family history was unremarkable. She had no history of ocular trauma or other ocular disease. She had no integumentary findings. Neurologic revealed mild headache and tinnitus and cerebrospinal fluid examination revealed normal. Cutaneous examination revealed normal.

Her ocular examination revealed visual acuities of 20/200 OD and 20/63 OS with normal intraocular pressure. Slit lamp examination revealed 1+ inflammatory cells in anterior chamber in both eyes. Fundus examination disclosed bilateral multifocal choroiditis, retinal detachments and optic disc edema (Figure 1A, 1B). Fundus fluorescein angiography (FFA) showed tiny leakages of hyperfluorescence at the level of the retina pigment epithelium with increasing hyperfluorescence as the angiogram proceeded. In the late phases, diffuse pooling of dye was noted in the subretinal pigment epithelial space and late optic disc staining in both eyes (Figure 1C, 1D). The laboratory data showed blood chemistry, complete blood count, and infective and parasitic examinations were normal. Erythrocyte sedimentation rate (ESR) was 70 mm/h. Serum complement C3 and C4 were 0.688 g/L and 0.159 g/L respectively. Antikeratin antibody (AKA) was positive. Rheumatoid factor (RF) was 99.3 IU/mL and anti-cyclic citrullinated peptide antibody (CCP) was greater than 500 U/mL.

According to the VKH Committee's revised diagnostic criteria incomplete VKH was diagnosed, prednisone 60 mg daily (1 mg/kg) and topical corticosteroid, nonsteroidal

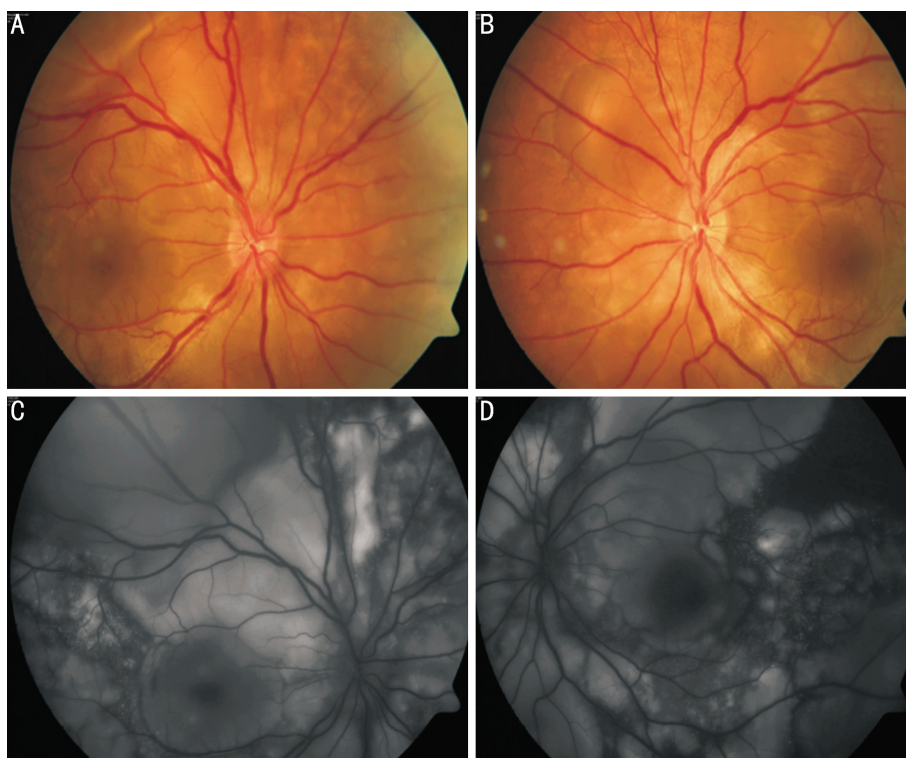


Figure 1 Fundus photographs of the right (A) and left (B) eyes prior to treatment showing localized exudative retinal detachments and optic disc edema. Fluorescein fundus angiography of the (C) right and (D) left eyes prior to treatment showing dye leakage from the damaged retinal pigment epithelium and dye pooling accumulation in the subretinal space.

anti-inflammatory ophthalmic solution and mydriatic drops were started immediately. The patient's visual acuity did not improve after 3wk therapy. She then presented to our department for further treatment. Radiography of the patient's hands showed mild osteopenia and slightly cartilage narrowing in the wrists. Therapy with LEF of 20 mg/d was introduced. Prednisone was tapered to 50 mg daily. She responded well to this combination therapy. At the third month examination, her visual acuity improved to 20/25 in the right eye and 20/32 in the left eye. Fundus examination showed attached retinas bilaterally, and FFA revealed that the leaks had resolved in both eyes. Levels of inflammatory markers decreased to the normal level and DAS-28 achieved remission of arthritis. Afterward, prednisone was gradually tapered to 10 mg/d. At 6mo follow-up, her visual acuity improved to 20/20 in both of eyes. The prednisone was discontinued one month later and TGPC was added. The dose of LEF was tapered to 10 mg/d and discontinued 3mo later. During the following one year, the patient remained in remission with no sign of relapse of her VKH syndrome and RA.

Both of RA and VKH active at the same time are rare, especially in adult. The existence of an overlap in these conditions has raised attention focused on the similar underlying pathophysiological mechanisms such as the imbalance of functional T cell subtypes and cytokines in the

two inflammatory responses ^[1]. Recent genetic studies have shown both of these independent diseases may share a common set of susceptibility genes, such as HLA-DR4 and a series of non-HLA genes of CTLA-4 and STAT4, supporting the probability of shared autoimmunity ^[2,3]. Thus, it is likely an overlap between RA and VKH at present, but may also be an unknown broad symptom of autoimmune disease.

During the acute stage of VKH, corticosteroids administered orally or intravenously constitute the mainstay treatment to prevent irreversible damage and visual loss. Immunosuppressive drugs are frequently used in chronic and recurrent phases of VKH, including cyclosporin (the most widely used adjuvant to steroid), azathioprine, cyclophosphamide, and MTX. LEF, a pyrimidine synthesis inhibitor, has similar clinical efficacy as MTX, both in early and established RA. It can be used to combine with MTX or as an alternative therapy. In this patient, she responded well to therapy and experienced a rapid decrease in both diseases activity, without significant side effects of LEF.

The clinical course of restoration of ocular inflammation may not be explained by the natural history of her illness or attributable to prednisone completely. Our experience suggests that LEF may be a valuable and efficacious addition to the treatment of VKH. More recent studies suggested that immunosuppressive therapy can achieve superior visual outcomes when compared to corticosteroids as monotherapy

or with the delayed addition of immunosuppressive therapy for the treatment of inflammatory disease associated with VKH^[4]. Experimental evidences have demonstrated that LEF affects multiple inflammatory mediators, and is able to shift the Th1/Th2 balance toward Th2 cells, improves the percentage of CD4+CD25+Tregs, and has effect in the inflammatory diseases with genetic polymorphisms such as HLA-DR modulation^[5]. Despite its known immunomodulatory effects, there are few studies regarding the role of LEF in VKH disease. A previous study reported LEF inhibited experimental autoimmune uveoretinitis (EAU) more potently than cyclosporine^[6]. Roy^[7] reported the well effect of LEF usage in chronic bilateral granulomatous anterior uveitis with stable juvenile idiopathic arthritis patient.

We believe this case may indicate the potential pathogenic link between the two diseases and raise awareness that co-operation between ophthalmologists and rheumatologists is crucial to early diagnosis and initiation of treatment of such condition. More importantly, LEF might be considered a therapeutic option in the treatment of certain autoimmune ocular diseases.

ACKNOWLEDGEMENTS

Foundations: Supported by National Natural Science

Foundation of China (No. 81401362); Scientific Research Foundation of Sichuan Provincial Health and Family Planning Commission (No. 140080); Doctoral Foundation of Sichuan Provincial People's Hospital (No. 30305030564).

Conflicts of Interest: Wang J, None; Xie QB, None; Zhao Y, None; Liu Y, None.

REFERENCES

- 1 Wang W, Shao S, Jiao Z, Guo M, Xu H, Wang S. The Th17/Treg imbalance and cytokine environment in peripheral blood of patients with rheumatoid arthritis. *Rheumatol Int* 2012;32(4):887-893
- 2 Du L, Yang P, Hou S, Lin X, Zhou H, Huang X, Wang L, Kijlstra A. Association of the CTLA-4 gene with Vogt-Koyanagi-Harada syndrome. *Clin Immunol* 2008;127(1):43-48
- 3 Hu K, Yang P, Jiang Z, Hou S, Du L, Li F. STAT4 polymorphism in a Chinese Han population with Vogt-Koyanagi-Harada syndrome and Behçet's disease. *Hum Immunol* 2010;71(7):723-726
- 4 Greco A, Fusconi M, Gallo A, Turchetta R, Marinelli C, Macri GF, De Virgilio A, de Vincentiis M. Vogt-Koyanagi-Harada syndrome. *Autoimmun Rev* 2013;12(11):1033-1038
- 5 Caspi RR. A look at autoimmunity and inflammation in the eye. *J Clin Invest* 2010;120(9):3073-3083
- 6 Salzman J, Lightman S. The potential of newer immunomodulation drugs in the treatment of uveitis: a review. *BioDrugs* 2000;13(6):397-408
- 7 Roy M. Early clinical experience with leflunomide in uveitis. *Can J Ophthalmol* 2007;42(4):634