

Curative effect assessment of bandage contact lens in neurogenic keratitis

Yu-Zhao Sun¹, Lei Guo², Fu-Sheng Zhang²

¹Department of Ophthalmology, the First Affiliated Hospital of China Medical University, Shenyang 110001, Liaoning Province, China

²Optometry Center, the First Affiliated Hospital of China Medical University, Shenyang 110001, Liaoning Province, China

Correspondence to: Yu-Zhao Sun. Department of Ophthalmology, the First Affiliated Hospital of China Medical University, Shenyang 110001, Liaoning Province, China. sunyz91667@sina.com.

Received: 2014-02-23 Accepted: 2014-05-26

Abstract

• **AIM:** To observe the curative effect of bandage contact lens in neurogenic keratitis.

• **METHODS:** Twenty cases of neurogenic keratitis were studied at the Department of Ophthalmology, the First Affiliated Hospital of China Medical University, between October 2012 and June 2013. These included 13 males and 7 females, aged from 35 to 88y. Patients were voluntarily divided into an experimental group (lens wearing group, $n=10$) and control group (drug therapy, $n=10$). In experimental group patients wore silicone hydrogel bandage soft contact lens. Both groups used the following eyedrops: 0.5% levofloxacin TID; 0.5% Sodium carboxymethyl cellulose QID; fibroblast growth factor BID; ganciclovir BID [cases complicated with herpes simplex virus (HSV)]; compound tropicamide BID (cases concurrent hypopyon). The healing time of corneal ulcer and complication rates were observed in the two groups.

• **RESULTS:** The healing time of corneal ulcer in the experimental group was 10.80 ± 4.44 d versus 46.70 ± 13.88 d in the control group ($P<0.05$). No complications occurred in the experimental group, except for the lens falling off twice in one case, the patient recovered eight days after rewearing the lens. While in the control group, all cases vascularized, 2 cases were complicated with descemetocele that recovered with amniotic membrane transplantation and 1 case was complicated with corneal perforation that recovered by autologous conjunctival flap covering.

• **CONCLUSION:** Bandage contact lens is a safe and effective method of treating neurogenic keratitis and

significantly shortened the healing time of corneal ulcer.

• **KEYWORDS:** neurogenic keratitis; bandage; contact lens

DOI:10.3980/j.issn.2222-3959.2014.06.12

Sun YZ, Guo L, Zhang FS. Curative effect assessment of bandage contact lens in neurogenic keratitis. *Int J Ophthalmol* 2014;7(6):980-983

INTRODUCTION

Neurogenic keratitis is a form of corneal epithelial degenerative disease secondary to corneal hypesthesia or loss caused by a variety of reasons^[1], such as herpes simplex viral infection, facial trigeminal nerve palsy caused by tumor and surgery, diabetes, lack of vitamin A, long-term local drops with glaucoma medication^[2-6], and corneal degeneration^[7]. It is characterized by corneal anesthesia, and reduced neurotransmitters/trophic factors for corneal epithelium, resulting in drying of the ocular surface, epithelial growth rate decline, which in turn, affects epithelial healing, and even stromal dissolution and perforation. The typical clinical signs of neurogenic keratitis are the widespread lack of corneal epithelium and ulcer in palpebral fissure part, the epithelium of the ulcer edge is smooth slightly uplifted, with no obvious stroma infiltration around the ulcer, and sustained corneal ulcer. Descemet's membrane folds and hypopyon, and even corneal ulcer perforation and eyeball loss may occur in severe cases.

The previous treatments for neurogenic keratitis include: drug treatment (artificial tears, nerve growth factor, collagen enzyme inhibition and antibiotics) and surgical treatment (tarsorrhaphy, amniotic membrane transplantation and conjunctival flap covering surgery)^[1,8,9]. Drug treatment is the most commonly used but is associated with a long recovery time and a poor curative effect. Although surgery is relatively simple, it is associated with complications such as inconvenience of observation, higher cost or affected vision, and it carries a larger psychological and economic burden. Therefore, it is important to explore a new kind of convenient and feasible treatment for neurogenic keratitis.

In recent years, with the rapid development of material science, specifically many aspects of the contact lens, such as the material, and the characteristics, have led to great improvements. The bandage contact lens is a new type of lens made from silicone hydrogel. It has the advantage of high oxygen permeability and anti-surface deposition. The

lens has been used for protection of the ocular surface, and treatment or auxiliary treatment of corneal disease [10-12]. The lens has the following characteristics: 1) Promotion of corneal wound healing; 2) Convenient application of eyedrops; 3) Facilitation of follow-up of corneal lesions; 4) Easy operation; and 5) Sustainable wear. Thus, we observed the curative effect of bandage contact lens on neurogenic keratitis, and explored a new treatment for neurogenic keratitis.

SUBJECTS AND METHODS

Ethics Statement Our investigation adhered to the tenets of the Declaration of Helsinki. This investigation was approved by the Institutional Review Board of the First Affiliated Hospital of China Medical University, and following a full explanation of the study, written informed consent was obtained from all patients.

Subjects Twenty cases of neurogenic keratitis at Department of Ophthalmology at the China Medical University Affiliated Hospital, were studied between October 2012 and June 2013. These included 13 males and 7 females aged from 35 to 88y.

Diagnosis of Neurogenic Keratitis The twenty patients were diagnosed with neurogenic keratitis using the following criteria:

- 1) Medical history: Herpes zoster virus or herpes simplex virus (HSV) infection, intracranial or maxillofacial surgery, head trauma, diabetes, long-term local with anti-glaucoma eyedrops;
- 2) Corneal sensation: hypesthesia or loss (tested by Cochet-Bonnet aesthesiometer);
- 3) Corneal scraping or confocal laser scanning microscopy: infection of bacteria, fungi and amoebic pathogen were eliminated.

Condition of Corneal Ulcers Ulcers in the twenty patients were 3 to 7 mm in diameter, and did not exceed the elastic layer in depth.

Materials Bandage contact lens: PureVision of BAUSCH & LOMB Incorporated. The lens parameters were: water content: 36%, oxygen transmission rate (DK/t): 110; material: balafilcon A, surface treatment: Performa, diameter: 14.00 mm; center thickness: 0.09 mm; the base of arc: 8.60 mm; diopter: 0 D, service life: 24 h/d, 1-21d.

Compound tropicamide and 0.5% levofloxacin (Santan company, Japan), 0.5% Sodium carboxymethyl cellulose (AiErJian Ireland pharmaceutical companies), bovine restructuring fibroblast growth factor (bFGF) (YiSheng biological pharmaceutical co., Ltd., China), ganciclovir (KeYi Pharmaceutical co., Ltd., China).

Group All cases were evaluated for wearing the bandage lens, the size and depth of corneal ulcer in each of these cases were eligible for wearing lens treatment. To determine the risk of wearing contact lens or drug treatment to the

patients and their families, patients were voluntary assigned to the experimental group (wearing lens group) and the control group (drug therapy).

Medication Both groups used the following eyedrops: 0.5% levofloxacin TID; 0.5% Sodium carboxymethyl cellulose QID; bFGF BID; ganciclovir BID (cases complicated with virus infection); compound tropicamide BID (cases concurrent hypopyon).

Curative Effect Assessment To consider corneal ulcer healing once fluorescein staining was negative. To observe the healing time of corneal ulcer and complication rates in the two groups.

Follow-up All twenty cases received medicine or contact lens therapy according to their different groups. All the cases were followed up for 7 to 15mo.

Statistical Methods To compare the healing time of corneal ulcer in the two groups by *t*-test method.

RESULTS

There were ten cases in each group, and the ages in the experimental group and control groups were $62.60 \pm 14.90y$ and $56.80 \pm 15.88y$, respectively. In the experimental group, neurogenic keratitis was caused by HSV infection in 4 cases, and by intracranial or maxillofacial surgery in 5 cases, while by facial herpes zoster virus infection occurred 1 case. In the control group, neurogenic keratitis was caused by HSV infection in 4 cases, and by intracranial or maxillofacial surgery in 5 cases, and by diabetes in 1 case.

The healing time of corneal ulcer was $10.80 \pm 4.44d$ in the experimental group (Figures 1, 2) compared with $46.70 \pm 13.88d$ in the control group (Figures 3, 4; $P < 0.05$).

Complications There were no complications in the experimental group except for the lens falling off in one case twice, this patient recovered eight days after re-wearing the lens. Only 1 patient who infected HSV 3mo experienced corneal neovascularization prior to wearing the lens, but the neovascular faded and shrunk after the corneal ulcer had healed (Figure 2).

In the control groups, 2 cases were complicated with descemetocele; these patients recovered with amniotic membrane transplantation. One case complicated with corneal perforation recovered with autologous conjunctival flap covering. Neovascularization occurred in all cases.

Twenty cases had no complications with bacterial, fungal or acanthamoeba infection during the treatment period.

Follow-up There were no cases of recurrence during the follow-up period of 7 to 15mo.

DISCUSSION

In neurogenic keratitis, artificial tears and neurotrophic factor eyedrops are associated with a long time to cure of corneal lesions (many months)^[8]. This was also demonstrated in this study: the healing time in the corneal ulcer control group was $46.70 \pm 13.88d$. Furthermore, if the stroma dissolved faster

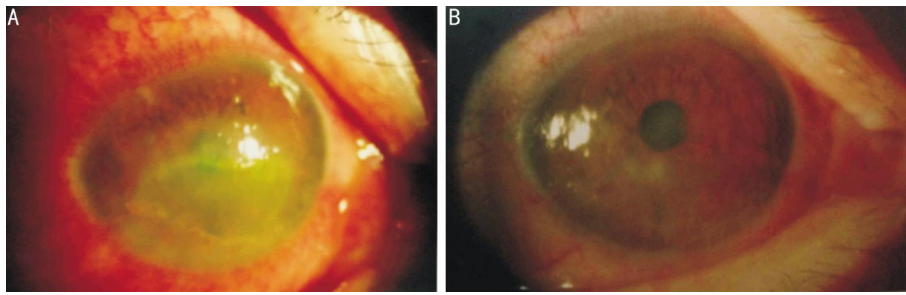


Figure 1 Case 1, male, 56y, 2mo post maxillofacial tumor surgery, neurogenic keratitis in right eye A: Pre-treatment anterior segment photograph showing a ulcer of 7×4 mm in diameter, without stroma infiltration; B: Ten days after wearing the bandage contact lens, the ulcer healed, and the cornea was transparent, without neovascularization.

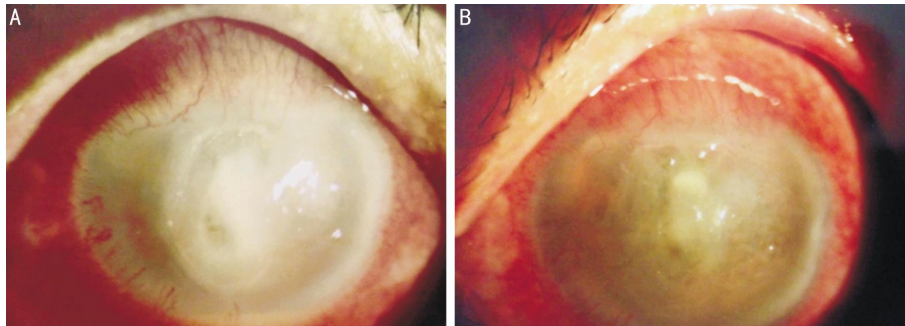


Figure 2 Case 2, male, 66y, herpes simplex viral keratitis (HSK) 3mo, neurogenic keratitis in left eye A: Pre-treatment anterior segment photograph showing a ulcer of 4×7 mm in diameter, slight stromal opacity in the ulcer, neovascular around the limbus, and hypopyon was about 1 mm; B: Seventeen days after wearing the bandage contact lens, the ulcer healed, the cornea became transparent, and neovascular faded and shrunk.

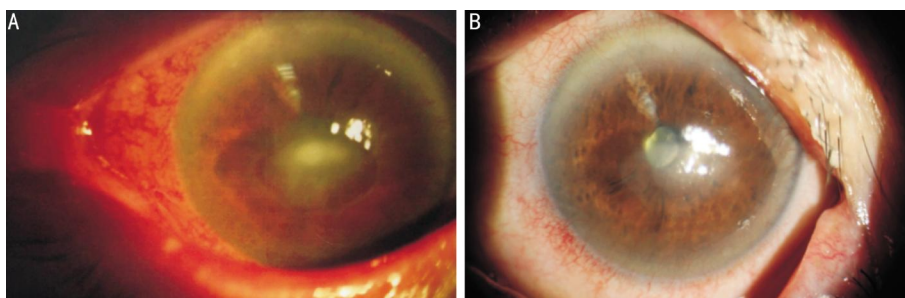


Figure 3 Case 3, female, 82y, diabetic for 23y, 2.5mo post PEA+IOL, neurogenic keratitis in left eye A: Pre-treatment anterior segment photograph showing a ulcer of 5×3 mm in diameter, and 3×1 mm slight stromal opacity in the ulcer; B: Sixty days after drug treatment, the ulcer healed, but the nebula and neovascular was observed around the limbus.

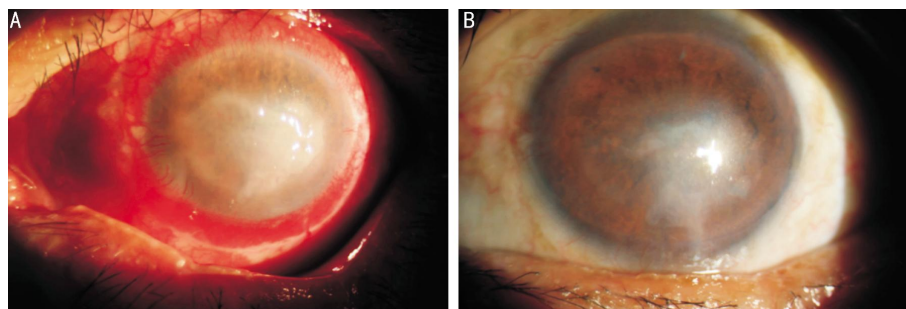


Figure 4 Case 4, male, 59y, 5mo post craniocerebral operation, neurogenic keratitis in left eye A: Pre-treatment anterior segment photograph showing a ulcer of 6×5 mm in diameter, slight stromal opacity in the ulcer; B: Fifty-seven days after drug treatment, the ulcer healed, and the keratoleukoma and neovascular were observed around the limbus.

than the process of repair in the course of the treatment, descemetocoeur or corneal perforation appeared. In the control group, descemetocoeur occurred in two cases, and corneal perforation occurred in one case. At the same time, it

is well known that the vascularization is an important component of chronic inflammation, the longer recovery time observed in the control group, was associated with more neovascularization^[13].

While in the experimental group, the healing time of corneal ulcer only was 1/4 to 1/6 of the control group. More rapid recovery of neurogenic keratitis by bandage contact lens not only avoided complications during the treatment and pain in surgery for patients, but also reduced the economic burden of patients and their families. Despite the use of the same eyedrops in the two groups, the healing time of the corneal ulcer was completely different. The reason for rapid recovery of neurogenic keratitis with bandage contact lens maybe the special characteristics of the bandage contact lens, such as shelter, aquosity, flexibility, comfort and extending the duration of action of the drugs. Firstly, for the shelter characteristic, the lens could protect the surface of cornea and promote repair of the ulcer by acting as a "shield". Secondly, for the characteristics of flexibility, comfort, aquosity and higher oxygen transmission rate, the silicone hydrogel lens could be worn continuously^[11,12]. Therefore, continuous wear could reduce or avoid injury and infection of cornea in the process of removing lens. Thirdly, the bandage contact lens could extend the duration of action of the drugs, so the eyedrops used in experimental group could have a greater effect on the ocular surface^[14].

At the same time, the transparent feature of the bandage contact lens makes the follow-up of corneal lesions more convenient, and avoids the difficulty of the palpebral fissures operation.

The bigger diameter (14 mm) of bandage contact lens ensures it sticks to the cornea and makes it difficult to fall off. The incorrect operation may be the real reason for lens falling off.

More important is that no cases in the experimental group were complicated with bacterial, fungal or acanthamoeba infection during the treatment period^[15-17], which suggested that the bandage soft contact lens is safe^[18-20]. Anti-precipitation technology of bandage contact lens and antibiotics eyedrops may be the reason for preventing infection.

In conclusion, the bandage corneal contact lens is a safe and effective way of treating neurogenic keratitis, and the healing time of corneal ulcer can be significantly shortened.

ACKNOWLEDGEMENTS

Conflicts of Interest: Sun YZ, None; Guo L, None; Zhang FS, None.

REFERENCES

- 1 Semeraro F, Forbice E, Romano V, Angi M, Romano MR, Filippelli ME, Di Iorio R, Costagliola C. Neurotrophic Keratitis. *Ophthalmologica* 2014; 231(4):191-197
- 2 Hamrah P, Cruzat A, Dastjerdi MH, Zheng L, Shahatit BM, Bayhan HA, Dana R, Pavan-Langston D. Corneal sensation and subbasal nerve alterations in patients with herpes simplex keratitis: an in vivo confocal microscopy study. *Ophthalmology* 2010;117(10):1930-1936
- 3 Vantieghem G, Maudgal PC. Neuroparalytic keratopathy as the first sign

- of a cerebral meningioma. *Bull Soc Belge Ophthalmol* 2007;(303):81-86
- 4 Lanigan DT, Romanchuk K, Olson CK. Ophthalmic complications associated with orthognathic surgery. *J Oral Maxillofac Surg* 1993; 51(5): 480-494
- 5 Li XR, Wang W, Yuan JQ. Distribution and morphological changes of corneal nerves in type 2 diabetic patients detected by confocal microscopy. *Zhonghua Yan Ke Za Zhi* 2006;42(10):896-900
- 6 Baratz KH, Nau CB, Winter EJ, McLaren JW, Hodge DO, Herman DC, Bourne WM. Effect of glaucoma medications on corneal endothelium, keratocytes, and subbasal nerves among participants in the ocular hypertension treatment study. *Cornea* 2006;25(9):1046-1052
- 7 Bozkurt B, Irkec M. In vivo laser confocal microscopic findings in patients with epithelial basement membrane dystrophy. *Eur J Ophthalmol* 2009;19(3):348-354
- 8 Bonini S, Lambiase A, Rama P, Caprioglio G, Aloe L. Topical treatment with nerve growth factor for neurotrophic keratitis. *Ophthalmology* 2000; 107(7):1347-1351
- 9 Chen HJ, Pires RT, Tseng SC. Amniotic membrane transplantation for severe neurotrophic corneal ulcers. *Br J Ophthalmol* 2000;84(8):826-833
- 10 Daglioglu MC, Coskun M, Ilhan N, Tuzcu EA, Ilhan O, Keskin U, Ayintap E, Oksuz H. The effects of soft contact lens use on cornea and patient's recovery after autograft pterygium surgery. *Cont Lens Anterior Eye* 2014;37(3):175-177
- 11 Ahad MA, Anandan M, Tah V, Dhingra S, Leyland M. Randomized controlled study of ocular lubrication versus bandage contact lens in the primary treatment of recurrent corneal erosion syndrome. *Cornea* 2013 Aug 22. [Epub ahead of print]
- 12 Plaka A, Grentzelos MA, Astyrakakis NI, Kymionis GD, Pallikaris IG, Plainis S. Efficacy of two silicone- hydrogel contact lenses for bandage use after photorefractive keratectomy. *Cont Lens Anterior Eye* 2013;36 (5): 243-246
- 13 Giménez F, Suryawanshi A, Rouse BT. Pathogenesis of herpes stromal keratitis—a focus on corneal neovascularization. *Prog Retin Eye Res* 2013; 33:1-9
- 14 Shi Y, Lv H, Fu Y, Lu Q, Zhong J, Ma D, Huang Y, Xue W. Preparation and characterization of a hydrogel carrier to deliver gatifloxacin and its application as a therapeutic contact lens for bacterial keratitis therapy. *Biomater* 2013;8(5):055007
- 15 Omali NB, Zhu H, Zhao Z, Willcox MD. Protein deposition and its effect on bacterial adhesion to contact lenses. *Optom Vis Sci* 2013;90 (6): 557-564
- 16 Willcox MD. Microbial adhesion to silicone hydrogel lenses: a review. *Eye Contact Lens* 2013;39(1):61-66
- 17 Pacella E, La Torre G, De Giusti M, Brillante C, Lombardi AM, Smaldone G, Lenzi T, Pacella F. Results of case-control studies support the association between contact lens use and Acanthamoeba keratitis. *Clin Ophthalmol* 2013;7:991-994
- 18 Saini A, Rapuano CJ, Laibson PR, Cohen EJ, Hammersmith KM. Episodes of microbial keratitis with therapeutic silicone hydrogel bandage soft contact lenses. *Eye Contact Lens* 2013;39(5):324-328
- 19 Szczotka-Flynn L, Jiang Y, Raghupathy S, Bielefeld RA, Garvey MT, Jacobs MR, Kern J, Debanne SM. Corneal inflammatory events with daily silicone hydrogel lens wear. *Optom Vis Sci* 2014;91(1):3-12
- 20 Gu X, Jennings JD, Snarr J, Chaudhary V, Pollard JE, Savage PB. Optimization of ceragenins for prevention of bacterial colonization of hydrogel contact lenses. *Invest Ophthalmol Vis Sci* 2013;54(9):6217-6223