

# Long term results of no – alcohol laser epithelial keratomileusis and photorefractive keratectomy for myopia

*Leopoldo Spadea, Francesca Verboschi, Vittoria De Rosa, Mariella Salomone, Enzo Maria Vingolo*

Department of Medico-Surgical Sciences and Biotechnologies, Sapienza University of Rome, Latina 04100, Italy

**Correspondence to:** Leopoldo Spadea. Via Benozzo Gozzoli 34, Rome 00142, Italy. leopoldo.spadea@uniroma1.it

Received: 2014-03-17

Accepted: 2014-10-25

**DOI:10.3980/j.issn.2222-3959.2015.03.25**

Spadea L, Verboschi F, De Rosa V, Salomone M, Vingolo EM. Long term results of no-alcohol laser epithelial keratomileusis and photorefractive keratectomy for myopia. *Int J Ophthalmol* 2015;8 (3):574-579

## Abstract

• **AIM:** To evaluate the long term clinical results of mechanical no –alcohol –assisted laser epithelial keratomileusis (LASEK) versus standard photorefractive keratectomy (PRK) for low-moderate myopia.

• **METHODS:** Twenty-five eyes treated with LASEK and twenty-five eyes treated with PRK were evaluated with a mean follow-up duration of 60mo. Mechanical separation of the epithelium was performed with blunt spatula and without application of alcohol. Laser ablation was performed with the MEL-70 excimer laser. All patients were examined daily until epithelial closure; at 1, 3, 6, and 12mo, and every year subsequently. Main outcome measures were uncorrected distance visual acuity (UDVA), corrected distance visual acuity (CDVA), manifest refraction, haze, efficacy and safety indexes.

• **RESULTS:** Twenty-one eyes and 22 eyes completed follow-up of 60mo in LASEK and PRK group respectively. Manifest refraction at 60mo follow-up was -0.01 and 0.26 in LASEK and PRK group respectively. In the LASEK group mean UDVA and mean CDVA after 60mo were 20/22 and 20/20 respectively ( $P > 0.01$ ). In the PRK group mean UDVA and mean CDVA at 60mo follow-up were 20/20 and 20/20 after 60mo ( $P > 0.01$ ). The efficacy indexes were 0.87 and 0.95, and the safety indexes were 1.25 and 1.4 respectively for LASEK group and PRK group.

• **CONCLUSION:** Both standard PRK and no –alcohol LASEK offer safe and effective correction of low – moderate myopia in the long term without any statistically significant difference between the two groups.

• **KEYWORDS:** alcohol; laser epithelial keratomileusis; myopia; photorefractive keratectomy

## INTRODUCTION

The refractive outcome of laser refractive surgery for myopia has gained a remarkable level of efficacy and a fair degree of safety. Photorefractive keratectomy (PRK) involves the use of an excimer laser to reshape the anterior corneal surface [1]. PRK has been accepted as a reasonably predictable, effective and safe method for the correction of low to high myopia [2]. However, postoperative pain, relatively slow recovery, subepithelial corneal haze and myopic regression are shortcomings of PRK [3]. Laser epithelial keratomileusis (LASEK) is a modified PRK technique introduced by Camellin [4] in 1998 based on the detachment of an epithelial flap after the application of an alcohol solution, and then the repositioning of this flap following laser application. The use of alcohol, a cytotoxic agent, to detach the epithelial cells from the Bowman's membrane is probably a crucial factor in the dampened wound response in LASEK [5]. The alcohol has a multiplicity of toxic effect mechanisms, but the predominant mode of action appears to derive from enzymatic protein coagulation and denaturation. Consequently, the cell function is lost. The exposure of the human cornea to ethanol reduces the number of vital epithelial cells rapidly and increases cell death in a time and dose-dependent manner [6,7]. Usually the corneal epithelium is strongly attached to the stroma and therefore the use of a diluted ethanol solution is necessary to perform an epithelial flap. Nevertheless, in 4.6% of eyes this link is less strong and is possible to perform a no-alcohol LASEK. In this study, we have evaluated the effectiveness and safety of no-alcohol LASEK after long follow-up of 60mo and we have compared the obtained results with no-alcohol standard PRK.

## SUBJECTS AND METHODS

**Subjects** Eyes of myopic patients were included in a prospective case series from 2004 to 2013. Fifty myopic eyes of 40 patients (range age 24-48y) were submitted to

**Table 1 Preoperative data**

Variables	LASEK	PRK	$\bar{x} \pm S$ (range)
Age (a)	37.7±7.0 (27-48)	35.4±6.89 (27-48)	0.27
UDVA	0.125±0.04 (0.10-0.16)	0.1±0.03 (0.10- 0.16)	0.90
CDVA	0.80±0.06 (0.60-1.00)	0.85±0.05 (0.60-1.00)	0.10
SE (D)	-3.87±2.61 (-1.00 to -7.75)	-3.90±2.06 (-1.00 to -6.50)	0.87
Optic zone (mm)	6.83±0.38 (5.97-7.24)	6.92±0.23 (6.12-7.35)	0.20
Ablation depth (µm)	63.7±7.0 (51.3-75.8)	65.1±6.4 (49.8-78.5)	0.96

UDVA: Uncorrected distance visual acuity; CDVA: Corrected distance visual acuity; SE: Spherical equivalent manifest refraction.

preoperative examinations, including slit lamp microscopy, manifest and cycloplegic refractions, corneal topography and keratometry, tonometry, pachymetry, scotopic pupil diameter evaluation and fundus examination. In this study were excluded patients with amblyopia, corneal disease, cataract, glaucoma, retinal disease, active ocular and systemic disease. Patients were stratified in two groups: the first group included 25 eyes of 20 patients (11 males and 9 females), mean age 37.7±7.0y standard deviation (SD) (range 27-48y), treated with no-alcohol LASEK, with a mean myopia -3.87±2.61 diopters (D) SD (range -1.00 to -7.75D); the second group included 25 eyes of 20 patients (13 males and 7 females), mean age 35.4±6.89y SD (range 27-48y), with mean myopia -3.90±2.06D SD(range -1.00 to -6.50D), treated with no-alcohol PRK.

### Methods

**Surgical technique** After topical anesthesia (oxybuprocaine 0.4% ), without using an alcohol solution, the surgical procedures have started for all patients in the same manner, performing a pre-incision of the corneal epithelium to circumscribe the flap area with a marker 9.0 mm diameter; then by using a smooth spatula the epithelium was moved centripetally. In patients with a light adhesion of the epithelium a LASEK procedure was performed, lifting an intact epithelial flap (LASEK group), in those with a strong epithelial adhesion the epithelium was removed (PRK group). In LASEK technique, the epithelium was lifted and an epithelial flap was gently gathered at the 12 o'clock position. At this time we performed the photoablation; the optical zone diameter mean was 6.83±0.38 mm with a transition zone of 1.8 mm. After laser ablation the epithelial flap was repositioned and a soft contact lens was applied to the eye.

In PRK technique, after mechanical deepithelialization the photoablation was performed on a dry cornea. The mean optical zone diameter, corresponding to the diameter intended for the treatment area, was 6.92±0.23 mm SD with a transition zone of 1.8 mm.

In both groups after the photoablation, a soft contact lens was applied and topical antibiotic (ofloxacin 3%) and artificial tears were given until the epithelial healing was complete. Topical corticosteroid (butyrate clobetasone 0.1%) drops were administrated for at least 1mo, then the drops were

tapered and titrated depending on the corneal haze and refractive outcome. In all patients the soft contact lens was removed after 5d post refractive surgery.

All eyes were examined daily until epithelial closure at 1, 3, 6, 12mo and every year subsequently. Main outcome measures were uncorrected distance visual acuity (UDVA), corrected distance visual acuity (CDVA), manifest refraction, haze, efficacy and safety indexes.

**Laser treatment** An active eye-tracking system, oriented to an iron ring put on the limbus, constantly monitored the central position of the treatment. It was used for these techniques a MEL-70 excimer laser (Carl Zeiss, Meditec, Jena, Germany) setted at 193 nm, 35 Hz frequency and 180 mJ/cm<sup>2</sup> fluency with a 0.25 µm ablation rate. The laser uses a 1.8 mm diameter flying spot with a Gaussian profile. A cone for controlled atmosphere has been added to the laser to extract smoke or particles in the air without creating a draft, removing all obstacles on the path to the laser beam.

**Statistical Analysis** Data was entered into an Excel spreadsheet (Microsoft, Redmond, WA, USA), which was also used for analysis; *P* values less than 0.01 were considered statistically significant.

### RESULTS

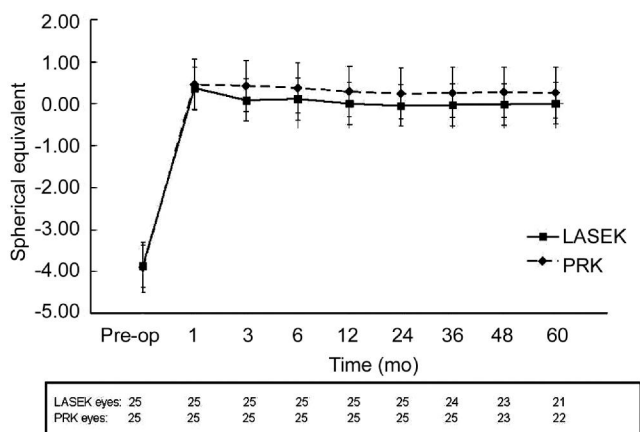
There were no significant statistical differences between the two groups in age, UDVA, CDVA, myopia, optic zone and ablation depth (Table 1). After 60mo follow-up, there were no significant differences between two groups in mean epithelial healing time, discomfort after 1d postoperative (by using a verbal descriptor scale), the presence of haze (always <1 in a 0-5 scale). No serious or vision-threatening complications were noted in both groups.

Twenty-one eyes completed follow-up of 60mo in the LASEK group; one eye was lost at 36mo and two eyes were lost at 48 eyes. While in the PRK group twenty-three eyes completed follow-up of 48mo and twenty-two eyes completed follow-up of 60mo.

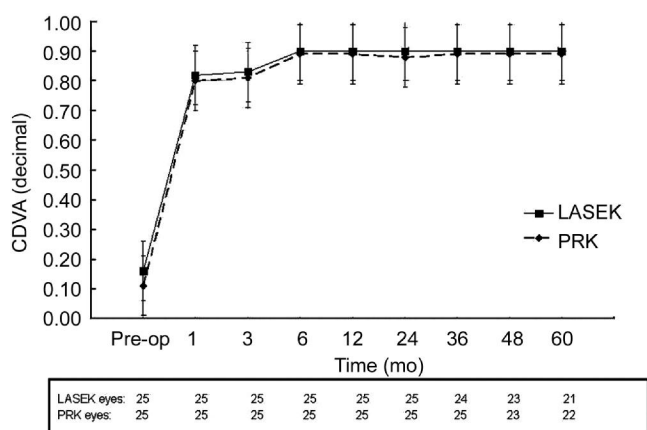
Manifest refraction results are summarized in Figure 1. There was no statistically significant difference between LASEK and PRK group (Table 2). No statistically significant difference was shown in the postoperative UDVA (*P*=0.36; Figure 2) and CDVA (*P*=0.78) between the two groups (Figure 3) and these results were unchanged after 60mo follow-up.

**Table 2 Postoperative data**

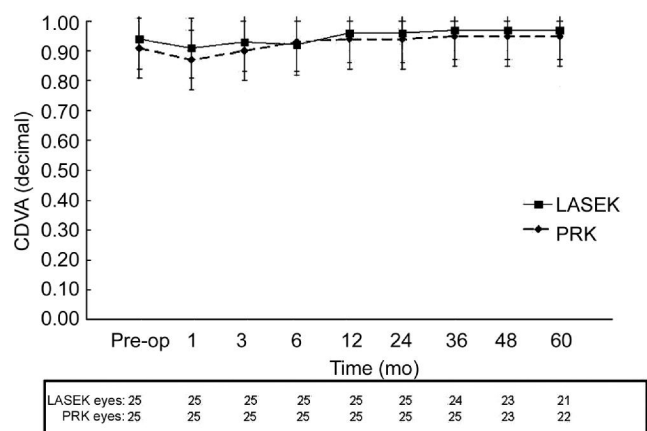
Variables	LASEK	PRK	$\bar{x} \pm s$
Epithelial healing time (d)	5.04 ± 2.31(2.71-7.37)	5.49 ± 2.25 (3.04-7.45)	0.13
Number of discomfort after 1d (%)	14 (56)	12 (60)	0.43
Haze of eye ≤ 1 (0-5) (%)	2 (11.1)	3 (14.3)	0.25



**Figure 1 Manifest refraction preoperatively and at each postoperative visit after no-alcohol LASEK vs PRK.**



**Figure 2 UDVA preoperatively and at each postoperative visit after no-alcohol LASEK vs PRK.**



**Figure 3 CDVA preoperatively and at each postoperative visit after no-alcohol LASEK vs PRK.**

73% (16 eyes) in the PRK group, ±1.0 D in 90% (19 eyes) in the LASEK group and 91% (20 eyes) in the PRK group, and ±2.0 D in 100% in both groups, without any statistically significant difference. The efficacy indexes were 0.87 for LASEK and 0.95 for PRK, and the safety indexes were 1.25 for LASEK and 1.4 for PRK. Analyzing these last couple data revealed no statistically significant change ( $P > 0.01$ ).

**DISCUSSION**

In the present study we evaluated the long term follow-up of PRK and LASEK without alcohol for low-moderate myopia. The PRK procedure is commonly used to correct myopia and astigmatism. PRK involves the use of an excimer laser to reshape the anterior corneal surface [1]. The excimer laser alters the refractive state of the eye by removing tissue from the anterior cornea through a process known as photoablative decomposition. This process uses ultraviolet energy from the excimer laser to disrupt chemical bonds in the cornea without causing any thermal damage to surrounding tissue [8].

The popularity of LASEK has been gaining momentum among refractive ophthalmologists after a few clinical series showed that LASEK might have significant clinical advantages over PRK [9]. Atrata and Rehurek [10] compared the clinical results (efficacy, safety, stability, and postoperative pain or discomfort) of LASEK and conventional PRK for the correction of low to moderate myopia and they showed that there were no statistically significant differences in the safety and efficacy indices at 2y. Lee *et al* [11] learned that LASEK-treated eyes had less significant postoperative pain and corneal haze than PRK-treated eyes in the early postoperative period. LASEK consists on the detachment of an epithelial flap after the application of an alcohol solution, and then the repositioning of this flap following laser application. From the viewpoint of the decreased corneal haze after LASEK, although the details of underlying cellular events remain unclear, we speculate that if an epithelial flap is made, it becomes loose and lengthens enough to cover the cut epithelial border. It seals up the bare stroma. That prevents the release of cytokines and growth factors from the stroma and damaged epithelium, which decreases the initial inflammatory damage to the stroma. This may reduce the apoptosis of anterior stromal keratocytes and subsequent replenishment with activated keratocytes, later decreasing the synthesis of collagens [12].

After 5y of follow-up, the mean refraction of within ±0.5 D was measured in 71% (15 eyes) in the LASEK group and in

Ethanol was initially used in refractive surgery to assist in the removal of the epithelium before PRK and has been shown to enhance corneal flap lifting without significant loss of flap viability [13,14]. Alcohol acts on the corneal epithelium-basement membrane complex by splitting the epithelial basement membrane without affecting the anchoring of the basement membrane to the underlying Bowman's layer [15]. However, alcohol is known to be cytotoxic among a multiplicity of toxic effect mechanisms, the predominant mode of action appears to derive from protein coagulation/denaturation, which takes place at the cell membrane and among the various plasma proteins [16]. Coagulation of enzymatic proteins leads to the loss of cell functions [17]. Hence, caution is required when applying alcohol to the cornea. Removal of the corneal epithelium before PRK with 18% or 20% ethanol left for 20 to 40s is safe to the underlying corneal stroma and is an effective alternative to scraping (*i.e.* mechanical debridement) [18,19]. Even an exposure time of 3min with 25% alcohol appears safe, effective, and predictable without stromal dehydration or toxic effects and is not associated with significant loss of CDVA after PRK [20]. However, higher alcohol concentrations such as 50% and 100% ethanol can lead to substantial damage to the underlying stroma [21,22].

Soma *et al* [23] evaluated the effect of mechanical epithelial separation with an epikeratome on the histologic ultrastructure of epithelial flaps and stromal beds from human corneas. He showed that on scanning electron microscopy, the cleavage planes of epithelial flaps and stromal beds were relatively smooth; on transmission electron microscopy, epithelial flaps were separated partially within the lamina fibroreticularis and partially within the lamina lucida; immunofluorescence showed positive staining for type VII collagen and discontinuous staining for type IV collagen in stromal beds. Discontinuous linear staining for types IV and VII collagens was observed in epithelial flaps. Staining for integrins alpha 6 and beta 4 was positive in some regions and discontinuous in other regions of epithelial flaps. In stromal beds, integrins alpha 6 and beta 4 had a patchy expression pattern. Staining for laminin 5 was intermittently positive along the basal side of epithelial flaps and stromal beds. In 1995 we examined four human corneas that had undergone one PRK and subsequent penetrating keratoplasty by means of light and electron microscopy in an attempt to detect possible causes for complications after PRK and despite recovery of a continuous epithelial layer as early as 3d after PRK, abnormalities of both epithelium and superficial stroma could be detected in all specimens, including the one obtained 13mo after the refractive procedure were observed [24]. Cui

*et al* [25] using immunohistochemical staining and Western blot analysis, observed and compared the accurate dynamic changes of type I, III, V, VI collagen in the wound healing processes of the rabbit cornea which underwent LASEK or PRK to investigate the possible mechanism of corneal haze and myopic regression. They showed that after LASEK, the corneal wound healing with type I and III collagen were much faster than PRK, and the wound response was also much weaker. Whereas for type V and VI collagen, their dynamic changes were resemble between LASEK and PRK, they both reached the peak value after 3mo since the surgery, but LASEK group returned to normal earlier than PRK. The value of these two types of collagen after PRK were higher than LASEK. The changes of these four types of collagen may offer us at least partial explanation for the difference between forming between corneal haze and refractive regression. These results meant that there were significant differences between LASEK and PRK on type I, III, V and VI collagens or the time of reacting, reaching an apex and returning to normal. LASEK had slighter intensity of reaction and there is an excessive aggregation of collagens after PRK that it may be the histological foundation of obvious haze and myopic regression. Zhou *et al* [26] evaluated short-term corneal endothelial changes after LASEK and they documented that acute endothelial changes occur on specular microscopic examination after LASEK. When taken as a whole, LASEK-treated eyes had a significant increase in postoperative coefficient of variation (CV) of cell size and a significant decrease in endothelial cell density (ECD) and cell hexagonality at 15min postoperatively. These findings indicate that, immediately after LASEK, the number of cells/mm<sup>2</sup> decreases and the endothelial cells became much more swollen compared with their preoperative size. But these changes were transient; ECD and variations in cell area returned to near baseline (preoperative) levels by 1d postoperatively. An increased CV of cell size would be expected if there was a decrease in the percentage of hexagonal cells, as observed by Zhou *et al* [26]. The percentage of hexagonal cells also returned to near the baseline (preoperative) level by 1wk postoperatively, suggesting that endothelial cell function recovered 1wk after LASEK. Studies that have evaluated the endothelium after PRK have reported little or no endothelial change, with no clinically significant decrease in central ECD [27,28].

The vitality of the epithelial flap is probably a crucial factor in the dampened wound response in LASEK versus PRK. Gabler *et al* [5] investigated the vitality of the corneal epithelium after exposure to 20% ethanol during LASEK and they demonstrated that after 15 and 30s of exposure to 20%

ethanol, the epithelium is intact and most corneal epithelial cells are alive. They also recommend 20 to 30s exposure to 20% alcohol (ethanol) for LASEK. At 30s, they found predominantly vital epithelial cells, whereas after 45s, the fraction of dead cells increased substantially to about 50%. Predominantly dead epithelial cells are seen after 60 and 120s of exposure. There might have been an overestimation of the fraction of dead cells because of the time between the donor's death and the beginning of the study. However, their experiments confirmed that after exposure of the cornea to 20% ethanol for up to 30s, the epithelial flap contained predominantly vital cells, which is probably one of the crucial factors in the dampened flap contained predominantly vital cells, which is probably one of the crucial factors in the dampened wound response in LASEK compared to that in PRK. The exposure of the human cornea to ethanol reduces the number of vital epithelial cells rapidly and increases cell death in a dose- and time-dependent manner [6]. Chen *et al* [7] studied the effect of dilute alcohol on human corneal epithelial cell morphology and viability with electron microscopy and they showed that the conventional concentrations and duration of alcohol treatment (20%, 25s) resulted in varying morphological changes in the basement membrane zone by electron microscopy and varying viability in standard tissue culture conditions. Their electron microscopic findings showed morphological differences in the plane of cleavage among several patients, in whom the same technique was used for creating the epithelial flap. This may be due to variability between individuals in relation to the adhesion of the epithelium to the basal membrane or to the variability of the effect of alcohol on adhesion of epithelial cells. Electron microscopy showed varying degrees of basement membrane alterations after alcohol application, including disruptions, discontinuities, irregularities and duplication. Cellular destruction and vacuolization of basal epithelial cells associated with absent basement membrane were also observed. Their studies in vitro suggest a time and dose-dependent effect of alcohol on epithelial cells. The 25% concentration of ethanol was the inflection point of epithelial survival. Significant increase in cellular death occurred after 35s of ethanol exposure. Forty seconds of exposure further increased apoptosis after 8h of incubation. These findings are consistent with the clinical observations of varied epithelial attachment to the stromal bed after LASEK surgery. Then they demonstrated that alcohol diluted in keratinocyte serum-free medium (KSFM) had no effect on cellular survival and apoptosis. At this time, it is not clear whether modification of the preparation of dilute alcohol, used during LASEK and PRK, would allow for better cell survival and

adhesion *in vivo*. The dilution of alcohol in balanced salt solution (BSS), physiologic solution, or sterile water, thus obtaining different osmolarities, is an area of active debate but none of the LASEK studies has shown a definite advantage of a specific formulation. Camellin strongly points out the importance of a hypotonic solution obtained by diluting alcohol in distilled water for facilitating epithelial detachment [9].

Yuksel *et al* [29] evaluated clinical and confocal results of alcohol-assisted LASEK for correction of myopia in twenty-two eyes with a mean follow-up duration of 45mo and they showed that LASEK offered safe and effective correction of myopia in the long term. In a retrospective study the stability of visual acuity and refraction, the predictability, corneal keratometry, safety, efficacy, and postoperative complications after 10y after excimer laser surface ablation performed on thin corneas were evaluated. It was demonstrated that surface ablation seems to be safe and effective to correct myopia in corneas thinner than 500  $\mu\text{m}$ , with stable visual and refractive outcomes [30].

In conclusion in the present long term study, LASEK with mechanical deepithelialization without the use of alcohol solution was a safe and effective technique to correct low to medium myopia, without any statistically significant difference from mechanical standard PRK.

#### ACKNOWLEDGEMENTS

**Conflicts of Interest:** Spadea L, None; Verboschi F, None; De Rosa V, None; Salomone M, None; Vingolo EM, None.

#### REFERENCES

- 1 Trokel SL, Srinivasan R, Braren B. Excimer laser surgery of the cornea. *Am J Ophthalmol* 1983;96(6):710-715
- 2 Spadea L, Colucci S, Bianco G, Balestrazzi E. Long-term results of excimer laser photorefractive keratectomy in high myopia: a preliminary report. *Ophthalm Surg Lasers* 1998;29(6):490-496
- 3 Wang Z, Chen J, Yang B. Comparison of laser in situ keratomileusis and photorefractive keratectomy to correct myopia from 1.25 to 6.00 diopters. *J Refract Surg* 1997;13(6):528-34
- 4 Camellin M. LASEK: nuova tecnica di chirurgia rifrattiva mediante laser ad eccimeri. *Viscochirurgia* 1998;39-43
- 5 Gabler B, Winkler von Mohrenfels C, Dreiss AK, Marshall J, Lohmann CP. Vitality of epithelial cells after alcohol exposure during laser assisted subepithelial keratectomy flap preparation. *J Cataract Refract Surg* 2002; 28(10):1841-1846
- 6 Sandwig KU, Kravik K, Haaskjold E, Blika S. Laser epithelial wound healing of the rat cornea after excimer laser ablation. *Acta Ophthalmol Scand* 1997;75(2):115-119
- 7 Chen CC, Chang JH, Lee JB, Javier J, Azar DT. Human corneal epithelial cell viability and morphology after dilute alcohol exposure. *Invest Ophthalmol Vis Sci* 2002;43(8):2593-2602
- 8 Manche EE, Carr JD, Haw WW, Hersh PS. Excimer laser refractive

- surgery. *West J Med* 1998;169(1):30-38
- 9 Camellin M. Laser epithelial keratomileusis for myopia. *J Refract Surg* 2003;19(6):666-670
- 10 Atrata R, Rehurek J. Laser-assisted subepithelial keratectomy for myopia: two-year follow-up. *J Cataract Refract Surg* 2003;29(4):661-668
- 11 Lee JB, Choe CM, Seong GJ, Gong HY, Kim EK. Laser Subepithelial Keratomileusis for low to moderate myopia: 6-month follow-up. *Jpn J Ophthalmol* 2002;46(3):299-304
- 12 Wilson SE. Keratocyte apoptosis in refractive surgery. *CLAO J* 1998;24(3):181-185
- 13 Abad JC, Talamo JH, Vidaurri-Leal J, Cantu-Charles C, Helena MC. Dilute ethanol versus mechanical debridement before photorefractive keratectomy. *J Cataract Refract Surg* 1996;22(10):1427-1433
- 14 Abad JC, An B, Power WJ, Foster CS, Azar DT, Talamo JH. A prospective evaluation of alcohol-assisted versus mechanical epithelial removal before photorefractive keratectomy. *Ophthalmology* 1997;104(10):1566-1574
- 15 Espana EM, Grueterich M, Mateo A, Romano AC, Yee SB, Yee RW, Tseng SC. Cleavage of corneal basement membrane components by ethanol exposure in laser-assisted subepithelial keratectomy. *J Cataract Refract Surg* 2003;29(6):1192-1197
- 16 Kamm O. The prediction of the physiological action of alcohols. *Science* 1921;15;54(1385):55
- 17 Sobernheim G. Alkohol als Desinfektionsmittel. *Schweiz Med Wochenschr* 1947; 77(46):1211-1213
- 18 Carones F, Fiore T, Brancato R. Mechanical vs alcohol epithelial removal during photorefractive keratectomy. *J Refract Surg* 1999;15(5):556-562
- 19 Shah S, Doyle SJ, Chatterjee A, Williams BE, Ilango B. Comparison of 18% ethanol and mechanical debridement for epithelial removal before photorefractive keratectomy. *J Refract Surg* 1998;14(2 Suppl):S212-S214
- 20 Stein HA, Stein RM, Price C, Salim GA. Alcohol removal of the epithelium for excimer laser ablation: outcomes analysis. *J Cataract Refract Surg* 1997;23(8):1160-1163
- 21 Helena MC, Filatov V, Johnston WT, Vidaurri-Leal J, Wilson SE, Talamo JH. Effects of 50% ethanol and mechanical epithelial debridement on corneal structure before and after excimer photorefractive keratectomy. *Cornea* 1997;16(5):571-579
- 22 Campos M, Raman S, Lee M, McDonnell PJ. Keratocyte loss after different methods of de-epithelialization. *Ophthalmology* 1994;101(5):890-894
- 23 Soma T, Nishida K, Yamato M, Kosaka S, Yang J, Hayashi R, Sugiyama H, Maeda N, Okano T, Tano Y. Histological evaluation of mechanical epithelial separation in epithelial laser *in situ* keratomileusis. *J Cataract Refract Surg* 2009;35(7):1251-1259
- 24 Balestrazzi E, De Molfetta V, Spadea L, Vinciguerra P, Palmieri G, Santeusano G, Spagnoli L. Histological, immunohistochemical, and ultrastructural findings in human corneas after photorefractive keratectomy. *J Refr. Surg* 1995;11(3):181-187
- 25 Cui X, Bai J, He X, Zhang Y. Western Blot analysis of type I, III, V, VI collagen after laser epithelial keratomileusis and photorefractive keratectomy in cornea of rabbits. *Yan Ke Xue Bao* 2005;21(4):141-148
- 26 Zhou J, Lu S, Dai J, Yu Z, Zhou H, Zhou X. Short-Term Corneal endothelial changes after laser-assisted subepithelial keratectomy. *J Intern Med Res* 2010;38(4):1484-1490
- 27 Stulting RD, Thompson KP, Waring GO 3<sup>rd</sup>, Lynn M. The effect of photorefractive keratectomy on the corneal endothelium. *Ophthalmology* 1996;103:1357-1365
- 28 Spadea L, Dragani T, Blasi MA, Mastrofini MC, Balestrazzi E. Specular microscopy of the corneal endothelium after excimer laser photorefractive keratectomy. *J Cataract Refract Surg* 1996;22(2):188-193
- 29 Yuksel N, Bilgihan K, Hondur AM, Yildiz B, Yuksel E. Long term results of Epi-LASIK and LASEK for myopia. *Cont Lens Anterior Eye* 2014;37(3):132-135
- 30 De Benito-Llopis L, Alió JL, Ortiz D, Teus MA, Artola A. Ten-year follow-up of excimer laser surface ablation for myopia in thin corneas. *Am J Ophthalmol* 2009;147(5):768-773