

Comparative clinical study of conjunctival toxicities of newer generation fluoroquinolones without the influence of preservatives

Han Sang Park¹, Jun Hun Lee², Hong Kyun Kim²

¹Nune Eye Hospital, Daegu 705-817, Korea

²Department of Ophthalmology, Kyungpook National University, School of Medicine, Daegu 700-721, Korea

Correspondence to: Hong Kyun Kim. Department of Ophthalmology, Kyungpook National University Hospital 50 Samduk-2Ga, Jung-Gu, Daegu 700-721, Korea. okeye@knu.ac.kr

Received: 2014-06-05

Accepted: 2014-10-11

Abstract

• **AIM:** To compare the conjunctival epithelial toxicities of three newer -generation fluoroquinolones without preservatives.

• **METHODS:** In a prospective, randomized, double blind comparative study, 47 eyes of 47 patients with a primary pterygium were enrolled, and divided randomly into three groups (levofloxacin 0.5% , gatifloxacin 0.3% , and moxifloxacin 0.5%). After pterygium surgery with the same conjunctival autograft technique, each patient maintained a regimen with a randomly assigned fluoroquinolone eye drop. Patients were examined every other day after surgery until the epithelium had completely healed. Photos were taken and used to measure the area of residual epithelial defects. Conjunctival healing time and speed (initial defect area/healing time (mm²/d) compared in each group using Kruskal–Wallis tests.

• **RESULTS:** There were no significant differences in mean age, gender, and conjunctival defect size of the donor site between these groups. However, the mean of conjunctival healing time and speed were statistically different in each group. The mean of conjunctival epithelial healing time was 8.93 ±2.69d (levofloxacin group), 10.31±2.96d (gatifloxacin group), and 13.50±4.10d (moxifloxacin group), *P*=0.006. The mean conjunctival epithelial healing speed was 6.18±1.39 mm²/d (levofloxacin group), 5.52±1.68 mm²/d (gatifloxacin group), and 4.40±1.30 mm²/d (moxifloxacin group), *P* =0.003.

• **CONCLUSION:** Without the influence of preservatives, levofloxacin and gatifloxacin might be less toxic to the regeneration of conjunctival epithelial cells and cause a faster conjunctival wound healing relative to moxifloxacin.

• **KEYWORDS:** conjunctival epithelial toxicity; fluoroquinolone; preservatives; pterygium

DOI:10.3980/j.issn.2222-3959.2015.06.26

Park HS, Lee JH, Kim HK. Comparative clinical study of conjunctival toxicities of newer generation fluoroquinolones without the influence of preservatives. *Int J Ophthalmol* 2015;8(6):1220–1223

INTRODUCTION

In the selection of specific antibiotics, drug toxicity is also an important factor for consideration, as are many characteristics of antibiotics such as antimicrobial potency and penetration into the targeted tissues. Among the variety of antibacterial drugs, topical fluoroquinolones, which inhibit bacterial DNA gyrase (topoisomerase II) and topoisomerase IV, are most commonly used as a primary drug in various ocular infections. However, these inhibitory effects on bacterial DNA may affect the regeneration of ocular epithelial cells, thus delaying the healing process [1]. Because topical antibiotics are often used for the treatment of the compromised ocular surface such as keratitis, dry eye, or injured eye, the drug toxicity on ocular surface should be considered.

Many of commercially available topical antibiotics contain preservatives. Preservatives, such as benzalkonium chloride (BAK) have been recognized as a major toxic factor for topical drugs [2]. The ocular surface toxicities of newer-generation fluoroquinolones (levofloxacin, gatifloxaicn, moxifloxacin) have also been evaluated in previous studies. Some of these studies have come to conflicting conclusions when comparing the surface toxicities of fluoroquinolones on ocular surface. Burka *et al* [3] evaluated the corneal reepithelialization of 35 patients who received gatifloxacin 0.3% (Zymar, Allergan, Irvine, USA) in one eye and moxifloxacin 0.5% (Vigamox, Alcon, Fort Worth, USA) in the fellow eye after photorefractive keratectomy (PRK) with a 9.0 mm epithelial defect; they concluded that moxifloxacin-treated eyes healed more quickly and had smaller defects on the same postoperative day than those treated with gatifloxacin. On the contrary, in the study of patients who underwent penetrating keratoplasty (PKP), 0.5% moxifloxacin evidenced a significant delay as

compared with 0.3% gatifloxacin in corneal reepithelialization^[4]. In the studies, there were some differences in the content of preservatives between the commercially available drugs; the commercially available moxifloxacin used in their studies had no preservatives, while the other fluoroquinolones contained BAK as a preservative. Thus, neither the epithelial toxicity nor the effects on wound reepithelialization of the drugs themselves could not be accurately compared among one another, because BAK itself is toxic to corneal and conjunctival epithelial cells and delays wound healing^[2,5,6]. The conclusions of the studies have suffered from some critical limitations for making comparisons of the toxicity of each fluoroquinolone substance itself rather problematic. To overcome the critical limitations for the evaluation of the epithelial toxicity each of the newer-generation fluoroquinolones without preservatives, we conducted a prospective, double-blind, randomized clinical trial with preservative free fluoroquinolones in the patients who underwent primary pterygium excision with a conjunctival autograft. We compared the conjunctival epithelial healing rate on donor sites in each of the fluoroquinolone-treated groups.

SUBJECTS AND METHODS

This prospective, randomized, double-blind, comparative study was conducted at the Kyungpook National University Hospital (Daegu, Korea) from May 2009 to December 2011, and the study protocols were all approved by the Institutional Review Board (IRB) of the Kyungpook National University Hospital and followed the tenets of the Declaration of Helsinki. All subjects in this study were scheduled for a primary pterygium surgery *via* the conjunctival autograft technique, and fell within an age range of 18-70y. Written informed consent was obtained from all patients after a thorough explanation of this study. Subjects who had traumatic or secondary pseudopterygium, recurrent pterygium, nasolacrimal drainage malfunction, history of evidence of significant ocular surface disease, any types of infection or inflammation, active blepharitis, hypersensitivity to fluoroquinolones, tendency to delayed epithelial healing such as diabetes, autoimmune diseases (especially rheumatoid arthritis), those in an immunocompromised state, and pregnant women or those planning to bear a child were excluded from this study, as were those who were taking any other topical antibiotic ophthalmic medications. We also excluded patients who had experienced a severe conjunctival inflammation or granulation during the healing time, because postoperative uncontrolled inflammation can delay conjunctival healing. All pterygium excision surgeries with a conjunctival autograft were performed by a single surgeon (Kim HK).

All patients were assigned randomly to three groups and received the assigned fluoroquinolones among the following:

levofloxacin 0.5% (Cravit; Santen, Osaka, Japan), gatifloxacin 0.3% (Gatiflo; Handok, Seoul, Korea), and moxifloxacin 0.5% (Vigamox; Alcon, Fort Worth, Texas, USA). All of these antibiotics do not contain any preservatives in their preparations. One hour before the operation, the patients received a solution containing 0.1% epinephrine, proparacaine, and the assigned fluoroquinolone at 20min interval. After a subconjunctival injection of 2% lidocaine into the body of the pterygium, all abnormal pterygium tissues were removed from the scleral and corneal surface, and subconjunctival fibrous tissues were resected in an area slightly larger than the pterygium body itself. For the conjunctival autografts, a free conjunctival graft of a size similar to the conjunctival defect area was harvested from the underlying tendon at the superotemporal bulbar conjunctiva. The graft was transplanted into the defect area on the bare sclera by multiple interrupted 10-0 nylon sutures. The epithelial defect at the donor conjunctival site was left exposed and regularly examined to evaluate the natural healing process.

After surgery, each of the subjects maintained a regimen of the preoperatively-used antibiotic eye drop four times daily until the conjunctival epithelial defect at the donor site had healed completely. Additionally, all patients were treated with a topical nonpreserved 1% methylprednisolone solution four times daily for two weeks, which was prepared by diluting intravenous methylprednisolone with sterile normal saline solution, and nonpreserved artificial tears (Hyalein Mini ophthalmic solution 0.1%; Santen, Osaka, Japan) were used every two hours for the first 72h, and then four times daily. The conjunctival wound was examined every other day until the donor epithelial defect was almost completely healed. Thereafter, the wound was examined daily to determine the exact day that healing was complete. At every visit, abnormal infection or inflammation was assessed in the donor area and attached conjunctival graft via slit-lamp examination. All patients were followed-up for at least 3mo to evaluate pterygium recurrence.

On every follow-up, slit-lamp photographs of the conjunctival donor area was taken with a cobalt blue filter after staining with fluorescein paper strips. With the digital photographs, the fluorescein-stained nonepithelialized donor area and the epithelial healing rate were evaluated. We employed the Adobe Photoshop program (CS4, Adobe Systems Incorporated, California, USA) and the Image J program (version 1.42, <http://rsbweb.nih.gov/ij/>: open source, public domain software) in the calculation of the dimension of the nonepithelialized area on the digital photographs. The border of total epithelial defect area in each patient was drawn with the Photoshop program and the dimension of total defect area was obtained with the Image J program (Figure 1).

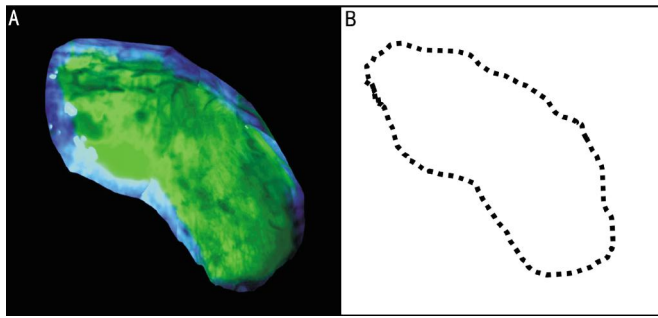


Figure 1 Measurement of epithelial defect area A: Slit-lamp photograph of a patient in the levofloxacin group showing the conjunctival donor defect area with fluorescein stain on postoperative day 1, which was made by combining with several images, because the large conjunctival epithelial defect area could not be taken in a single photograph. B: Draw of line that indicated the conjunctival donor defect area on postoperative day 1 using the image program.

The conjunctival epithelial healing speed in each patient was calculated by dividing the initial defect size on the donor site at the first postoperative day by the postoperative day at which conjunctival healing was complete. The donor defect area was measured by 2 masked evaluators (Park HS, Kim HK). All analyses were conducted using SPSS for Windows (version 17.0 SPSS, Inc.). A *P* value of less than 0.05 was regarded as statistically significant. Background demographic data such as gender and age were compared *via* Chi-square analyses and Kruskal-Wallis tests. The size of the conjunctival donor defect, the epithelial healing speed, and the day of complete healing were analyzed via Kruskal-Wallis tests. The *post hoc* analyses were conducted using nonparametric Mann-Whitney *U* test with Bonferroni's correction.

RESULTS

Forty-seven eyes of 47 patients with primary pterygium were enrolled in this study and were divided into three groups (levofloxacin group: 15 eyes, gatifloxacin group: 16 eyes, moxifloxacin group: 16 eyes). No significant differences in the mean age and gender were observed between these groups. In the levofloxacin group, the patients included 9 males and 6 females, in the gatifloxacin group, 10 males and 6 females, and in the moxifloxacin group, 9 males and 7 females. The mean age of the levofloxacin group was 60.67±10.92y, that of the gatifloxacin group was 61.75±6.17y, and that of the moxifloxacin group was 56.31±11.57y, *P*=0.384 (Kruskal-Wallis test). There were no cases of severe, uncontrolled conjunctival inflammation, infection, and granulation, and no adverse reaction to the topical fluoroquinolones used herein. No cases of re-proliferation of pterygial tissue were detected during the follow-up period.

The initial conjunctival defect size of the donor site was 54.00±15.87-mm² in the levofloxacin group, 54.56±16.64-mm² in the gatifloxacin group, and 56.66 ±15.79-mm² in the

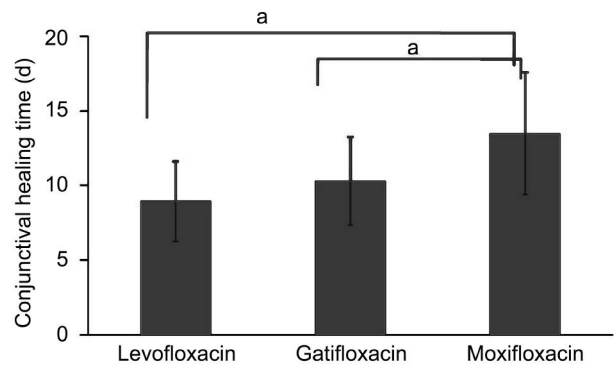


Figure 2 Comparison of conjunctival epithelial healing time
^aStatistically significant differences between two groups.

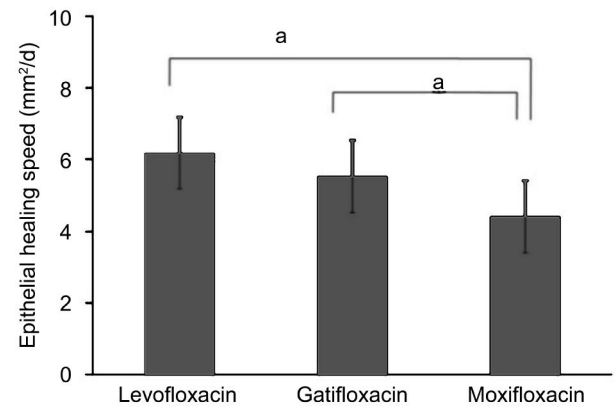


Figure 3 Comparison of conjunctival epithelial healing speed
^aStatistically significant differences between two groups.

moxifloxacin group; these results were not statistically significant (*P*=0.832). The postoperative day of complete conjunctival healing was 8.93±2.69d (range: 5-15d) in the levofloxacin group, 10.31 ±2.96d (range: 6-15d) in the gatifloxacin group, and 13.50±4.10d (range: 7-19d) in the moxifloxacin group, and these results showed significantly statistical differences among the 3 groups according to the results of the Kruskal-Wallis test (*P*=0.011). In the *post hoc* test, no statistical significance was noted between the levofloxacin and the gatifloxacin group (*P*=0.202), but a statistically significant difference was noted between the moxifloxacin group and the other fluoroquinolones (*P*=0.003 with the levofloxacin group and *P*=0.019 with the gatifloxacin group; Figure 2).

The conjunctival healing speed was 6.18±1.39 mm²/d (range: 3.49-8.13) in the levofloxacin group, 5.52±1.68 mm²/d (range: 2.14-9.65) in the gatifloxacin group, and 4.40±1.30 mm²/d (range: 2.58-7.65) in the moxifloxacin group, and statistical significance was noted between the three groups by a Kruskal-Wallis test (*P*=0.003). In the *post hoc* test, no statistical significance was noted between the levofloxacin and the gatifloxacin group (*P*=0.188), but a statistically significant difference was noted between the moxifloxacin group and the other fluoroquinolones (*P*=0.001 with the levofloxacin group and *P*=0.017 with the gatifloxacin group; Figure 3).

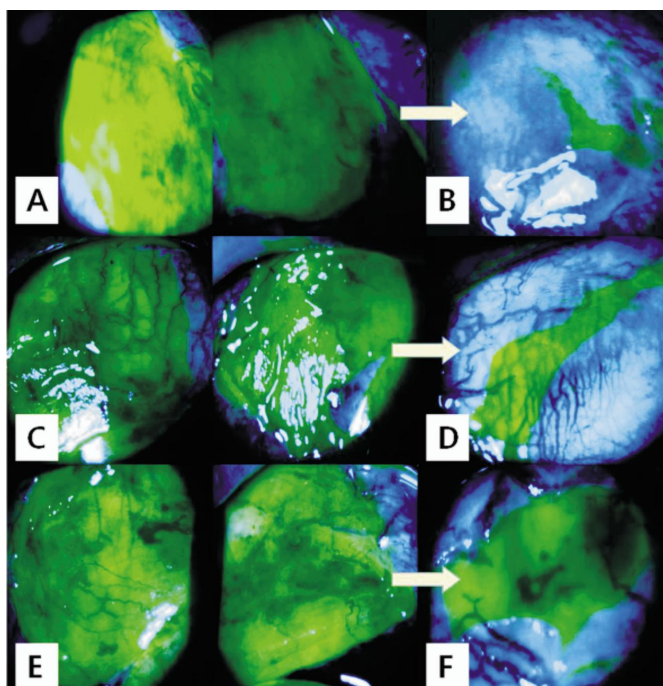


Figure 4 Slit-lamp photograph showing conjunctival donor defect area of patient in three groups on postoperative day 1 and day 5 A, Postoperative day 1 and B, day 5 in the levofloxacin group. C, Postoperative day 1 and D, day 5 in the gatifloxacin group. E, Postoperative day 1 and F, day 5 in the moxifloxacin group.

DISCUSSION

According to our statistical results, the moxifloxacin group evidenced slower reepithelialization of conjunctival epithelial defects on the donor site than was observed in the levofloxacin ($P=0.003$) and gatifloxacin groups ($P=0.019$) (Figure 4). This result can be explained with following two reasons: different inhibitory effects on mammalian topoisomerase II and different drug penetrations of fluoroquinolones. Kim *et al*^[7] suggested that moxifloxacin was more toxic than levofloxacin ($P<0.05$). Moreover, moxifloxacin inhibited the effect of wound healing in HCEC injury, but levofloxacin did not ($P<0.05$). Moxifloxacin was also shown to evidence significantly greater penetration into normal and abnormal conjunctival tissues than the other fluoroquinolones, and thus are found at higher concentrations in the conjunctival tissues. These higher concentrations may provide greater efficacy in eliminating bacteria, but might also increase ocular toxicity owing to an abundance of fluoroquinolone, which could delay reepithelialization^[8-11]. These findings are consistent with the result of the present study, which focused on conjunctival epithelial cells. The ocular surface toxicities of topical antibiotics depend on its potency, tissue penetration, drug concentration and accompanied preservatives. When we compare the toxicity of antibiotics on ocular surface, we should consider all of the factors. Because this study is a clinical trial, we could not control the characteristics of the drug and concentration except the presence of preservatives. Herein, we could not

decide and compare the absolute toxicity of antibiotics itself. This is inevitable limitation of this study. However, the result will be helpful for the clinical selection along with patients' ocular surface status.

Conclusively, in the absence of the influence of preservatives, levofloxacin and gatifloxacin evidenced similar rates of conjunctival reepithelialization, and moxifloxacin evidenced the slowest reepithelialization of the donor conjunctival defect. In other words, moxifloxacin might be more toxic to the regeneration of conjunctival epithelial cells and might cause greater delays in the process of conjunctival wound healing than the other fluoroquinolone substances. In the treatment of ocular infection, the antimicrobial potency of the specific antibiotic is the most important factor. However, drug toxicity should also be taken into consideration. Particularly in the case of ocular infections coupled with ocular surface defects, care should be taken in the topical application of the fluoroquinolone used, as a different fluoroquinolone substance itself, as well as preservatives, can affect the rate at which the surface defect heals.

ACKNOWLEDGEMENTS

Conflicts of Interest: Park HS, None; Lee JH, None; Kim HK, None.

REFERENCES

- 1 Pagel GM, Chuang AZ, Kiang E, Ramesh N, Mitra S, Yee RW. Epithelial healing rates with topical ciprofloxacin, ofloxacin, and ofloxacin with artificial tears after photorefractive keratectomy. *J Cataract Refract Surg* 2000;26(5):690-694
- 2 Baudouin C, Labbé A, Liang H, Pauly A, Brignole-Baudouin F. Preservatives in eyedrops: the good, the bad and the ugly. *Prog Retin Eye Res* 2010;29(4):312-334
- 3 Burka JM, Bower KS, Vanroekel RC, Stutzman RD, Kuzmowych CP, Howard RS. The effect of fourth-generation fluoroquinolones gatifloxacin and moxifloxacin on epithelial healing following photorefractive keratectomy. *Am J Ophthalmol* 2005;140(1):83-87
- 4 Moshirfar M, Marx DP, Kumar R. The effect of the fourth-generation fluoroquinolones on corneal reepithelialization after penetrating keratoplasty. *Cornea* 2005;24(7):833-836
- 5 Noecker R. Effects of common ophthalmic preservatives on ocular health. *Adv Ther* 2001;18(5):205-215
- 6 Lin Z, He H, Zhou T, Liu X, Wang Y, He H, Wu H, Liu Z. A mouse model of limbal stem cell deficiency induced by topical medication with the preservative benzalkonium chloride. *Invest Ophthalmol Vis Sci* 2013;54(9):6314-6325
- 7 Kim SY, Lim JA, Choi JS, Choi EC, Joo CK. Comparison of antibiotic effect and corneal epithelial toxicity of levofloxacin and moxifloxacin in vitro. *Cornea* 2007;26(6):720-725
- 8 Torkildsen G, Proksch JW, Shapiro A, Lynch SK, Comstock TL. Concentrations of besifloxacin, gatifloxacin, and moxifloxacin in human conjunctiva after topical ocular administration. *Clin Ophthalmol* 2010;4:331-341
- 9 Fiscella RG, Jensen MK. Evaluation of the penetration of fluoroquinolones in human conjunctival tissue. *Arch Ophthalmol* 2006;124(12):1796-1797
- 10 Aihara M, Miyanaga M, Minami K, Miyata K, Eguchi S, Shiroma H, Sawaguchi S. A comparison of fluoroquinolone penetration into human conjunctival tissue. *J Ocul Pharmacol Ther* 2008;24(6):587-591
- 11 Proksch JW, Ward KW. Ocular pharmacokinetics/pharmacodynamics of besifloxacin, moxifloxacin, and gatifloxacin following topical administration to pigmented rabbits. *J Ocul Pharmacol Ther* 2010;26(5):449-458