

A case of severe refractive changes induced by Galyfilcon A silicone hydrogel contact lenses

Boris Severinsky

New England College of Optometry, Boston 02115, USA

Correspondence to: Boris Severinsky. New England College of Optometry, 424, Beacon Street, Boston 02115, USA. severinskiy@yahoo.com

Received: 2015-02-06 Accepted: 2015-05-29

DOI:10.18240/ijo.2016.01.31

Severinsky B. A case of severe refractive changes induced by Galyfilcon A silicone hydrogel contact lenses. *Int J Ophthalmol* 2016; 9(1):175-177

Dear Sir,

I'm Boris Severinsky from the New England College of Optometry, Boston, USA. I write you to present an interesting case of extreme refractive and corneal topography changes induced by daily wearing of Acuvue Advance (Johnson&Johnson, Vision Care) contact lens (CL).

One of the side effects of CL wear is a condition called corneal warpage (CW). In that condition the corneal curvature undergoes series of changes as a result of CL wear. The change in corneal contour may be a result of either mechanical action of the lens on the cornea, chronic metabolic corneal insult or inflammation [1]. Signs of CL induced CW include flattening or steepening of the central cornea with variable corneal irregularity, loss of radial symmetry of the astigmatic pattern, and changes in the refractive status of the eye [2]. The other manifestation of CW is a condition called "spectacle blur", a reversible loss of spectacle corrected visual acuity that happens immediately after removal of CLs[3].

In general the resolution of CW caused by soft CL wear is not as long as with rigid gas permeable (RGP) lenses. The general consensus stands on 2-2.5wk [4-5] for daily soft CLs and 5-8.8wk for RGP[5-6].

The prevalence of warpage amongst soft CL wearers varies between reports. Phillips [3] reported that approximately 27% of all CW cases are induced by hydrogel CL wear. According to Wang *et al* [5] out of 165 long term CL wearing patients, who underwent pre-refractive surgery evaluation, significant CW was revealed in 20 eyes of 11 patients, when 12 eyes (60%) among these patients wore soft CL.

Changes in refraction and topography patterns are mostly associated with RGP and extended hydrogel CL wear [3,5], similar changes, but of lesser extent, were documented with

the use of first generation silicone hydrogels (SiH)[7]. The aim of this report is to describe a case of significant refractive and topographical changes caused by Galyfilcon A CLs.

CASE DESCRIPTION

Generally healthy 23 years old myopic female presented with complaints of decreased CL and spectacle corrected visual acuity (VA) during the past two weeks. The patient also reported a history of headaches and inability to perform prolonged near work. For number of years, she had used hydrogel, monthly replacement CLs for myopia correction. A year ago she was refitted with Galyfilcon A (Acuvue Advance), silicone hydrogel CL, due to incipient peripheral corneal neovascularization. She has been replacing her lenses monthly, despite manufacturer's 2-week replacement schedule, wearing them all day long (14-16h) and has reported that never wore her lenses overnight. She has been using polyhexamethyl biguanide (PHMB) 0.0001% (ReNu MultiPlus, Bausch & Lomb Vision Care, Rochester, NY, USA) multipurpose solution for disinfection and overnight storage purposes.

Initial Examination Patient's habitual spectacle correction and visual acuities were: RE -4.75/-1.00×95, VA 6/12; LE -6.50/-0.50×95, VA 6/6.

Manifest refraction revealed the following values: RE -3.75/-1.00×60, VA 6/9; LE -6.00/-0.50×95, VA 6/6.

There were marked differences in the appearance of retinoscopic reflex between the eyes. While the reflex of the left eye was clear, the reflex of the right eye was dim and distorted.

Keratometry reading were: RE 44.0D@75/45.0D@165, with mild distortion of mires; LE 45.25D@110/45.50D@20, with clear mires.

Ocular adnexa were unremarkable with clear lashes and eyelids. Slit lamp examinations revealed dense central superficial punctuate keratopathy (SPK) of the right cornea. The left cornea was mostly clear, with few, inferiorly located SPK's. Neither corneal neovascularization, nor pannus were seen in both eyes. Dilated fundus exam was unremarkable.

The patient was advised to discontinue CL wear, use preservatives free lubricating agent (Hypotears, Novartis) and was scheduled for the follow-up after one week.

Follow up 1 (7th day) On the next visit the patient continued to report further deterioration of her vision. Repeated refraction reveal following results: RE -0.75/-3.25×75, VA 6/9; LE -6.00/-0.50×95, VA 6/6.

Severe refractive changes induced by Galyfilcon A contact lenses

Keratometry: RE 42.25D@75/44.50D@165, distorted mires. LE 45.25D@110/45.50D@20.

The quality of retinoscopic reflex and slit lamp findings of the right eye were similar to those taken on the first visit.

Due to extreme changes in corneal curvature, refraction and non-resolving keratopathy the patient was referred to cornea specialist evaluation.

Cornea clinic (10th day) Patient's refraction continued to fluctuate: RE -0.25/-3.00×75, VA 6/10; LE -6.00/-0.50×95, VA 6/6.

Dense central epitheliopathy with mild stromal haze (Figure 1) was observed on slit-lamp examination. Pachymetry examination has showed significant difference in central corneal thickness with measurements of 498 μm for the right eye and 528 μm for the left.

Schirmer's test indicated limited tears production in the right eye and normal production rate in the left, with measurements of 10 and 30 mm respectively. Endothelial cell count was about 2900 cells per square millimeter in each eye, with no cell polymorphism.

Corneal topography (EyeSys Vision, Inc., Houston, TX, USA) have showed significant asymmetry of corneal profiles with significant central flattening, and superior steepening of the right eye cornea (Figure 2A). The topography of the left eye was within normal limits (Figure 2B).

Paradoxically, when attempting to perform an intraocular pressure (IOP) measurement (Goldman) in the right eye the first obtained measurement was around zero mark. The second measurement performed slightly off-center, revealed IOP of 14 mm Hg. The left eye pressure was 15 mm Hg. Such misleading results were probably caused by tears accumulation in the ablated central corneal zone. In such cases, the measurement is reflecting the pressure inside the interface fluid pocket, rather than real IOP^[8].

The diagnosis of CL induced CW with mild sterile keratitis was established.

The patient was prescribed with two weeks treatment course of generic chloramphenicol 0.5% to cover against possible bacterial contamination, and increased, preservative free, daily (Refresh, Allergan) and overnight (Duratears, Alcon) lubrication. No CL wearing was permitted.

Follow up 2 (28th day) Upon finishing the treatment course and almost a month after the cessation of CL wear patient's refraction stabilized to the habitual prescription values. RE -4.50/-1.00×80, VA 6/6; LE -6.25/-0.50×90, VA 6/6.

The clinical appearance of right cornea improved markedly. Epitheliopathy fully resolved and both corneas were clear without signs of fluorescein staining. Corneal topography of the right eye has showed significant improvement in surface regularity (Figure 3). Repeated pachymetry revealed similar corneal thicknesses of 519 and 530 μm , respectively.

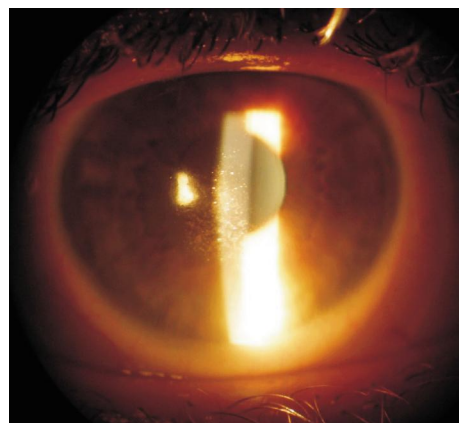


Figure 1 Right cornea exhibits dense central epitheliopathy
The image has been taken ten days later the discontinuation of contact lens wear.

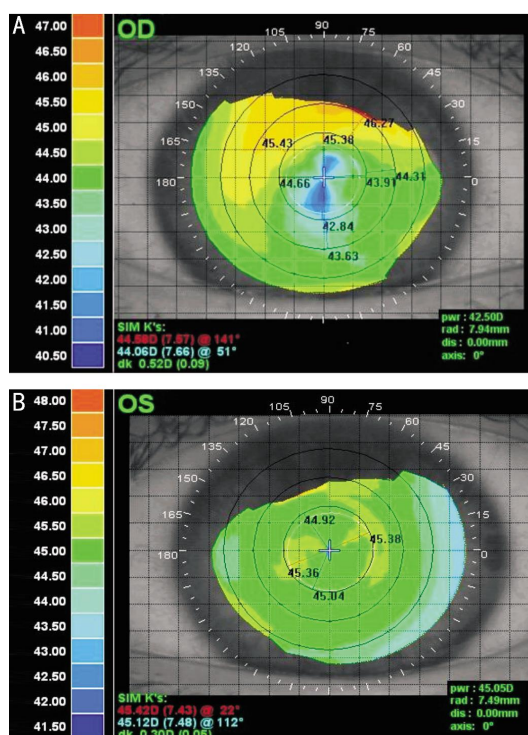


Figure 2 Corneal topography of right and left eyes 10d after the discontinuation of contact lens wear A: Note the oblate pattern of right cornea and up to 4.0 D of height asymmetry in 3 mm central corneal zone; B: Topography of the left eye exhibits regular corneal surface.

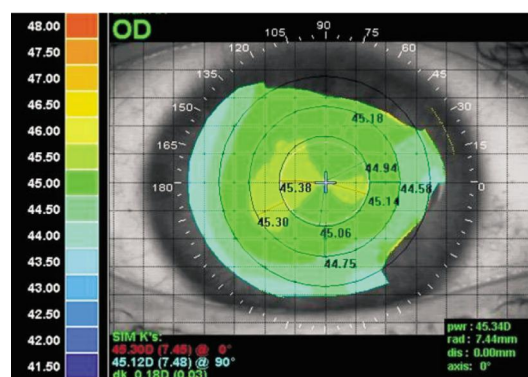


Figure 3 Corneal topography of the right eye one month later the cessation of lens wear Note marked improvement in surface regularity.

Follow up 3 Three month later refraction and topographic values remain the same as on the previous visit. Both corneas were clear with no signs of punctate staining or inflammation. She was permitted to start using her CLs again and advised to use peroxide based solution (AOSept® Plus, Ciba Vision) for overnight storage and disinfection.

DISCUSSION

The clinical picture of the CW often exhibits a "keratoconus like" topography pattern, characterized by inferior steepening and superior flattening of the cornea [9]. In the presented case the topographical pattern of the cornea has mimicked more a myopic orthokeratology effect observed after reverse geometry lens wear, *i.e.* central corneal flattening and mid-peripheral steepening. Although we cannot determine an exact etiology of the described above corneal shape fluctuations, we would suggest a number of possible scenarios.

Contact Lens Mechanical Influence It's known that use of first generation SiH CLs, characterized by high modulus of elasticity, is associated with high incidence of mechanically induced, non-inflammatory corneal complications, such as giant papillary conjunctivitis, conjunctival flap and SEAL (superior epithelial arcuate lesion) [10]. Studies suggest that the extended wear of high modulus lenses (lotrafilcon A) may impact corneal integrity, causing central flattening [11]. Mountford [12] in his review on SiH materials, reported that about 12% of patients with stable hypermetropia, fitted with lotrafilcon A or Balafilcon A CLs, have exhibited an "unexpected" hyperopia increase of more than +0.50 D during the first year of the lens wear. Described above refractive and topographical changes are the direct outcomes of elevation in the mechanical forces applied over the central cornea. These forces may cause epithelial compression and tissue redistribution, as similar to orthokeratology, producing central flattening effect.

Giving that Galyfilcon A is a second generation SiH material with lowest modulus (0.43 MPa) of elasticity and highest water content (47%), among commercially available disposable silicone hydrogel CL. It also incorporates "Hydraclear" a long-chain, high-molecular weight hydrophilic molecule that improves water retention and acts as humectant (moisture loving agent) and lubricant in such a way minimizing the mechanical lens-cornea friction. We suggest that prolonged wearing time, in this case twice more than recommended by contact lens manufacturer, led to an increase in lens modulus (stiffness) with consecutive alternation of the corneal shape and refraction.

Solutions Toxicity and Corneal Inflammation Studies have shown that the use of PHMB based CL solutions with silicone hydrogel CL is associated with an increase in non-mechanically related corneal staining, corneal toxicity and chronic, low grade inflammatory reaction [13]. A possible

etiology of toxic staining and keratitis is PHMB related epithelial damage. This damage weakens the ability of the corneal epithelium to resist lens related or other environmental challenges and triggers an inflammatory event. Chronic inflammation in turn leads to sub-epithelial fibrosis with consecutive surface irregularity. Switch to preservative free, peroxide based solutions should be recommended in such cases.

Treatment protocol of CL related CW should include discontinuation of contact lens wear till corneal topography and refraction stabilize. Patients should be encouraged to replace their lenses accordingly to the manufacturer recommendations and to perform scheduled follow up visits. Besides ocular health evaluation, contact lens follow up exam should include refraction and corneal topography in order to allow early detection of CL induced corneal warpage.

ACKNOWLEDGEMENTS

Conflicts of Interest: Severinsky B, None.

REFERENCES

- 1 Liesegang TJ. Physiologic changes of the cornea with contact lens wear. *CLAO J* 2002;28(1):12-27.
- 2 Ashbell PA, Wasserman D. Contact lens-induced corneal warpage. *Int Ophthalmol Clin* 1991;31(2):121-126.
- 3 Phillips CL. Contact lenses and corneal deformation: cause, correlate, or coincidence? *Acta Ophthalmol* 1990;68(6):661-668.
- 4 Lloyd McKernan A, O'Dwyer V, Simo Mannion L. The influence of soft contact lens wear and two weeks cessation of lens wear on corneal curvature. *Cont Lens Anterior Eye* 2014;37(1):31-37.
- 5 Wang X, McCulley JP, Bowman RW, Cavanagh HD. Time to resolution of contact lens-induced corneal warpage prior to refractive surgery. *CLAO J* 2002;28(4):169-171.
- 6 Tsai PS, Dowidar A, Naseri A, McLeod SD. Predicting time to refractive stability after discontinuation of rigid contact lens wear before refractive surgery. *J Cataract Refract Surg* 2004;30(11):2290-2294.
- 7 Alba-Bueno F, Beltran-Masgoret A, Sanjuan C, Biarnes M, Marín J. Corneal shape changes induced by first and second generation silicone hydrogel contact lenses in daily wear. *Cont Lens Anterior Eye* 2009;32(2):88-92.
- 8 Rehany U, Bersudsky V, Rumelt S. Paradoxical hypotony after laser in situ keratomileusis. *J Cataract Refract Surg* 2000;26(12):1823-1826.
- 9 Tseng SS, Hsiao JC, Chang DC. Mistaken diagnosis of keratoconus because of corneal warpage induced by hydrogel lens wear. *Cornea* 2007;26(9):1153-1155.
- 10 Lin MC, Yeh TN. Mechanical complications induced by silicone hydrogel contact lenses. *Eye Contact Lens* 2013;39(1):115-124.
- 11 Gonzalez-Mejome JM, Gonzalez-Perez J, Cervino A, Yebra-Pimentel E, Parafita MA. Changes in corneal structure with continuous wear of high-Dk soft contact lenses: a pilot study. *Optom Vis Sci* 2003;80(6):440-446.
- 12 Mountford J. Unintended orthokeratology effect of silicone hydrogels on hypermetropic patients. 2003. http://www.siliconehydrogels.org/featured_review/featured_review_aug_03.asp. Accessed on May 12, 2015.
- 13 Malet F. An acute clinical comparison of corneal staining and comfort associated with contact lens care solutions. *Cont Lens Anterior Eye* 2014;37(5):351-357.