

# Uncovering the profile of mutations of transforming growth factor beta–induced gene in Chinese corneal dystrophy patients

*Xiao-Dan Hao<sup>1</sup>, Yang-Yang Zhang<sup>1</sup>, Peng Chen<sup>1</sup>, Su-Xia Li<sup>2</sup>, Ye Wang<sup>1</sup>*

<sup>1</sup>State Key Laboratory Cultivation Base, Shandong Provincial Key Laboratory of Ophthalmology, Shandong Eye Institute, Shandong Academy of Medical Sciences, Qingdao 266071, Shandong Province, China

<sup>2</sup>Shandong Eye Hospital, Shandong Eye Institute, Shandong Academy of Medical Sciences, Jinan 250021, Shandong Province, China

**Co–first authors:** Xiao-Dan Hao and Yang-Yang Zhang

**Correspondence to:** Ye Wang. State Key Laboratory Cultivation Base, Shandong Provincial Key Laboratory of Ophthalmology, Shandong Eye Institute, Shandong Academy of Medical Sciences, No. 5 Yanerdao Road, Qingdao 266071, Shandong Province, China. wyel12002@126.com

Received: 2014-08-04 Accepted: 2015-12-01

## Abstract

• **AIM:** To uncover the mutations profile of transforming growth factor beta–induced (*TGFBI*) gene in Chinese corneal dystrophy patients and further investigate the characteristics of genotype–phenotype correlations.

• **METHODS:** Forty–two subjects (6 unrelated families including 15 patients and 8 unaffected members, and 19 sporadic patients) of Chinese origin were subjected to phenotypic and genotypic characterization. The corneal phenotypes of patients were documented by slit lamp photography. Mutation screening of the coding regions of *TGFBI* was performed by direct sequencing.

• **RESULTS:** We detected four corneal dystrophy types. The most frequent phenotypes were granular corneal dystrophy (GCD) (including 3 families and 8 sporadic patients) and lattice corneal dystrophy (LCD) (including 2 families and 9 sporadic patients). The next phenotypes were corneal dystrophy of Bowman layer (CDB) (1 family and 1 sporadic patient) and epithelial basement membrane dystrophy (EBMD) (1 sporadic patient). Six distinct mutations responsible for *TGFBI* corneal dystrophies were identified in 30 individuals with corneal dystrophies. Those were, p.R124H mutation in 1 family and 2 sporadic patients with GCD, p.R555W mutation in 2 families and 3 sporadic patients with GCD, p.R124C mutation in 2 families and 7 sporadic patients with LCD, p.A620D mutation in 1 sporadic patient with LCD, p.H626R mutation in 1 sporadic patient with LCD, and p.R555Q in 1 family and 1 sporadic patient with CDB. No mutation

was detected in the remaining 3 atypical GCD patients and 1 EBMD patient.

• **CONCLUSION:** GCD and LCD are the most frequent phenotypes in Chinese population. R555W was the most common mutation for GCD; R124C was the most common mutation for LCD. Our findings extend the mutational spectrum of *TGFBI*, and this is the extensively delineated *TGFBI* mutation profile associated with the various corneal dystrophies in the Chinese population.

• **KEYWORDS:** transforming growth factor beta–induce; corneal dystrophy; mutations; Chinese

**DOI:10.18240/ijo.2016.02.03**

Hao XD, Zhang YY, Chen P, Li SX, Wang Y. Uncovering the profile of mutations of transforming growth factor beta–induced gene in Chinese corneal dystrophy patients. *Int J Ophthalmol* 2016;9(2):198–203

## INTRODUCTION

Corneal dystrophy (CD) is a group of inherited, bilateral, symmetric, slowly progressive corneal diseases, characterized by deposition of nonnative protein or other material in different layers of the cornea which leading to the loss of corneal transparency and vision acuity<sup>[1]</sup>. Corneal dystrophies usually manifest themselves during the first or second decade but sometimes later. CDs are commonly subdivided depending on its specific location within the cornea. It can be basically divided into anterior, stromal, or posterior according to the layer of the cornea affected by the dystrophy<sup>[1]</sup>. Most forms of CD are inherited as autosomal dominant (AD) traits; a few are inherited as autosomal recessive (AR) traits<sup>[2]</sup>.

Transforming growth factor beta–induced (*TGFBI*) gene locates in chromosome 5q31 and encodes for TGFBI–associated protein, an extracellular matrix protein, which plays a role in cell–collagen interactions<sup>[3]</sup>. Mutations in *TGFBI* gene [(Online Mendelian Inheritance in Man (OMIM) 601692] have been identified in several AD corneal dystrophies, including: epithelial basement membrane dystrophy (EBMD), Reis–Bücklers corneal dystrophy (RBCD), Thiel–Behnke corneal dystrophy (TBCD), classic lattice corneal dystrophy (LCD1), granular corneal dystrophy (GCD)

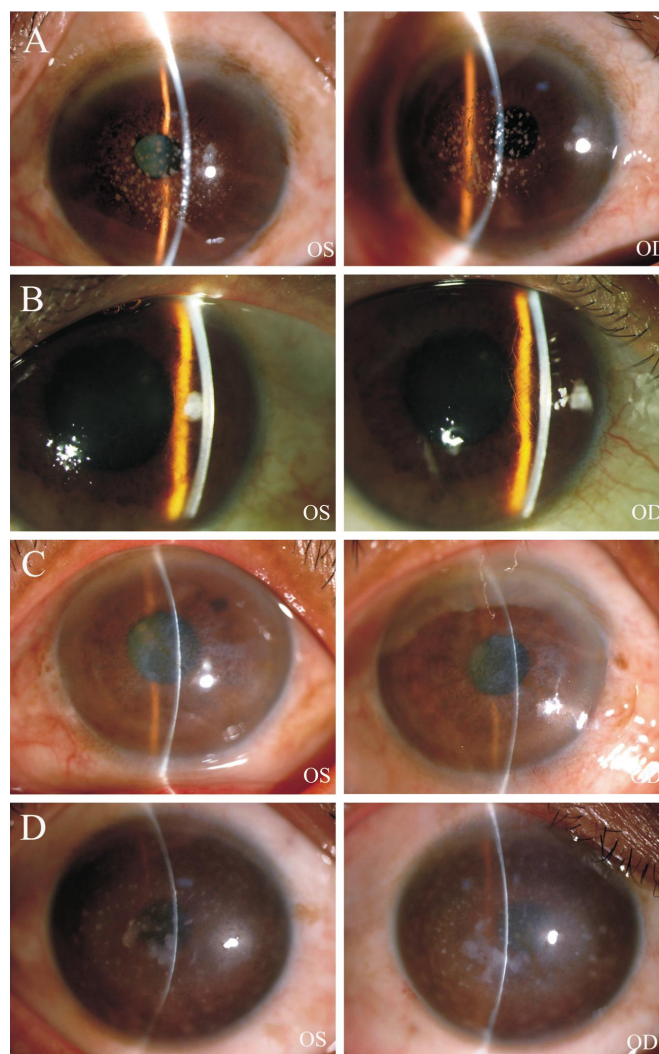
Type 1 (GCD1) and Variants, GCD Type 2 (GCD2)<sup>[4-9]</sup>. Until now, dozens of distinct disease-causing mutations in *TGFBI* have been identified in different population with different phenotypes<sup>[1,10]</sup>. Although few genotype-phenotype correlations, *e.g.* p.R555W in GCD1, p.R124C in LCD1, p.R124H in GCD2, and p.R555Q in TBCD, have emerged from these molecular studies, for the majority of the corneal dystrophies, a genotype-phenotype correlation has not been demonstrated in that multiple different identified coding region mutations. In the clinic, it is difficult to make an accurate diagnosis and classification for patients with variable and atypical phenotypes.

In this paper, we present the results of a clinical and genetic analysis of Chinese families and sporadic patients with *TGFBI*-related corneal dystrophies, with the aims to uncover the profile of mutations of *TGFBI* gene in Chinese CD patients and further investigate the characteristics of genotype-phenotype correlations. Our result extended the database of genotype-phenotype correlations and was helpful to make an accurate diagnosis and classification for patients with variable and atypical phenotypes.

#### SUBJECTS AND METHEDS

**Subjects** A total of 23 family subjects (6 unrelated families including 15 patients and 8 unaffected members), 19 sporadic patients and 50 health controls of Chinese origin were included in the present study. The mean age of patients was 33±16y. Patients affected with CD were recruited from cornea clinic, Qingdao Eye Hospital and Shandong Eye Hospital. All the patients were performed with complete ophthalmologic examination by the experienced ophthalmologists. Eight patients from 3 families and 8 sporadic patients were diagnosed as GCD which was characterized by central, fine, whitish granular lesions in the cornea (Figure 1A, 1D). Four patients of 2 families and 9 sporadic patients presented with LCD which was characterized by clear, comma-shaped overlapping dots and branching filaments, creating a lattice effect in the stroma (Figure 1B). Four patients including 3 patients from 1 family and 1 sporadic patient presented with corneal dystrophy of Bowman layer (CDB) (Figure 1C). One sporadic patient was diagnosed as EBMD. The pedigree of each family was also recorded. The disease showed an AD inheritance pattern in all families. Unaffected family members without CD were confirmed by a similar testing protocol. The study was performed in accordance with the tenet of the World Medical Association of Helsinki regarding research involving human subjects. Written consent was obtained from all participants, in accordance with protocols approved by the institutional review board at each contributing center.

**DNA Collection, Isolation, Amplification and Sequencing** We sequenced all the exons and flanking introns of the *TGFBI* gene in patients of 6 families and 19 sporadic patients. Peripheral blood samples (5 mL) were



**Figure 1 Representative corneal phenotypes as shown by slit lamp examination** A: Clinical photographs of one sporadic patient with typical GCD; B: Clinical photographs from the proband of family L1 with LCD; C: Clinical photographs from the proband of CDB family; D: Clinical photographs of one sporadic patient with atypical GCD.

collected from all participators and genomic DNA was isolated by standard phenol/chloroform method. DNA concentration was measured by Eppendorf BioPhotometer. All exons and adjacent intronic sequences of the *TGFBI* gene were polymerase chain reaction (PCR) amplified from genomic DNA with previously reported primers<sup>[11]</sup>. PCR was carried out in 25  $\mu$ L of reaction containing 1  $\times$  LA PCR buffer II (Mg<sup>2+</sup> plus), 20 ng DNA, 0.5  $\mu$ mol/L each of the primers, 0.4 mmol/L each of deoxynucleotide triphosphate, and 1.25 U of LA Taq DNA polymerase (Takara, Dalian, Liaoning Province, China). The reaction mixture was initially denatured at 95°C for 3min followed by 35 cycles of 95°C for 40s, 50°C for 40s, and 72°C for 1min for the exons 1-3, 5, 7-16 reactions, or 35 cycles of 95°C for 40s, 57°C for 40s, and 72°C for 1min for the exon 4 reaction, or 35 cycles of 95°C for 40s, 52°C for 40s, and 72°C for 1min for the exons 6 and 17 reactions. The PCR was completed by a final

## Transforming growth factor beta–induced gene mutations in Chinese corneal dystrophy patients

**Table 1** *TGFBI* mutations and phenotypes of patients in 6 families and 19 sporadic cases

CD	Exon	Nucleotide change	AA change	Function prediction	No. of families	No. of individuals	Percentage (%)
GCD	4	c.371G>A	p.R124H	Damaging	1	2	27.3
	12	c.1663 C>T	p.R555W	Damaging	2	3	45.5
		Absence			0	3	27.3
LCD	4	c.370C>T	p.R124C	Damaging	2	7	81.8
	14	c.1859C>A	p.A620D	Damaging	0	1	9.1
	14	c.1877A>G	p.H626R	Possibly damaging	0	1	9.1
CDB	12	c.1664G>A	p.R555Q	Possibly damaging	1	1	100
EBMD		Absence			0	1	100

*TGFBI*: Transforming growth factor beta-induced gene; GCD: Granular corneal dystrophy; LCD: Lattice corneal dystrophy; CDB: Corneal dystrophy of Bowman layer; EBMD: Epithelial basement membrane dystrophy; AA: Amino acid; CD: Corneal dystrophy.

extension at 72 °C for 10min. The products were purified with gel extraction kits (Watson BioMedical Inc., Shanghai, China) and were subjected to direct DNA sequencing using the BigDye® Terminator v3.1 Cycle Sequencing kit and ABI PRISM 3730 sequencer (Applied Biosystems Inc., USA). Sequences were aligned and analyzed with DNASTar software package (DNASTar Inc., Madison, WI, USA). Nucleotide sequences were compared with the wild-type *TGFBI* sequence (GenBank NG\_012646.1). As an additional step, gene mutations were also sequenced in unaffected family subjects and 50 unrelated controls. Polymorphism Phenotyping v2 (PolyPhen-2) was used to predict the functional effects of mutations.

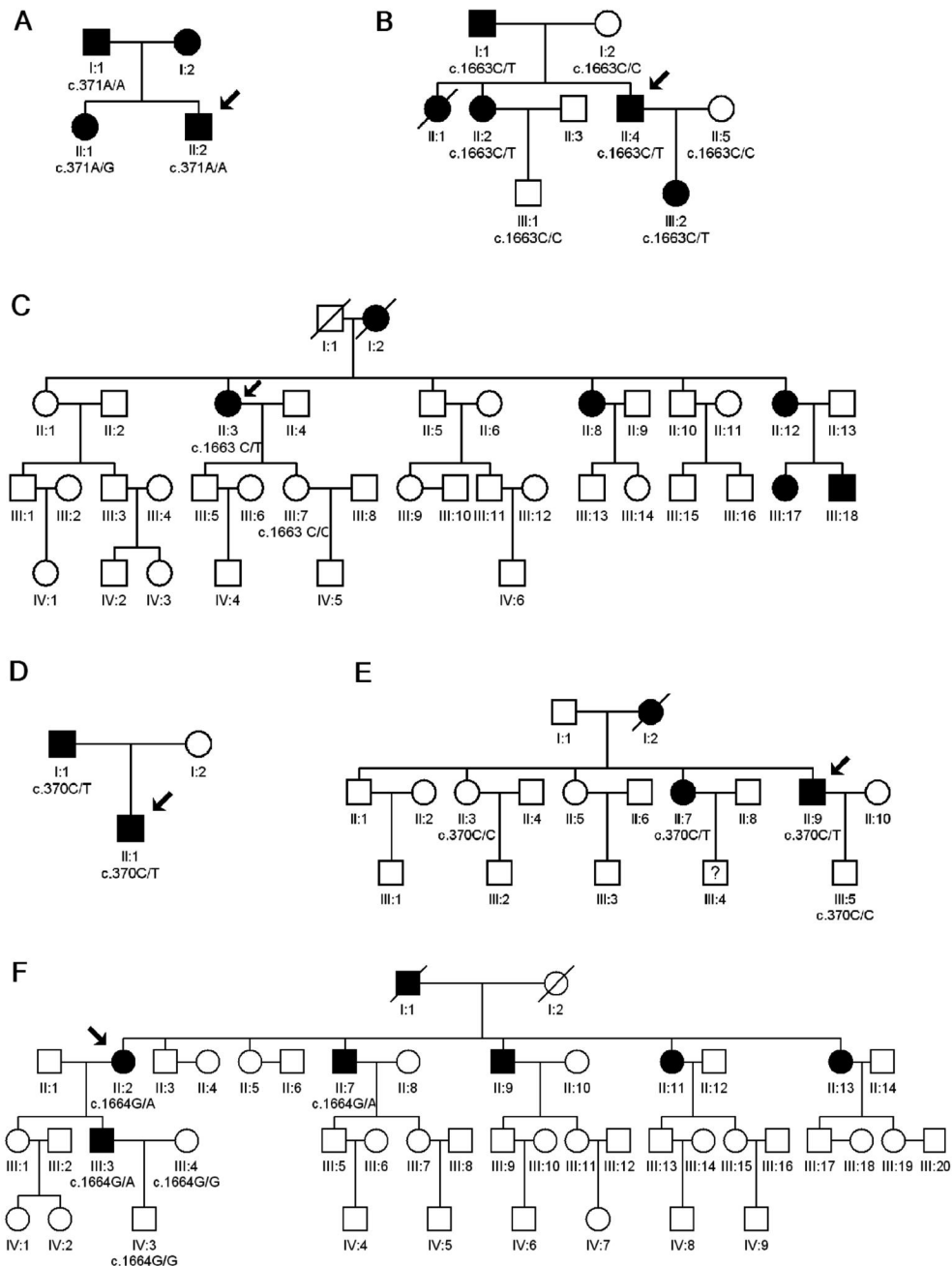
### RESULTS

*TGFBI* mutations and phenotypes of patients in 6 families and 19 sporadic cases are shown in Table 1. In total, we detected four CD types, including GCD, LCD, CDB and EBMD. Six distinct mutations responsible for *TGFBI* corneal dystrophies were identified in 30 individuals with corneal dystrophies. All mutations segregated with the disease and were not observed in 50 unrelated health controls. PolyPhen-2 analysis revealed a score for each of the six mutations and predicted that the replaced amino acid was "damaging" or "possibly damaging" to protein function. Further details are described below.

**Granular Corneal Dystrophy** Eight patients from 3 families (family G1, G2 and G3) and 8 sporadic patients were diagnosed as GCD. In total, two reported mutations were detected in 3 families and 5 sporadic patients. No mutation of *TGFBI* gene was detected in 3 sporadic patients (Table 1). The pedigree of family G1 was shown in Figure 2A. G to A transition at nucleotide position 371 (c.371G>A) were detected in all affected members of this family. For three available patients, the proband (II:2) and his father (I:1) were homozygous, and his sister (II:1) was heterozygous. This nucleotide substitution resulted in the amino acid change from Arginine to Histidine at amino acid position 124 (p.R124H), and was predicted to be damaging. Two sporadic patients also harbor this mutation, one with a homozygous genotype and another with a heterozygous genotype. Two

families and 3 sporadic patients carried C to T transition at nucleotide c.1663 (c.1663 C>T), which resulted in the amino acid change from Arginine to Tryptophan at amino acid position 555 (p.R555W). This mutation was also predicted to be damaging. The pedigree of family G2 was shown in Figure 2B. For this family, 4 affected members and 3 unaffected members were collected for sequencing. All affected members harbored a heterozygous p.R555W mutation, whereas unaffected family members were not detected. The pedigree of family G3 was shown in Figure 2C. One affected member and one unaffected member were collected. Affected member of family G3 harbored a heterozygous p.R555W mutation, which is absence in unaffected family member too. All of the 3 sporadic patients harboring p.R555W mutation were heterozygous. For the rest 3 sporadic patients, there was no mutation of *TGFBI* gene was detected.

**Lattice Corneal Dystrophy** Four patients of 2 families (family L1 and L2) and 9 sporadic patients presented with LCD. Totally, three reported mutations were detected in LCD patients. The pathogenic mutations were detected in all of LCD patients. We identified a C to T transition at position c.370 (c.370 C>T) in exon 4 of *TGFBI* in 2 families and 7 sporadic patients, which caused the substitution of Arginine for Cysteine at codon 124 (p.R124C). This mutation was predicted to be damaging by PolyPhen-2 analysis. The pedigree of family L1 was shown in Figure 2D. Two affected members of family L1 were recruited, including proband and his father. They all carried a heterozygous p.R124C mutation. The pedigree of family L2 was shown in Figure 2E. For this family, 2 affected members and 2 unaffected members were collected for sequencing. All affected members harbored a heterozygous p.R124C mutation, whereas unaffected family members were not detected. Seven sporadic patients harbored heterozygous p.R124C mutation. Heterozygous A to G transition at position c.1877 (c.1877 A>G) was detected in one LCD sporadic patient, which results in substitution of Histidine to Arginine at codon 626 (p.H626R). This mutation was predicted to be possibly damaging. In another LCD sporadic patient, we



**Figure 2** Pedigrees of 6 Chinese families with corneal dystrophies and their corresponding mutations of *TGFBI*.

identified a heterozygous C to A transversion at position c.1859 (c.1859 C>A), which resulted in the amino acid change from Alanine to Aspartic acid at amino acid position 620 (p.A620D). This mutation was predicted to be damaging too.

**Corneal Dystrophy of Bowman Layer** Four patients including 3 patients from 1 family and 1 sporadic patient presented with CDB. A reported mutation, c.1664G>A was detected in the CDB family and sporadic patient. The pedigree of CDB family was shown in Figure 2F. Five members including 3 affected members and 2 unaffected members were recruited. A heterozygous c.1664 G>A mutation was detected in the 3 affected members, and which is absent in unaffected members. This mutation resulted in substitution of Arginine to Glutamine at codon 555 (p.R555Q), and was predicted to be possibly damaging. The

sporadic patient also carried this heterozygous p.R555Q mutation.

**Epithelial Basement Membrane Dystrophy** After direct sequencing all exons of *TGFBI*, no mutation was detected in the sporadic patient diagnosed as EBMD.

**DISCUSSION**

In this comprehensive report of *TGFBI* mutations in a Chinese population, we detected four CD types, and identified six reported distinct mutations responsible for *TGFBI* corneal dystrophies in 30 individuals with corneal dystrophies. There are two studies have analyzed the *TGFBI* gene mutations in Chinese CD patients previously [10,12]. Most of our results were identical with them, but there were some new findings. The most frequent phenotypes were GCD (including 3 families and 8 sporadic patients) and LCD

(including 2 families and 9 sporadic patients) in our study, which were similar to the previous studies [10,12]. The next phenotypes were CDB (1 family and 1 sporadic patient) and EBMD (1 sporadic patient), which were absent in the previous studies [10,12]. In our study, 6 mutations of *TGFBI* were identified in 30 individuals with corneal dystrophies. Those were, p.R124H mutation in 3 patients from 1 GCD family and 2 sporadic patients with GCD, p.R555W mutation in 5 patients from 2 GCD families and 3 sporadic patients with GCD, p.R124C mutation in 4 patients from 2 LCD families and 7 sporadic patients with LCD, p.A620D mutation in 1 sporadic patient with LCD, p.H626R mutation in 1 sporadic patient with LCD and p.R555Q in 3 patients from 1 CDB family and 1 sporadic patient with CDB. Same as previous studies, our results showed that p.R124H and p.R555W were the most common mutations for GCD; p.R124C was the most common mutation for LCD [10,12]. For LCD patients, we also identified p.A620D and p.H626R mutations, which were not observed in the previous studies [10,12]. All the mutations were locus on exons 4, 12 or 14, which suggested that these three exons are mutation hot spots. All detected mutations segregated with the disease and were not observed in 50 unrelated health controls. PolyPhen-2 analysis predicted that the six mutations were "damaging" or "possibly damaging" to protein function. Pathogenic *TGFBI* mutations were detected in 84% (6/6 family and 15/19 sporadic patients) of our CD patients, which is lower than Yang *et al* [10] (100%). No mutation was detected in the remaining 3 atypical GCD patients (Figure 1D) and 1 EBMD patient, which may be caused by some other genes. Our findings extended the mutational spectrum of *TGFBI*, and confirmed a strong correlation between gene specific mutations and corneal dystrophies in Chinese. This will be helpful to make an accurate diagnosis and classification for patients with variable and atypical phenotypes.

In most cases, mutations in *TGFBI* gene-related CDs are heterogeneous, and R124H mutation of *TGFBI* gene has been reported as the most common mutation in GCD2 [10-15]. In this present study, we found p.R124H mutation in 3 patients from 1 GCD family and 2 sporadic patients with GCD, which suggested they belong to the GCD2. Among them, there were two cases from one family and one sporadic patient harbored homozygous R124H mutation. The clinical features include more severe symptoms, earlier onset, and faster progression than other heterozygous GCD. Three cases were reported previously as homozygous R124H mutation from northern China as the offsprings of two consanguineous marriages [15-16]. In our study, neither this family nor individual was aware of consanguineous marriage. The R555W mutation of *TGFBI* was first identified associated with GCD1 by Munier *et al* [17]. Since then, this mutation has been demonstrated to have a clear genotype-phenotype

association with GCD1 [2,12,18-19]. In this present study, by directly genetic analysis, we found R555W mutation in 5 patients from 2 GCD families and 3 sporadic patients with GCD, which suggested they belong to a classification of GCD type 1. For the rest 3 sporadic patients, there was no mutation of *TGFBI* gene was detected, which may be caused by some other genes.

p. R124C mutation is one of the most common mutations of LCD1 worldwide [10,20-21]. Our study also identified the R124C mutation in 4 patients from 2 LCD families and 7 sporadic patients with LCD, which suggested they belong to LCD1. All the patients exhibited the similar phenotype of LCD. Typical progressive vision acuity loss and cornea opacity were present in their first decade of life, accompanied by ocular pain and recurrent corneal erosions. Our study supported R124C as the hot mutation spot of LCD. Our study also identified p.A620D mutation and p.H626R mutation in 1 sporadic patient with LCD from China, respectively. The p.A620D mutation was first identified in a Chinese patient with LCD [22]. To our knowledge, this is the second report of this mutation. The p.H626R mutation of *TGFBI* gene was previously reported to cause LCD in several white families, Vietnamese people and two Chinese patients [22-25]. The H626R mutation, located at the b-strand 9 of the fourth fasciclin-like (FAS1) domain presents in diverse ethnic groups.

Patients with corneal opacities at the level of Bowman's layer have been previously diagnosed as having CDB [26]. In this present study, we also found p.R555Q in 3 patients from 1 CDB family and 1 sporadic patient with CDB. RBCD and TBCD are typically characterized by geographic opacities and honeycomb-shaped opacities, respectively. Most patients reported to have RBCD had the R124L mutation and those reported to have TBCD had the R555Q mutation [27-28]. Our data indicated that all patients with Bowman's layer dystrophy carried the R555Q mutation (heterozygous form), but not R124L, which suggested they belong to the TBCD type.

After direct sequencing all exons of *TGFBI*, no mutation was detected in the sporadic patient diagnosed as EBMD. It is probable that only a subset of EBMD is induced by *TGFBI* mutations [4]. The EBMD patient of our study may be due to nongenetic cause or mutation in other genes. Genes that are expressed in the cornea and have adhesion function would represent good candidates.

In conclusion, we reported here phenotype-genotype correlations in a Chinese population with *TGFBI*-related corneal dystrophies. A group of families and patients from China were analyzed, and 6 reported distinct mutations responsible for *TGFBI* corneal dystrophies were identified. The data suggested that a strong correlation between gene specific mutations and corneal dystrophies in Chinese. GCD and LCD are the most frequent phenotypes in Chinese

population. R555W was the most common mutation for GCD; p.R124C was the most common mutation for LCD. It appears that the different phenotypes of CD are caused by particular amino acid change, as one mutation type just corresponds to one phenotype. No mutation was detected in 3 atypical GCD patients (Figure 1D) and 1 EBMD patient, which may be caused by some other genes. Further genetic study is needed for these patients.

#### ACKNOWLEDGEMENTS

We are grateful for the persons who participated in this research.

**Foundations:** Supported by the National Natural Science Foundation of China (No.81370990); the Young and Middle-Aged Scientists Research Awards Fund of Shandong Province, China (No. BS2013YY013, No. BS2015YY014); the Science and Technology Foundation of Shinan District, Qingdao, Shandong Province, China (No. 2013-13-014-YY).

**Conflicts of Interest:** Hao XD, None; Zhang YY, None; Chen P, None; Li SX, None; Wang Y, None.

#### REFERENCES

- 1 Weiss JS, Moller HU, Lisch W, Kinoshita S, Aldave AJ, Belin MW, Kivela T, Busin M, Munier FL, Seitz B, Sutphin J, Bredrup C, Mannis MJ, Rapuano CJ, Van Rij G, Kim EK, Klintworth GK. The IC3D classification of the corneal dystrophies. *Cornea* 2008;27 Suppl 2:S1-83.
- 2 Pieramici SF, Afshari NA. Genetics of corneal dystrophies: the evolving landscape. *Curr Opin Ophthalmol* 2006;17(4):361-366.
- 3 Escibano J, Hernando N, Ghosh S, Crabb J, Coca-Prados M. cDNA from human ocular ciliary epithelium homologous to beta ig-h3 is preferentially expressed as an extracellular protein in the corneal epithelium. *J Cell Physiol* 1994;160(3):511-521.
- 4 Boutboul S, Black GC, Moore JE, Sinton J, Menasche M, Munier FL, Laroche L, Abitbol M, Schorderet DF. A subset of patients with epithelial basement membrane corneal dystrophy have mutations in TGFBI/BIGH3. *Hum Mutat* 2006;27(6):553-557.
- 5 Piao MZ, Zhou XT, Wu LC, Chu RY. Arg555Gln mutation of TGFBI gene in geographical-type Reis-Bucklers corneal dystrophy in a Chinese family. *J Int Med Res* 2012;40(3):1149-1155.
- 6 Hieda O, Kawasaki S, Wakimasu K, Yamasaki K, Inatomi T, Kinoshita S. Clinical outcomes of phototherapeutic keratectomy in eyes with Thiel-Behnke corneal dystrophy. *Am J Ophthalmol* 2013;155(1):66-72.e1.
- 7 Zhong X, Chen S, Huang W, Yang J, Chen X, Zhou Y, Zhou Q, Wang Y. Novel and known mutations of TGFBI, their genotype-phenotype correlation and structural modeling in 3 Chinese families with lattice corneal dystrophy. *Mol Vis* 2010;16:224-230.
- 8 Zhao SJ, Zhu YN, Shentu XC, Miao Q. Chinese family with atypical granular corneal dystrophy type I caused by the typical R555W mutation in TGFBI. *Int J Ophthalmol* 2013;6(4):458-462.
- 9 Li Y, Li T, Song XS, Li JZ, Wu QS, Li HY. TGFBI and CHST6 gene analysis in Chinese stromal corneal dystrophies. *Int J Ophthalmol* 2012;5(3):301-306.
- 10 Yang J, Han X, Huang D, Yu L, Zhu Y, Tong Y, Zhu B, Li C, Weng M, Ma X. Analysis of TGFBI gene mutations in Chinese patients with corneal dystrophies and review of the literature. *Mol Vis* 2010;16:1186-1193.
- 11 Gu Z, Zhao P, He G, Wan C, Ma G, Yu L, Zhang J, Feng G, He L, Gao L. An Arg124His mutation in TGFBI associated to Avellino corneal dystrophy in a Chinese pedigree. *Mol Vis* 2011;17:3200-3207.
- 12 Yam GH, Wang K, Jhanji V, Choy KW, Baum L, Pang CP. *In vitro*

amyloid aggregate forming ability of TGFBI mutants that cause corneal dystrophies. *Invest Ophthalmol Vis Sci* 2012;53(9):5890-5898.

13 Yoshida S, Kumano Y, Yoshida A, Hisatomi T, Matsui H, Nishida T, Ishibashi T, Matsui T. An analysis of BIGH3 mutations in patients with corneal dystrophies in the Kyushu district of Japan. *Jpn J Ophthalmol* 2002;46(4):469-471.

14 Huerva V, Velasco A, Sanchez MC, Matias-Guiu X. Role of BIGH3 R124H mutation in the diagnosis of Avellino corneal dystrophy. *Eur J Ophthalmol* 2008;18(3):345-350.

15 Cao W, Ge H, Cui X, Zhang L, Bai J, Fu S, Liu P. Reduced penetrance in familial Avellino corneal dystrophy associated with TGFBI mutations. *Mol Vis* 2009;15:70-75.

16 Yu J, Zou LH, He JC, Liu NP, Zhang W, Lu L, Sun XG, Dong DS, Wu YY, Yin XT. Analysis of mutation of BIGH3 gene in Chinese patients with corneal dystrophies. *Zhonghua Yan Ke Za Zhi* 2003;39(10):582-586.

17 Munier FL, Frueh BE, Othenin-Girard P, Uffer S, Cousin P, Wang MX, Heon E, Black GC, Blasi MA, Balestrazzi E, Lorenz B, Escoto R, Barraquer R, Hoeltzenbein M, Gloor B, Fossarello M, Singh AD, Arsenijevic Y, Zografos L, Schorderet DF. BIGH3 mutation spectrum in corneal dystrophies. *Invest Ophthalmol Vis Sci* 2002;43(4):949-954.

18 Aldave AJ, Sonmez B. Elucidating the molecular genetic basis of the corneal dystrophies: are we there yet? *Arch Ophthalmol* 2007;125(2):177-186.

19 Kannabiran C, Klintworth GK. TGFBI gene mutations in corneal dystrophies. *Hum Mutat* 2006;27(7):615-625.

20 Fujiki K, Hotta Y, Nakayasu K, Yamaguchi T, Kato T, Uesugi Y, Ha NT, Endo S, Ishida N, Lu WN, Kanai A. Six different mutations of TGFBI (betaig-h3, keratopithelin) gene found in Japanese corneal dystrophies. *Cornea* 2000;19(6):842-845.

21 Romero P, Vogel M, Diaz JM, Romero MP, Herrera L. Anticipation in familial lattice corneal dystrophy type I with R124C mutation in the TGFBI (BIGH3) gene. *Mol Vis* 2008;14:829-835.

22 Lakshminarayanan R, Vithana EN, Chai SM, Chaurasia SS, Saraswathi P, Venkatraman A, Rojare C, Venkataraman D, Tan D, Aung T, Beuerman RW, Mehta JS. A novel mutation in transforming growth factor-beta induced protein (TGFbetaI<sub>p</sub>) reveals secondary structure perturbation in lattice corneal dystrophy. *Br J Ophthalmol* 2011;95(10):1457-1462.

23 Stewart H, Black GC, Donnai D, Bonshek RE, McCarthy J, Morgan S, Dixon MJ, Ridgway AA. A mutation within exon 14 of the TGFBI (BIGH3) gene on chromosome 5q31 causes an asymmetric, late-onset form of lattice corneal dystrophy. *Ophthalmology* 1999;106(5):964-970.

24 Schmitt-Bernard CF, Guittard C, Arnaud B, Demaille J, Argiles A, Claustres M, Tuffery-Giraud S. BIGH3 exon 14 mutations lead to intermediate type I/IIIA of lattice corneal dystrophies. *Invest Ophthalmol Vis Sci* 2000;41(6):1302-1308.

25 Chau HM, Ha NT, Cung LX, Thanh TK, Fujiki K, Murakami A, Kanai A. H626R and R124C mutations of the TGFBI (BIGH3) gene caused lattice corneal dystrophy in Vietnamese people. *Br J Ophthalmol* 2003;87(6):686-689.

26 Haddad R, Font RL, Fine BS. Unusual superficial variant of granular dystrophy of the cornea. *Am J Ophthalmol* 1977;83(2):213-218.

27 Dighiero P, Valleix S, D'Hermies F, Drunat S, Ellies P, Savoldelli M, Pouliquen Y, Delpech M, Legeais JM, Renard G. Clinical, histologic, and ultrastructural features of the corneal dystrophy caused by the R124L mutation of the BIGH3 gene. *Ophthalmology* 2000;107(7):1353-1357.

28 Ridgway AE, Akhtar S, Munier FL, Schorderet DF, Stewart H, Perveen R, Bonshek RE, Odenthal MT, Dixon M, Barraquer R, Escoto R, Black GC. Ultrastructural and molecular analysis of Bowman's layer corneal dystrophies: an epithelial origin? *Invest Ophthalmol Vis Sci* 2000;41(11):3286-3292.