

# Femtosecond laser capsulotomy versus manual capsulotomy: a Meta-analysis

Dao-Wei Qian<sup>1,2,3</sup>, Hai-Ke Guo<sup>2</sup>, Shang-Li Jin<sup>1,2</sup>, Hong-Yang Zhang<sup>2</sup>, Yuan-Cun Li<sup>1,2</sup>

<sup>1</sup>Southern Medical University, Guangzhou 510515, Guangdong Province, China

<sup>2</sup>Department of Ophthalmology, Guangdong General Hospital/Guangdong Academy of Medical Sciences, Guangzhou 510080, Guangdong Province, China

<sup>3</sup>Department of Ophthalmology, Pingshan New District People's Hospital of Shenzhen, Shenzhen 518118, Guangdong Province, China

**Correspondence to:** Hai-Ke Guo. Department of Ophthalmology, Guangdong General Hospital/Guangdong Academy of Medical Sciences, Guangzhou 510080, Guangdong Province, China. guohaike@medmail.com.cn

Received: 2015-01-14 Accepted: 2015-06-11

## Abstract

• **AIM:** To perform a Meta-analysis on the precision and safety of femtosecond laser (FSL) capsulotomy compared with manual continuous curvilinear capsulotomy (CCC).

• **METHODS:** We searched PubMed, EMBASE, Web of Science, the Cochrane Library databases, and ClinicalTrials.gov that maintained our inclusion criteria. Reference lists of retrieved articles were also reviewed. The effects of morphology of capsulorhexis and the tears of anterior capsule were calculated by using random-effect models.

• **RESULTS:** We identified 4 randomized and 7 nonrandomized studies involving 2941 eyes. The diameter of capsulotomy and the rates of anterior capsule tear showed no statistically difference between FSL group and manual group (MD=0.03; 95%CI, -0.03 to 0.09,  $P=0.31$ ), and (OR=1.40; 95%CI, 0.28 to 6.97,  $P=0.68$ ) respectively. In terms of the circularity of capsulotomy, FSL group had a more significant advantage than the manual CCC group (MD=0.09; 95%CI, 0.05 to 0.12,  $P<0.001$ ).

• **CONCLUSION:** Our Meta-analysis shows that FSL can perform a capsulotomy with more precision and higher reliability than manual CCC. The results in diameter of capsulotomy and the rate of anterior capsule tears was no significant difference between FSL and manual CCC groups. However in terms of circularity, the FSL was superior to the manual procedure.

• **KEYWORDS:** femtosecond laser; cataract surgery;

capsulotomy/capsulorhexis; phacoemulsification; Meta-analysis

**DOI:10.18240/ijo.2016.03.23**

Qian DW, Guo HK, Jin SL, Zhang HY, Li YC. Femtosecond laser capsulotomy versus manual capsulotomy: a Meta-analysis. *Int J Ophthalmol* 2016;9(3):453-458

## INTRODUCTION

Cataract surgery is one of the most successfully and commonly performed ophthalmic procedure worldwide<sup>[1]</sup>. As a critical step in the cataract procedure, the capsulorhexis is making a window in anterior capsule wall, techniques employed for this task have undergone sustained evolution<sup>[2]</sup>. Continuous curvilinear capsulotomy (CCC) has been recognized as the standard method of anterior capsulectomy. The size, shape, and centration of capsulotomy is key determinants of the positioning and refractive outcomes, too small or too large capsulotomies caused intraocular lens (IOL) decentration or tilting, fibrosis and hyperopic shift, posterior capsular opacification<sup>[3-6]</sup>, even more profound in patients undergoing surgery with toric, multifocal or accommodating IOLs. Unfortunately, the CCC is still a manual procedure, the size, shape, and centration of the capsulorhexis can be variable depending on the type of cataract, even in the experience surgeons, these have implications for the final refractive outcome, while also increasing the risk of aberrations such as astigmatism, halo and coma.

Femtosecond lasers (FSL) use a shorter pulse time of  $10^{-15}$ s, thus further decrease energy output for a given effect without collateral damage<sup>[7]</sup>. FSL first became available for refractive surgery in 2001, the flaps created by FSL were more reproducible, uniform, closer to their intended thickness and centration, had improved safety profiles compared with those made by manual keratome<sup>[8]</sup>. FSL cataract surgery witnessed increasing emerging evidence of reduced phacoemulsification time, better wound architecture, greater precision and accuracy of the anterior capsulotomy, as well as more stable and predictable positioning of the intraocular lens<sup>[4,9-12]</sup>.

In this study, we focus on capsulotomy, to review FSL capsulotomy versus manual CCC in cataract surgery, and assessed the precision and safety of the two techniques in a Meta-analysis approach.

**MATERIALS AND METHODS**

**Search Strategy** We searched PubMed, EMBASE, Web of Science, the Cochrane Library databases for articles published between January 1, 2009 to September 30, 2014, and Clinical Trials. gov. The database keywords were: capsulorhexis/capsulotomy, CCC, FSL, laser capsulotomy, phacoemulsification, cataract surgery. We manually searched the references of all potentially relevant articles to identify studies not found by the electronic searches. We did not contact authors of the primary studies for additional information. The search strategy did not include language and FSL platforms restriction. Searches were performed independently by 2 reviewers (Qian DW and Jin SL).

**Inclusion and Exclusion Criteria** Two reviewers (Qian DW and Jin SL) independently initially scanned the titles and abstracts to identify those that fulfilled the inclusion criteria: randomized controlled trials (RCTs) and non-RCTs that compared FSL capsulotomy versus manual CCC: morphology (diameter and circular) of capsulotomy. The rate of intraoperative anterior capsule tears. Patients older than 18y with insertion of a posterior chamber IOL in routine cataract surgery were enrolled in the study. Exclusion criteria: case reports, case series and studies that do not report primary data such as editorials and non-systematic reviews.

**Data Collection** Two reviewers (Qian DW and Jin SL) independently performed the data extraction that met the inclusion criteria. We removed duplicate records and obviously irrelevant titles and abstracts at this stage. We obtained full-text copies of any report referring to definitely or possibly relevant trials. Results were compared and any discrepancies between the reviewers' results were resolved by discussion (Qian DW and Jin SL), and if disagreements between the 2 reviewers arose, a third reviewer (Guo HK) was consulted. A customized form was used to record 1) the author of each study; 2) year of publication; 3) the country in which the study was conducted; 4) the number of eyes; 5) diameter of capsulotomy; 6) circularity of capsulotomy; 7) tears of anterior capsule.

**Quality Assessment of the Retrieved Articles** Studies were assessed for quality by means of the Downs and Black checklist [13]. It has been found to be valid and reliable for critically evaluating experimental and nonexperimental studies [14-15]. The criteria of the study's power was omitted because few studies reported. Scoring on the modified version could range between 0 and 27, with a higher score indicating higher methodological quality. The quality of each study was considered excellent (21-23), good (15-20), fair (10-14), and poor ( $\leq 9$ ) [16]. Scoring was performed independently by two researchers (Qian DW and Jin SL), and disagreements were resolved through discussion with a third researcher (Guo HK).

**Statistical Analysis** The data of both FSL capsulotomy and manual CCC on diameter, circularity and the rate of capsule tears were aggregated, the means and standard deviations of diameter and circularity were used to calculate the estimated mean difference (MD) between groups, the pooled odds ratio (OR) and 95%CI were performed. Continuity correction of 0.5 in studies with zero frequencies.

The Chi-square and  $I^2$  tests were used to assess the heterogeneity of the studies [17]. A random effects model was chosen because the trials with patients from the clinical centers have varying risk profiles and selection criteria. The 11 studies in our Meta-analysis differed in design and FSL platform, which was a potential source of heterogeneity between studies.

Potential publication bias was evaluated using the funnel graph. Asymmetry in such plots simplifies the existence of bias, which is usually publication bias due to nonpublication of small studies with negative results. Overall we considered the trials at risk of performance and detection bias because it was difficult to mask patients and outcome assessors, it was also difficult to assess the role of reporting bias. All analyses were performed using STATA version 12.0 (StataCorp, College Station, Texas, USA). A  $P$  value  $< 0.05$  was considered significant. Figures drafted using R software (Version 3.1.2) [18].

**RESULTS**

**Search Result and Study Characteristics** The electronic searches yielded a total of 453 records. After adjusting for duplicates, 346 different studies were identified, 315 were excluded on the basis of their abstracts for not meeting the primary inclusion criteria as described earlier. We obtained full-text copies of 31 records for further investigation. After assessing the full-text of the 31 potentially relevant articles. We identified 12 eligible studies for analysis [4,11,12,19-27]: two reporting on the same subjects [19,23], the report with higher quality and the most recent publication was selected [19]. Of them, two studies were conducted in the United States, five in Europe, three in Australia, and one in Mexico. These studies comprised four RCTs [12,20,22,26], seven prospective nonrandomized comparative studies [4,11,19,21,24-25,27]. It involved altogether 2941 eyes, of which 1527 (51.92%) underwent FSL capsulotomy and 1414 (48.08%) manual CCC. Five studies reported the diameter, six reported the circularity of the capsulotomy, and six reported the rate of anterior capsule tears (complication), five did not mention any of them. The characteristics of the included studies are presented in Table 1. Table 2 summarizes the quality of the 11 studies. Their quality scores ranged from 17 to 20, with an average of  $18.27 \pm 0.90$ . Based on the Quality Assessment Score (QAS), all studies were rated good. In surgical research, it was difficult to mask patients and outcome assessors, the criteria of blind and measuring were zero in all the included studies, which was a potential heterogeneity between studies.

**Table 1 Characteristics of 11 includes**

Study (first author, year)	Country	Study design	n		Diameter		Circularity		Tears	
			FSL	CCC	FSL	CCC	FSL	CCC	FSL	CCC
Schultz T, 2014 <sup>[25]</sup>	Germany	Case control	50	50	0.99±0.03	0.98±0.34	0.95±0.02	0.81±0.07	-	-
Reddy KP, 2013 <sup>[20]</sup>	Germany	RCT	56	63	1.02±0.05	0.93±0.09	0.97±0.02	0.92±0.05	1	1
Tackman RN, 2011 <sup>[21]</sup>	Mexico	Case control	49	24	0.97±0.18	0.92±0.53	-	-	-	-
Kranitz K, 2011 <sup>[11]</sup>	Hungary	Case control	20	20	1.01±0.15	1.04±0.42	0.86±0.01	0.83±0.02	-	-
Friedman NJ, 2011 <sup>[4]</sup>	USA	Case control	39	23	0.99±0.03	0.93±0.26	0.94±0.04	0.80±0.15	0	0
Nagy ZZ, 2011 <sup>[22]</sup>	Hungary	RCT	54	57	-	-	0.86±0.04	0.85±0.03	-	-
Palanker DV, 2010 <sup>[12]</sup>	USA	RCT	29	30	-	-	0.95±0.04	0.77±0.15	-	-
Abell RG, 2014 <sup>[19]</sup>	Australia	Case control	804	822	-	-	-	-	15	1
Abell R, 2012 <sup>[24]</sup>	Australia	Case control	200	200	-	-	-	-	1	1
Conrad-Hengerer I, 2013 <sup>[26]</sup>	Germany	RCT	75	75	-	-	-	-	0	1
Abell RG, 2013 <sup>[27]</sup>	Australia	Case control	151	50	-	-	-	-	0	0

FSL: Femtosecond laser capsulotomy; CCC: Manual continuous curvilinear capsulotomy; RCT: Randomized controlled trial; “-”: Unrelated.

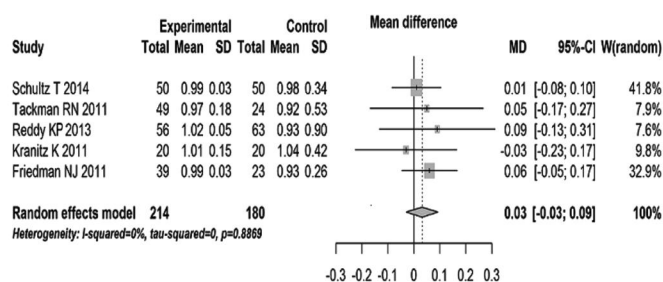
**Table 2 Scores of Downs and Black scale**

Studies (first author, year)	Reporting	External validity	Internal validity bias	Internal validity confounding	Total scores
Schultz T, 2014 <sup>[25]</sup>	9	3	4	2	18
Reddy KP, 2013 <sup>[20]</sup>	10	3	4	3	20
Tackman RN, 2011 <sup>[21]</sup>	8	3	4	2	17
Kranitz K, 2011 <sup>[11]</sup>	9	3	4	2	18
Friedman NJ, 2011 <sup>[4]</sup>	9	3	4	2	18
Nagy ZZ, 2011 <sup>[22]</sup>	9	3	4	3	19
Palanker DV, 2010 <sup>[12]</sup>	8	3	4	3	18
Abell RG, 2014 <sup>[19]</sup>	9	3	4	3	19
Abell R, 2012 <sup>[24]</sup>	8	3	4	2	17
Conrad-Hengerer I, 2013 <sup>[26]</sup>	9	3	4	3	19
Abell RG, 2013 <sup>[27]</sup>	9	3	4	2	18

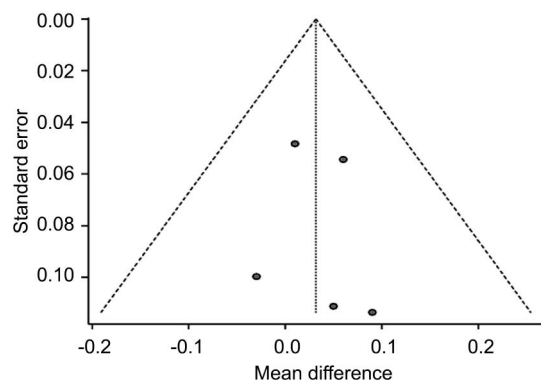
**Diameter** Five studies provided data<sup>[4,11,20-21,25]</sup> for calculating the MD of capsulotomy diameter (Figure 1). There was no statistically significant difference in the diameter between FSL and manual CCC groups (MD=0.03; 95%CI, -0.03 to 0.09,  $P=0.31$ ). The studies were characterized by low heterogeneity ( $I^2=0$ ,  $\tau^2=0$ ,  $P=0.8869$ ). The funnel plot was symmetric, with no evidence of a relevant small study bias (Figure 2).

**Circularity** Six studies provided data<sup>[4,11-12,20,22,25]</sup> for calculating the MD of capsulotomy circularity (Figure 3). There was a statistically significant difference in the circular between FSL capsulotomy and manual CCC groups (MD=0.09; 95% CI, 0.05 to 0.12,  $P<0.001$ ). The studies were characterized by high heterogeneity ( $I^2=96.2\%$ ,  $\tau^2=0.0019$ ,  $P<0.0001$ ). A subgroup analysis showed no significant differences in studies between RCTs studies and the case control studies ( $P=0.56$ ), still with high heterogeneity ( $I^2=92.9\%$  and  $98\%$ ).

**Anterior Capsule Tear** Six studies<sup>[4,19-20,24,26-27]</sup> reported capsule tears intraoperative (Figure 4). Two reported zero<sup>[4,27]</sup>. The incidence of anterior capsule tear was 17 of 1325 eyes (1.28%) in FSL group compared with 4 of 1233 eyes



**Figure 1 Forest plot comparing of diameter in femtosecond laser capsulotomy (experimental) versus that in manual CCC (control).**



**Figure 2 Funnel plot of publication bias of diameter.**

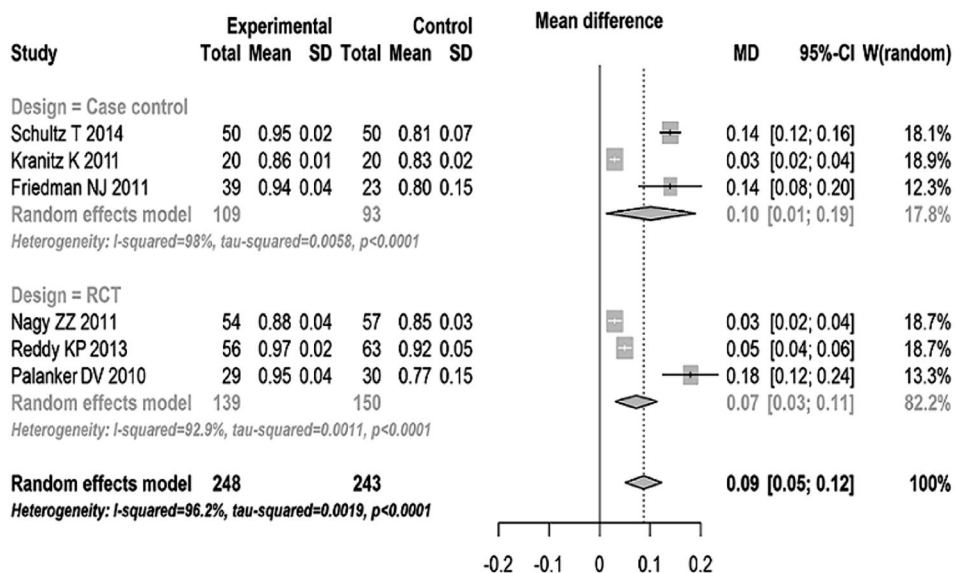


Figure 3 Forest plot comparing overall effect of circularity with femtosecond laser capsulotomy (experimental) versus manual CCC (control).

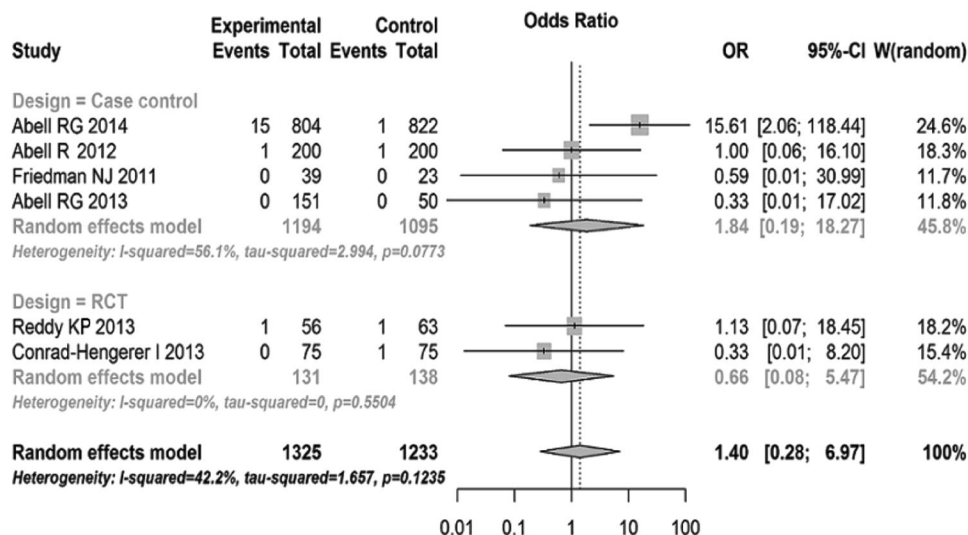


Figure 4 Conventional computation overall effect of the OR and 95% CI on tears with femtosecond laser capsulotomy (experimental events) versus manual CCC (control events).

(0.32%) in manual group. Meta-analysis shows no statistically significant difference between the FSL and manual groups (OR=1.40; 95% CI, 0.28 to 6.97,  $P=0.68$ ). Moderate heterogeneity was identified in this analysis ( $I^2=42.2%$ ,  $\tau^2=1.657$ ,  $P=0.1235$ ). A subgroup analysis showed no significant differences between RCTs studies and the case control studies ( $P=0.52$ ). The heterogeneity was moderate in case control ( $I^2=56.1%$ ) and low in RCTs studies ( $I^2=0$ ).

**DISCUSSION**

Femtosecond lasers are able to create exquisitely precise, customizable incisions in ocular tissue without collateral damage [28]. The results of FSL applications in cataract surgery for more than 4y are promising [29-30]. Recently a study found a significantly higher rate of anterior capsule tears in FSL capsulotomy [19], thus we performed a Meta-analysis to compare the diameter and circularity of capsulotomy, and rate of anterior capsule tears between FSL and manual CCC

to assess the new technology of FSL in capsulotomy.

A precise and well-performed capsulotomy can improve the steps of cataract extraction, and reduce complications [31]. Variations in size of the capsulorhexis can result in aberrant IOL position [32]. The size and shape of the capsulorhexis therefore are key determinants in both position and performance of IOL [25], but they can be variable. A 360° overlapping capsular edge is thought to be an important factor for standardizing refractive results by keeping the IOL in the desired center position. The overlap sets not only the horizontal-vertical but also the anteroposterior positioning of the IOL [32]. Because the data of diameter came from  $(d_{\text{major/horizontal}} + d_{\text{minor/vertical}}) / 2$ , there was little difficulty for the experienced surgeons to perform a capsulorhexis in order to attain the size and shape that they want through manual technique. So in the five studies of diameter, there was no statistical significant difference in diameter of capsulotomy

between FSL and manual CCC groups. The contour of the capsulorhexis was ellipse and asymmetric in manual CCC. The mean deviation of capsule diameter from intended diameter was  $0.18 \pm 0.17$  mm and significantly less in buttons created using FSL compared with the mean deviation of  $0.53 \pm 0.54$  mm among buttons constructed using manual CCC in Tackman's study [21]. Friedman [4] demonstrated the deviation from the intended diameter of capsule button was  $29 \pm 26$   $\mu$ m using FSL and  $337 \pm 258$   $\mu$ m using manual CCC. So the overlap of the capsule on the IOL was better in FSL than in manual CCC, the difference is significant (SMD = -1.29,  $P < 0.0001$ ).

Besides the proper size, a perfect anterior capsule opening has to be resistant to prevent capsular tears during surgery [33]. Circularity is a parameter used to determine the regularity of the shape of the capsulotomy. In the six studies of circularity [4,11-12,20,22,25], the values of 1.0 indicate a perfect circle. In Schultz *et al*'s [25] study, the capsule disk samples of the FSL group were closer to an ideal roundness of 1. Very little variation was observed in circularity in the FSL group and a greater variation in the manual CCC groups. Palanker *et al* [12] reported similar results. An essential aspect of the femtosecond laser cataract surgery is the integrated OCT that performs 3-D mapping of the cornea and lens. The system automatically aligns all incision patterns in 3-D to follow the contour of ocular structures, which minimizes the degree of required cutting overlaps and optimizes the safety zone distances. This critical feature guarantees safe, precise, and reproducible placement of the cutting patterns within the target tissue [4]. So the FSL may be able to provide a more circular, stronger, precisely planned and executed capsulorhexis, which could offer more control over capsulotomy unpredictability and more accurate refractive outcomes than manual CCC [34]. Studies have demonstrated that a better visual acuity was found in the patients treated with femtosecond laser comparing to those treated with conventional cataract surgery in one year follow-up ( $P < 0.05$ ) [9]. Although, the other study found post-operative CDVA was  $0.97 \pm 0.08$  in the FSL group and  $0.97 \pm 0.06$  in the conventional group ( $P > 0.05$ ). But the FSL group had significantly lower values of intraocular vertical tilt ( $-0.50 \pm 0.36$  vs  $0.27 \pm 0.57$ ) and coma ( $-0.003 \pm 0.11$  vs  $0.1 \pm 0.15$ ;  $P = 0.006$ ) [10]. Anterior tear of the capsule is a significant complication in cataract surgery. Radial tears in turn may lead to a series of complications such as zonular rupture, posterior capsular tear, vitreous presentation, insufficient capsular support for IOL implantation, or even nucleus drop during phacoemulsification [2]. Evidence-based guidelines for cataract surgery suggest a capsule complication frequency of  $< 2\%$  should be possible and desirable to achieve [35]. In the included six studies of tear [4,19-20,24,26-27], the anterior capsule tear rates from 0 to 1.87% in FSL groups versus 0 to 1.6% in

manual groups. Abell *et al* [19] reported 15 cases of anterior capsule tear, 7 anterior capsule tear extended to the posterior capsule and required sulcus IOL implantation. Five of these patients had no vitreous loss, whereas the remaining 2 patients underwent an anterior and posterior vitrectomy, respectively. And 1 case in manual CCC, the surgery procedure was evenly. During Roberts *et al* [30] early experiences, the anterior capsule tear rates was 4%, and degraded to 0.31% when experienced. There was a clear learning curve associated with the use of FSL for cataract surgery [36]. Study found that little manual manipulation was needed in 96% of cases during removal of the capsule, indicating that a free-floating capsule was generated by the FSL [21]. The Meta-analysis did not reveal any statistically significant difference between the tears of the capsule from FSL groups and these from manual CCC group ( $P = 0.68$ ). These findings should be interpreted cautiously because Abell *et al* [19] was a multicenter study, where different techniques and experience may introduce several variables. While other studies were single surgeon completed the surgery in every study. Under scanning electron microscope, compared with the smooth edges of the manual CCC capsule disk, the FSL capsule disk edge has a wave-like structures or postage-stamp perforations [19,25,37]. This can lead to an increased rate of anterior capsule tears.

Potential limitations of this study should be considered. First because of retraction of the capsular bag, the diameter of the excised capsulorhexis was slightly smaller than the in situ diameter of the capsule cut. Second limitation is predefined study population of each study. All studies excluded eyes with ocular diseases, some studies even excluded patients with systemic diseases (*e.g.* rheumatic disease). As a result, the findings in this Meta-analysis are only valid for patients meeting these criteria and initially having good prognostic factors for visual outcome and complications. Another limitation is the high heterogeneity in terms of circularity. When we analyzed RCTs and Case control respectively, the heterogeneity was still high. As we did not restrict laser platform, each company used different measurement techniques for capsulotomy shape. As a result a comparison is not easily assessed [8], and unknown sources of clinical variation of the impact of circularity by unmeasured confounders and methodological issues. Further, future studies, especially multicenter prospective randomized controlled studies should be matched for FSL platform, FSL energy setting, lens grades, surgeon's experience, and study designs to make valid comparisons between studies.

In conclusion, the data from the Meta-analysis do not indicate an advantage of FSL over manual CCC. Overall, the use of the femtosecond laser in cataract surgery resulted in a better capsulorhexis geometry and circularity than manual CCC.

ACKNOWLEDGEMENTS

**Conflicts of Interest:** Qian DW, None; Guo HK, None; Jin SL, None; Zhang HY, None; Li YC, None.

REFERENCES

1 Uy HS, Edwards K, Curtis N. Femtosecond phacoemulsification: the business and the medicine. *Curr Opin Ophthalmol* 2012;23(1):33–39.

2 Mohammadpour M, Erfanian R, Karimi N. Capsulorhexis: Pearls and pitfalls. *Saudi J Ophthalmol* 2012;26(1):33–40.

3 Sanders DR, Higginbotham RW, Opatowsky IE, Confino J. Hyperopic shift in refraction associated with implantation of the single-piece Collamer intraocular lens. *J Cataract Refract Surg* 2006;32(12):2110–2112.

4 Friedman NJ, Palanker DV, Schuele G, Andersen D, Marcellino G, Seibel BS, Batlle J, Feliz R, Talamo JH, Blumenkranz MS, Culbertson WW. Femtosecond laser capsulotomy. *J Cataract Refract Surg* 2011; 37 (7): 1189–1198.

5 Walkow T, Anders N, Pham DT, Wollensak J. Causes of severe decentration and subluxation of intraocular lenses. *Graefes Arch Clin Exp Ophthalmol* 1998;236(1):9–12.

6 Ravalico G, Tognetto D, Palomba M, Busatto P, Baccara F. Capsulorhexis size and posterior capsule opacification. *J Cataract Refract Surg* 1996;22 (1):98–103.

7 Sugar A. Ultrafast (femtosecond) laser refractive surgery. *Curr Opin Ophthalmol* 2002;13(4):246–249.

8 He L, Sheehy K, Culbertson W. Femtosecond laser-assisted cataract surgery. *Curr Opin Ophthalmol* 2011;22(1):43–52.

9 Kranitz K, Mihaltz K, Sandor GL, Takacs A, Knorz MC, Nagy ZZ. Intraocular lens tilt and decentration measured by Scheimpflug camera following manual or femtosecond laser-created continuous circular capsulotomy. *J Refract Surg* 2012;28(4):259–263.

10 Mihaltz K, Knorz MC, Alio JL, Takacs AI, Kranitz K, Kovacs I, Nagy ZZ. Internal aberrations and optical quality after femtosecond laser anterior capsulotomy in cataract surgery. *J Refract Surg* 2011;27(10):711–716.

11 Kranitz K, Takacs A, Mihaltz K, Kovacs I, Knorz MC, Nagy ZZ. Femtosecond laser capsulotomy and manual continuous curvilinear capsulorhexis parameters and their effects on intraocular lens centration. *J Refract Surg* 2011;27(8):558–563.

12 Palanker DV, Blumenkranz MS, Andersen D, Wiltberger M, Marcellino G, Gooding P, Angeley D, Schuele G, Woodley B, Simoneau M, Friedman NJ, Seibel B, Batlle J, Feliz R, Talamo J, Culbertson W. Femtosecond laser-assisted cataract surgery with integrated optical coherence tomography. *Sci Transl Med* 2010;2(58):58ra85.

13 Downs SH, Black N. The feasibility of creating a checklist for the assessment of the methodological quality both of randomised and non-randomised studies of health care interventions. *J Epidemiol Community Health* 1998;52(6):377–384.

14 Altman DG, Burton MJ. The cochrane collaboration. *Langenbecks Arch Surg* 1999; 384(5):432–436.

15 Saunders LD, Soomro GM, Buckingham J, Jamtvedt G, Raina P. Assessing the methodological quality of nonrandomized intervention studies. *West J Nurs Res* 2003;25(2):223–237.

16 Liang GL, Wu J, Shi JT, Liu J, He FY, Xu W. Implantable collamer lens versus iris-fixed phakic intraocular lens implantation to correct myopia: a meta-analysis. *PLoS One* 2014;9(8):e104649.

17 Higgins JP, Thompson SG, Deeks JJ, Altman DG. Measuring inconsistency in meta-analyses. *BMJ* 2003; 327(7414):557–560.

18 R. Core Team, R: A language and environment for statistical computing. R Foundation for Statistical Computing. Vienna, Austria. <https://www.R-project.org/> 2014

19 Abell RG, Davies PE, Phelan D, Goemann K, McPherson ZE, Vote BJ.

Anterior capsulotomy integrity after femtosecond laser-assisted cataract surgery. *Ophthalmology* 2014;121(1):17–24.

20 Reddy KP, Kandulla J, Auffarth GU. Effectiveness and safety of femtosecond laser-assisted lens fragmentation and anterior capsulotomy versus the manual technique in cataract surgery. *J Cataract Refract Surg* 2013;39(9):1297–1306.

21 Tackman RN, Kuri JV, Nichamin LD, Edwards K. Anterior capsulotomy with an ultrashort-pulse laser. *J Cataract Refract Surg* 2011;37(5):819–824.

22 Nagy ZZ, Kranitz K, Takacs A, Mihaltz K, Kovacs I, Knorz MC. Comparison of intraocular lens decentration parameters after femtosecond and manual capsulotomies. *J Refract Surg* 2011; 27(8):564–569.

23 Abell RG, Davies PEL, Bylsma G, Phelan D, Goemann K, Vote BJ. Does the femtosecond laser cut the anterior capsule in a safe and accurate way? *Clinical and Experimental Ophthalmology* 2013; 41:64–65.

24 Abell R, Kerr N, Vote B. Catalys femtosecond laser pretreatment in cataract surgery compared to conventional phacoemulsification cataract surgery. *Clinical and Experimental Ophthalmology* 2012; 40:52–53.

25 Schultz T, Joachim SC, Tischoff I, Dick HB. Histologic evaluation of in vivo femtosecond laser-generated capsulotomies reveals a potential cause for radial capsular tears. *Eur J Ophthalmol* 2014;25(2):112–118

26 Conrad-Hengerer I, Al JM, Schultz T, Hengerer FH, Dick HB. Corneal endothelial cell loss and corneal thickness in conventional compared with femtosecond laser-assisted cataract surgery: three-month follow-up. *J Cataract Refract Surg* 2013;39(9):1307–1313.

27 Abell RG, Kerr NM, Vote BJ. Toward zero effective phacoemulsification time using femtosecond laser pretreatment. *Ophthalmology* 2013;120 (5): 942–948.

28 Trikha S, Turnbull AM, Morris RJ, Anderson DF, Hossain P. The journey to femtosecond laser-assisted cataract surgery: new beginnings or a false dawn? *Eye (Lond)* 2013;27(4):461–473.

29 Nagy Z, Takacs A, Filkorn T, Sarayba M. Initial clinical evaluation of an intraocular femtosecond laser in cataract surgery. *J Refract Surg* 2009;25 (12):1053–1060.

30 Roberts TV, Lawless M, Bali SJ, Hodge C, Sutton G. Surgical outcomes and safety of femtosecond laser cataract surgery: a prospective study of 1500 consecutive cases. *Ophthalmology* 2013;120(2):227–233.

31 Ostovic M, Klaproth OK, Hengerer FH, Mayer WJ, Kohnen T. Light microscopy and scanning electron microscopy analysis of rigid curved interface femtosecond laser-assisted and manual anterior capsulotomy. *J Cataract Refract Surg* 2013;39(10):1587–1592.

32 Cekic O, Batman C. The relationship between capsulorhexis size and anterior chamber depth relation. *Ophthalmic Surg Lasers* 1999;30 (3): 185–190.

33 Artzen D, Lundstrom M, Behndig A, Stenevi U, Lydahl E, Montan P. Capsule complication during cataract surgery: case-control study of preoperative and intraoperative risk factors: Swedish Capsule Rupture Study Group report 2. *J Cataract Refract Surg* 2009;35(10):1688–1693.

34 Moshirfar M, Churgin DS, Hsu M. Femtosecond laser-assisted cataract surgery: A current review. *Middle East Afr J Ophthalmol* 2011;18 (4): 285–291.

35 Lundstrom M, Barry P, Henry Y, Rosen P, Stenevi U. Evidence-based guidelines for cataract surgery: guidelines based on data in the European Registry of Quality Outcomes for Cataract and Refractive Surgery database. *J Cataract Refract Surg* 2012;38(6):1086–1093.

36 Bali SJ, Hodge C, Lawless M, Roberts TV, Sutton G. Early experience with the femtosecond laser for cataract surgery. *Ophthalmology* 2012;119 (5):891–899.

37 Schultz T, Tischoff I, Ezeanosike E, Dick HB. Histological sections of corneal incisions in OCT-guided femtosecond laser cataract surgery. *J Refract Surg* 2013;29(12):863–864.