

# A modified approach to actively remove high viscosity silicone oil through 23-gauge cannula

Zong-Ming Song<sup>1</sup>, Xu-Ting Hu<sup>1</sup>, Lei Wang<sup>1</sup>, Zhi-Xiang Hu<sup>1</sup>, Pei-Quan Zhao<sup>2</sup>, Ding Chen<sup>1</sup>

<sup>1</sup>Eye Hospital, Wenzhou Medical University, Wenzhou 325027, Zhejiang Province, China

<sup>2</sup>Xin Hua Hospital Affiliated to Shanghai Jiao Tong University School of Medicine, Shanghai 200092, China

**Correspondence to:** Ding Chen. Eye Hospital, Wenzhou Medical University, 270 Xueyuan Road, Wenzhou 325027, Zhejiang Province, China. necoding@126.com

Received: 2015-12-12 Accepted: 2016-02-26

## Abstract

• **AIM:** To report a simple approach to actively remove high viscosity silicone oil through a 23-gauge cannula *via* pars plana.

• **METHODS:** Forty-eight eyes of 48 patients underwent silicone oil (5700 centistokes) removal (SOR) were enrolled. A section of blood transfusion set was prepared to connect a standard 23-gauge cannula and vitrectomy machine. Silicone oil was removed with suction of 500-mm Hg vacuum through the cannula. Main outcome measures were SOR duration, number of sutured sites, intraocular pressure (IOP), best-corrected visual acuity (BCVA), and complications.

• **RESULTS:** Silicone oil was successfully removed in all cases. The mean SOR time was 5.70±0.85min. Nine eyes (18.75%) needed suture partial sclerotomies. No intraoperative complications were noted. Transient hypotony ( $\leq 8$  mm Hg) was seen in 3 eyes (6.25%) on postoperative day 1, but all resolved within 1wk. Retinal reattachment was achieved in all cases and no other postoperative complications were noted during 3-month following-up. BCVA at the final visit improved or stabilized in all patients comparing to the preoperative level.

• **CONCLUSION:** Active removal of high viscosity silicone oil through a 23-gauge instrument cannula jointed with blood transfusion set is a practical and reliable technique when considering two sides of efficacy and safety.

• **KEYWORDS:** silicone oil; active removal; 23-gauge; pars plana

**DOI:10.18240/ijo.2016.09.10**

Song ZM, Hu XT, Wang L, Hu ZX, Zhao PQ, Chen D. A modified approach to actively remove high viscosity silicone oil through 23-gauge cannula. *Int J Ophthalmol* 2016;9(9):1294-1298

## INTRODUCTION

Silicone oil tamponade is commonly used for complex cases during pars plana vitrectomy (PPV). Long term use of silicone oil may lead to complications such as cataract, glaucoma, band keratopathy and toxicity to the retina [1-5]. Therefore, silicone oil should be removed later once the objectives of the tamponade have been achieved and the retinal status is stable. Several surgical techniques have been introduced to remove the silicone oil [6-8].

The 23-gauge transconjunctival sutureless vitrectomy, first introduced by Eckardt [9] in 2005, is one of the most important advances in vitreoretinal surgical techniques in recent years and has gained wide popularity rapidly. Comparing to traditional 20-gauge sclerotomies, 23-gauge sclerotomies have the advantages of sutureless, less surgical trauma and less postoperative discomfort. Several approaches to remove the silicone oil using 23-gauge sutureless vitrectomy system have been reported, either by passive drainage or by active suction [10-13]. The passive approach is usually time consuming and more suitable for extracting silicone oil of lower viscosity. For active approach, a specially designed 23-gauge silicon cannula was adopted to remove silicone oil *via* pars plana. However, this special silicon cannula is relatively costly and not easily available in the developing country such as China. We reported an alternative approach for active removal of silicone oil *via* pars plana through a regular 23-gauge instrument cannula [14]. In that method, different auxiliary materials were needed as tube adaptors to connect the cannula and the silicone vacuum tube, depending on different types of trocar-cannula systems, which limited the applicability of this method.

In this study, we develop a modified technique to actively remove high viscosity silicone oil through 23-gauge cannula *via* pars plana, and make it universally applicable to almost all types of trocar-cannula systems. The efficiency and safety of this new technique is evaluated.

## SUBJECTS AND METHODS

**Subjects** The study included 48 eyes of 48 patients who underwent silicone oil removal (SOR) *via* pars plana in the Eye Hospital of Wenzhou Medical University between October 2013 and December 2014. The design of the study was approved by the Institutional Review Board of Wenzhou Medical University. Informed consent form was signed by all patients before the procedure, and all data were collected in accordance with the Declaration of Helsinki.

All patients accepted their previous 23-gauge transconjunctival sutureless vitrectomy surgeries in the same hospital. The indications for vitrectomy and silicone oil [5700 centistokes (cSt)] injection were rhegmatogenous retinal detachment (RRD), proliferative vitreoretinopathy (PVR), diabetic retinal detachment (DTRD), and severe ocular trauma with traumatic retinal detachment (TRD) or choroidal detachment (CD). The indication for SOR was the attachment of retina and the stability of silicone oil tamponade for at least 3mo.

**Methods** All procedures were performed under retrobulbar anesthesia with a 50% mixture of lidocaine 2% and bupivacaine 0.75% by the same surgeon (Song ZM). 23-gauge cannulas were placed using the one-step technique with a trocar-cannula system [either Alcon (Fort Worth, TX, USA), or Bausch & Lomb (Rochester, NY, USA), or DORC (Zuidland, Holland), or MID Labs (San Leandro, CA, USA)]. In order to purposefully misalign the conjunctival and scleral incisions, the conjunctiva was slightly displaced away from the intended sclerotomy site with forceps. A trocar was then inserted parallel to the limbus with the bevel up at an angle of approximately 30 degrees. The angle was changed to perpendicular to surface and the cannula was inserted into the eye once past the trocar sleeve. The trocar was removed while the cannula was held in place with forceps. The sclerotomy was first made in the inferotemporal region to establish the infusion. After the infusion line was opened and the intraocular pressure was maintained at 25-30 mm Hg, 1 or 2 sclerotomies were made in the superotemporal and/or superonasal regions.

One instrument cannula was utilized for SOR, either at the superonasal or superotemporal region, depending on the surgeon's preference. Remaining cannula was closed by plug during SOR. A disposable blood transfusion set (Model 04-003, Shanghai Kindly Enterprise Development Group, Shanghai, China) was prepared to connect to the vitrectomy machine [either Accurus 800cs (Alcon Laboratories Inc, Fort.Worth, TX, USA), or Stellaris PC (Bausch & Lomb Incorporated, Rochester, NY, USA)] and worked as the vacuum tube (Figure 1). Both ends of the blood transfusion set were cut off with a scissor at the locations as marked in Figure 1A. Location 1 should be cut perpendicularly to the tube and kept the cross section as smooth as possible (Figure 1B). Location 2 should be cut at an angle of approximately 45 degrees parallel to the tube (Figure 1C) for the ease of insertion when connected to the vitrectomy machine with a short section of silicon tube (Figure 1D). The blood chamber of the transfusion set worked as the silicone oil collecting chamber (Figure 1E). If the cannula sleeve has closure valve, then it should be removed before connecting to the transfusion tube (Figure 2A). The internal diameter of the transfusion tube is 3.0 mm which is slightly larger than the

external diameter of the cannula, therefore subtle gap existed in-between when the two components were connected. The flat end of the tube was held in place by the surgeon and gentle pressure was exerted against the eye wall during the SOR procedure. The tube could be sucked onto the eye wall under vacuum aspiration and watertight/airtight effect could be achieved (Figure 2B). The silicone oil was then removed actively with suction of 500-600 mm Hg vacuum through the 23-gauge cannula (lumen diameter: 0.65 mm) using vitrectomy machine. When oil bubble was shown at the end of removal, eyeball was tilted to remove it completely and the vacuum was decreased accordingly to prevent eyeball collapse. After removal of all silicone oil, the intraocular pressure was maintained at 20-25 mm Hg and retinal status was carefully checked with a light probe. Other procedures such as endo-laser and membrane peeling were performed if necessary through the cannula (s) (Figure 2C). Phacoemulsification with foldable posterior chamber intraocular lens (PC-IOL) implantation was performed before SOR in the phakic eye, while PC-IOL implantation was performed after SOR in the aphakic eye. After fluid-air exchange, cannulas were removed and the entry site was checked for any sign of leakage (Figure 2D). If leakage was indicated by the formation of a subconjunctival bleb, a sterile cotton-tip applicator was applied to the site with pressure until leakage ceased. The wound would be sutured to if the leakage continued beyond 1min.

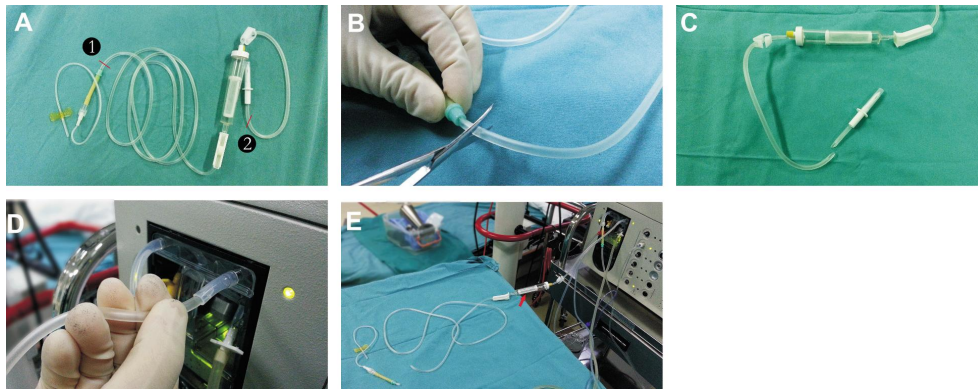
The surgical duration, SOR duration, number of sutured 23-gauge sclerotomy sites, presence of intra-operative complications, postoperative hypotony (IOP  $\leq$  8 mm Hg) and any other postoperative complications were recorded. The baseline data was also recorded. Patients were followed up on 1d, 1wk, 1 and 3mo after surgery. The postoperative ophthalmic examinations included the best-corrected visual acuity (BCVA), slit-lamp examination, IOP, and indirect ophthalmoscopy.

**Statistical Analysis** SPSS 16.0 for Windows software program was used for the statistical analysis. The experimental data were expressed as the mean  $\pm$  standard deviation or the median and range. Analysis of variance, paired *t*-tests were used as appropriate. *P* value  $<$ 0.05 is considered to be statistically significant.

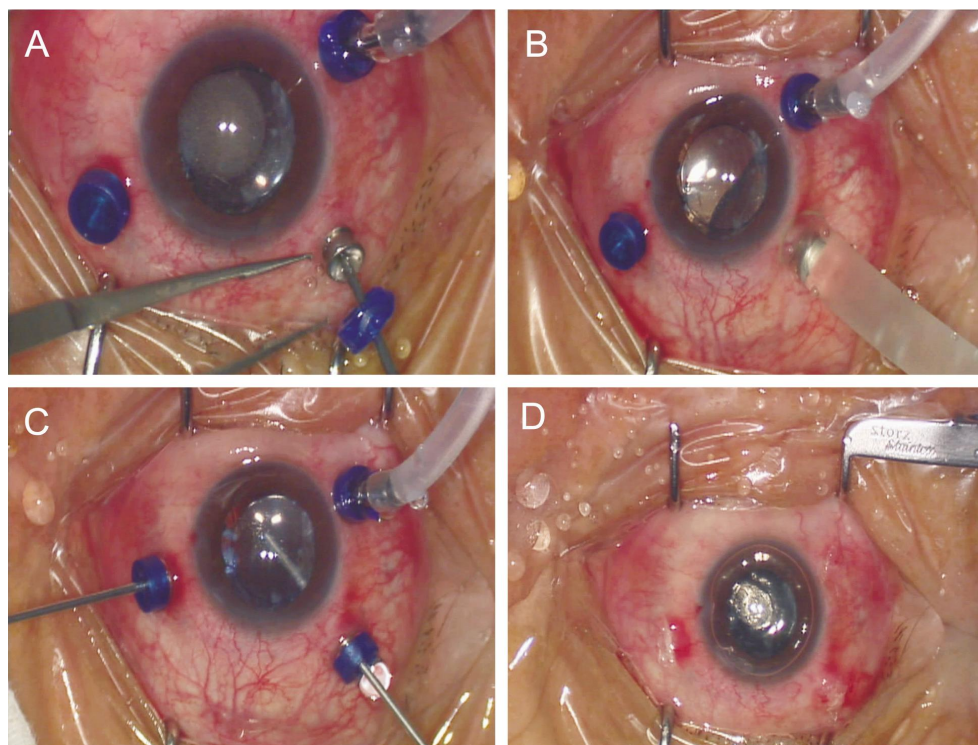
## RESULTS

The mean ( $\pm$ SD) age of 27 male and 21 female patients was 54.47  $\pm$  9.93y. The mean interval between PPV with silicone oil endotamponade and SOR was 5.27  $\pm$  1.41mo. Twelve eyes were phakic, 23 eyes were aphakic, and 13 eyes were pseudophakic with an intact posterior capsule. Each type of trocar-cannula system (Alcon, Bausch & Lomb, DORC, and MID Labs) was adopted in 12 eyes for SOR.

Silicone oil (5700 cSt) was removed completely from all eyes. The mean SOR time was 5.70  $\pm$  0.85min (range:



**Figure 1** The assembly of vacuum tube for SOR A: A section of a disposable blood transfusion set (between markers number 1 and number 2) was intercepted for connection; B: The lower end was cut perpendicularly to the tube and kept the cross section as flat and smooth as possible; C: The upper end was cut at an angle of approximately 45 degrees parallel to the tube and formed a beveled tip; D: The beveled tip was easily inserted into a short section of silicon tube when connected to the vitrectomy machine. E: The blood chamber of the transfusion set worked as the silicone oil collecting chamber (marked with an arrow).



**Figure 2** The main steps for SOR A: 23-gauge cannulas were placed using the one-step technique and infusion was established. The closure valve of the cannula sleeve was removed if necessary; B: The flat end of the tube was connected to the cannula sleeve and gentle pressure was applied against the eye ball during SOR. The tube was sucked onto the eye wall under vacuum aspiration; C: Additional procedures as needed were performed through the cannula (s) after SOR; D: Cannulas were removed after fluid-air exchange and the sclerotomy was left unsutured with no sign of leakage.

4.35-7.13min). There was no significant difference in SOR time among different types of trocar-cannula systems (all  $P > 0.05$ ). No intraoperative complications were documented. No suture placement after cannula removal was needed in any of the sclerotomies in 39 out of 48 eyes. Six eyes (12.50%) needed suture 1/3 of the sclerotomies and 3 eyes (6.25%) needed suture 2/3 of the sclerotomies. Patients were followed-up for a mean period of  $3.77 \pm 0.75$  mo. Upon the postoperative examinations, no clinically significant residual oil in the vitreous cavity or in the anterior chamber was observed in any eye.

The mean preoperative IOP was  $17.27 \pm 2.94$  mm Hg, and mean postoperative IOPs at 1d, 1wk, 1 and 3mo visits were  $10.13 \pm 2.31$  mm Hg,  $15.74 \pm 3.54$  mm Hg,  $15.70 \pm 2.66$  mm Hg, and  $14.67 \pm 2.30$  mm Hg, respectively. A significant decrease in IOP was found on postoperative day 1 comparing to the preoperative baseline ( $P = 0.001$ ). Postoperative hypotony ( $\leq 8$  mm Hg) was noted in 3 (6.25%) eyes on postoperative day 1, which resolved spontaneously within 1wk. Retinal reattachment was achieved in all cases (100%) after tamponade removal, and retina remained attached in all eyes at the end of the following-up period. No other postoperative

complications such as vitreous hemorrhage, CD, macular edema, endophthalmitis, or corneal endothelial decompensation were noted.

The BVCA improved in 39 (81.25%) eyes and remained unchanged in 9 (18.75%) eyes. The median preoperative BCVA was 20/800 (range: HM-20/100), and median postoperative BCVA at the final visit was 20/400 (range: CF/50 cm - 20/50) ( $P=0.01$ ).

## DISCUSSION

Silicone oil removal is one of the most common procedures in vitreoretinal surgery. Several techniques for silicone oil removal have been developed<sup>[6-7,10-11,14-15]</sup>. As a basic principle, the silicone oil is either removed passively through the sclerotomy port or by active suction while balanced saline solution is infused into the vitreous cavity to maintain the IOP. Silicone oil can be either removed through a superior limbal or clear corneal incision in aphakic eyes, however, this technique precludes any posterior segment manipulations. Traditionally, silicone oil is removed *via* pars plana and the conjunctival peritomy and sclerotomy need to be sutured at the end of the procedure. However, the dissections and sutures become more difficult and may result in incision leakage in eyes previously undergoing repeated vitreoretinal procedures. In addition, trauma to the conjunctiva and sclera in these eyes caused by reoperation may result in significant inflammation and discomfort after surgery.

The transconjunctival sutureless vitrectomy system introduced a new concept in vitreoretinal surgery as a less invasive technique<sup>[9]</sup>. Kapran and Acar<sup>[15]</sup> introduced an approach for passive drainage of silicone oil through two instrument cannulas with 25-gauge transconjunctival sutureless vitrectomy system. However, it was only suitable for removal of silicone oil with low viscosity (*e.g.* 1000 cSt), for removal of silicone oil with high viscosity (*e.g.* 5700 cSt) it would be very time-consuming. They then developed an approach for active removal of silicone oil through two specially designed 25-gauge cannulas, which was claimed to be more efficient for both 1000 and 5000 cSt silicone oils<sup>[16]</sup>. In order to increase the efficiency, two vacuum tubes were connected to two cannulas with a three-way stopcock. In this approach, it still took about 10min for removal of 5000 cSt silicone oil. A 23-gauge silicone cannula designed to inject and aspirate silicone oil is commercially available (PolyTip VFI Cannula, MedOne Surgical, Sarasota, FL, USA). Romano *et al*<sup>[11]</sup> utilized this type of silicone cannula on a 23-gauge transconjunctival sutureless vitrectomy system to remove heavy silicone oil (Densiron-68, gravity of 1.06 g/cm<sup>3</sup>, and viscosity of 1387 cSt) *via* pars plana. However, the silicone cannula needs to enter through the 23-gauge cannula, which makes the effective lumen decreased. The resistance to flow is inversely related by a factor of four to

the lumen radius, and flow is inversely related to the resistance to flow according to the law of Hagen-Poiseuille. Therefore, the decrease in the cannula lumen can significantly impede the silicone oil removal, especially for silicone oil with high viscosity.

In the current study, we introduced a simple approach to actively remove high viscosity silicone oil through a standard 23-gauge cannula. The advantage of this technique lies in the following aspects. First, the disposable material (blood transfusion set) used as the silicone vacuum tube is easily available at a low cost (less than 1 USD per piece). The blood transfusion tube has the property of low compliance which can prevent tube collapse under high vacuum. It can be simply prepared and used to connect the 23-gauge cannula to the vitrectomy machine in less than 1min. Second, no strict match is required to joint the blood transfusion tube and 23-gauge cannula, so this technique is applicable to almost all different kinds of trocar-cannula systems on market. This marks the major improvement comparing to our previously reported approach<sup>[14]</sup>. Third, the efficiency of this technique for removal of high-viscosity silicone oil is considerably higher than those approaches reported by other authors<sup>[7,12,16]</sup>. This duration for removal of 5700 cSt silicone oil was around 6min, which is comparable with that reported by Garodia and Kulkarni<sup>[17]</sup> who used a 20-gauge cannula to actively aspirate the silicone oil. The entire lumen of the 23-gauge instrument cannula can ensure high flow rates at a given vacuum level, which can shorten the SOR time significantly. Fourth, the pars planar approach of this technique makes the subsequent manipulations of the posterior segment easier when comparing to the limbal or clear corneal approach. In addition, surgical trauma to the conjunctiva and sclera of these eyes that have undergone repeated surgeries can be reduced by the sutureless sclerotomies. This new technique can be universally applied on phakic, aphakic, or pseudophakic eyes.

The potential disadvantage of this technique is mainly associated with the sutureless sclerotomies, which might lead to postoperative wound leakage and hypotony. In our study, suture placement was necessary at partial sclerotomy sites in only 9 eyes at the end of surgery. Three eyes presented postoperative hypotony due to a subclinical amount of leakage on postoperative day one. The overall IOP level on postoperative day 1 was significantly lower than the preoperative baseline. This finding is comparable to the previous experiences with 23-gauge sutureless vitrectomy reported by other authors<sup>[18-19]</sup>. Fortunately, all IOPs recovered to normal limit within one week without additional postoperative intervention and remained stable thereafter. However, there are some limitations of the current study, including the nonrandomized, non-controlled nature of the study, and relatively small population and short follow-up

time. Future study with larger controlled cases and longer follow-up is warranted to further prove the efficacy and safety of this technique.

In conclusion, active removal of 5700 cSt silicone oil through a standard 23-gauge cannula jointed with a blood transfusion set is a simple and practical technique when considering two sides of efficacy and safety. It has advantages in economy, efficiency and universal applicability. This technique is recommended for silicone oil removal in phakic, aphakic, and pseudophakic eyes on the current 23-gauge sutureless vitrectomy system.

### ACKNOWLEDGEMENTS

**Foundations:** Supported by the National Nature Science Foundation (No.81473295); Science Technology project of Zhejiang Province (No.2014C33260); Wenzhou Science and Technology Bureau (No.Y20140142).

**Conflicts of Interest:** Song ZM, None; Hu XT, None; Wang L, None; Hu ZX, None; Zhao PQ, None; Chen D, None.

### REFERENCES

- 1 Inoue M, Iriyama A, Kadonosono K, Tamaki Y, Yanagi Y. Effects of perfluorocarbon liquids and silicone oil on human retinal pigment epithelial cells and retinal ganglion cells. *Retina* 2009;29(5):677–681.
- 2 Borislav D. Cataract after silicone oil implantation. *Doc Ophthalmol* 1993;83(1):79–82.
- 3 Baillif S, Gastaud P. Complications of silicone oil tamponade. *J Fr Ophthalmol* 2014;37(3):259–265.
- 4 Lucke K, Strobel B, Foerster M, Laqua H. Secondary glaucoma after silicone oil surgery. *Klin Monbl Augenheilkd* 1990;196(4):205–209.
- 5 Bennett SR, Abrams GW. Band keratopathy from emulsified silicone oil. *Arch Ophthalmol* 1990;108(10):1387.
- 6 Bajaire BJ, Oudovitchenko E, Salguero AE, Paipilla DF. Active silicone oil removal with a modified vacuum syringe. *Retin Cases Brief Rep* 2012;6(4):396–399.
- 7 Henderson RH, Reddie IC, Campbell WG. A novel technique for high-density silicone oil removal. *Retina* 2012;32(8):1672–1673.
- 8 Tan HS, Dell'omo R, Mura M. Silicone oil removal after rhegmatogenous retinal detachment: comparing techniques. *Eye (Lond)* 2012;26(3):444–447.
- 9 Eckardt C. Transconjunctival sutureless 23-gauge vitrectomy. *Retina* 2005;25(2):208–211.
- 10 Oh HJ, Chang W, Sagong M. Efficacy and safety of active silicone oil removal through a 23-gauge transconjunctival cannula using an external vacuum pump. *Int J Ophthalmol* 2015;8(2):347–352.
- 11 Romano MR, Groenwald C, Das R, Stappeler T, Wong D, Heimann H. Removal of Densiron-68 with a 23-gauge transconjunctival vitrectomy system. *Eye (Lond)* 2009;23(3):715–717.
- 12 Cekiç O, Cakir M, Yilmaz OF. Passive silicone oil removal in 23-gauge transconjunctival vitrectomy. *Ophthalmic Surg Lasers Imaging* 2011;42(6):514–515.
- 13 Zhang Z, Wei Y, Jiang X, Qiu S, Zhang S. A machine-independent method to have active removal of 5,000 centistokes silicone oil using plastic infusion tube and 23-gauge microcannulas. *BMC Ophthalmol* 2015;15:114.
- 14 Song ZM, Chen D, Ke ZS, Wang RH, Wang QM, Lu F, Qu J. A new approach for active removal of 5,000 centistokes silicone oil through 23-gauge cannula. *Retina* 2010;30(8):1302–1307.
- 15 Kapran Z, Acar N. Removal of silicone oil with 25-gauge transconjunctival sutureless vitrectomy system. *Retina* 2007;27(8):1059–1064.
- 16 Kapran Z, Acar N. Active removal of silicone oil with 25-gauge sutureless system. *Retina* 2007;27(8):1133–1135.
- 17 Garodia VK, Kulkarni A. Silicone oil removal using vitrectomy machine: a simple and safe technique. *Retina* 2001;21(6):685–687.
- 18 Gupta OP, Ho AC, Kaiser PK, Regillo CD, Chen S, Dyer DS, Dugel PU, Gupta S, Pollack JS. Short-term outcomes of 23-gauge pars plana vitrectomy. *Am J Ophthalmol* 2008;146(2):193–197.
- 19 Kim MJ, Park KH, Hwang JM, Yu HG, Yu YS, Chung H. The safety and efficacy of transconjunctival sutureless 23-gauge vitrectomy. *Korean J Ophthalmol* 2007;21(4):201–207.