

Ultra-wide field imaging system and traditional retinal examinations for screening fundus changes after cataract surgery

Jie Peng, Qi Zhang, Hai-Ying Jin, Wu-Yi Lu, Pei-Quan Zhao

Department of Ophthalmology, Xinhua Hospital Affiliated to Shanghai Jiao Tong University School of Medicine, Shanghai 200092, China

Correspondence to: Pei-Quan Zhao. Department of Ophthalmology, Xinhua Hospital Affiliated to Shanghai Jiao Tong University School of Medicine, No.1665, Kong Jiang Road, Shanghai 200092, China. zhaopeiquan@126.com

Received: 2015-09-15 Accepted: 2016-03-04

DOI:10.18240/ijo.2016.09.11

Peng J, Zhang Q, Jin HY, Lu WY, Zhao PQ. Ultra-wide field imaging system and traditional retinal examinations for screening fundus changes after cataract surgery. *Int J Ophthalmol* 2016;9(9):1299-1303

Abstract

• **AIM:** To compare the results of non-mydratic ultra-wide field imaging system, mydratic slit-lamp lens (Volk +90 D) and mydratic Goldmann three-mirror contact lens examinations in screening fundus lesions among patients after cataract surgery.

• **METHODS:** Non-mydratic images were obtained with an Optomap panoramic 200Tx (Optomap 200Tx) 3d after surgery and graded by a blinded ophthalmologist. A mydratic slit-lamp lens examination was performed by another blinded retinal specialist on the same day. A third blinded retinal specialist examined patients two weeks after surgery using a Goldmann three-mirror contact lens.

• **RESULTS:** In total, 160 patients (184 eyes) were examined, and 66, 69, and 75 cases of retinal lesion(s) were identified using the Optomap 200Tx, slit-lamp lens, and Goldmann three-mirror contact lens, respectively. In 13 cases, fundus changes were sight-threatening. The results obtained by Optomap 200Tx examination and by mydratic slit-lamp lens examination have good consistency ($P=0.375$, Kappa =0.942). The mydratic Goldmann three-mirror lens examination revealed more fundus lesions but are consistent with Optomap 200Tx ($P=0.004$, Kappa =0.897) and mydratic slit-lamp lens examination ($P=0.031$, Kappa=0.932).

• **CONCLUSION:** Early post-operative fundus screening in cataract patients is extremely important and necessary to prevent further vision loss. Wide-field imaging is a feasible and convenient tool for fundus examination that can be used as a primary screening method among patients after cataract surgery.

• **KEYWORDS:** cataract; fundus screening; Goldmann three-mirror contact lens; Optomap 200Tx; slit-lamp lens

INTRODUCTION

Cataract is a major vision-threatening disease that is responsible for almost half of all cases of blindness in the world^[1]. Phacoemulsification is the first choice for cataract surgery in western countries and some developing countries such as China. Phacoemulsification surgery is very safe, but complications still occur. The incidence of retinal detachment (RD) is 0.23%, and RD causes enormous damage to vision and patients' quality of life^[2]. Risk factors associated with RD include: lattice degeneration or ocular trauma history, long axial length, a history of RD in the fellow eye, male sex, and surgical complications such as posterior capsular rupture and vitreous loss^[3-5]. Neglect of fundus lesions, including peripheral retinal tears, may increase the risk of RD. However, an opaque lens makes detailed fundus examination before cataract surgery very difficult, and thus, comprehensive fundus examination is particularly important after the removal of the opaque lens.

Examination by the Optomap panoramic 200A laser scanning ophthalmoscope (Optomap 200Tx) (Optos, PLC, Dunfermine, Scotland) is non-mydratic and non-invasive. This system uses red (633 nm) and green (532 nm) lasers reflected off a large concave elliptical mirror, enabling large scan angles of up to 200° to the ora serrata. The resulting images are displayed as red only, green only, and a combined red-green (pseudocolor) image. The anterior retinal layers appear in the "green-only" view, whereas deeper layers of the retina and the choroid are better seen in the "red-only" view. A blue (488 nm) laser allows the system to take ultra-widfield fluorescein angiography (FFA) pictures. Not only does the Optomap ophthalmoscope record a non-mydratic picture encompassing about 80% of the retina in one frame, it only takes 0.3s to make one image, making it especially suitable for elderly patients who exhibit poor compliance^[6]. The newest generation Optomap 200Tx covers 96°, 101°, 76° and 102° in the up, right, down, and left directions, respectively^[7]. Equipped with fundus autofluorescence (FAF) and FFA, it

has become a popular and useful screening tool in many fields such as pediatric retinal disease [8-9], diabetic retinopathy [10-13], uveitis [14], RDs [15], fundus screening [16] and so on.

Dilated fundus screenings have been performed on patients who have had refractive surgery [17]. However, the incidence of fundus lesions among patients with cataract after cataract surgery has rarely been documented, so we evaluated retinal changes among the patients with cataract after cataract surgery using a non-mydratic Optomap 200Tx, mydratic slit-lamp Volk lens, and mydratic Goldmann three-mirror contact lens and comparisons among the three fundus screening tools were made.

SUBJECTS AND METHODS

Subjects Patients who underwent cataract surgery were consecutively recruited from our hospital between November 29, 2013 and January 5, 2014. The study was approved by the Ethical Committee of our hospital. And all procedures were in accordance with the ethical standards of the responsible committee on human experimentation and with the Helsinki Declaration. Informed consent was obtained from all patients. Patients needing simultaneous cataract and vitrectomy surgery were excluded. Excluding myopic shift related to nuclear cataract, 50 patients (27.1%) had high myopia (>-6.00 D and/or axial length >26.5 mm measured by ultrasound biometry).

Methods

Acquiring and processing Optomap 200Tx images Non-mydratic images were taken by a trained resident using an Optomap 200Tx in a dark room. To avoid the effects of transient postoperative corneal opacification, the examination was performed three days after the surgery. Eye lids were retracted by the operator's fingers to obtain better pictures. Under the guidance of eye steering, pseudocolor fundus pictures of the posterior pole, superior field, nasal field, temporal field, and inferior field were taken. Resmax mode images and ultra-wide field FAF images were taken when necessary. Images were digitally captured and viewed using Optos V2 Vantage Review Software (Optos, PLC, Dunfermine, Scotland). Each image was magnified and viewed in "composite", "red-only", and "green-only" views. All images were viewed and diagnosed by a blinded retinal specialist.

Slit-lamp lens examination with Volk lens and assistant examination Slit lamp biomicroscopic examination with a +90 D Volk lens was performed by another blinded retinal specialist on the same day, after pupil dilation with 0.5% tropicamide and 0.5% epinephrin. Patients were asked to look in nine directions to achieve a comprehensive examination.

Goldmann three-mirror contact lens examination Goldmann three-mirror examinations were performed after the operation incision had healed 2wk after surgery, by

another blinded retinal specialist after pupil dilation with 0.5% tropicamide and 0.5% epinephrin. Goldmann three-mirror contact lens examination was set as a gold standard.

Adjunct examinations and treatment When fundus lesions were suspected, additional examinations were performed. Once confirmed, appropriate treatment was applied.

Statistical Analysis All data were analyzed using SPSS 19.0 (SPSS, Chicago, IL, USA). Chi-square tests and Kappa statistics were performed to compare differences between the examination methods.

RESULTS

Before surgery, preoperative exams were carefully performed and a medical history was taken. Exams included best-corrected visual acuity (BCVA) with Chinese standard logarithmic visual acuity chart, intraocular pressure, slit-lamp anterior segment examination, and ultrasound biometry. A dilated fundus examination was performed in a dark room by each operator with an indirect ophthalmoscope. Before the surgery, BCVA ranged from light perception to 0.4. A total of 180 out of 184 patients had no history of intraocular diseases, whereas 4 patients had glaucoma. Fundus lesions were observed before surgery in 17 cases, including optic dystrophy caused by glaucoma (4/17), severe non-proliferative diabetic retinopathy (NPDR) (1/17), mild-to-moderate NPDR (2/17), and pathological myopic macular dystrophy (9/17). An ultrasound examination found one patient with retinal thickening and one patient with macular disease. After applying the exclusion criteria, phacoemulsification and intra-ocular lens implantation were performed on all patients.

A total of 160 patients (66 males and 94 females, 184 eyes) were included in our study. A total of 50 eyes (27.17%) had high myopia. Preoperative BCVA ranged from light perception to 0.4. Three days after surgery, BCVA ranged from finger counting at 40 cm to 1.0. Fundus examinations with an Optomap 200Tx, a mydratic slit-lamp lens (Volk 90 D), and a mydratic Goldmann three-mirror lens identified 66, 69, and 75 eyes with retinal lesion(s), respectively (Table 1). The results obtained by Optomap 200Tx examination and by mydratic slit-lamp lens examination have good consistency ($P=0.375$, Kappa=0.942>0.75). The mydratic Goldmann three-mirror lens examination revealed more fundus lesions (75 out of 184 patients, 40.76%) but are consistent with Optomap 200Tx ($P=0.004$, Kappa=0.897>0.75) and mydratic slit-lamp lens examination ($P=0.031$, Kappa=0.932>0.75).

Of the observed lesions, 61.33% (46/75) were posterior to the equator and 38.67% (29/75) were located at the peripheral retina. Timely treatment was applied in 13 eyes (Table 2). Six eyes showed peripheral retinal tears or holes (3.26%), one had branch retinal vein occlusion (0.54%), one had wet age-related macular degeneration (0.54%), and one patient

Table 1 Examination results

Vitreoretinal changes	Examination methods		
	Optomap 200Tx	Slit-lamp lens (90 D)	Goldmann three-mirror lens
High myopic macular atrophy	17	17	17
Peripheral retinal degeneration	12	15	20
Dry age-related macular degeneration	9	9	9
Hypertensive retinopathy	6	6	6
Peripheral retinal hole (s)	5	5	6
Severe NPDR	4	4	4
Mild to medium NPDR	2	2	2
Retinochoroiditis	3	3	3
Asteroid hyalosis	3	3	3
Macular lamellar hole associated with epiretinal membrane	2	2	2
BRVO	1	1	1
Wet age-related macular degeneration	1	1	1
Myelinated nerve fiber	1	1	1
Total	66	69	75

NPDR: Non-proliferative diabetic retinopathy; BRVO: Branch retinal vein occlusion. All numbers refer to the number of eyes.

Table 2 Thirteen cases needed immediate medical intervention

No.	Gender	Age (a)	Preop. BCVA	Postop. BCVA	Medical history	Diagnosis	Optomap 200Tx	Slit-lamp lens (90 D)	Goldmann three-mirror lens
1	M	66	0.15	0.6	HTN, type 2 DM	Retinal hole	Yes	Yes	Yes
2	M	61	0.05	0.8	Myopia (-3.00 D)	Retinal hole	Yes	Yes	Yes
3	F	70	0.15	0.6	HTN	Multiple retinal tears	Yes	Yes	Yes
4	F	65	0.2	0.8	(-)	Retinal tear	Yes	Yes	Yes
5	M	72	0.15	0.8	HTN	Retinal tear	Yes	No	Yes
6	M	59	FC/BE	0.08	DM	Severe-NPDR			
7	F	55	0.04	0.6	DM	Severe-NPDR	No	Yes	Yes
8	F	55	0.12	0.8	DM	Severe-NPDR	Yes	Yes	Yes
9	M	77	0.1	0.3	HTN, type 2 DM	BRVO, drusen	Yes	Yes	Yes
10	M	82	0.15	0.6	HTN, type 2 DM	Severe-NPDR	Yes	Yes	Yes
11	M	90	0.1	0.12	HTN	Wet-AMD	Yes	Yes	Yes
12	M	61	0.06	0.4	HTN	Multiple lattice degeneration with retinal hole	Yes	Yes	Yes
13	F	69	0.01	0.15	High myopia (-13.00 D)	Retinal hole and myopic macular atrophy	Yes	Yes	Yes

BCVA: Best-corrected visual acuity; HTN: Hypertension; DM: Diabetes mellitus; BRVO: Branch retinal vein occlusion; NPDR: Non-proliferative diabetic retinopathy; Wet-AMD: Wet age-related macular degeneration.

had multiple lattice degenerations with a possible retinal tear (0.54%). In the six patients with retinal tears, the fellow eye was examined. Only one (16.67%) patient had bilateral retinal tears.

Among those 50 eyes with high myopia, peripheral retinal pathology was detected in 10 eyes (20.00%), and 7 of them had pigmentary degeneration, 2 had paving stone degeneration, and 1 had a retinal break.

Regarding treatment, laser therapy was promptly performed in patients with retinal tear (s). After photocoagulation, ultra-widefield images were taken as well. Interestingly, we found a "missed" retinal tear after initial photocoagulation treatment in one case, which were paired (Figure 1). Optomap 200Tx examination is optimal to facilitate follow-up treatment.

The Optomap 200Tx imaging system is suitable for elderly

patients who have relatively poor compliance and eye fixation, because each image requires only 0.3s. In our study, a retinal tear was found by Optomap 200Tx examination in a 72 year-old man that was not observed by dilated slit-lamp examination as a result of poor patient cooperation (Figure 2). However, the Optomap 200Tx image covers least in the down direction [7]. This feature limits its performance especially in the inferior direction, as demonstrated by a missed retinal hole located in the inferior quadrant anterior to the equator in one patient (Figure 3).

DISCUSSION

Poor or suboptimal visual outcomes following successful cataract surgery may be due to a pre-existing fundus pathology, although postoperative changes including cystoid macular oedema are possible. Pre-existing fundus pathology may not be obvious pre-operatively because of poor fundus

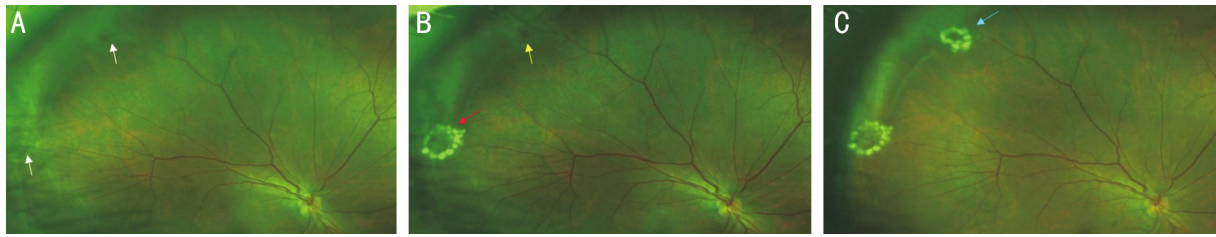


Figure 1 Retinal images of a 60-year-old female A: Pseudocolor image shows two retinal holes (white arrow); B: After photocoagulation (red arrow). One retinal hole was missed (yellow arrow); C: Re-photocoagulation with Optomap 200Tx guidance (blue arrow).

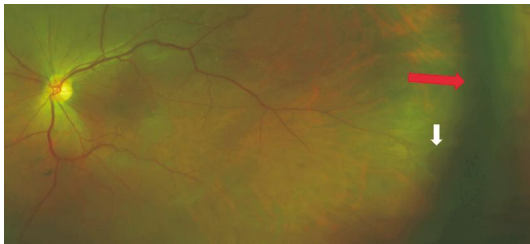


Figure 2 Retinal image of a 72-year-old male White arrow: A retinal hole missed by mydriatic slit-lamp indirect lens examination. Red arrow: The edge of the implantable ocular lens.

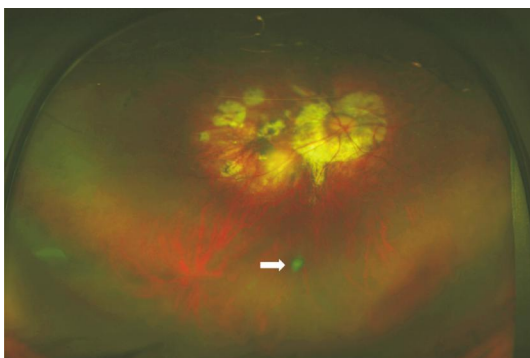


Figure 3 Retinal image of a 55-year-old female Composite image of the inferior direction shows retinal dystrophy and a free-floating operculum. After mydriation, a retinal hole was detected by examinations with a slit-lamp indirect lens and a Goldmann three-mirror contact lens.

visualization. Removal of the opaque lens makes early fundus screening possible. Dilated fundus screenings were performed in patients who had undergone refractive surgery, and a posterior segment pathology requiring intervention was found in 1.1% of the patients [17]. Peripheral lesions, such as no surgery-related retinal breaks and/or detachments were identified in 52.6% eyes as reported in asymptomatic cataract patients [18]. However, the incidence of fundus lesions among patients after cataract surgery in china remains unknown. Traditional fundus examination tools include direct or indirect ophthalmoscopy, with no contact lens, and Goldmann three-mirror contact lens, which requires optimal mydriasis. Mydriatic fundus examination is considered to be time-consuming and depends on operator experience and patient cooperation. Furthermore, mydriasis should be avoided in patients with a high risk of angle closure due to

glaucoma. The need for a feasible and accurate fundus examination method is great, especially in China where the number of patients in need of screening is large. Relying less on the photographer's experience and the patients' compliance, Optomap 200Tx examination is advantageous over traditional fundus examinations and meets the demand for cost and time reduction. In addition, a non-contact exam is more likely to be free from some complications, such as infections, corneal injury, and subconjunctival hemorrhage. We found that multi-wave length laser scanning ophthalmoscopy provides much more information than traditional fundus imaging systems and thus, may help to better identify retinal lesions. Green separation images of peripheral retinal tears are much better than pseudo color images. The Optomap 200Tx offers a higher resolution image of the retina (11 μm) compared with traditional fundus imaging systems, thus a macular lamellar hole or epiretinal membrane can be detected with this technique. FAF images reveal retinal pigment epithelium cell function and could represent an additional diagnostic method for several diseases, such as Stargart's disease, age-related macular degeneration, retinitis pigmentosa, and Best disease. When post-cataract surgery examinations were made with a three-mirror contact lens, we found 40.76% (75/184) of eyes had fundus lesions. Before the surgery, such lesions were detected in only 17 patients. This gap illustrates the importance of a postoperative fundus examination method that could lead to the preservation of visual acuity. Moreover, 13 out of 184 eyes (7.07%) required medical intervention. The sooner the fundus disease is found, the greater the chance that visual acuity can be preserved. Interestingly, BCVA was higher than 0.3 units in 10 eyes and higher than 0.4 units in the 5 cases with retinal tears. Fundus screening should never be neglected, even when the BCVA is relatively promising. A Chinese study found that 71.4% of high myopic eyes had peripheral retinal degeneration. Most had a pigmentary degeneration (51.2%), followed by lattice degeneration (12.2%) and retinal holes (7.5%)^[19], suggesting that special care should be taken in treating highly myopic eyes. The former generation of Optomap 200 was reported to have a high specificity and moderate sensitivity for lesions

posterior to the equator and low sensitivity for lesions anterior to the equator [20]. Non-mydratric ultra-widefield fundus examination with the Optomap 200Tx could be a convenient and feasible tool for fundus screening, but it has some drawbacks as well. For instance, a retinal hole located in the inferior quadrant anterior to the equator in one patient was missed (Figure 3).

Obviously, peripheral retinal degeneration is the major factor that has the highest variation among all other variables. Three lesions missed by Optomap 200Tx but observed with slit-lamp examination were located in the inferior field (two) and superior field (one) which demonstrates Optomap 200Tx's limitation in detecting peripheral lesions in inferior and superior fields. Goldmann three-mirror lens revealed more lesions located before the equator and this makes it the most effective of the three tools. However, the accuracy of the Goldmann three-mirror lens examination relies greatly on the examiner's experience, and the examination is time-consuming and uncomfortable. Optomap 200Tx without pupil dilation is comparatively more convenient and comfortable with good detection rate of fundus changes so it could be a good choice for examination.

Limitation of the study We chose the Goldmann three-mirror contact lens examination as the gold standard examination tool because it is more commonly used than indirect ophthalmoscopy with scleral indentation in Chinese clinics. However the Goldmann three-mirror contact lens itself could miss some fundus lesions located far from the peripheral retina and this could represent an important bias. The sample size was small and further study on a larger scale is needed.

In conclusion, retinal lesions were found in 40.76% (75/184) of eyes with a Goldmann three-mirror lens, 35.87% (66/184) with the Optos system, and 37.50% (69/184) with the 90 D, and 7.01% (13/184) required immediate medical treatment. For this reason, early postoperative fundus examination among cataract patients is very essential. Ultra-wide imaging system could be a convenient and feasible tool for screening, but cannot completely replace Goldmann three-mirror contact lens examination.

ACKNOWLEDGEMENTS

Foundations: Supported by the National Natural Science Foundation of China (No.81271045; No.81470642); Shanghai Science and Technology Committee (No.15XD1502800).

Conflicts of Interest: Peng J, None; Zhang Q, None; Jin HY, None; Lu WY, None; Zhao PQ, None.

REFERENCES

- 1 Resnikoff S, Pascolini D, Etya'ale D, Kocur I, Pararajasegaram R, Pokharel GP, Mariotti SP. Global data on visual impairment in the year 2002. *Bull of the World Health Organization* 2004;82(11):844-851.
- 2 Bjerrum SS, Mikkelsen KL, La Cour M. Risk of pseudophakic retinal detachment in 202,226 patients using the fellow nonoperated eye as reference. *Ophthalmology* 2013;120(12): 2573-2579.

- 3 Erie JC, Raecker MA, Baratz KH, Schleck CD, Robertson DM. Risk of retinal detachment after cataract extraction, 1980-2004: a population-based study. *Ophthalmology* 2006;113(11):2026-2032.
- 4 Jakobsson G, Montan P, Zetterberg M, Stenevi U, Behndig A, Lundstöm M. Capsule complication during cataract surgery: Retinal detachment after cataract surgery with capsule complication: Swedish Capsule Rupture Study Group report 4. *J Cataract Refract Surg* 2009;35(10):1699-1705.
- 5 Sheu SJ, Ger LP, Ho WL. Late increased risk of retinal detachment after cataract extraction. *Am J Ophthalmol* 2010;149(1):113-119.
- 6 Khandhadia S, Madhusudhana KC, Kostakou A, Forrester JV, Newsom RS. Use of Optomap for retinal screening within an eye casualty setting. *Br J Ophthalmol* 2009;93(1):52-55.
- 7 Oishi A, Hidaka J, Yoshimura N. Quantification of the image obtained with a wide-field scanning ophthalmoscope. *Invest Ophthalmol Vis Sci* 2014;55(4):2424-2431.
- 8 Kashani AH, Learned D, Nudleman E, Drenser KA, Capone A, Trese MT. High prevalence of peripheral retinal vascular anomalies in family members of patients with familial exudative vitreoretinopathy. *Ophthalmology* 2014;121(1):262-268.
- 9 Kang KB, Wessel MM, Tong J, D'Amico DJ, Chan RV. Ultra-widefield imaging for the management of pediatric retinal diseases. *J Pediatr Ophthalmol and Strabismus* 2013;50(5):282-288.
- 10 Kernt M, Hadi I, Pinter F, Seidensticker F, Hirneiss C, Haritoglou C, Kampik A, Ulbig MW, Neubauer AS. Assessment of diabetic retinopathy using nonmydratric ultra-widefield scanning laser ophthalmoscopy (Optomap) compared with ETDRS 7-field stereo photography. *Diabetes Care* 2012;35(12):2459-2463.
- 11 Lopez-Bastida J, Cabrera-Lopez F, Serrano-Aguilar P. Sensitivity and specificity of digital retinal imaging for screening diabetic retinopathy. *Diabet Med* 2007;24(4):403-407.
- 12 Neubauer AS, Kernt M, Haritoglou C, Priglinger SG, Kampik A, Ulbig MW. Nonmydratric screening for diabetic retinopathy by ultra-widefield scanning laser ophthalmoscopy (Optomap). *Graefes Arch Clin Exp Ophthalmol* 2008;246(2):229-235.
- 13 Wessel MM, Aaker GD, Parlitsis G, Cho M, D'Amico DJ, Kiss S. Ultra-wide-field angiography improves the detection and classification of diabetic retinopathy. *Retina* 2012;32(4):785-791.
- 14 Reznicek L, Seidensticker F, Stumpf C, Kampik A, Thureau S, Kernt M, Neubauer A. Systematic analysis of wide-field fundus autofluorescence (FAF) imaging in posterior uveitis. *Curr Eye Res* 2014;39(2):164-171.
- 15 Salvanos P, Navaratnam J, Ma J, Bragadóttir R, Moe MC. Ultra-widefield autofluorescence imaging in the evaluation of scleral buckling surgery for retinal detachment. *Retina* 2013;33(7):1421-1427.
- 16 Heussen FM, Tan CS, Sadda SR. Prevalence of peripheral abnormalities on ultra-widefield greenlight (532 nm) autofluorescence imaging at a tertiary care center. *Invest Ophthalmol Vis Sci* 2012;53(10):6526-6531.
- 17 Brady J, O'Keefe M, Kilmartin D. Importance of funduscopy in refractive surgery. *J Cataract Refract Surg* 2007;33(9):1602-1607.
- 18 Schwartz S, Gonzalez CL, Bhandari R, Oliver SN, Mandava N, Quiroz-Mercado H. Retina evaluation with nonmydratric ultrawide-field color imaging after cataract extraction surgeries in asymptomatic patients. *Ophthalmic Surg Lasers Imaging Retina* 2015;46(1):50-55.
- 19 Lam DS, Fan DS, Chan WM, Tam BS, Kwok AK, Leung AT, Parsons H. Prevalence and characteristics of peripheral retinal degeneration in Chinese adults with high myopia: a cross-sectional prevalence survey. *Optom Vis Sci* 2005;82(4):235-238.
- 20 Mackenzie PJ, Russell M, Ma PE, Isbister CM, Maberley DA. Sensitivity and specificity of the optos optomap for detecting peripheral retinal lesions. *Retina* 2007;27(8):1119-1124.