

# Preoperative evaluation and outcome of corneal transplantation for limbal dermoids: a ten-year follow-up study

Meng Xin<sup>1,2</sup>, Yue-Rong Gong<sup>3</sup>, Shan-Hao Jiang<sup>2</sup>, Chun-Hua Dai<sup>2</sup>, Su-Xia Li<sup>4</sup>, Wei-Yun Shi<sup>4</sup>

<sup>1</sup>Shandong University, Jinan 250012, Shandong Province, China

<sup>2</sup>Department of Ophthalmology, Yantai Affiliated Hospital of Binzhou Medical University, Yantai 264100, Shandong Province, China

<sup>3</sup>Department of Ophthalmology, Binzhou Medical University Hospital, Binzhou 256603, Shandong Province, China

<sup>4</sup>Shandong Eye Hospital, Shandong Eye Institute, Shandong Academy of Medical Sciences, Jinan 250021, Shandong Province, China

**Correspondence to:** Wei-Yun Shi. Shandong Eye Hospital, Shandong Eye Institute, Shandong Academy of Medical Sciences, No. 372 Jingsi Road, Jinan 250021, Shandong Province, China. weiyunshi@163.com

Received: 2016-04-27 Accepted: 2016-09-05

## Abstract

• **AIM:** To summarize preoperative evaluation and outcome of corneal transplantation for limbal dermoids for ten years.

• **METHODS:** Eighty-five patients diagnosed with limbal dermoids and treated with corneal transplantation were analyzed retrospectively. All patients were further divided into two groups according to absence or presence of neovascularization surrounding the dermoids in the corneal stroma. Eighty-two eyes were treated with tumor excision combined with partial lamellar sclerokeratoplasty, and the other three eyes were performed by penetrating keratoplasty. The size and location of the tumor, the associated ocular and systemic anomalies, the depth of the corneal penetration of tumor tissues, the preoperative and postoperative best-corrected visual acuity (BCVA), graft survival and cosmetic outcome, and surgical complications were recorded respectively.

• **RESULTS:** The average age at surgery was 5.3y (range, 3mo–36y). The mean size of dermoids was 6.1±1.6 mm. The 43.5% of eyes (37/85) were present with hair at the surface of the dermoid and 72.9% of dermoids were located inferotemporal of the eye. Amblyopia was present in 34.1% of patients (29/85) and 9.4% of patients (8/85) had lipodermoids. Eighteen patients suffered from Goldenhar's syndrome with an accessory ear. The 75% of patients in group 1 had involvement of the corneal deep stroma down to Descemet's membrane without

involving it, but 71.4% of patients had Descemet's membrane involvement in group 2. Preoperative BCVA ranged from counting fingers to 20/20. Postoperatively 81.1% had a BCVA of 20/800 or better. There was no significant difference between the post-surgical BCVA of the two groups ( $t=1.584$ ,  $P>0.05$ ). The grafts of 70.5% patients were present as 1+ opacity, 21.1% as 2+ opacity, 8.2% as 3+ opacity and none as 4+ opacity. Surgical complications included graft rejection, microperforation, prolonged reepithelialization, steroid glaucoma, interface neovascularization, and interface hemorrhage.

• **CONCLUSION:** The dermoids with neovascularization surrounding them in the corneal stroma invaded deeper tissues in the cornea than those with no neovascularization surrounding them in the corneal stroma. Therefore, surgeons should take care to avoid corneal perforation during the corneal transplantation operation. The majority of patients markedly improved their cosmetic appearance after surgery.

• **KEYWORDS:** limbal dermoids; corneal transplantation; neovascularization

DOI:10.18240/ijo.2016.12.09

Xin M, Gong YR, Jiang SH, Dai CH, Li SX, Shi WY. Preoperative evaluation and outcome of corneal transplantation for limbal dermoids: a ten-year follow-up study. *Int J Ophthalmol* 2016;9(12):1756–1760

## INTRODUCTION

Limbal dermoids are congenital benign tumors consisting of tissues with ectodermal and mesodermal origins. They are usually yellowish-white bulbous lesions in the limbal area and contain fibers, adipose tissue, hair, and vessels. These tumors can result in astigmatism, cosmetic problems, and vision impairment along with lesions and increasing astigmatism<sup>[1-2]</sup>. At present, the effective treatment for this disease is surgical excision, but intraoperative complications such as corneal perforation are possible while stripping lesions. Although slit-lamp, gonioscopy, and ultrasound biomicroscope (UBM) are helpful for the preoperative evaluation for limbal dermoids, there are still many restrictions. Currently, there is no subtle instrument that can accurately measure the depth of the corneal penetration of tumor tissues<sup>[2-6]</sup>. The clinical features of limbal

dermoids differ, particularly their location, shape, and depth. If we can achieve an in-depth understanding of the clinical characteristics and conduct an accurate preoperative evaluation, corneal perforation will be avoided effectively while stripping lesions intraoperatively. It is beneficial to guide the performer to develop a reasonable and accurate plan for operation and to promote rapid recovery for patients postoperatively<sup>[7]</sup>.

## SUBJECTS AND METHODS

**Patients** This retrospective case series study was approved by the Ethics Committee of Shandong Eye Institute and followed the tenets of the Declaration of Helsinki. All patients signed the informed consent. In this paper, 85 eyes of 85 patients with limbal dermoids who underwent corneal transplantation from July 2004 to September 2014 at Shandong Eye Hospital were analyzed retrospectively. Eighty-two eyes were treated with tumor excision combined with partial lamellar sclerokeratoplasty, and the other three eyes were treated with penetrating keratoplasty. All patients diagnosed with limbal dermatoids were further divided into two groups according to the designed group categories. Patients with dermatoids characterized by no neovascularization surrounding the dermoids in the corneal stroma were classified as group 1, while those patients with dermatoids characterized by neovascularization surrounding the them in the corneal stroma were classified as group 2. Group 1 included 64 patients (64 eyes), and group 2 included 21 patients (21 eyes). The size and location of the tumor, the associated ocular and systemic anomalies, the depth of the corneal penetration of tumor tissues, the preoperative and postoperative best-corrected visual acuity (BCVA), graft survival and cosmetic outcomes, and surgical complications were recorded respectively. Visual acuity was tested using the Snellen chart and was converted into a logarithm of the minimum angle of resolution score for analysis. Sixteen patients (16 eyes) were not cooperative enough to perform visual acuity testing using the Snellen chart because of their younger age. The opacity of the graft was graded clinically on a scale of 0 to 4+ (0=completely clear; 1=minimal haze seen with difficulty under direct illumination; 2=mild haze seen easily; 3=moderately dense opacity partially obscuring the iris details; 4=dense opacity completely obscuring all details of the intraocular structure)<sup>[8]</sup>.

**Excision and Partial Lamellar Sclerokeratoplasty** The operation was performed on infants and children under general anesthesia, and on adults under local anesthesia. First, the external rectus muscle was pulled with sutures, and the conjunctiva was cut open around the lesion to fully expose to the lesion. The size of the trephine was chosen according to the tumor size. Generally, the diameter of the trephine was 0.25 mm larger than the excised dermoid bed (3.5-10.0 mm). The cutting depth was 1/4-1/3 corneoscleral

thickness until the recipient bed was clear. Most donor eyes were preserved in low-temperature glycerin from an eye bank, and only a few from DX solution. The lamellar corneoscleral button (2/3 from the cornea, 1/3 from the sclera) was 0.25 mm larger than the excised dermoid bed. The donor button was laid over the area of the cornea from where the dermoid was excised, and the corneal edge was sutured with 8-12 interrupted 10-0 nylon. The conjunctiva was anchored to the limbus with 10-0 nylon. All surgeries were performed by one surgeon (Shi WY).

## Postoperative Chemotherapy and Statistical Analysis

All the patients received general and topical corticosteroids and antibiotics after surgery. The mean intraocular pressure was measured with a Tono-Pen tonometer. Statistical analysis was performed using the method of two-tailed independent sample *t*-tests with SPSS 17.0 statistical software (SPSS Inc., Chicago, IL, USA). A *P*-value of <0.05 was considered statistically significant.

## RESULTS

**Demographic Data** The average age at surgery was 5.3y (range, 3mo to 36y), and there were 49 men and 36 women. The operations were performed in 41 right eyes and 44 left eyes, respectively. The mean follow-up time was 17.95mo (range, 1mo to 6y). There was no significant difference in age and sex between the two groups. Four patients were diagnosed with recurrent dermoids. The dermoid in 1 patient was recurrent following excision and lamellar keratoplasty, and in 3 patients it was recurrent following simple excision.

**Size and Location** The mean size of dermoids was 6.1±1.6 mm; 43.5% of eyes (37/85) were present with hair at the surface of the dermoid. The location of dermoids was shown in Table 1.

**Associated Ocular and Systemic Anomalies** Anisometropia was present in 34.1% of patients (29/85); 9.4% of patients (8/85) had lipodermoids. Eighteen patients suffered from Goldenhar's syndrome with an accessory ear.

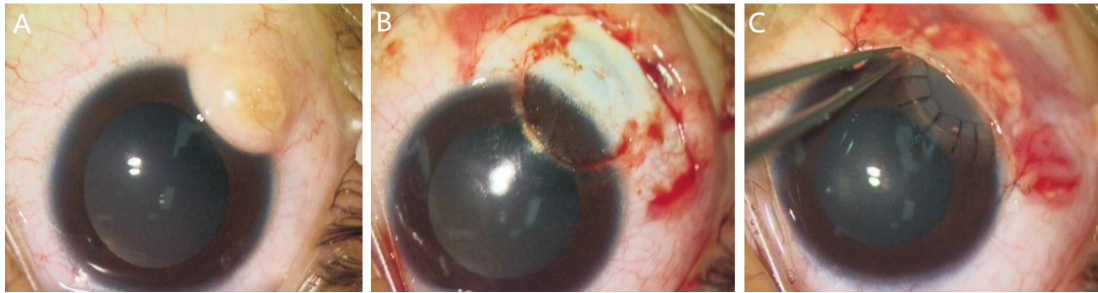
**Depth of the Corneal Penetration of Dermoids** The depth of the corneal penetration of dermoids was shown in Table 2. All measurements showed statistically significant differences (*P* <0.05). Specific surgical procedure of excision combined with partial lamellar sclerokeratoplasty of two groups was shown in Figures 1, 2.

**Preoperative and Postoperative Best-corrected Visual Acuity** Preoperative BCVA ranged from counting fingers to 20/20. Postoperatively in the last follow-up, 81.1% (56/69) had a BCVA of 20/800 or better. In 43.4% (30/69) of patients, the BCVA was 20/40 or better and for 14.4% (10/69) of them it was 20/25 or better. In group 1, the preoperative BCVA was 20/200-20/20 (0.41±0.32 logMAR) and the postoperative was 20/400-20/20 (0.31±0.22 logMAR) in the last follow-up. The postoperative BCVA improved in

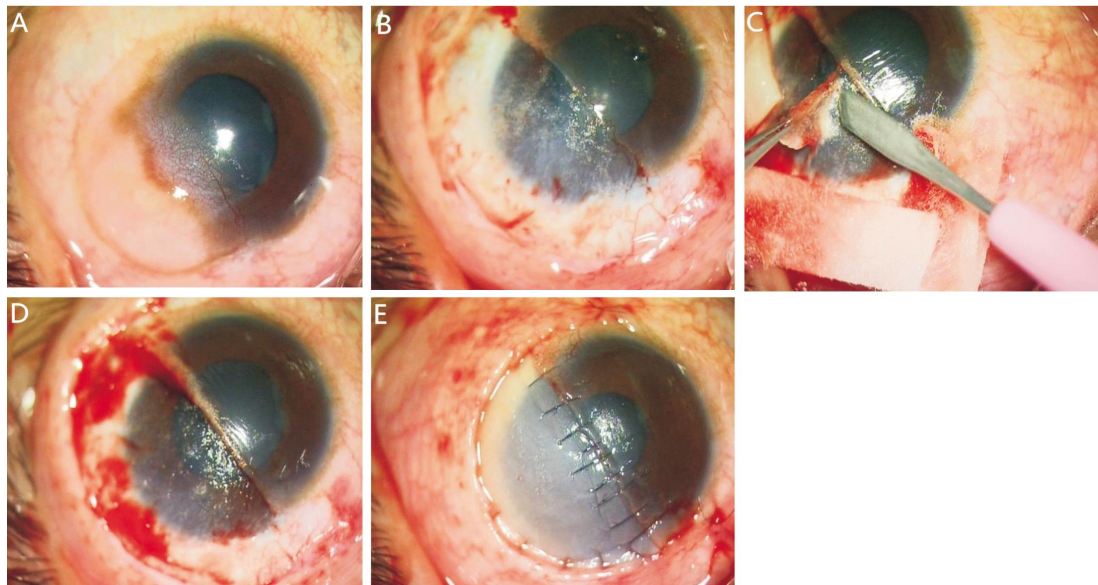
**Table 1 The location of dermoids**

Location	IT	ST	TEMP	SN	IN	Central	Inferior	Whole cornea	Total
Eye (%)	62 (72.9)	2 (2.4)	8 (9.4)	1 (1.2)	5 (5.9)	2 (2.4)	3 (3.5)	2 (2.4)	85

IT: Inferotemporal; ST: Superotemporal; TEMP: Temporal; SN: Superonasal; IN: Inferonasal.



**Figure 1 Excision and partial lamellar sclerokeratoplasty in group 1** A: The limbal dermoid with yellowish white bulbous and hairy was located in the inferotemporal of eye and neovascularization was not present on the surrounding lesion in the corneal stroma; B: After excising the lesion, the depth of corneal penetration of dermoid was in the superficial stroma; C: The corneal graft was sutured with 12 interrupted 10-0 nylon. The conjunctiva was anchored to the limbus with 10-0 nylon.



**Figure 2 Excision and partial lamellar sclerokeratoplasty in group 2** A: Neovascularization was present around the lesion in the corneal stroma; B: After excising the lesion, the depth of corneal penetration of dermoid was in the deeper stroma and the recipient bed was still opaque; C: Continue excising the lesion until the recipient bed was visible; D: The recipient bed was visible; E: The corneal graft was sutured with interrupted 10-0 nylon. The conjunctiva was anchored to the limbus with 10-0 nylon.

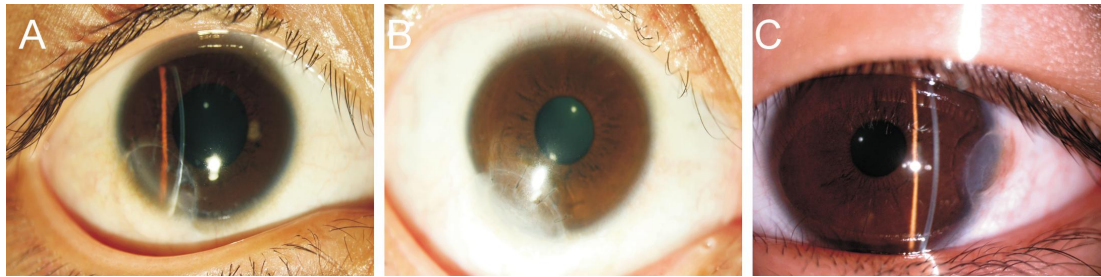
32 of 50 eyes (64%), remained unchanged in 8 eyes (16%), and decreased in 10 eyes (20%). In group 2, the preoperative BCVA was 20/2000-20/20 (0.75 ± 0.4 logMAR) and the postoperative was 20/400-20/20 (0.66 ± 0.43 logMAR) in the last follow-up. The postoperative BCVA improved in 12 of 19 eyes (63.2%), remained unchanged in 4 eyes (21.1%), and decreased in 3 eyes (15.8%). There were no significant difference between the post-surgical BCVA of the two groups ( $t=1.584, P>0.05$ ) (Table 3).

**Cosmetic Outcome** All patients markedly improved their cosmetic appearance, except one patient due to interface neovascularization and opacity. The grafts of 70.5% patients were present as 1+ opacity, 21.1% as 2+ opacity, 8.2% as 3+ opacity and none as 4+ opacity. The cosmetic outcome was shown in Table 4 and Figure 3.

**Table 2 The depth of corneal penetration of dermoids in eyes** eye (%)

Depth of corneal penetration	Group 1	Group 2
Superficial stroma	16 (25)	0
Deep stroma	48 (75)	3 (14.2)
Descemet's membrane	0	15 (71.4)
Whole cornea	0	3 (14.3)
Total	64	21

**Surgical Complications** Graft rejection occurred in 3 patients with penetrating keratoplasty, but improved under anti-rejection medications. No recurrence was noted after surgery. Microperforation was present in 1 patient and repaired during the operation. After surgery, prolonged reepithelialization occurred in 4 eyes, steroid glaucoma was seen in 2 eyes, interface neovascularization was present in 1 eye, and interface hemorrhage occurred in 1 eye.



**Figure 3 The grading of graft** A: The graft of patient was present as 1+opacity; B: Graft opacity graded as 2+; C: The graft of patient was present as 3+opacity and was moderately dense opacity partially obscuring iris details.

**Table 3 Comparison of the BCVA of the two groups pre and post surgery** n (%)

BCVA	Group 1		Group 2	
	Preoperative	Postoperative	Preoperative	Postoperative
<20/400	1 (2)	0 (0)	2 (10.5)	1 (5.3)
≥20/400	0 (0)	1 (2)	3 (15.8)	0 (0)
<20/200	26 (52)	13 (26)	11 (57.9)	14 (73.7)
≥20/200	17 (34)	27 (54)	2 (10.5)	3 (15.8)
<20/40	6 (12)	9 (18)	1 (5.3)	1 (5.3)
≥20/40	17 (34)	27 (54)	2 (10.5)	3 (15.8)
<20/25	6 (12)	9 (18)	1 (5.3)	1 (5.3)
≥20/25	17 (34)	27 (54)	2 (10.5)	3 (15.8)
<20/20	6 (12)	9 (18)	1 (5.3)	1 (5.3)
≥20/20	17 (34)	27 (54)	2 (10.5)	3 (15.8)
Total	50	50	19	19

**Table 4 Cosmetic outcome of grafts in the two groups** Eye (n)

Groups	Cosmetic outcome					Total
	0	1+	2+	3+	4+	
Group 1	0	50	12	2	0	64
Group 2	0	10	6	5	0	21
Total	0	60	18	7	0	85

## DISCUSSION

Limbal dermoids are the most common tumors in the corneal limbus. Limbal dermoids are classified into 3 grades according to their anatomy. Grade I limbal dermoids are lesions with a superficial tumor measuring <5 mm. Grade II limbal dermoids are of larger size and extend into the corneal stroma down to Descemet's membrane without involving it. Grade III limbal dermoids involve the whole cornea and structures of the anterior chamber [7,9-11]. Limbal dermoid patients need to undergo surgical excision for cosmetic appearance and vision impairment. Common surgical methods reported in prior literature included simple excision, amniotic membrane transplantation, and lamellar or penetrating keratoplasty [7,10,12-16]. In our report, excision combined with partial lamellar sclerokeratoplasty was mainly applied to Grade II limbal dermoids, while those patients with Grade III limbal dermoids were performed by penetrating keratoplasty. Jeong *et al* [17] demonstrated that combined corneal tattooing and a sutureless limboconjunctival autograft with simple excision in patients with grade 1 limbal dermoids resulted in good cosmetic and functional outcomes. Usually, appropriate treatment depends on the size, location, and the degree of corneal involvement of the lesion. However, regardless of what kind of operation method is chosen,

intraoperative complications such as corneal perforation are possible while stripping lesions [18-20]. If handled improperly, there are serious consequences for patients, particularly in the absence of cornea donors. Watts *et al* [3] reported that in the process of corneal transplantation for the treatment of 49 patients with limbal dermoids, microperforation was present in 3 patients; therefore, a penetrating graft was carried out for 1 and the other 2 patients required re-grafts. In our study, microperforation was present in 1 patient and repaired during the operation on account of the lesion involving Descemet's membrane of the cornea. Therefore, no matter what operation method is selected, an accurate preoperative assessment is particularly important. Although slit-lamp, gonioscopy, and ultrasound biomicroscope (UBM) are helpful for the preoperative evaluation of limbal dermoids, there are still many restrictions. Hoops *et al* [6] reported that UBM improved the preoperative evaluation of limbal dermoids, but it reduced the visibility of deep corneal structures and Descemet's membrane was not visible because of the strong sound attenuation in this lesion's tissue. Thus far, there is no subtle instrument that can accurately measure the depth of the corneal penetration of tumor tissues. Therefore, the preoperative evaluation and postoperative results of the patients with dermoids mainly rely on the performer's rich experience and surgical skills.

We found that of the patients treated with surgery, 75% of those in group 1 had the involvement of the corneal deep stroma down to Descemet's membrane without involving it, but in group 2, 71.4% of patients had Descemet's membrane involvement. So the dermatoids with neovascularization in the corneal stroma invaded into deeper tissues of the cornea than those with no neovascularization in the corneal stroma. When excising tumors and lamellar cornea, the surgeon should take care to avoid corneal perforation in the course of surgery. For performers with limited surgical experience, it is beneficial to develop an operation plan and conduct a preoperative evaluation to avoid complications.

It is very helpful for performers to master the clinical features of limbal dermoids, but each patient has his/her specificity. Thus, it is more important to strengthen clinical practice and master operating skills. Only in this way can we deal with

intraoperative and postoperative conditions reasonably and improve the success rate of surgery. With the development of medical science and technology, we believe that a more subtle instrument can accurately measure the depth of corneal penetration of tumor tissues. This should be the focus of future research.

We found that the dermoids with neovascularization surrounding them in the corneal stroma invaded deeper tissues in the cornea than those with no neovascularization surrounding them in the corneal stroma. Therefore, surgeons should take care to avoid corneal perforation during surgery. The majority of patients markedly improved their cosmetic appearance after surgery.

### ACKNOWLEDGEMENTS

**Conflicts of Interest:** Xin M, None; Gong YR, None; Jiang SH, None; Dai CH, None; Li SX, None; Shi WY, None.

### REFERENCES

- 1 Robb RM. Astigmatic refractive errors associated with limbal dermoids. *J Pediatr Ophthalmol Strabismus* 1996;33(4):241–243.
- 2 Scott JA, Tan DT. Therapeutic lamellar keratoplasty for limbal dermoids. *Ophthalmology* 2001;108(10):1858–1867.
- 3 Watts P, Michaeli-Cohen A, Abdoell M, Rootman D. Outcome of lamellar keratoplasty for limbal dermoids in children. *J AAPOS* 2002;6(4):209–215.
- 4 Lanzl IM, Augsburger JJ, Hertle RW, Rapuano C, Correa-Melling Z, Santa Cruz C. The role of ultrasound biomicroscopy in surgical planning for limbal dermoids. *Cornea* 1998;17(6):604–606.
- 5 Grant CA, Azar D. Ultrasound biomicroscopy in the diagnosis and management of limbal dermoid. *Am J Ophthalmol* 1999;128(3):365–367.
- 6 Hoops JP, Ludwig K, Boergen KP, Kampik A. Preoperative evaluation of limbal dermoids using high-resolution biomicroscopy. *Graefes Arch Clin Exp Ophthalmol* 2001;239(6):459–461.
- 7 Pirouzian A. Management of pediatric corneal limbal dermoids. *Clin Ophthalmol* 2013;7:607–614.
- 8 Shen YD, Chen WL, Wang IJ, Hou YC, Hu FR. Full-thickness central corneal grafts in lamellar keratoscleroplasty to treat limbal dermoids. *Ophthalmology* 2005;11(112):1955–1962.
- 9 Sunderraj PP, Viswanathan RK, Balachander R. Neoplasms of the limbus. *Indian J Ophthalmol* 1991;39(4):168–169.
- 10 Stergiopoulos P, Link B, Naumann GO, Seitz B. Solid corneal dermoids and subconjunctival lipodermoids: impact of differentiated surgical therapy on the functional long-term outcome. *Cornea* 2009;28(6):644–651.
- 11 Pirouzian A, Holz H, Merrill K, Sudesh R, Karlen K. Surgical management of pediatric limbal dermoids with sutureless amniotic membrane transplantation and augmentation. *J Pediatr Ophthalmol Strabismus* 2011;49(2):114–119.
- 12 Cha DM, Shin KH, Kim KH, Kwon JW. Simple keratectomy and corneal tattooing for limbal dermoids: results of a 3-year study. *Int J Ophthalmol* 2013;6(4):463–466.
- 13 Mader TH, Stulting D. Technique for the removal of limbal dermoids. *Cornea* 1998;17(1):66–67.
- 14 Pirouzian A, Ly H, Holz H, Sudesh RS, Chuck RS. Fibrin-glue assisted multilayered amniotic membrane transplantation in surgical management of pediatric corneal limbal dermoid: a novel approach. *Graefes Arch Clin Exp Ophthalmol* 2011;249(2):261–265.
- 15 Hong S, Kim EJ, Seong GJ, Seo KY. Limbal stem cell transplantation for limbal dermoid. *Ophthalmic Surg Lasers Imaging* 2010;1–2.
- 16 Lang SJ, Böhringer D, Reinhard T. Surgical management of corneal limbal dermoids: retrospective study of different techniques and use of Mitomycin C. *Eye(Lond)* 2014;28(7):857–862.
- 17 Jeong J, Song YJ, Jung SI, Kwon JW. New surgical approach for limbal dermoids in children: simple excision, corneal tattooing, and sutureless limboconjunctival autograft. *Cornea* 2015;34(6):720–723.
- 18 Panda A, Ghose S, Khokhar S, Das H. Surgical outcomes of epibulbar dermoids. *J Pediatr Ophthalmol Strabismus* 2002;39(1):20–25.
- 19 Lazzaro DR, Coe R. Repair of limbal dermoid with excision and placement of a circumlimbal pericardial graft. *Eye Contact Lens* 2010;36(4):228–229.
- 20 Sommer F, Pillunat LE. Epibulbar dermoids—clinical features and therapeutic methods. *Klin Monbl Augenheilkd* 2004;221(10):872–877.