

# Giant non-pulsatile polypoidal choroidal vasculopathy

*Elton Lik Tong Tay, Augustinus Laude*

National Healthcare Group Eye Institute, Tan Tock Seng Hospital, 308433, Singapore

**Correspondence to:** Elton Lik Tong Tay. Department of Ophthalmology, Tan Tock Seng Hospital, 11 Jalan Tan Tock Seng, 308433, Singapore. Elton\_tay@ttsh.com.sg  
Received: 2016-02-04 Accepted: 2016-04-12

**DOI:10.18240/ijo.2016.12.26**

Tay ELT, Laude A. Giant non-pulsatile polypoidal choroidal vasculopathy. *Int J Ophthalmol* 2016;9(12):1849-1851

**Dear Editor,**

Polypoidal choroidal vasculopathy (PCV) was first described by Yannuzzi *et al*<sup>[1]</sup> in the 1980s as a distinct choroidal abnormality. Clinically, PCV is seen as orange-red subretinal nodules<sup>[2]</sup> frequently presenting with submacular haemorrhage or serosanguinous pigment epithelial detachments (PED)<sup>[3]</sup>. Indocyanine green angiography (ICGA) provides the means to confirm the diagnosis of PCV, with angiographic features of early focal hyperfluorescence (within 6min of angiography), with or without associated branching vascular networks.

Formal PCV definitions were first proposed by the Japanese Study Group of Polypoidal Choroidal Vasculopathy, which suggested a diagnosis of "definite" PCV in the presence of protruding elevated orange-red lesions on fundus examination and/or characteristic polypoidal lesions on ICGA. A diagnosis of "probable" PCV was made if only the abnormal branching vascular network was seen on ICGA and/or presence of recurrent hemorrhagic and/or serous detachment of the retinal pigment epithelium (RPE)<sup>[4]</sup>.

More recently, the EVEREST trial defined PCV as presence of early (within 6min of dye injection) subretinal focal ICGA hyperfluorescence, plus at least one of the following angiographic or clinical criteria: association with a branching vascular network, presence of pulsatile polyp, nodular appearance when viewed stereoscopically, presence of hypofluorescent halo (in the first 6min of angiography), orange subretinal nodule on colour fundus photograph or association with massive submacular hemorrhage (at least 4 disc areas)<sup>[5]</sup>.

In this report, we describe three cases that met the EVEREST trial definition of PCV, as well as the Japanese Study Group's definition of "definite" PCV. However, they appear to be a unique subset of PCV as they presented with very large

non-pulsatile polyps with an apparent internal architecture. The cases were also more resistant to treatment. To our knowledge, this distinctive phenotypic subset of PCV has not been described before.

**Report of Cases** A 64 year-old Chinese male presented with right poor vision of uncertain duration. He was a smoker and had hypertension, hyperlipidemia, and a history of a previous cerebrovascular accident.

His right best corrected visual acuity (BCVA) on presentation was counting fingers at half metre. In the right fundus, there was an orange-red nodule associated with a half disc diameter haemorrhagic PED at the macula with surrounding subretinal fluid (SRF) and hard exudates (Figure 1).

Right eye ICGA revealed a large polyp measuring 1381  $\mu\text{m}$  (in the largest diameter). It was nodular stereoscopically, non-pulsatile, with no associated branching vascular networks (BVN). There was presence of a hypofluorescent halo around the polyp, and the polyp appeared to have an intraluminal architecture. Optical coherence tomography (OCT) showed a peaked sub-RPE lesion with SRF in the right eye. The patient declined anti-vascular endothelial growth factor (VEGF) injections in view of his vascular risk factors and opted for photodynamic therapy (PDT). He underwent 2 PDT treatments with no sustained improvement. His most recent BCVA is counting fingers closely in the right eye.

**Case 2** A 55 year-old Chinese gentleman presented with right poor vision for a month. He had hypertension and was a smoker. His right BCVA on presentation was 20/80. In the right fundus, there was an orange-red nodule seen with subretinal haemorrhage and surrounding SRF (Figure 2).

Right ICGA revealed a large polyp measuring 1388  $\mu\text{m}$  (in the largest diameter). It was nodular stereoscopically, non-pulsatile, with no associated BVN. There was presence of a hypofluorescent halo around the polyp, and the polyp appeared to have an intraluminal architecture. OCT showed a peaked sub-RPE lesion with SRF. The patient underwent 11 intravitreal ranibizumab injections. However, the SRF persisted and his most recent BCVA is 20/50.

**Case 3** A 60 year-old Chinese gentleman presented with right blurred vision for 3mo. He was a smoker with hypertension, hyperlipidemia and ischaemic heart disease. His right BCVA on presentation was 20/40. In the right fundus, there were two orange-red nodules seen with PEDs at the macula (Figure 3).

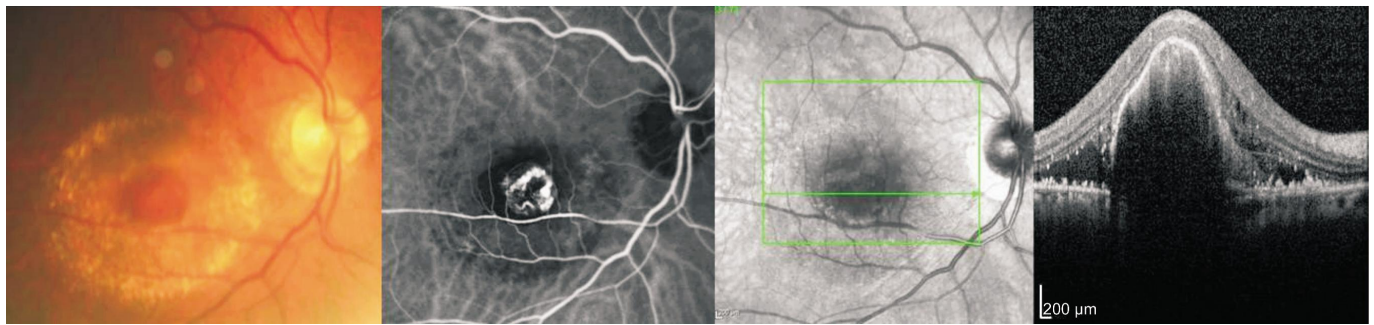


Figure 1 Case 1 fundus photo, indocyanine green angiography, and optical coherence tomography images.

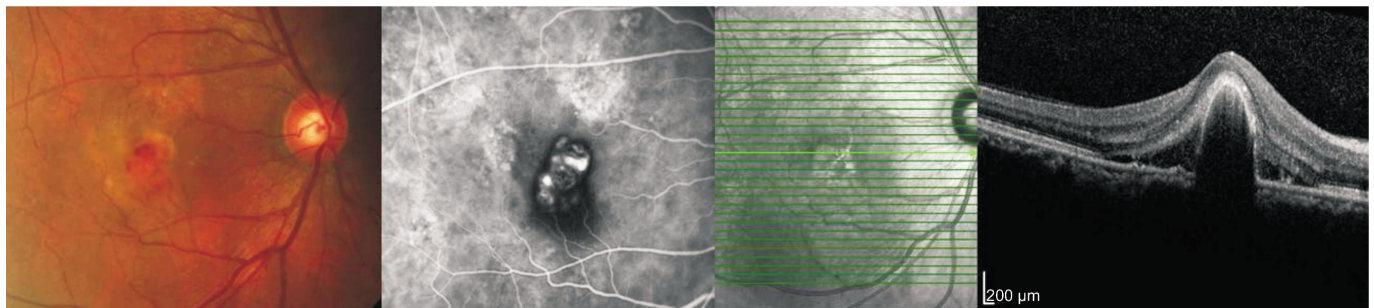


Figure 2 Case 2 fundus photo, indocyanine green angiography, and optical coherence tomography images.

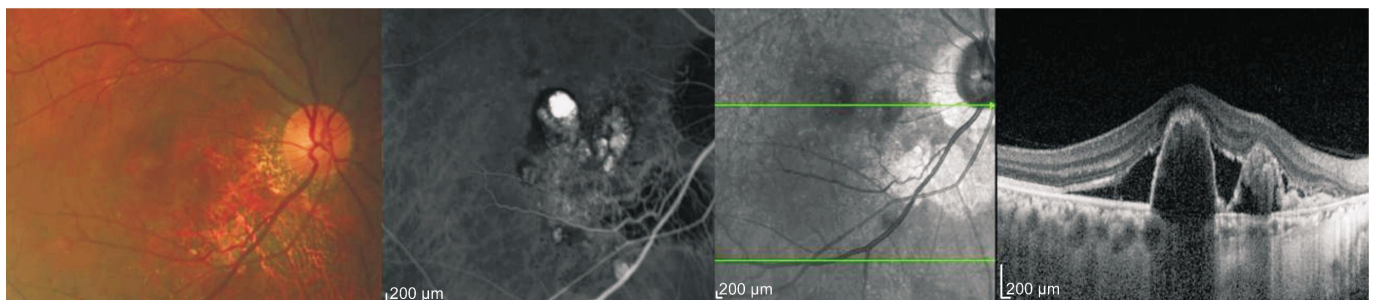


Figure 3 Case 3 fundus photo, indocyanine green angiography, and optical coherence tomography images.

ICGA revealed two large polyps measuring 1105 and 1448  $\mu\text{m}$  (in their largest diameters). They were nodular stereoscopically, were non-pulsatile, and with no associated BVN. There were presence of a hypofluorescent halos around the polyps, and the polyps appeared to have intraluminal architectures. OCT of the right eye showed two peaked sub-RPE lesions with SRF. The patient underwent 3 intravitreal ranibizumab, 3 intravitreal aflibercept injections as well as PDT with no sustained improvement. He subsequently developed a macular scar and still has minimal macula thickening. His latest BCVA is 20/40.

#### DISCUSSION

PCV lesions often vary histopathologically. Lafaut *et al*<sup>[6]</sup> described PCV as sub-RPE fibrovascular membranes containing dilated thin-walled vessels supporting the postulate that PCV could be a neovascular lesion. Another study showed histological similarities between branch retinal vein occlusion and PCV lesions, with vessel walls hyalinization<sup>[7]</sup>. Nakashizuka *et al*<sup>[8]</sup> reported histological findings of hyalinization of choroidal vessels similar to retinal macroaneurysms, and proposed that arteriosclerotic processes contributed to PCV lesions. One study compared

larger and smaller-sized PCVs and proposed that in addition to histopathological differences, large-sized PCVs could reflect later stage of disease<sup>[9]</sup>.

We present a case series of three patients with arteriosclerotic risk factors who presented with giant PCVs. In addition to similar patient profiles, the three giant PCV cases also shared clinical and angiographic similarities of very large non-pulsatile polyps with an internal architecture. We hypothesise that the internal filling pattern within the giant polyp represented angiographic dye filling up spaces around areas of partial thrombosis of stagnant blood within the lumen of the giant PCV. The intraluminal thrombosis hypothesis also supports the finding of absence of pulsatility on angiography. All cases of giant PCVs appeared more resistant to treatment, with poor visual acuity after treatment. In conclusion, we present a case series of a unique phenotype that we term giant PCV. We note that patients with giant PCV have similar risk factors of smoking, hypertension and vascular risk factors. Giant PCV have angiographic features of large non-pulsatile polyps with internal luminal architectures. Giant PCVs are also resistant to treatment with poorer resultant visual acuity. Histological studies will

benefit greater understanding of giant PCVs, and as this is a small case series, a review of more giant PCVs will elucidate more clearly its natural history and response to treatment.

#### ACKNOWLEDGEMENTS

**Conflicts of Interest:** Tay ELT, None; Laude A, None.

#### REFERENCES

- 1 Yannuzzi LA, Sorenson J, Spaide RF, Lipson B. Idiopathic polypoidal choroidal vasculopathy (IPCV). *Retina* 1990;10(1):1-8.
- 2 Yannuzzi LA, Ciardella A, Spaide RF, Rabb M, Freund KB, Orlock DA. The expanding clinical spectrum of idiopathic polypoidal choroidal vasculopathy. *Arch Ophthalmol* 1997;115(4):478-485.
- 3 Ahuja RM, Stanga PE, Vingerling JR, Reck AC, Bird AC. Polypoidal choroidal vasculopathy in exudative and haemorrhagic pigment epithelial detachments. *Br J Ophthalmol* 2000;84(5):479-484.
- 4 Japanese Study Group of Polypoidal Choroidal Vasculopathy. Criteria for diagnosis of polypoidal choroidal vasculopathy. *Nippon Ganka Gakkai Zasshi* 2005;109(7):417-427.
- 5 Koh A, Lee WK, Chen LJ, Chen SJ, Hashad Y, Kim H, Lai TY, Pilz S, Ruamviboonsuk P, Tokaji E, Weisberger A, Lim TH. EVEREST study: efficacy and safety of verteporfin photodynamic therapy in combination with ranibizumab or alone versus ranibizumab monotherapy in patients with symptomatic macular polypoidal choroidal vasculopathy. *Retina* 2012;32(8):1453-1464.
- 6 Lafaut BA, Aisenbrey S, Van den Broecke C, Bartz-Schmidt KU, Heimann K. Polypoidal choroidal vasculopathy pattern in age-related macular degeneration. A clinicopathologic correlation. *Retina* 2000;20(6):650-654.
- 7 Okubo A, Sameshima M, Uemura A, Kanda S, Ohba N. Clinicopathological correlation of polypoidal choroidal vasculopathy revealed by ultrastructural study. *Br J Ophthalmol* 2002;86(10):1093-1098.
- 8 Nakashizuka H, Mitsumata M, Okisaka S, Shimada H, Kawamura A, Mori R, Yuzawa M. Clinicopathologic findings in polypoidal choroidal vasculopathy. *Invest Ophthalmol Vis Sci* 2008;49(11):4729-4737.
- 9 Okubo A, Hirakawa M, Ito M, Sameshima M, Sakamoto T. Clinical features of early and late stage polypoidal choroidal vasculopathy characterized by lesion size and disease duration. *Graefes Arch Clin Exp Ophthalmol* 2008;246(4):491-499.