

Concurrent optic disc pit and retinal cavernous hemangioma

Alec L Amram, Renata Picciani, Jaafar El-Annan

Department of Ophthalmology and Visual Sciences, University of Texas Medical Branch, Galveston, Texas 77555, USA

Correspondence to: Alec L Amram. Department of Ophthalmology and Visual Sciences, 700 University Boulevard, Galveston, Texas 77555, USA. Alec.Amram.MD@gmail.com

Received: 2016-08-15 Accepted: 2016-09-18

DOI:10.18240/ijo.2017.01.28

Amram AL, Picciani R, El-Annan J. Concurrent optic disc pit and retinal cavernous hemangioma. *Int J Ophthalmol* 2017;10(1):168-170

Dear Editor,

We present, to the authors' knowledge, the first reported case of an optic disc pit (ODP) and retinal cavernous hemangioma (RCH) in the same eye in addition to a review of both clinical entities. An ODP is a rare congenital or acquired cavitary defect in the optic nerve head. ODPs are usually unilateral but can be bilateral in about 10% to 15% of cases. ODPs are most often located in the inferotemporal quadrant of the optic disc, although 10% to 20% occur centrally^[1]. They are usually asymptomatic but can present with progressive vision decline if associated with macular serous retinal detachment^[1]. A RCH is a benign and rare vascular hamartoma typically diagnosed in young adults or children. It usually presents as an isolated finding or as a component of an autosomal dominant syndrome with variable retinal and systemic characteristics^[2]. Herein, we report a patient with both of these rare conditions present in the same eye. Her workup included a complete eye examination, fundus photography, fundus autofluorescence photography, optical coherence tomography (OCT) and intravenous fluorescein angiogram (IVFA). This case provided the unique opportunity to review the workup and management of ODP and RCH in the same eye.

CASE REPORT

A 32-year-old Caucasian female with a known history of an ODP in the right eye, diagnosed at age 12 with early maculopapillary schisis, presented to our clinic for her annual eye exam. She had no visual complaints, changes in vision or other ocular symptoms.

Review of systems was negative for neurological symptoms or skin lesions. The patient's past medical history was significant for anxiety, depression, asthma, celiac disease, fibromyalgia,

and deep vein thrombosis. She had no history of brain masses or dermatologic history. Her family history was negative for ocular, dermatologic, and neurologic anomalies.

On examination, her best corrected visual acuity was 20/20 in both eyes. Her manifest refraction was -1.50+1.00×40 in the right eye and -1.75+1.25×120 in the left eye. Her intraocular pressure was 15 mm Hg in the right eye and 12 mm Hg in the left eye *via* Goldmann applanation. Her pupillary exam was normal without an afferent pupillary defect. Slit lamp examination of the anterior segment was unremarkable. Fundus examination of the right eye revealed a temporal optic pit, elevation of the retina in the papillomacular area, and a small cluster of dilated blood vessels in the inferonasal aspect of the retina, consistent with a vascular lesion (Figure 1A). Exam of the left eye was unremarkable. IVFA did not show any signs of leakage in the macula corresponding to the maculoschisis from the ODP (Figure 1B). IVFA of the left eye did not reveal any abnormalities.

Spectral-domain optical coherence tomography (SD-OCT) of the macula showed a small schisis cavity nasal to the fovea and demonstrated disorganization of the inner retina at the area corresponding to the inferonasal vascular lesion (Figure 2).

Autofluorescence imaging of the inferonasal vascular lesion demonstrated hypofluorescent round spots (Figure 3). IVFA showed dilated hyperfluorescent saccular lesions without leakage, consistent with a RCH (Figure 3). All tests of the left eye were unremarkable.

DISCUSSION

An ODP is a rare anomaly of the optic disc head with unclear pathogenesis. ODPs are thought to arise from an incomplete closure of the superior end of the embryonic fissure and are believed to be part of a spectrum of congenital optic disc anomalies which include optic disc coloboma, morning glory anomaly, and juxtapapillary staphyloma. Some reports describe the cavity as filled with fine interlacing tissue thought to be glial in nature^[1]. While optic disc colobomas are often familial and associated with other ocular disease and congenital or systemic abnormalities, pits are thought to have a sporadic hereditary pattern with equal gender prevalence^[3-4].

ODP can be associated with macular serous retinal detachment in 30% to 45% of cases, or can be associated with nerve fiber layer defects. There is no correlation between pit size and extent of resulting maculopathy, although larger temporal pits appear more likely to present with larger detachments^[5].

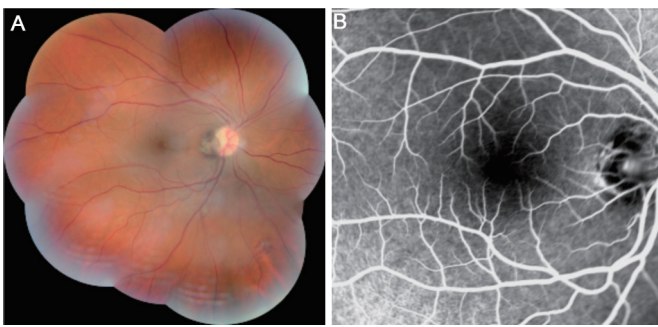


Figure 1 Fundus photo and IVFA of the right eye A: Montage fundus photograph of the right eye showing a temporal ODP and a cluster of dilated blood vessels inferonasally corresponding to the cavernous hemangioma; B: Late phase IVFA photograph (1min 40s) of the right eye showing no leakage at the macula.

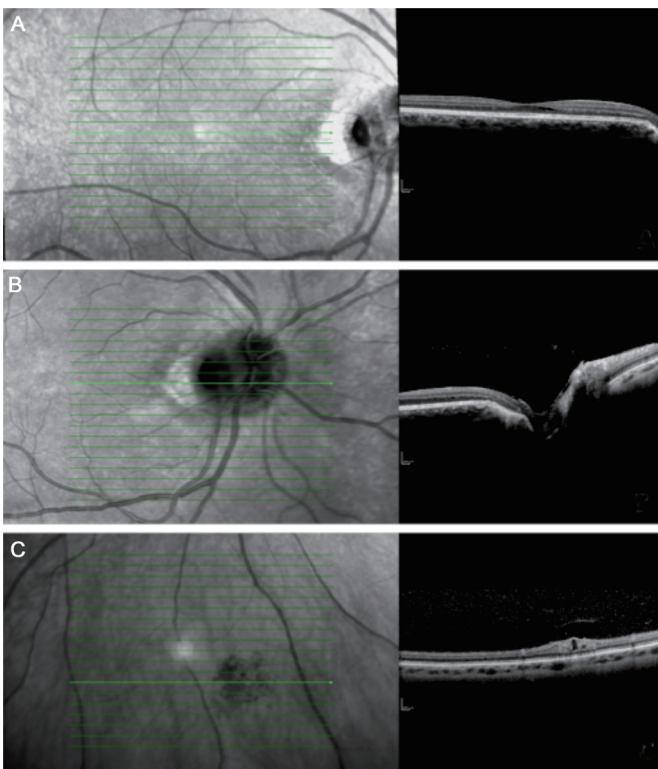


Figure 2 SD-OCT of the right eye A: Intraretinal fluid corresponding to the maculoschisis; B: Optic nerve pit; C: Cavernous hemangioma with disorganization of retinal layers.

Studies have reported that ODP may be a result of PAX2 gene mutations, as this mutation is often present in other malformations involving the optic nerve head^[4]. It has been demonstrated that unilateral ODP may be inherited in an autosomal dominant fashion, but no genetic marker has been identified^[3].

Most cases of ODP are found incidentally and are asymptomatic. In some cases, ODP can lead to a progressive decline in vision consistent with the formation and progression of a serous macular detachment^[5]. On IVFA, ODP demonstrates early hypofluorescence followed by late staining and does not leak (as was the case in our patient's testing). On OCT, findings are variable and depend on which retinal layer is affected. The source of the intraretinal fluid remains uncertain, but several studies have proposed potential mechanisms by which fluid

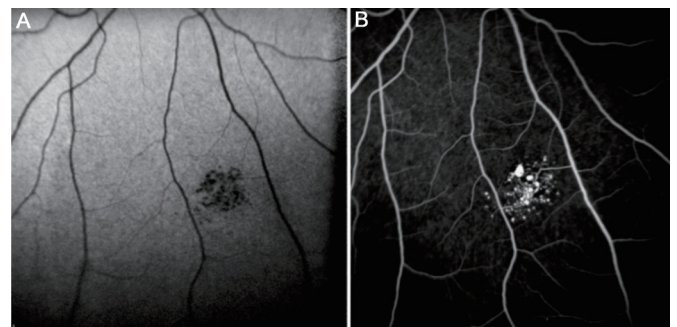


Figure 3 Autofluorescence photo and IVFA of the RCH A: Autofluorescence fundus photography showing hypofluorescent saccular lesions; B: Late phase IVFA photo showing hyperfluorescent fluorescein pooling without leakage.

could accumulate in ODP maculopathy; some argue that fluid originates from the vitreous, others from the cerebral spinal fluid (CSF). Initial resolution and restoration of visual acuity after vitrectomy followed by subsequent recurrence of ODP maculopathy in the same eye has been reported, suggesting that both vitreous and CSF may be linked to the pathophysiology of ODP macular fluid accumulation^[1].

Given the pathology involving both optic nerve and macula, any invasive intervention is at great risk of damaging these critical structures and causing permanent vision loss. Isolated optic pits are usually observed, while ODP associated with maculopathy may be treated surgically. Since the pathology and mechanism of ODP maculopathy is not completely understood, there have been many proposed treatment modalities that have shown variable visual and anatomic success^[1,5]. Some studies propose that early intervention with vitrectomy and peripapillary photocoagulation, with or without internal limiting membrane peeling and gas tamponade, may provide patients with the best chance at visual improvement, given the cystic retinal degenerative changes that occur secondary to chronicity. However, anatomic improvement may occur more slowly than visual improvement^[5]. Our patient presented with excellent visual acuity and minimal fluid on OCT located away from the fovea.

A RCH is a rare vascular retinal hamartoma composed of clusters of saccular aneurysms. They are located within the inner retina and range in size from microscopic microaneurysms to one half disc diameter. Clinical appearance can vary with wide distribution over the fundus or following the course of a major vein. Larger lesions tend to have associated preretinal gliosis from recurrent hemorrhages^[6].

RCH has distinctive fluorescein angiographic findings, including hypofluorescence in the early phases and hyperfluorescence in the later phases, usually without leakage. Depending on the lesion size, IVFA may demonstrate a fluorescein-blood level, with blood settling inferiorly and fluorescein located superiorly within the aneurysm^[6-7].

Most cases of RCH are isolated, but others may represent a

Optic disc pit and retinal cavernous hemangioma

feature in central nervous system and oculocutaneous vascular syndromes. Genetic associations include CCM1 (7q), CCM2 (7p) and CCM3 (3q) genes that encode for a protein named KRIT1, found in families with cavernous hemangiomatosis of the retina, skin, and central nervous system^[6]. Our patient did not undergo genetic testing, but a review of her family history did not reveal any ocular or dermatologic diseases or abnormalities.

RCH can be symptomatic when located in or adjacent to the macula. Visual disturbance can also occur as a result of hyphema or vitreous hemorrhage in larger lesions. The natural history of RCH is variable; lesions only grow in extremely rare cases and the majority do not require treatment. In rare cases, repeated episodes of hemorrhaging have led to fibrosis and scarring which has then led to secondary glaucoma, vitreoretinal traction and vision loss requiring treatment^[2,7]. Treatment options include photocoagulation and cryotherapy but the value of these remains unproven; periodic observation remains the standard of care^[2,7]. Our patient had no episodes of decreased vision, pain, or other symptoms and did not present with any evidence of intralesional hemorrhage.

CONCLUSION

To our knowledge, following extensive literature review, this is the first report of the simultaneous presence of an ODP and RCH in the same eye. Both conditions represent rare ocular disorders. The standard of care for each, if asymptomatic, is observation. Complications from each may require intervention as needed. An attempt was made to investigate a common

genetic or developmental element linking these two conditions, but as of now none exists.

ACKNOWLEDGEMENTS

Conflicts of Interest: Amram AL, None; Picciani R, None; El-Annan J, None

REFERENCES

- 1 Shah SD, Yee KK, Fortun JA, Albini T. Optic disc pit maculopathy: a review and update on imaging and treatment. *Int Ophthalmol Clin* 2014;54(2):61-78.
- 2 Shields CL, Honavar SG, Shields JA, Cater J, Demirci H. Circumscribed choroidal hemangioma: clinical manifestations and factors predictive of visual outcome in 200 consecutive cases. *Ophthalmology* 2001;108(12):2237-2248.
- 3 Stefko ST, Campochiaro P, Wang P, Li Y, Zhu D, Traboulsi EI. Dominant inheritance of optic pits. *Am J Ophthalmol* 1997;124(1):112-113.
- 4 Nornes HO, Dressler GR, Knapik EW, Deutsch U, Gruss P. Spatially and temporally restricted expression of Pax2 during murine neurogenesis. *Development* 1990;109(4):797-809.
- 5 McDonald HR, Schatz H, Johnson RN. Treatment of retinal detachment associated with optic pits. *Int Ophthalmol Clin* 1992;32(2):35-42.
- 6 Haghghi A, Fathi D, Shahbazi M, Motahari MM, Friedman B. Identification of a c.601C>G mutation in the CCM1 gene in a kindred with multiple skin, spinal and cerebral cavernous malformations. *J Neurol Sci* 2013;334(1-2):97-101.
- 7 Atmaca LS, Kanpolat A. Diagnosis and treatment of cavernous hemangiomas of the choroid and the retina. *Ann Ophthalmol* 1983;15(3):210-212.