

The expressions of metadherin and LEF-1 in mucosa-associated lymphoid tissue lymphoma of ocular adnexal

Dan Qi, Hong Lin, Yan Gao, Jing Lin, Li-Ting Hu, Gui-Qiu Zhao

Department of Ophthalmology, the Affiliated Hospital of Qingdao University, Qingdao 266003, Shandong Province, China

Correspondence to: Hong Lin. Department of Ophthalmology, the Affiliated Hospital of Qingdao University, No.16 Jiangsu Road, Qingdao 266003, Shandong Province, China. lh-qd@126.com

Received: 2016-09-08 Accepted: 2017-02-23

Abstract

• **AIM:** To investigate the expressions of metadherin (astrocyte elevated gene-1, AEG-1) and lymphoid enhancer-binding factor-1 (LEF-1) in ocular adnexal mucosa-associated lymphoid tissue (MALT) lymphoma.

• **METHODS:** The expressions of AEG-1 and LEF-1 were detected on specimens harvested from patients suffering from MALT lymphoma and lymphadenosis of ocular adnexal in Ophthalmology Department, Affiliated Hospital of Qingdao University from 2000 to 2015 by immunohistochemical and polymerase chain reaction (PCR) analysis.

• **RESULTS:** AEG-1 and LEF-1 expressions in MALT lymphoma was respectively higher than that in lymphadenosis, both by immunohistochemical and PCR analysis ($P<0.05$). Diversity of AEG-1 and LEF-1 expressions in different Ann Arbor clinical stages showed a statistically significant result ($P<0.05$). A positive relevance between AEG-1 and LEF-1 was observed in MALT ocular adnexal lymphoma ($r=0.435$, $P=0.016$).

• **CONCLUSION:** The over expressions of AEG-1 and LEF-1 at the level of protein and mRNA participates in the tumorigenesis of ocular adnexal MALT lymphoma. They should act as a new biological marker for pathological diagnosis in the future.

• **KEYWORDS:** ocular adnexal lymphoma; astrocyte elevated gene-1; lymphoid enhancer-binding factor-1

DOI:10.18240/ijo.2017.05.07

Qi D, Lin H, Gao Y, Lin J, Hu LT, Zhao GQ. The expressions of metadherin and LEF-1 in mucosa-associated lymphoid tissue lymphoma of ocular adnexal. *Int J Ophthalmol* 2017;10(5):705-710

INTRODUCTION

Mucosa-associated lymphoid tissue (MALT) lymphoma known as extranodal marginal zone B-cell lymphoma is among the commonest histological subset^[1], cover around 35% to 90% of primary ocular adnexal lymphoma cases^[2]. MALT lymphoma, usually presenting an indolent course, frequently relaps in various extranodal sites^[3]. Generally, the neoplasm can be found on different sites on ocular adnexal, ranging from eyelid, conjunctiva, lacrimal gland to orbita. This usually bring some bad effects to patients, such as mass nodular, painful swelling, dry eye symptoms, diplopia, strabism, even decreased vision to some extent. What's more, with the incidence of this disease rising up recently, researchers are increasingly interested in figuring out its pathogenesis. The former studies have found its connection with microorganism infection, such as helicobacter pylori (Hp) or Chlamydomphila psittaci (Cp), and with autoimmunologically mediated diseases^[4]. But it is fewer about oncogene and molecular mechanism.

Metadherin, also known as astrocyte elevated gene-1 (AEG-1), introduced in primary human fetal astrocytes initially^[5-6], has been probed overexpression in many mankind malignancies, such as non-small lung cell cancer, breast cancer, esophageal cancer and so on^[7-9]. Furthermore, researches support of AEG-1 association with neoplasm development, evolution, metastasis and invasion. As previous studies elucidated, AEG-1 contribute to tumor progression and evolution by activating abnormally various oncogenic signaling pathways such as phosphatidylinositol 3-kinase (PI3K)/Akt, nuclear factor-kappaB (NF- κ B), and wntless and INT-1 (Wnt)/ β -catenin pathways and so forth^[10-11]. Ordinarily, the regulation of Wnt signaling pathway also works in physiological progression, including embryo development and keeping organs and tissues in adults. However, it appears to a driving force in many malignancies^[12-13]. It is supposed that AEG-1 brings about β -catenin the vital element of Wnt/ β -catenin pathway nuclear translocation then upregulates different target gene expressions, by activating the Raf/MEK/mitogen-activated protein kinases (MAPK) signal pathway in hepatocellular carcinoma cells^[14]. Lymphoid enhancer-binding factor 1 (LEF-1), a major transcription factor of Wnt pathway, is one member of the LEF/T cell factors (TCFs) transcription factor family^[15-16]. LEF/TCFs are DNA binding transcription factors, functioning

in Wnt signaling channel, by raising β -catenin to nucleus for target genes expression^[17]. It acts as an executive of transcription. Specific inhibitor, AEG-1 siRNA, visibly down-regulated LEF-1 expression. Researchers assumed that AEG-1 may be a participator in gastric carcinoma evolvement, which may depend on Wnt pathway^[18] and this role of the oncogene has been studied in many tissues. However, little is known in ocular adnexal MALT lymphoma. Consequently, we hypothesize that the two factors, AEG-1 and LEF-1, may give play to crucial effect on MALT and participate in the pathogenesis of MALT.

The current study aims to detect the expression of AEG-1 and LEF-1 in ocular adnexal MALT lymphoma by immunohistochemistry and real-time polymerase chain reaction (RT-PCR)

SUBJECTS AND METHODS

Specimens' Collection This study collected 30 specimens of ocular adnexal lymphoma (which has been diagnosed as MALT lymphoma by immunohistochemical in our institution) at the Pathological Lab of Ophthalmology Department, Affiliated Hospital of Qingdao University from 2000 to 2015. There are No.5, No.7, No.4 and No.14 samples respectively taken from eyelid, conjunctiva, lacrimal gland and orbita. The total specimens include 19 males and 11 females, 16 beyond an age of 60, and 14 below 60. According to Ann Arbor clinical stage, the specimens from I to IV phase were 20, 8, 1 and 1 respectively. Of 20 cases of reactive hyperplastic lymphadenopathy were used as negative control. The patients' agreement and favor from the Institutional Research Ethics Committee were acquired for research purposes.

Hematoxylin Eosin and Immunohistochemical Staining

The tissues from various stages were made to paraffin section and hematoxylin eosin (HE) staining. Of 3- μ m-thick paraffin sections were cut on a microtome (CM1900; Leica Microsystems, Deerfield, IL, USA) and then mounted onto glass slides with 100 g/L polylysine. Immunohistochemical staining proceeded in the light of the manufacturer's specification [SP kit (Biosynthesis Biotechnology)]. In short, after deparaffinising in xylene and dehydrating in ethanol, the sections were immersed in a citrate buffer and heated under high pressure steam for 15min to retrieve antigens, then immersed in 3% H₂O₂ for 15min to inactivate endogenous peroxidase. After washing three times with phosphate buffered saline (PBS), the sections were incubated with either rabbit anti-AEG-1 monoclonal antibody (1:400) or rabbit anti-LEF-1 monoclonal antibody (1:400) (Abcam Company) for 3h at room temperature before washing three times with PBS. After that, keeping these sections incubated with horseradish peroxidase labeled goat anti-rabbit polymer (Zhong Shan-Golden Bridge Biological Technology) for 20min at 37 °C. After washing three times with PBS, the sections was

stained by diaminobenzidine, and then dyed by hematoxylin counterstain. Neutral balsam was used for sealing all specimens for microscopy observation. Instead of the primary antibody, PBS was also used for negative control. Specificity of primary antibody was also examined on reactive lymphoid hyperplasia. The positive expression appears as diffuse brown yellow particles located in nucleus or in cytoplasm.

Selection of five typical regions at random, with 1000 cells in all (200 for each field), were observed under a high-power optical microscope for 400. The status was evaluated independently by at least two researchers. Moreover, immunostaining categories based on the positive cells percent, grade score was as follows: 0: <5%; 1: 5%-25%; 2: 25%-50%; 3: 50%-75%; and 4: >75%; the staining intensity was classified into the following status: 1=weak staining; 2=moderate staining; 3=strong staining. Multiply the grade score of positive tumor cells percent by staining intensity, a value was got for every case, of which value <1 was determined negative otherwise positive^[19].

Real-time Polymerase Chain Reaction RNA was extracted from dissolved aim tissues, with the TRIzol reagent, according to the manufacturer's recommendations. Of 1 μ L RNA is used for reverse transcriptase cDNA (single chain cDNA synthesis kit), which conduct in the total volume of 20 μ L system. During this procedure, cDNA acts as a template, and specific primers involved. RT-PCR analysis the expression of AEG-1 and LEF-1 mRNA, and β -actin acted as an internal control. Briefly, SybrGreen qPCR Master Mix (2 \times) 10 μ L, 0.5 μ L primer F, 0.5 μ L primer R, 7 μ L dH₂O, 2 μ L cDNA. PCR amplification conditions: 95 °C denaturation for 15s, 60 °C annealing and extension for 1min, 40 cycles. Calculation of the expression of the sample by standard curve compares to internal reference β -actin. β -actin primer sequence: F-GATTACTGCTCTGGCTCCTAGC, R-GACTCATCGTACTCCTGCTTGC; AEG-1 primer sequence: F-TTACCACCGAGCAACTTACAAC, R-ATTCCAGCCTCCTCCATTGAC; LEF-1 primer sequence: F-GACGAGATGATCCCCTTCAA, R-AGGGCTCCTGAGAGGTTTGT, these sequences were referenced to literature^[20].

Statistical Analysis SPSS17.0 software was used for statistical analysis (SPSS, Chicago, IL, USA). The statistically different expressions of AEG-1 and LEF-1 among groups were determined by χ^2 tests, among the stages were determined by Fishers' exact probabilities. The mutual relation between AEG-1 and LEF-1 was analyzed by Spearman correlation test. PCR result analysis was manifested by one-way ANOVA and both mutual compares in LSD test. *P* value of <0.05 was considered statistically significant.

RESULTS

Real-time Polymerase Chain Reaction Our current result

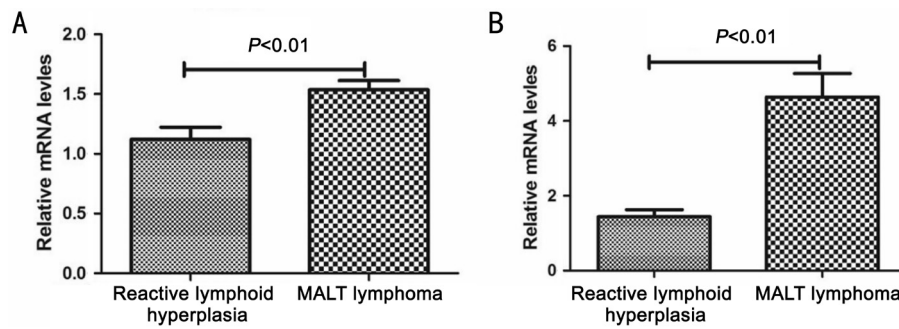


Figure 1 AEG-1 and LEF-1 mRNA expression in reactive lymphoid hyperplasia and MALT lymphoma A: AEG-1 mRNA expression in MALT lymphoma was higher than that in reactive lymphoid hyperplasia, significantly ($P < 0.01$); B: LEF-1 mRNA expression in MALT lymphoma was marked higher than reactive lymphoid hyperplasia ($P < 0.001$).

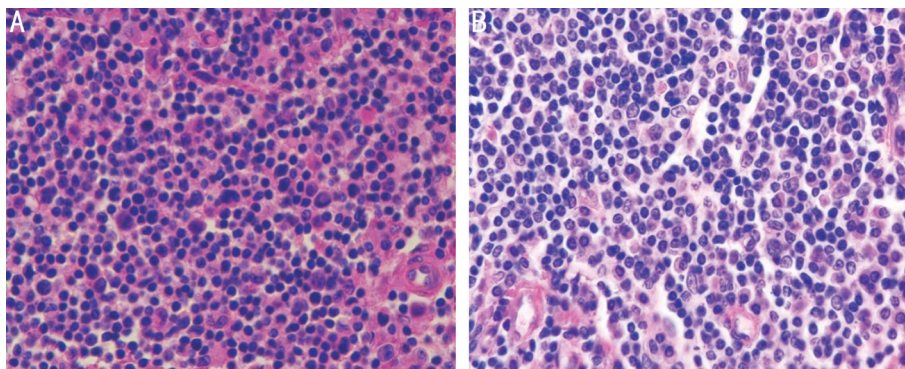


Figure 2 HE staining of reactive lymphoid hyperplasia and MALT lymphoma A: A compound of plasma cells, histiocytes, and small lymphocytes and a sporadic network of thin-walled capillaries were seen in reactive lymphoid hyperplasia ($\times 400$); B: The image of MALT ocular adnexal lymphoma consist of monotonous pattern of small cell lymphocytes with round or irregular nuclei and clustered chromatin, un conspicuous nucleoli and deficient cytoplasm ($\times 400$).

indicated that AEG-1 and LEF-1 mRNA was distinctly higher in most MALT lymphoma tissues than in the reactive lymphoid hyperplasia ($P < 0.001$; Figure 1A, 1B).

Hematoxylin Eosin Staining There are normal follicular structures in reactive lymphoid hyperplasia tissues which consisted of different patterns of mature lymphocytes and is scattered with plasmocytes, histocytes and immunoblasts (Figure 2A). The samples of MALT lymphoma was composed of diffuse, similar and small lymphocytes which appeared as irregular nucleus, deep stain. Considering as high-differentiated and moderately-differentiated lymphoma (Figure 2B).

Immunohistochemical Staining

Expression of astrocyte elevated gene-1 in mucosa-associated lymphoid tissue lymphoma The result shows that a positive staining, brown yellow particles accumulating, mainly appears much membrane, less cytoplasm (Figure 3B, 3C). Furthermore, difference of AEG-1 protein expressions in various Ann Arbor clinical stage shows a statistical meaning ($P < 0.05$; Table 1), but no relation when it comes to the age, gender, or occurrence site. We examined higher proportion of AEG-1 positive staining in MALT lymphoma (73.3%) than that in reactive lymphoid hyperplasia (20%) significantly ($P < 0.05$; Table 2). While there was almost no positive staining in control group (Figure 3A).

Expression of lymphoid enhancer-binding factor-1 in mucosa-associated lymphoid tissue lymphoma

As the result shows, the positive staining primarily was apparently detected in nucleus (Figure 4B, 4C). We examined a higher rate of expression of LEF-1 in MALT lymphoma (53.3%) than in reactive lymphoid hyperplasia (10%) significantly ($P < 0.05$; Table 2). In addition, LEF-1 protein high expression represent remarkable diversity among different Ann Arbor clinical stage ($P < 0.05$; Table 1). However, the relationship cannot be found, when involving the age, gender, and occurrence site. However no positive staining detected in control group (Figure 4A).

Mutual relation between AEG-1 and LEF-1 in mucosa-associated lymphoid tissue lymphoma Our datas revealed a positive relation between the expression of AEG-1 and that of LEF-1 in MALT lymphoma ($r = 0.435$, $P < 0.05$; Table 3).

DISCUSSION

Ocular adnexal lymphomas (OAL) are histological heterogeneous malignancies, reaching up to 55% of all orbital tumors^[21]. MALT was recognized as the most common histological subtype. However, we did know little about the pathogenesis of this disease at present. There remains much more to be explored for the future therapy. Reviewing the numerous previous papers, AEG-1, an oncogene, have involvement in tumor generation and evolution, irregularly expressive

Table 1 Relationship between expressions of AEG-1 and LEF-1 and clinical characteristics of ocular adnexal MALT lymphoma *n* (%)

Characteristics	<i>n</i>	Positive expression of AEG-1	¹ <i>P</i>	Positive expression of LEF-1	² <i>P</i>
Age (a)			0.689		0.730
≥60	16	11 (68.8)		8 (50.0)	
<60	14	11 (78.6)		8 (57.1)	
Gender			0.417		1.000
M	19	15 (73.7)		10 (52.6)	
F	11	7 (72.8)		6 (54.5)	
Current site			1.000		0.950
Orbita	14	10 (78.6)		8 (57.1)	
Eyelid	5	3 (60.0)		3 (60.0)	
Conjunctiva	7	5 (71.4)		3 (42.8)	
Lacrimal gland	4	3 (75.0)		2 (50.0)	
Ann Arbor stage			0.036 ^a		0.016 ^a
I	20	17 (85.0)		7 (35.0)	
II	8	3 (37.5)		7 (87.5)	
III	1	1 (100.0)		1 (100.0)	
IV	1	1 (100.0)		1 (100.0)	

The expression rate of AEG-1 and LEF-1 was significant in different Ann Arbor stage. ¹*P* value for positive expression of AEG-1, ²*P* value for positive expression of LEF-1. ^a*P*<0.05.

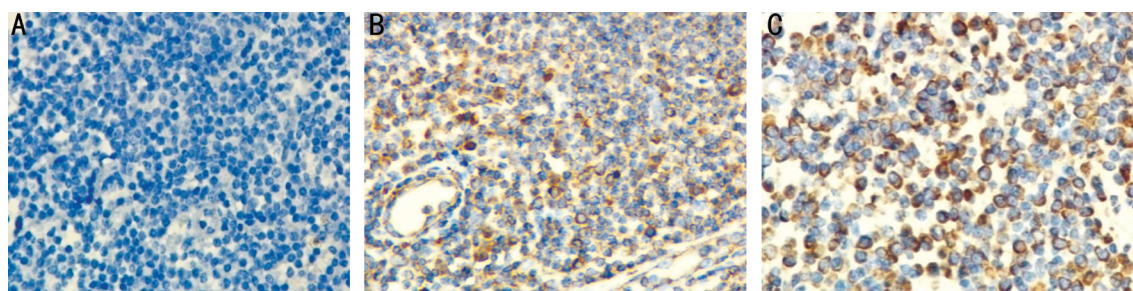


Figure 3 AEG-1 expression in reactive lymphoid hyperplasia and MALT lymphoma A: No expression of AEG-1 in either cytoplasm or nucleus of reactive lymphoid hyperplasia (×400); B: Cytoplasm weak expression of AEG-1 in MALT, with many little brown yellow particles (×400); C: Cytoplasm strong expression of AEG-1 in MALT lymphoma (×400).

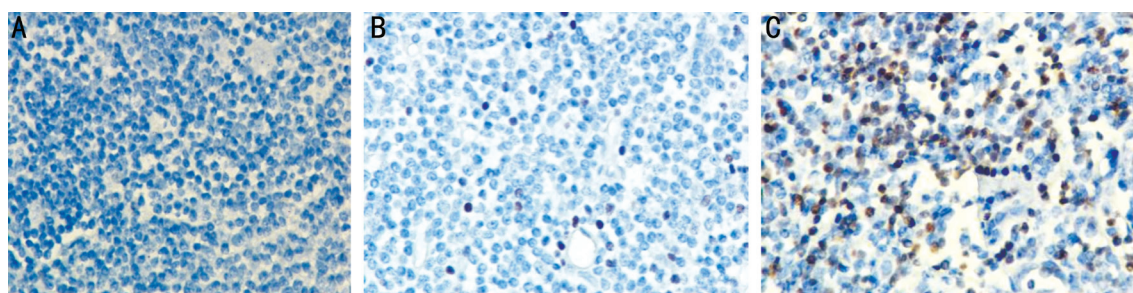


Figure 4 LEF-1 expression in reactive lymphoid hyperplasia and MALT lymphoma A: No expression of LEF-1 in reactive lymphoid hyperplasia (×400); B: LEF-1 nucleus weak expression in MALT lymphoma (×400); C: LEF-1 nucleus strong expression in MALT lymphoma (×400).

in diversified human malignancies, containing nervous^[22], urogenital^[23], respiratory^[7], digestive^[9] and Hemic and Lymphatic Systems^[20]. LEF-1 broadly positive emerging in growth tissues during embryogenesis, but is limited to hair follicle bulbs, pre-B and pre-T lymphocytes in adulthood^[24-25]. In addition, LEF-1 was observed an elevation in some blood system malignancies. More evidences have been found the

two factors playing a role in hematological malignancies. We determined to detect their expression situation in ocular adnexal lymphoma.

The current exploration manifested that AEG-1, highly expressive in the cytoplasm, correlated significantly with the development and progress of ocular adnexal MALT. Our study discovered AEG-1 expressive elevation either at mRNA or

Table 2 The expression of AEG-1 and LEF-1 in MALT lymphoma and reactive lymphoid hyperplasia

Groups	n	n (%)	
		Positive expression of AEG-1	Positive expression of LEF-1
Reactive lymphoid hyperplasia	20	4 (20.0)	2 (10.0)
MALT	30	22 (73.3)	16 (53.3)
χ^2		13.675	9.780
P		0.00	0.02

The positive ratio of AEG-1 and of LEF-1 in MALT lymphoma was significantly higher than those in reactive lymphoid hyperplasia ($P<0.05$).

Table 3 The relation between AEG-1 and LEF-1 in MALT lymphoma

AEG-1	LEF-1			n
	-	+	++	
-	6	2	0	8
+	5	4	1	10
++	3	6	3	12

These data revealed a significant correlation between AEG-1 and LEF-1 in MALT lymphoma ($r=0.435$, $P=0.016$).

at protein in ocular adnexal MALT tissues. Besides, 73.3% (22/30) of MALT samples positively express AEG-1 protein presented by immunohistochemical staining, while the control group detected only little expression. Corresponding with outcome of immunohistochemical staining, the amount of AEG-1 mRNA is as much again as its counterparts. Dong *et al*^[19] demonstrated that overexpression of AEG-1 at the level of protein and mRNA is relation to metastasis, Ann Arbor clinical stage, and poor prognosis in gastric cancer. Integrated the clinical characters of MALT patients, the different ratio of highly expressive AEG-1 along with the Ann Arbor clinical stage indicated a statistical significance in MALT, nevertheless this is not exist in age, gender of patients or tumorous location. Consequently, the state of our protein expression was in consistent with the former researches.

LEF-1, the core factor of Wnt pathway, participated in transcription of tumor cell by conjunction to DNA combanding region. The outcome of our study indicated that 16/30 (53.3%) MALT samples showed a positive nuclear staining, with little expression of LEF-1 in its counterparts. Simultaneously, high expression of LEF-1 mRNA in tumor tissue had been examined compared with reactive lymphoid hyperplasia. This high expression of protein and mRNA is accordance with the accumulating evidences demonstrated in several malignancies, including colorectal^[26], prostate^[27], and leukemia^[28]. Moreover, some researchers found that LEF-1 is linked with tumor migration and invasion. Liang *et al*^[29] illustrated LEF1-miR-181 engaging in prostate cancer epithelial-mesenchymal transition process which specifically modulate subsequent migration and invasion.

Additionally, Walther *et al*^[30] detected devoid of expression of LEF-1 in (0/6) marginal zone B-cell lymphoma by Immunohistochemistry, when studying the mechanism of LEF-1 in Burkitt's lymphoma. It's opposite to our result. Our expression of LEF-1 mRNA in test group is five times more than that in control group. This finding corresponds to the demonstration of Kühnl *et al*^[31]. Together the clinical characters of MALT patients, the expression of LEF-1 displays a strongly correlation to the Ann Arbor clinical stage of patients with MALT lymphoma. However, this relationship has not been seen in age, gender or occurrence site. This indicated that expression of LEF-1 increases along with the grade of the tumor stage.

For the present, we found a positive relation between AEG-1 and LEF-1 expression in MALT lymphoma, and their high expression in association with tumor differentiation. Giving the limited samples, we only got the evidence of AEG-1 and LEF-1 involving the development of ocular adnexal MALT lymphoma. AEG-1 overexpression, testified in many mankind malignancies, promoted tumor formation through NF- κ B, PI3K/Akt and Wnt/ β -catenin pathways^[10-11]. As is known, Wnt signaling pathway regulate either of B-cell development or self-renewal of hematopoietic stem cells^[32]. By implication, AEG-1 may have effect on Wnt signal pathway. However, to figure out the two factors' pattern of interaction remains further researches.

To summarize, these research findings herein delivered that AEG-1 and LEF-1 overexpression is probably connected with the tumorigenesis of MALT. There is a positive correlation between AEG-1 and LEF-1 in ocular adnexal MALT.

ACKNOWLEDGEMENTS

Foundation: Supported by Public Domain of Science and Technology Project of Qingdao, Shandong Province, China (NO.2012-1-3-2-14-snh).

Conflicts of Interest: Qi D, None; Lin H, None; Gao Y, None; Lin J, None; Hu LT, None; Zhao GQ, None.

REFERENCES

- Ferry JA, Fung CY, Zukerberg L, Lucarelli MJ, Hasserjian RP, Preffer FI, Harris NL. Lymphoma of the ocular adnexa: a study of 353 cases. *Am J Surg Pathol* 2007;31(2):170-184.
- Cho EY, Han JJ, Ree HJ, Ko YH, Kang YK, Ahn HS, Ahn SD, Park CJ, Huh J. Clinicopathologic analysis of ocular adnexal lymphomas: extranodal marginal zone b-cell lymphoma constitutes the vast majority of ocular lymphomas among Koreans and affects younger patients. *Am J Hematol* 2003;73(2):87-96.
- Coupland SE, Hummel M, Stein H. Ocular adnexal lymphomas: five case presentations and a review of the literature. *Surv Ophthalmol* 2002; 47(5):470-490.
- Auw-Hädrich C, Göbel N, Illerhaus G. Infectious agents in ocular adnexal tumours. *Klin Monbl Augenheilkd* 2010;227(7):530-537.

- 5 Su ZZ, Kang DC, Chen Y, Pekarskaya O, Chao W, Volsky DJ, Fisher PB. Identification and cloning of human astrocyte genes displaying elevated expression after infection with HIV-1 or exposure to HIV-1 envelope glycoprotein by rapid subtraction hybridization, RaSH. *Oncogene* 2002;21(22):3592-3602.
- 6 Kang DC, Su ZZ, Sarkar D, Emdad L, Volsky DJ, Fisher PB. Cloning and characterization of HIV-1-inducible astrocyte elevated gene-1, AEG-1. *Gene* 2005; 353(1):8-15.
- 7 Ke ZF, Mao X, Zeng C, He S, Li S, Wang LT. AEG-1 expression characteristics in human non-small cell lung cancer and its relationship with apoptosis. *Med Oncol* 2013;30(1):383.
- 8 Tokunaga E, Nakashima Y, Yamashita N, Hisamatsu Y, Okada S, Akiyoshi S, Aishima S, Kitao H, Morita M, Maehara Y. Overexpression of metadherin/MTDH is associated with an aggressive phenotype and a poor prognosis in invasive breast cancer. *Breast Cancer* 2014;21(3):341-349.
- 9 Yu C, Chen K, Zheng H, Guo X, Jia W, Li M, Zeng M, Li J, Song L. Overexpression of astrocyte elevated gene-1 (AEG-1) is associated with esophageal squamous cell carcinoma (ESCC) progression and pathogenesis. *Carcinogenesis* 2009;30(5):894-901.
- 10 Hu G, Wei Y, Kang Y. The multifaceted role of MTDH/AEG-1 in cancer progression. *Clin Cancer Res* 2009;15(18):5615-5620.
- 11 Emdad L, Das SK, Dasgupta S, Hu B, Sarkar D, Fisher PB. AEG-1/MTDH/LYRIC: signaling pathways, downstream genes, interacting proteins, and regulation of tumor angiogenesis. *Adv Cancer Res* 2013;120:75-111.
- 12 Clevers H, Loh KM, Nusse R. Stem cell signaling. An integral program for tissue renewal and regeneration: Wnt signaling and stem cell control. *Science* 2014;346(6205):1248012.
- 13 Anastas JN, Moon RT. WNT signalling pathways as therapeutic targets in cancer. *Nat Rev Cancer* 2013;13(1):11-26.
- 14 Yoo BK, Emdad L, Su ZZ, Villanueva A, Chiang DY, Mukhopadhyay ND, Mills AS, Waxman S, Fisher RA, Llovet JM, Fisher PB, Sarkar D. Astrocyte elevated gene-1 regulates hepatocellular carcinoma development and progression. *J Clin Invest* 2009;119(3):465-477.
- 15 Waterman ML, Fischer WH, Jones KA. A thymus-specific member of the HMG protein family regulates the human T cell receptor C alpha enhancer. *Genes Dev* 1991;5(4):656-669.
- 16 Li TW, Ting JH, Yokoyama NN, Bernstein A, van de Wetering M, Waterman ML. Wnt activation and alternative promoter of LEF-1 in colon cancer. *Mol Cell Biol* 2006;26(14):5284-5299.
- 17 Miyake T, Tanaka Y, Kato K, Tanaka M, Sato Y, Ijiri R, Inayama Y, Ito Y, Aoki S, Kawabe R, Tohnai I. Gene mutation analysis and immunohistochemical study of beta-catenin in odontogenic tumors. *Pathol Int* 2006;56(122006):732-737.
- 18 Jian-bo X, Hui W, Yu-long H, Chang-hua Z, Long-juan Z, Shi-rong C, Wen-hua Z. Astrocyte-elevated gene-1 overexpression is associated with poor prognosis in gastric cancer. *Med Oncol* 2011;28(2):455-462.
- 19 Dong L, Qin S, Li Y, Zhao L, Dong S, Wang Y, Zhang C, Han S. High expression of astrocyte elevated gene-1 is associated with clinical staging, metastasis, and unfavorable prognosis in gastric carcinoma. *Tumor Biol* 2015;36(3):2169-2178.
- 20 Li PP, Yao QM, Zhou H, Feng LL, Ge XL, Lv X, Chen N, Lu K, Wang X. Metadherin contribute to BCR signaling in chronic lymphocytic leukemia. *Int J Clin Exp Pathol* 2014;7(4):1588-1594.
- 21 Bayraktar S, Bayraktar UD, Stefanovic A, Lossos IS. Primary ocular adnexal MALT lymphoma: single institution experience in a large cohort of patients. *Br J Haematol* 2011;152(1):72-80.
- 22 Noch EK, Khalili K. The role of AEG-1/MTDH/LYRIC in the pathogenesis of central nervous system disease. *Adv Cancer Res* 2013;120:159-192.
- 23 Nikpour M, Emadi-Baygi M, Fischer U, Niegisch G, Schulz WA, Nikpour P. MTDH/AEG-1 contributes to central features of the neoplastic phenotype in bladder cancer. *Urol Oncol* 2014;32(5):670-677.
- 24 Reya T, O'Riordan M, Okamura R, Devaney E, Willert K, Nusse R, Grosschedl R. Wnt signaling regulates B lymphocyte proliferation through a LEF-1 dependent mechanism. *Immunity* 2000;13(1):15-24.
- 25 Petropoulos K, Arseni N, Schessl C, Stadler CR, Rawat VP, Deshpande AJ, Heilmeyer B, Hiddemann W, Quintanilla-Martinez L, Bohlander SK, Feuring-Buske M, Buske C. A novel role for Lef-1, a central transcription mediator of Wnt signaling, in leukemogenesis. *J Exp Med* 2008;205(3):515-522.
- 26 Wang WJ, Yao Y, Jiang LL, Hu TH, Ma JQ, Ruan ZP, Tian T, Guo H, Wang SH, Nan KJ. Increased LEF1 expression and decreased Notch2 expression are strong predictors of poor outcomes in colorectal cancer patients. *Dis Markers* 2013;35(5):395-405.
- 27 Wu L, Zhao JC, Kim J, Jin HJ, Wang CY, Yu J. ERG is a critical regulator of Wnt/LEF1 signaling in prostate cancer. *Cancer Res* 2013;73(19):6068-6079.
- 28 Metzeler KH, Heilmeyer B, Edmaier KE, Rawat VP, Dufour A, Döhner K, Feuring-Buske M, Braess J, Spiekermann K, Büchner T, Sauerland MC, Döhner H, Hiddemann W, Bohlander SK, Schlenk RF, Bullinger L, Buske C. High expression of lymphoid enhancer-binding factor-1 (LEF1) is a novel favorable prognostic factor in cytogenetically normal acute myeloid leukemia. *Blood* 2012;120(10):2118-2126.
- 29 Liang J, Li X, Li Y, Wei J, Daniels G, Zhong X, Wang J, Sfanos K, Melamed J, Zhao J, Lee P. LEF1 targeting EMT in prostate cancer invasion is mediated by miR-181a. *Am J Cancer Res* 2015;5(3):1124-1132.
- 30 Walther N, Ulrich A, Vockerodt M, von Bonin F, Klapper W, Meyer K, Eberth S, Pukrop T, Spang R, Trümper L, Kube D. Aberrant lymphocyte enhancer-binding factor 1 expression is characteristic for sporadic Burkitt's lymphoma. *Am J Pathol* 2013;182(4):1092-1098.
- 31 Kühnl A, Gökbuget N, Kaiser M, Schlee C, Stroux A, Burmeister T, Mochmann LH, Hoelzer D, Hofmann WK, Thiel E, Baldus CD. Overexpression of LEF-1 predicts unfavorable outcome in adult patients with B-precursor acute lymphoblastic leukemia. *Blood* 2011;118(24):6362-6367.
- 32 Ugarte GD, Vargas MF, Medina MA, León P, Necuñir D, Elorza AA, Gutiérrez SE, Moon RT, Loyola A, De Ferrari GV. Wnt signaling induces transcription, spatial proximity, and translocation of fusion gene partners in human hematopoietic cells. *Blood* 2015;126(15):1785-1789.