

Pivot concept: achieving a good-quality capsulorrhexis through a 2.2 mm or less clear corneal incision by using standard capsulorrhexis forceps

Hung-Yuan Lin^{1,2,3}, Ya-Jung Chuang^{1,4,5}, Xin Tang⁶, Chun-Chang Lin⁵, Hsin-Yang Chen⁵, Pi-Jung Lin⁵

¹Department of Ophthalmology, Universal Eye Center, Zhong-Li Branch, Taoyuan 320, Taiwan, China

²Department of Optometry, Central Taiwan University of Science and Technology, Taichung 406, Taiwan, China

³Department of Ophthalmology, the First Affiliated Hospital of Fujian Medical University, Fuzhou 350003, Fujian Province, China

⁴Department of Ophthalmology, Universal Eye Center, Long-Tan Branch, Taoyuan 325, Taiwan, China

⁵Department of Ophthalmology, Universal Eye Center, Taipei Branch, Taipei 115, Taiwan, China

⁶Tianjin Eye Hospital, Tianjin 300020, China

Correspondence to: Ya-Jung Chuang, Department of Ophthalmology, Universal Eye Center, Zhong-Li Branch, No.212, Zhong-Shan Road, Zhong-Li City, Taoyuan Country 320, Taiwan, China. ranny.chuang@eyecenter.com.tw

Received: 2016-06-30 Accepted: 2016-12-05

DOI:10.18240/ijo.2017.07.25

Lin HY, Chuang YJ, Tang X, Lin CC, Chen HY, Lin PJ. Pivot concept: achieving a good-quality capsulorrhexis through a 2.2 mm or less clear corneal incision by using standard capsulorrhexis forceps. *Int J Ophthalmol* 2017;10(7):1175-1177

Dear Editor,

I am Dr. Hung-Yuan Lin, from the Universal Eye Center, Taiwan, China. I write to present one of the crucial techniques that enables easy maneuverability for ophthalmologists who perform the conventional method, which requires a corneal incision of 2.75-3.0 mm in width shifted to microincision phacoemulsification that only requires a corneal incision of 1.8-2.2 mm in width.

In 2014 APACRS survey and trends, we noted there are nearly 40% of cataract surgery with 2.8 mm clear corneal incision (CCI)^[1]. Learning to achieve an adequate capsulorrhexis following a shift in surgical techniques from conventional coaxial phacoemulsification to coaxial microincision cataract surgery (C-MICS) can be challenging, especially when attempting to create a quality circular continuous curvilinear capsulorrhexis (CCC) through a smaller incision using standard capsulorrhexis forceps. Some surgeons have performed CCC

in larger corneal wounds by moving the capsulorrhexis forceps in a parallel direction (Figure 1). Consequently, when the size of the CCI is reduced, it becomes difficult to achieve a well centered and amply sized CCC due to the tight fit of the capsulorrhexis forceps inside the main incision. Further, the decreased size of the incision reduces maneuverability and places local stress on the wound, which distorts the corneal surface and reduces visualization.

Many microincision capsulorrhexis forceps have been designed to accommodate smaller incisions and the subsequently reduced access size for achieving an adequate capsulorrhexis. But a learning curve always exists when using different types of forceps and that will increase risk factors for occurrence of intra-operative complications during phacoemulsification performed by inexperienced surgeon. Herein, we would like to share our experience that employs the same standard straight-shank capsulorrhexis forceps (Figure 2) used for single instrument capsulorrhexis procedures with different CCI widths (Figure 3).

We intend to introduce the pivot concept, that require any surgical instruments used for phacoemulsification, including standard capsulorrhexis forceps, to be centered on a fixed pivot point within the CCI to allow for a wide range of movement (Figure 4). When performing the CCC, the forceps shaft is supported between the thumb and the middle finger and the forefinger rests on the top of the shaft with keep the wrist steady and make small movements of the fingers to move the forceps tip in different direction to create curved line, both hands move together and where one hand stabilizes and the other manipulates (Figure 5). The hand of operator holding the instrument must move toward the right to shift the tip of the instrument toward the left (Figure 5). Similarly, to move the instrument downward, the back end of the instrument must be shifted upward. Further, with a fixed pivot point large movements outside the cornea produce only limited movement inside the eye^[2]. Another key point for accomplishing a consistent sized capsulorrhexis is that after a curving tear is directed radially to the desired diameter of the CCC, the flap must be grasped with the capsulorrhexis forceps, and the traction applied tangentially in the desired direction. Thus, the curvature angle must be larger (Figure 6) to achieve a similar

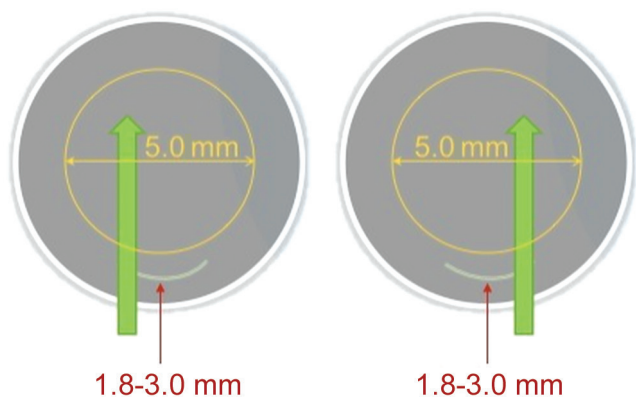


Figure 1 Movement of surgical instruments, including capsulorrhexis forceps, in a parallel direction such that it pushes on any edge of the incision; the actions can cause extensive corneal deformation, coupled with striae, which impairs the surgical view.




Figure 2 Standard straight-shank capsulorrhexis forceps used for single instrument capsulorrhexis procedure.

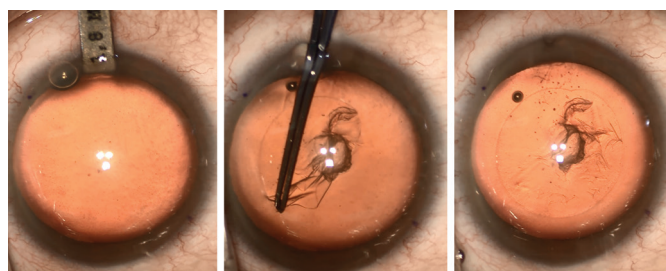


Figure 3 Standard straight-shank capsulorrhexis forceps used for single instrument 1.8-mm capsulorrhexis procedure.

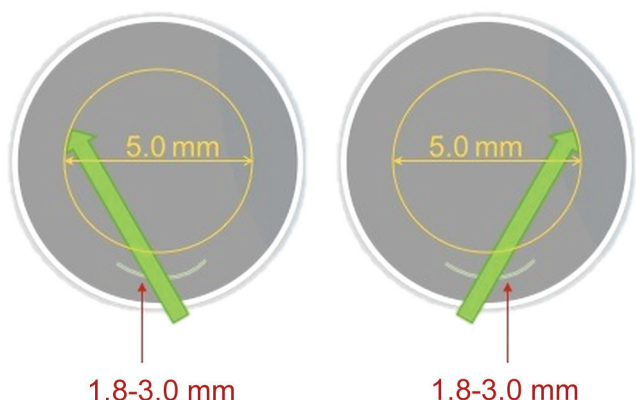

Figure 4 Surgical instruments used for phacoemulsification are centered on a fixed pivot point within the CCI to allow for a wide range of movement.

capsular opening (5.0-5.5 mm) when the corneal incision wound becomes smaller.

The recent developments in cataract surgery have focused on

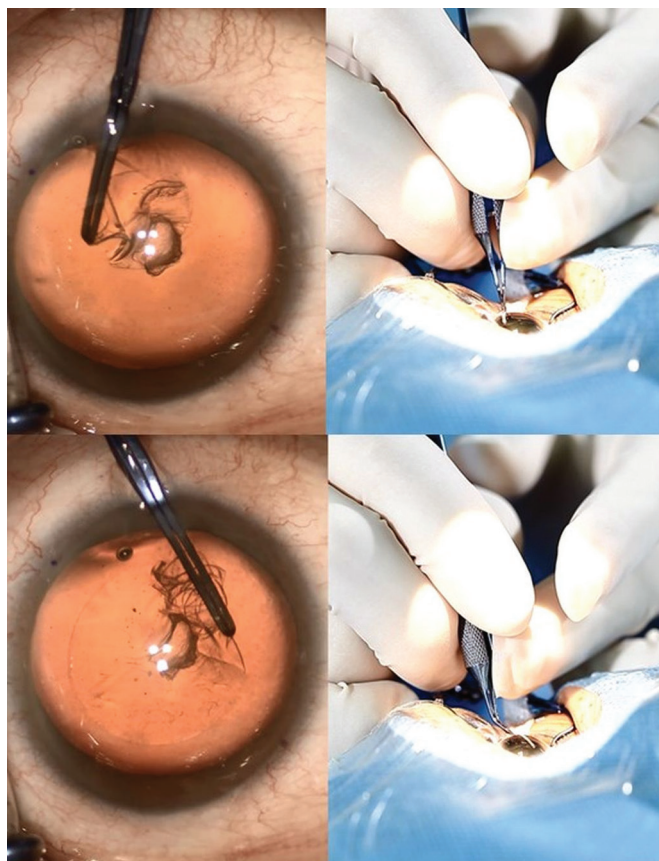


Figure 5 Hand of the operator holding the instrument must move toward the left such that the tip of the instrument shifts toward the right and vice versa.

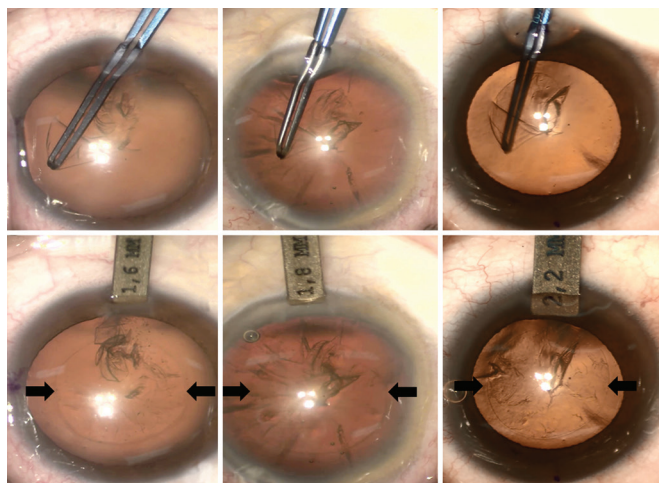


Figure 6 The curvature angle must be larger to achieve a similar capsular opening (5.0-5.5 mm) when the corneal incision wound becomes smaller (2.2, 1.8, 1.6 mm).

reducing the incision size^[3]. Many studies have determined that larger incisions cause increase surgically induced astigmatism (SIA). The SIA was approximately 0.50 D in the 3.0 mm and almost zero to 0.25 D in incisions of 2.2 mm or less^[4]. When considering the future of customized surgery, which could accommodate and allow adjustments for personal corneal aberrations, incisions less than 2.0 mm in size will be essential, and could enable the performance of surgery without degrading corneal optical quality^[5].

Phacoemulsification with CCI ranging between 1.8-2.8 mm was performed on our patients using different phacoemulsification devices. In our practice, we did not need to prepare a different type of capsulorhexis forceps for the distinct size of the CCI, which enabled the entire surgical procedure to proceed smoothly, and saved time during the pre-surgical preparation of instruments. Further, achieving proficiency does not require any change to our technique, and the use of standard capsulorhexis forceps to create a good quality CCC through a clear corneal wound less than 2.0 mm in size can be continued. In fact, pivot concept has demonstrated excellent intraocular instrument maneuverability using not only standard capsulorhexis forceps, but also the phacoemulsification probe, and the irrigation/aspiration tips. Because the elasticity of the corneal is limited, irreversible expansion of the incision and potential tissue lacerations may occur with a smaller incision. When a surgeon uses instruments forcefully to push on any edge of the incision, the actions can cause extensive corneal deformation, coupled with striae, which impairs the surgical view, and causes mechanical corneal trauma^[6]. Further, the ultrasonic energy from the phacoemulsification probe can produce a significant amount of heat, which can burn the cornea within seconds, and induce corneal thermal burn injuries^[7]. Clinical implications of wound trauma include difficulty in wound sealing, Descemet's membrane tears, or endothelial damage that causes corneal edema, or prolonged healing.

Even though similar ideas or principal has been proposed in the past, however, no publications of similar relevance can be found in current nor past literatures. Therefore, our hope is to share such findings with fellow residents in guiding them with future surgical techniques.

To conclude, our experience showed that a very simple alternative approach decreases the incidence of capsule complications reliably even in challenging cases. Adapting the pivot concept in all cataract surgeries enables the surgeon to make the successful performance of a much safer surgical procedure in patients.

ACKNOWLEDGEMENTS

Presented in part at the XXXII Congress of the European Society of Cataract & Refractive Surgeons, London, UK, September 2014.

The authors wish to thank Dr. Abhay Vasavada for many helpful comments of the manuscript.

Conflicts of Interest: Lin HY, None; Chuang YJ, None; Tang X, None; Lin CC, None; Chen HY, None; Lin PJ, None.

REFERENCES

- 1 2014 APACRS survey results and trends.
- 2 Devgan U. Surgeons should master pivoting, maneuvering within the eye. *Ocular Surgery News* 2012.
- 3 Klamann MK, Gonnermann J, Maier AK, Torun N, Bertelmann E. Smaller incision size leads to higher predictability in microcoaxial cataract surgery. *Eur J Ophthalmol* 2013;23(2):202-207.
- 4 Dewey S, Beiko G, Braga-Mele R, Nixon DR, Raviv T, Rosenthal K. ASCRS Cataract Clinical Committee, Instrumentation and IOLs Subcommittee. Microincisions in cataract surgery. *J Cataract Refract Surg* 2014;40(9):1549-1557.
- 5 Denoyer A, Ricaud X, Van Went C, Labbé A, Baudouin C. Influence of corneal biomechanical properties on surgically induced astigmatism in cataract surgery. *J Cataract Refract Surg* 2013;39(8):1204-1210.
- 6 Weikert MP, Wang L, Barrish J, Dimalanta R, Koch DD. Quantitative measurement of wound architecture in microincision cataract surgery. *J Cataract Refract Surg* 2012;38(8):1460-1466.
- 7 Sippel KC, Pineda R Jr. Phacoemulsification and thermal wound injury. *Semin Ophthalmol* 2002;17(3-4):102-109.