

Comparative analysis of cytomegalovirus retinitis and microvascular retinopathy in patients with acquired immunodeficiency syndrome

Chao Chen^{1,2}, Chun-Gang Guo¹, Li Meng³, Jing Yu¹, Lian-Yong Xie¹, Hong-Wei Dong¹, Wen-Bin Wei²

¹Beijing You An Hospital, Capital Medical University, Beijing 100069, China

²Beijing Tongren Eye Center, Beijing Key Laboratory of Intraocular Tumor Diagnosis and Treatment, Beijing Ophthalmology and Visual Sciences Key Lab, Beijing Tongren Hospital, Capital Medical University, Beijing 100730, China

³Xi'an Aier Ancient City Eye Hospital, Xi'an 710021, Shaanxi Province, China

Correspondence to: Wen-Bin Wei. Beijing Tongren Eye Center, Beijing Key Laboratory of Intraocular Tumor Diagnosis and Treatment, Beijing Ophthalmology and Visual Sciences Key Lab, Beijing Tongren Hospital, Capital Medical University, Beijing 100730, China. weiwenbintr@163.com

Received: 2017-04-05 Accepted: 2017-07-31

Abstract

• **AIM:** To compare the clinical manifestation of cytomegalovirus (CMV) retinitis and microvascular retinopathy (MVR) in patients with acquired immunodeficiency syndrome (AIDS) in China.

• **METHODS:** A total of 93 consecutive patients with AIDS, including 41 cases of CMV retinitis and 52 cases of MVR were retrospectively reviewed. Highly active antiretroviral therapy (HAART) status was recorded. HIV and CMV immunoassay were also tested. CD4+ T-lymphocyte count and blood CMV-DNA test were performed in all patients. Aqueous humor CMV-DNA test was completed in 39 patients. Ophthalmological examinations including best corrected visual acuity (BCVA, by International Standard Vision Chart), intraocular pressure (IOP), slit-lamp biomicroscopy, indirect ophthalmoscopy were performed.

• **RESULTS:** In MVR group, the anterior segment examination was normal in all patients with a mean BCVA of 0.93±0.13. Blood CMV-DNA was 0 (0, 269 000) and 42 patients (80.77%) did not receive HAART. In CMV retinitis group, 13 patients (31.71%) had anterior segment abnormality. The mean BCVA was 0.64±0.35 and blood CMV-DNA was 3470 (0, 1 450 000). Nineteen patients (46.34%) had not received HAART. MVR group and CMV retinitis group the positive rates of aqueous CMV-DNA were 0 and 50%, respectively.

Two patients with MVR progressed to CMV retinitis during the follow-up period.

• **CONCLUSION:** In comparison of CMV, patients with MVR have relatively mild visual function impairment. Careful ophthalmological examination and close follow-up are mandatory, especially for patients who have systemic complications, positive CMV-DNA test and without received HAART.

• **KEYWORDS:** acquired immunodeficiency syndrome; cytomegalovirus retinitis; microvascular retinopathy; CD4+ T-lymphocyte; CMV-DNA; highly active antiretroviral therapy

DOI:10.18240/ijo.2017.09.11

Citation: Chen C, Guo CG, Meng L, Yu J, Xie LY, Dong HW, Wei WB. Comparative analysis of cytomegalovirus retinitis and microvascular retinopathy in patients with acquired immunodeficiency syndrome. *Int J Ophthalmol* 2017;10(9):1396-1401

INTRODUCTION

Acquired immunodeficiency syndrome (AIDS) is caused by the human immunodeficiency virus (HIV) which affects all body organs either directly or by opportunistic infections, and the eye is not spared. AIDS is a multisystemic disease, but eye diseases occur in up to 70% of the cases during the natural history of infection. The spectrum of HIV-associated ophthalmic manifestations is very broad and extends from a simple blepharitis to retinal abnormalities. Multiple retinal abnormalities could be found in patients with AIDS. The most common diseases include cytomegalovirus retinitis and microvascular retinopathy (MVR)^[1]. Clinical manifestation of cytomegalovirus (CMV) retinitis is a potentially blinding opportunistic infection that used to occur in up to one-third of HIV-infected patients before the availability of Highly active antiretroviral therapy (HAART). CMV retinitis is characterized by typical white, crumbly areas of retinal necrosis and hemorrhage^[2]. Cotton-wool spot is an early manifestation of CMV retinitis. Previous studies have found that CMV-DNA is detected by polymerase chain reaction (PCR) at the position of the cotton-wool spot^[3]. CMV retinitis can cause irreversible vision loss and CMV retinitis is most common reason for blindness in patients with AIDS^[1]. HIV can also

Table 1 Ocular and physical examinations

Parameters	MVR group (n=52)	CMV group (n=41)	t	P
BCVA	0.93±0.13	0.64±0.35	-4.399	0.000
IOP	11.61±2.74	11.75±3.08	-0.231	0.818
Slit-lamp examination abnormality (%)	0 (0)	13 (31.71)	19.167	0.000
Both eye (%) / single eye (%)	23 (44.23) / 29 (55.77)	22 (53.66) / 19 (46.34)	1.108	0.575
CD4+ T-lymphocyte count	29.5 (0, 506)	21 (1, 400)	-1.235	0.217
Blood HIV virus load	84298.5 (0, 2216738)	94000 (0, 1879492)	-0.942	0.346
Blood CMV-DNA	0 (0, 269000)	3470 (0, 1450000)	-3.377	0.001

BCVA: Best corrected visual acuity; IOP: Intraocular pressure.

cause MVR assuming cotton-wool spots and small intraretinal hemorrhage which leads to mild to moderate visual function impairment^[4]. At some point the MVR may progress to CMV retinitis. The fundamentals of CMV retinitis management are early diagnosis and specific anti-CMV treatment. Up to now, there are rare studies reported about difference and relationship between CMV retinitis and MVR in AIDS patients.

In this study, we investigated 93 AIDS patients including 41 cases of CMV retinitis and 52 cases of MVR to analyze the clinical manifestation of CMV retinitis and MVR. To the best of our knowledge, this is the comprehensive study to compare CMV retinitis and MVR in AIDS patients in China.

SUBJECTS AND METHODS

Subjects This study was approved by the Beijing You An Hospital, Capital Medical University Institutional Review Board and adhered to the tenets of the Declaration of Helsinki. Records of 93 consecutive patients with AIDS, including 86 males and 7 females, aging from 21 to 65y were retrospectively reviewed. All patients had typical retinal abnormality secondary to AIDS and visited the Ophthalmology Department of Beijing You An Hospital, Capital Medical University between January 2013 and April 2015. Among of them, 41 cases were diagnosed as CMV retinitis and 52 cases were diagnosed as MVR.

Examinations 1) Ophthalmological examinations include best-corrected Snellen visual acuity (BCVA) testing, intraocular pressure (IOP) measurement (Alcon®), slit-lamp examination, indirect ophthalmoscopy, and Kowa VX-10 Fundus Camera (Kowa Company, Ltd., Japan); 2) General examinations: HIV and blood CMV-DNA diagnostic bioassay test were performed in all patients. CMV-DNA test of the aqueous humor was recorded in 39 patients whose physical condition could tolerate the examination. Among of them, the prevalence of MVR and CMV retinitis was 48.7% (19 eyes) and 51.3% (20 eyes) respectively. HAART status of all patients were recorded.

Diagnosis Criteria 1) According to the standard ACTGA criteria^[5], diagnosis of CMV retinitis was made by an experienced ophthalmologist based on the ocular manifestation. The progress of CMV retinitis was recorded by fundus

photography. Exclusion criteria included other necrotizing retinitis induced by varicella zoster virus, herpes simplex virus, syphilis, toxoplasmosis, or lymphoma^[6]. The uncertain cases should also be ruled out; 2) MVR was diagnosed according to the typical retinal abnormality such as cotton-wool spots, intraretinal hemorrhage, microaneurysms, and ischemic maculopathy^[6].

Data Analysis Clinical data of patients were analyzed using SPSS software for Windows (ver. 11.5, SPSS, Inc., Chicago, IL, USA). Normal distributed quantitative data was analyzed by *t*-test or ANOVA test. Qualitative data was analyzed by χ^2 test or Fish's exact probability method. For non-normal distributed data, median of minimum and maximum value were recorded and analyzed by rank test. Significance was defined as $P < 0.05$.

RESULTS

General Information There were 41 patients including 37 males and 4 females in CMV retinitis group. The mean patient age was 37.63±9.22y (range: 22 to 56y). There were 52 patients including 49 males and 3 females in MVR group. The mean subject age was 39.69±10.51y (range: 21 to 65y). There was no significant difference in the mean age between CMV retinitis and MVR groups. Patients were followed range: 6 to 28mo. During the follow-up, two patients in MVR group developed status of CMV retinitis.

Ocular and Physical Examinations The difference in BCVA, slit-lamp examination and blood CMV-DNA level between CMV retinitis and MVR groups was statistically significant (Table 1). The mean BCVA in MVR group was much better than that in CMV retinitis group (0.93±0.13 versus 0.64±0.35, $t = -4.399$, $P = 0.000$). The slit-lamp examination was normal anterior segment appearance in all patients in MVR group. In contrast, 13 patients (31.71%) in CMV retinitis group had abnormal anterior segment appearance ($t = 19.167$, $P = 0.000$), including: ciliary hyperemia, fine keratic precipitates, aqueous flare and cells. Blood CMV-DNA level was 0 (0, 269 000) in MVR group compared with 3470 (0, 1 450 000) in CMV retinitis group ($t = -3.377$, $P = 0.001$). The difference in IOP, CD4+ T-lymphocyte counts and blood HIV virus load was not statistically significant between both groups ($P > 0.05$).

Table 2 Blood and aqueous humor CMV-DNA analysis of 39 patients

Parameters	MVR group (n=19)	CMV group (n=20)	t	P
Blood CMV-DNA	0 (0, 269000)	5215 (0, 836000)	-2.358	0.028
Aqueous humor CMV-DNA	0 (0, 0)	54.5 (0, 1650000)	-3.478	0.007

Table 3 HAART treatment status in MVR and CMV groups

Parameters	MVR group (n=52)	CMV group (n= 41)	t	P
HAART therapy (N)	42 (80.77%)	19 (46.34%)	12.323	0.000
HAART therapy (Y)	10 (19.23%)	22 (53.66%)		

Aqueous Humor CMV-DNA Analysis In this study, 39 patients with systemic conditions could tolerate aqueous humor CMV-DNA detection, including 19 people in MVR group, 20 people in CMV group. CMV-DNA bioassay test was negative in all patients in MVR group, while 10 patients (50%) in CMV retinitis group had positive CMV-DNA test result (Table 2). The median value of CMV-DNA in the blood of MVR group was 0, the minimum value was 0, the maximum detection value was 269 000, and the aqueous humor CMV-DNA test was all 0. In the CMV group, the median CMV-DNA detection value was 5215, the minimum value was 0, and the maximum detection value was 836 000. The median of the measured values of CMV-DNA in the aqueous humor was 54.5, the minimum was 0, and the maximum detected value was 1 650 000. The difference in positive rate of blood and aqueous humor CMV-DNA test between the two groups was statistically significant ($t=-2.358$, $P=0.028$; $t=-3.478$, $P=0.007$). There were 3 patients in CMV retinitis group who had negative blood CMV-DNA test results, while had positive aqueous humor CMV-DNA test result.

HAART Status and Analysis There were 10 patients (19.23%) in MVR group and 22 patients (53.66%) in CMV retinitis group have received HAART in the first visit (Table 3). Patients without received HAART were 42 (80.77%) in MVR group and 19 (46.34%) in CMV retinitis group. The ratio of with HAART to without HAART in MVR and CMV retinitis group were 0.238 versus 1.158 respectively. The difference between both groups was statistically significant ($t=12.323$, $P=0.000$).

Two Patients with MVR Developed CMV During the Follow-up Two patients in MVR group were diagnosed as CMV retinitis during the follow-up (Figures 1-5). Their blood CD4+ T-lymphocytes were 20/μL and 1/μL respectively. The common feature of these two patients was combining bacterial pneumonia and lung tuberculosis. Both patients had positive blood CMV-DNA test that was 25 500 and 1 450 000 respectively. They had never received HAART before the first visit. These two patients had poor compliance and did not follow-up closely.

DISCUSSION

CMV retinitis is the most common eye disease leading to

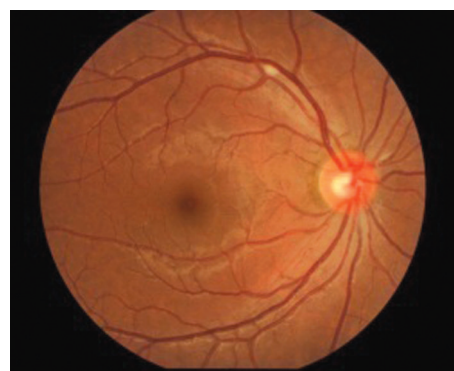

Figure 1 Initial fundus photograph from the patient who was diagnosed as MVR at the first visit and developed CMV retinitis during the follow-up. Cotton-wool spot was shown in the superotemporal retina of the right eye.

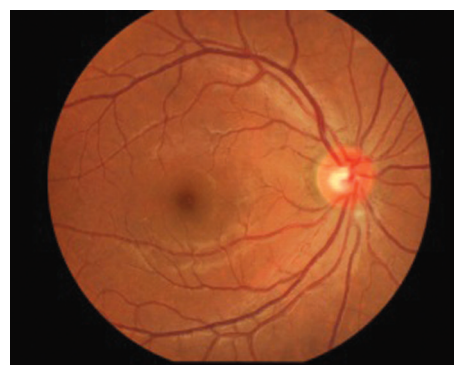

Figure 2 Fundus photograph of the same eye 3mo later demonstrated the cotton-wool spot showing in Figure 1 disappeared with a new cotton-wool spot appearing under the optic disc.



Figure 3 Fundus photograph of the same eye after 9mo displayed the typical CMV retinitis changes with extensive retinal necrosis and hemorrhage.

blindness in AIDS population. Early diagnosis for CMV retinitis could effectively control disease progress, prevent other serious complications and retain the patient’s visual function.

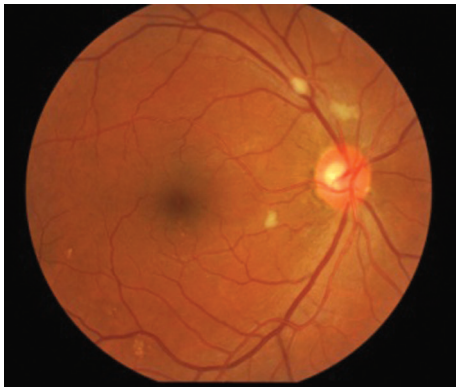


Figure 4 Fundus photograph at 3mo visit from the other patient who was diagnosed as MVR initially and developed CMV retinitis during the follow-up. There were three cotton-wool spots locating around the optic disc of the right eye.

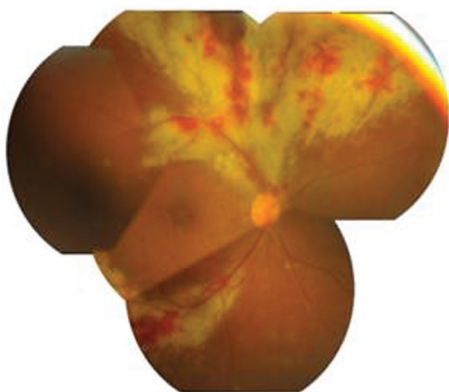


Figure 5 Fundus photograph of the same eye after 6mo follow-up visit showed superior and inferotemporal retinal necrosis and hemorrhage indicating typical CMV retinitis changes, whereas the initial cotton-wool spot disappeared.

Previous studies showed that low CD4+ T-lymphocyte level and HAART status was two major risk factors for the onset of CMV retinitis and MVR in AIDS patients^[6]. Another study indicated CD4+ T-lymphocyte count $<50/\mu\text{L}$, without HAART, and less strict BCVA monitoring was associated with CMV retinitis^[2]. In our study, there was no significant differences in CD4+ T-lymphocyte count between MVR and CMV retinitis, while patients without HAART had a higher prevalence of MVR. In the study of Abu *et al*^[7], the same is no significant association was found between ocular disorders and current CD4 counts. In accordance with previous studies, the mean BCVA of patients in CMV retinitis group was lower than that of patients in MVR group^[2].

Blood CMV-DNA bioassay method was regarded to have lower sensitivity comparing with other laboratory testing methods, therefore it was usually limited to CMV retinitis diagnosis in clinical practice^[8]. One previous study reported blood CMV-DNA tests using PCR method could efficiently support the diagnosis of mixed infection in HIV and CMV^[4]. Our study revealed that CMV-DNA level in blood and aqueous humor samples in CMV retinitis group was significantly higher than that in MVR group. This result indicated that patients with

high blood CMV-DNA virus load should be highly suspect of CMV retinitis. It's reported that CMV-DNA can also be found in aqueous humor and vitreous samples^[9]. And another study found that CMV-DNA from both vitreous and aqueous specimens can provide highly sensitive and specific markers to differentiate active and inactive CMV retinitis^[10].

In our study, the positive rate of aqueous humor CMV-DNA between CMV group and MVR group were 50% and 0 respectively. Aqueous humor CMV-DNA test could be helpful to differentiate between CMV retinitis and MVR in AIDS patients. Totally 50%-70% of AIDS patients had MVR which manifested cotton-wool spots and retinal bleeding^[11]. Pathological changes of MVR are pericyte loss and endothelial cell swelling^[12]. Cotton-wool spots are the most common sign which can be found in 25%-50% AIDS patients and in 75% of autopsy samples^[13]. Active CMV retinitis is characterized by progressive white areas of retinal necrosis and edema, with small white satellite lesions at the leading edge of the active retinitis^[14]. Lesions have often been classified into an indolent/granular form or a fulminant/edematous form, although the severity of opacity may be a more useful clinical description of disease^[15-16]. In practice, it is usually difficult to identify the tiny retinopathy which is an early manifestation of CMV retinitis or MVR in AIDS patients. In one of previous study reported that CMV retinitis often happened in AIDS patients who had MVR or already had MVR^[17-18]. PCR test of autopsy retina also showed CMV-DNA could be found in cotton-wool spot^[17,19]. The above-mentioned proofs supported the hypothesis of correlation between CMV infection and retinal blood vessel damage^[20-21]. In the Johns Hopkins CMV Retinitis Cohort Study, the presence of HIV microangiopathy, as evidenced by cotton-wool spots, increased the odds of CMV retinitis 1.46-fold ($P<0.05$)^[22]. MVR usually lasts for 6 to 12wk without impacting patient's visual function and generally do not need treatment, but should be regularly reviewed, and found that the possible occurrence of CMV retinitis. Treatments for CMV retinitis include intravenous ganciclovir, the oral pro-drug valganciclovir, intravenous foscarnet, intravenous cidofovir, intravitreal injections of ganciclovir or foscarnet, and the ganciclovir implant^[23]. With the effective anti-CMV treatment, CMV retinitis lesions began to dissipate, clinically manifested as bleeding, exudation disappeared, retinal vein sheath disappeared, and ultimately the formation of inactive scars. If retinal detachment occurs, surgical treatment is usually required.

In our study, there were two MVR patients progressed to CMV retinitis during the follow-up. In the fundus lesion, four in five cotton spots have progressed into CMV retinitis. The common features of these two patients were combining systemic complications, poor compliance, positive blood CMV-DNA test and HAART-naive status. Considering their poor physical

condition, aqueous humor CMV-DNA was not performed. In future study, blood and aqueous humor CMV-DNA will be tested at different stage to further observe the relationship between MVR and CMV retinitis.

The main shortcoming of our study was limitation of retrospective research and that only a few patients underwent aqueous humor CMV-DNA test. In addition, the mean follow-up was only 13mo. Previous reports have indicated that retinal lesions progressed over time and with longer AIDS history^[24-25]. In conclusion, the present study suggested the incidence of MVR was higher in AIDS patients without HAART. CMV-DNA level of blood and aqueous humor in MVR group were significantly lower than that in CMV retinitis group. Comparing with MVR, CMV retinitis presented a significant vision-threatening problem. Aqueous humor CMV-DNA test is helpful to differentiate between CMV retinitis and MVR. For MVR patients with systemic complications, positive blood CMV-DNA test, and HAART-naive status, careful initial ophthalmological examination and long-term follow-up are mandatory.

ACKNOWLEDGEMENTS

Foundations: Supported by National Natural Science Foundation of China (No.81570891;81272981); Beijing Natural Science Foundation (No.7151003); Capital Medical University Fundamental Clinical Research Cooperation Fund (No.16JL73); Beijing Municipal Administration of Hospitals' Ascent Plan (No.DFL20150201).

Conflicts of Interest: Chen C, None; Guo CG, None; Meng L, None; Yu J, None; Xie LY, None; Dong HW, None; Wei WB, None.

REFERENCES

- 1 Stewart MW. Optimal management of cytomegalovirus retinitis in patients with AIDS. *Clin Ophthalmol* 2010;4:285-299.
- 2 Sun HY, Peng XY, Li D, Mao FF, You QS, Jonas JB. Cytomegalovirus retinitis in patients with AIDS before and after introduction of HAART in China. *Eur J Ophthalmol* 2014;24(2):209-215.
- 3 González CR, Wiley CA, Arevalo JF, Garcíá RF, Kuppermann BD, Berry C, Freeman WR. Polymerase chain reaction detection of cytomegalovirus and human immunodeficiency virus-1 in the retina of patients with acquired immune deficiency syndrome with and without cotton-wool spots. *Retina* 1996;16(4):305-311.
- 4 Tsen CL, Chen SC, Chen YS, Sheu SJ. Uveitis as an initial manifestation of acquired immunodeficiency syndrome. *Int J STD AIDS* 2017: 956462417694569.
- 5 Mizushima D, Nishijima T, Yashiro S, Teruya K, Kikuchi Y, Katai N, Oka S, Gatanaga H. Diagnostic utility of quantitative plasma cytomegalovirus DNA PCR for cytomegalovirus end-organ diseases in patients with HIV-1 infection. *J Acquir Immune Defic Syndr* 2015;68(2): 140-146.
- 6 Becker KN, Becker NM. Ocular manifestations seen in HIV. *Dis Mon* 2014;60(6):268-275.

- 7 Abu EK, Abokyi S, Obiri-Yeboah D, Ephraim RK, Afedo D, Agyeman LD, Boadi-Kusi SB. Retinal microvasculopathy is common in HIV/AIDS patients: a cross-sectional study at the Cape Coast Teaching Hospital, Ghana. *J Ophthalmol* 2016;2016:8614095.
- 8 Jabs DA, Martin BK, Forman MS, Ricks MO; Cytomegalovirus Retinitis and Viral Resistance Research Group. Cytomegalovirus (CMV) blood DNA load, CMV retinitis progression, and occurrence of resistant CMV in patients with CMV retinitis. *J Infect Dis* 2005;192(4):640-649.
- 9 Carmichael A. Cytomegalovirus and the eye. *Eye (Lond)* 2012;26(2): 237-240.
- 10 Sittivarakul W, Seepongphun U. Incidence rates and risk factors for vision loss among AIDS-related cytomegalovirus retinitis patients in southern Thailand. *Ocul Immunol Inflamm* 2017:1-8.
- 11 Luo J, Jing D, Kozak I, Huiming Z, Siying C, Yezhen Y, Xin Q, Luosheng T, Adelman RA, Forster SH. Prevalence of ocular manifestations of HIV/AIDS in the highly active antiretroviral therapy (HAART) era: a different spectrum in central south China. *Ophthalmic Epidemiol* 2013;20(3):170-175.
- 12 Glasgow BJ. Evidence for breaches of the retinal vasculature in acquired immune deficiency syndrome angiopathy. A fluorescent microsphere study. *Ophthalmology* 1997;104(5):753-760.
- 13 Mansour AM, Rodenko G, Dutt R. Half-life of cotton-wool spots in the acquired immunodeficiency syndrome. *Int J STD AIDS* 1990;1(2): 132-133.
- 14 Heiden D, Ford N, Wilson D, Rodriguez WR, Margolis T, Janssens B, Bedelu M, Tun N, Goemaere E, Saranchuk P, Sabapathy K, Smithuis F, Luyirika E, Drew WL. Cytomegalovirus retinitis: the neglected disease of the AIDS pandemic. *PLoS Med* 2007;4(12):e334.
- 15 Holland GN, Vaudaux JD, Jeng SM, Yu F, Goldenberg DT, Folz IC, Cumberland WG, McCannel CA, Helm CJ, Hardy WD; UCLA CMV Retinitis Study Group. Characteristics of untreated AIDS-related cytomegalovirus retinitis. I. Findings before the era of highly active antiretroviral therapy (1988 to 1994). *Am J Ophthalmol* 2008;145(1):5-11.
- 16 Holland GN, Shuler JD. Progression rates of cytomegalovirus retinopathy in ganciclovir-treated and untreated patients. *Arch Ophthalmol* 1992;110(10):1435-1442.
- 17 Mao F, Wu J, Sun H, You Q, Li D. Frosted branch angiitis in an AIDS patient with cytomegalovirus retinitis. *Int J Infect Dis* 2016;52:9-11.
- 18 Freeman WR, Chen A, Henderly DE, Levine AM, Luttrull JK, Urrea PT, Arthur J, Rasheed S, Cohen JL, Neuberger D. Prevalence and significance of acquired immunodeficiency syndrome-related retinal microvasculopathy. *Am J Ophthalmol* 1989;107(3):229-235.
- 19 Yoganathan KT, Morgan AR, Yoganathan KG. Perforation of the bowel due to cytomegalovirus infection in a man with AIDS: surgery is not always necessary! *BMJ Case Rep* 2016;2016.pii:bcr2015214196.
- 20 Liu Y, Chen AS, Kamphaengkham S, Leenasirimakul P, Jirawison C, Ausayakhun S, Margolis TP, Keenan JD. Diagnostic utility of ocular symptoms and vision for cytomegalovirus retinitis. *PLoS One* 2016;11(10):e0165564.
- 21 Larochelle MB, Phan R, Craddock J, Abzug MJ, Curtis D, Robinson CC, Giller RH, Cosgrove S, Siringo F, McCourt E, Palestine AG.

- Cytomegalovirus retinitis in pediatric stem cell transplants: report of a recent cluster and the development of a screening protocol. *Am J Ophthalmol* 2017;175:8-15.
- 22 Jabs DA. Cytomegalovirus retinitis and the acquired immunodeficiency syndrome--bench to bedside: LXVII Edward Jackson Memorial Lecture. *Am J Ophthalmol* 2011;151(2):198-216.e1.
- 23 Jabs DA, Ahuja A, Van Natta M, Dunn JP, Yeh S; Studies of the Ocular Complications of AIDS Research Group. Comparison of treatment regimens for cytomegalovirus retinitis in patients with AIDS in the era of highly active antiretroviral therapy. *Ophthalmology* 2013;120(6):1262-1270.
- 24 Grønberg HL, Jespersen S, Hønge BL, Jensen-Fangel S, Wejse C. Review of cytomegalovirus coinfection in HIV-infected individuals in Africa. *Rev Med Virol* 2017;27(1):e1907.
- 25 Iyer JV, Agrawal R, Yeo TK, Gunasekeran DV, Balne PK, Lee B, Au VB, Connolly J, Teoh SC. Dataset of aqueous humor cytokine profile in HIV patients with Cytomegalovirus (CMV) retinitis. *Data Brief* 2016;8:1232-1242.