

Etiology and failure analysis of anterior lamellar keratoplasty

Zhen Wang^{1,2}, Xiao-Jun Tan², Hua-Lei Zhai³, Jun Cheng³, Yan Gao³, Li-Xin Xie³

¹Qingdao University Medical College, Qingdao 266071, Shandong Province, China

²Affiliated Yidu Central Hospital of Weifang Medical College, Weifang 262500, Shandong Province, China

³Qingdao Eye Hospital, Shandong Eye Institute, Shandong Academy of Medical Sciences, Qingdao 266071, Shandong Province, China

Correspondence to: Li-Xin Xie. Shandong Eye Institute, 5 Yanerdao Road, Qingdao 266071, Shandong Province, China. lixin_xie@hotmail.com

Received: 2017-06-30 Accepted: 2018-03-01

Abstract

• **AIM:** To analyze indications and reasons for failure of anterior lamellar keratoplasty (ALK).

• **METHODS:** The clinical records were retrospectively reviewed. Main outcome measures included indications for ALK and reasons for failure of ALK.

• **RESULTS:** A total of 434 patients (462 eyes) were treated with ALK at Qingdao Eye Hospital, Shandong Eye Institute from June 1, 2009 to May 31, 2016. The main indications were infectious keratitis (33.3%), keratoconus (23.6%), corneal dystrophy and degeneration (9.8%), Mooren's ulcer (8.4%), corneal neoplasm (7.8%), viral keratitis (6.5%) and re-grafting (3.7%). Fungal keratitis accounted for 73.4% in the infectious keratitis cases. ALKs were failed in 36 patients, with the major causes being recurrence of primary diseases (63.9%). The leading causes of graft failure was Mooren's ulcer (36.1%), followed by infectious keratitis (30.6%). Recurrence of fungal keratitis accounted for 81.8% in the failed cases after ALK for infectious keratitis cases.

• **CONCLUSION:** Infectious keratitis and keratoconus are the main indications for ALK, of which fungal keratitis was the major cause of corneal infections. Recurrence of primary disease is the main reason of graft failure after ALK, in which the main primary diseases associated with graft failure are Mooren's ulcer and fungal keratitis.

• **KEYWORDS:** anterior lamellar keratoplasty; indication; failure; infectious keratitis; Mooren's ulcer

DOI: 10.18240/ijo.2018.05.11

Citation: Wang Z, Tan XJ, Zhai HL, Cheng J, Gao Y, Xie LX. Etiology and failure analysis of anterior lamellar keratoplasty. *Int J Ophthalmol* 2018;11(5):786-790

INTRODUCTION

Over the past decade through, anterior lamellar keratoplasty (ALK) has become an alternative surgical procedure to penetrating keratoplasty (PKP) in the treatment of a variety of corneal diseases which does not involve the Descemet's membrane and endothelium^[1-3]. Otherwise, the shortage of donor grafts is a major limitation for the development of corneal transplantation in China, and this situation will worsen with an aging population and the increased use of cornea laser surgery^[4]. Fresh donors were not required for ALK, which is an advantage of ALK compared with PKP. The aim of this study is to analyze the indications and the reasons of graft failure after ALK from June 1, 2009 to May 31, 2016 in Qingdao Eye Hospital, Shandong Eye Institute, and provide reference for future ALK operation.

SUBJECTS AND METHODS

Medical records of 434 patients (462 eyes) underwent ALK at the Qingdao Eye Hospital, Shandong Eye Institute, China from June 1, 2009 to May 31, 2016 were retrospectively reviewed. This study was approved by the Ethics Committee of Shandong Eye Institute and conformed to Declaration of Helsinki guidelines.

Data of gender, age, preoperative diagnosis, rate of surgery success, and causes of graft failure were retrieved. The indications for ALK were divided into 8 categories: infectious keratitis, keratoconus, corneal dystrophy and degeneration, Mooren's ulcer, corneal neoplasm, viral keratitis, primary graft failure and others (such as ocular trauma, burn, keratoglobus, corneal ectasia after laser assisted *in situ* keratomilensis). Additionally, infectious keratitis was further classified into fungal, bacterial and Acanthamoeba keratitis according to the different pathogens. For cases with graft failure after ALK, reasons of graft failure and the primary diagnosis before ALK were reviewed.

In order to study the changes of ALK surgical indications with time and indications during this period, this study divided the case data into two groups, according to time, each group includes 3.5y of case data (June 1, 2009 to November 30, 2012 and December 1, 2012 to May 31, 2016).

RESULTS

Demographics, Culture Results, and Clinical Features

During the seven-year period, a total of 462 ALK performed for 434 patients were included in this study. The ages ranged from 5.5mo to 85y, with a mean age of 39.1±19.7y. There were 165 females (38.1%) and 269 males (61.9%). The majority of patients were in the age range of 41-60y (38.3%), 21-40y (26.2%), and 0-20y (22.3%).

Table 1 Annual indications distribution for ALK

Indications	n (%)							Total
	June 2009- May 2010	June 2010- May 2011	June 2011- May 2012	June 2012- May 2013	June 2013- May 2014	June 2014- May 2015	June 2015- May 2016	
Infectious keratitis	41 (46.6)	26 (43.3)	21 (42.9)	13 (34.3)	18 (17.3)	12 (21.4)	23 (34.4)	154 (33.3)
Keratoconus	20 (22.8)	12 (20.0)	13 (26.5)	4 (10.5)	36 (34.6)	14 (25.0)	10 (14.9)	109 (23.6)
Corneal dystrophy and degeneration	9 (10.2)	3 (5.0)	4 (8.2)	7 (18.5)	6 (5.8)	9 (16.1)	7 (10.4)	45 (9.8)
Mooren's ulcer	6 (6.8)	5 (8.3)	5 (10.2)	1 (2.6)	9 (8.7)	6 (10.8)	7 (10.4)	39 (8.4)
Corneal neoplasm	5 (5.7)	5 (8.3)	2 (4.1)	4 (10.5)	9 (8.7)	5 (8.9)	6 (9.0)	36 (7.8)
Viral keratitis	3 (3.4)	2 (3.4)	2 (4.1)	1 (2.6)	10 (9.5)	5 (8.9)	7 (10.4)	30 (6.5)
Regrafting	1 (1.1)	3 (5.0)	1 (2.0)	4 (10.5)	7 (6.7)	0 (0)	1 (1.5)	17 (3.7)
Others	3 (3.4)	4 (6.7)	1 (2.0)	4 (10.5)	9 (8.7)	5 (8.9)	6 (9.0)	32 (6.9)
Total	88 (100)	60 (100)	49 (100)	38 (100)	104 (100)	56 (100)	67 (100)	462 (100)

ALK: Anterior lamellar keratoplasty.

Table 2 Infectious keratitis for ALK

Indications	n (%)							Total
	June 2009- May 2010	June 2010- May 2011	June 2011- May 2012	June 2012- May 2013	June 2013- May 2014	June 2014- May 2015	June 2015- May 2016	
Fungal keratitis	32 (78.0)	24 (92.4)	18 (85.7)	12 (92.3)	12 (66.7)	8 (66.7)	7 (30.4)	113 (73.4)
Bacterial keratitis	3 (7.3)	1 (3.8)	1 (4.8)	0 (0)	4 (22.2)	1 (8.3)	3 (13.1)	13 (8.4)
Acanthamoebic keratitis	1 (2.5)	0 (0)	0 (0)	1 (7.7)	0 (0)	2 (16.7)	5 (21.7)	9 (5.8)
Others	5 (12.2)	1 (3.8)	2 (9.5)	0 (0)	2 (11.1)	1 (8.3)	8 (34.8)	19 (12.4)
Total	41 (100)	26 (100)	21 (100)	13 (100)	18 (100)	12 (100)	23 (100)	154 (100)

ALK: Anterior lamellar keratoplasty.

Indications for Anterior Lamellar Keratoplasty In the 462 eyes, the leading indications for ALK was infectious keratitis (33.3%), followed by keratoconus (23.6%), corneal dystrophy and degeneration (9.8%), Mooren's ulcer (8.4%) and corneal neoplasm (7.8%; Table 1). The most common pathogen of infectious keratitis was fungi, which accounted for 73.4% (113/154) in infectious cases (Table 2).

A significant increase in the number of ALK was noted during the 7y in the study, from 210 ALK in the first time period to 252 ALK in the second time period. In the first group, 43.8% of ALK were performed for infectious keratitis, while the second group of infectious keratitis accounted for only 24.6% (Table 3). The percentage of ALK performed for infectious keratitis decreased each year (Figure 1), further in 2013-2014 and 2014-2015, infectious keratitis was not the most common indication for ALK (Table 1). Conversely, there was a remarkable increase in ALK procedures used to treat keratoconus, corneal dystrophy and degeneration, Mooren's ulcer, corneal neoplasm and viral keratitis (Table 3).

Reasons of Graft Failure for Anterior Lamellar Keratoplasty

In this study, ALKs were failed in 36 patients and were performed again. The causes of reoperation was recurrence of primary disease (63.9%), graft infection (16.7%), corneal graft melting (8.3%) and others (11.1%). The leading primary diseases associated with reoperation were Mooren's ulcer (36.1%) and infectious keratitis (30.6%; Figure 2), and fungal infections accounted for 81.8% in the infectious keratitis cases reoperated.

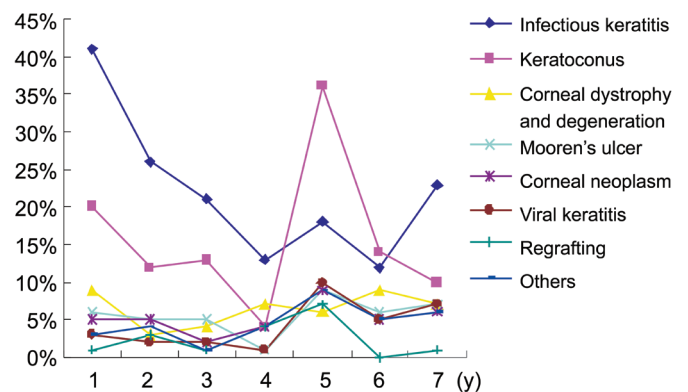


Figure 1 Indications for ALK between June 2009 and May 2016.

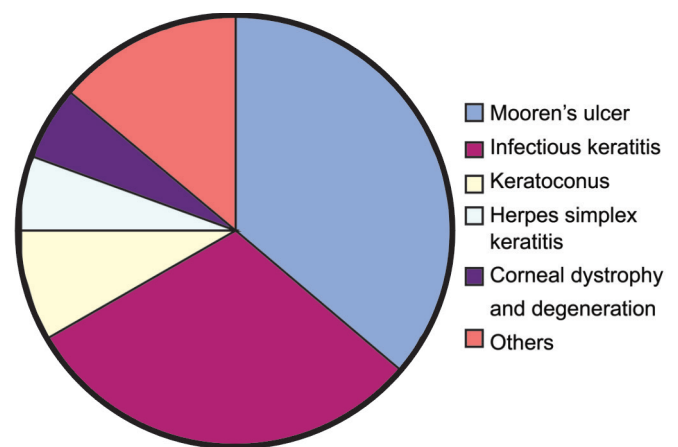


Figure 2 Primary disease of reoperation after ALK between June 2009 and May 2016 Infectious keratitis and keratoconus were the leading indications for ALK, and fungal infections were the major cause of corneal infections. Primary disease recurrence was the main reason of failure for ALK. The leading initial diagnoses associated with failure were Mooren's ulcer and fungal keratitis.

Etiology	n (%)		
	June 2009-November 2012	December 2012-May 2016	Total
Infectious keratitis	92 (43.8)	62 (24.6)	154 (33.3)
Keratoconus	47 (22.4)	62 (24.6)	109 (23.6)
Corneal dystrophy and degeneration	18 (8.6)	27 (10.7)	45 (9.8)
Mooren's ulcer	17 (8.1)	22 (8.8)	39 (8.4)
Corneal neoplasm	13 (6.2)	23 (9.1)	36 (7.8)
Viral keratitis	7 (3.3)	23 (9.1)	30 (6.5)
Regrafting	7 (3.3)	10 (4.0)	17 (3.7)
Others	9 (4.3)	23 (9.1)	32 (6.9)
Total	210 (100)	252 (100)	462 (100)

ALK: Anterior lamellar keratoplasty.

In the 36 eyes of reoperation, 17 eyes (47.2%) were performed with PKP, 13 eyes (36.1%) were performed second lamellar keratoplasty, 5 eyes (13.9%) were operated with lamellar keratoplasty and amniotic membrane transplantation and the other 1 eye (2.7%) was operated with corneal debridement and conjunctival flap cover.

DISCUSSION

As an extraocular surgery, ALK could avoid intraocular tissue damage and complications of PKP, such as eye content prolapse, secondary glaucoma, endothelial rejection. ALK retains the host endothelium, so no endothelial rejection will occur. The incidence of corneal graft rejection after ALK (1%)^[5-6] is significantly lower than that after penetrating keratoplasty (8.2%)^[11]. So ALK has become an alternative surgical procedure to PKP in the treatment of variety corneal diseases^[1-3].

The shortage of donor grafts is a major limitation for the development of corneal transplantation in China. In 2015, the first bioengineered cornea (Acornea, China Regenerative Medicine International Limited, CRMI) was approved by China Food and Drug Administration (CFDA) to be applied clinically as a substitute for human cornea in lamellar keratoplasty^[7], so sufficient donors could be supplied for ALK and a bright future of ALK development could be expected in China.

Infectious keratitis is the most common indication for ALK in this study, and the predominating pathogen of infectious keratitis is fungi. Fungal keratitis is one of the most severe infectious eye diseases leading to blindness, especially in the developing countries with temperate climates, such as China^[8] and India^[9]. It had been reported that fungal keratitis accounted for 61.9% in the infectious corneal diseases in China^[8]. With the advancement of surgical techniques, fewer surgical complications and more easily obtained donor corneas than PKP, ALK has become an important and effective method for fungal keratitis uncontrollable with medical treatment^[10].

Keratoconus, corneal dystrophy and degeneration, Mooren's ulcer and corneal neoplasm were the four most common

indications after infectious keratitis in our study. Over the past seven years, the infectious keratitis for ALK in our hospital have been declining, this trend may be attributable to improved management of corneal diseases with new drugs and diagnostic tools. Besides, because of the increasing awareness of the patients and the increasing number of patients who treated in time, the opportunity for ALK surgery has been increased. Meanwhile, keratoconus increased dramatically as an indication for ALK, further in 2013-2014 and 2014-2015, keratoconus became the most common indication for ALK, which is consistent with the reports of Western countries. In United States during the period of 2005-2014, the top four indications for ALK were corneal degeneration, ulcerative keratitis or perforation, keratoconus, and unspecified anterior stromal scarring^[11], while keratoconus, keratitis and non-Fuch's corneal dystrophies (NFCD) were the main clinical indications for ALK in the West of Scotland^[12]. Zhang *et al*^[13] reported that ALK accounted for approximately 30% of keratoplasty procedures for keratoconus in Ontario, Canada in 2012. In Western Scotland, ALK surpassed PKP as the more popular keratoplasty procedure for keratoconus after 2004^[12]. Many groups advocate the use of ALK over PKP on the basis of reports that similar postoperative visual acuity and longer graft survival based largely on the reported outcomes of single centers were found^[14-16]. Further, femtosecond laser-assisted ALK facilitates the preparation of donor and recipient tissue^[17], and achieve less interface irregularity and haze, which may result in faster and better visual rehabilitation^[18]. Since 2013, most of the ALK for keratoconus have been done using femtosecond laser-assisted DALK at Qingdao Eye Hospital. In our study, primary disease recurrence was the major cause of failure for ALK, and Mooren's ulcer and infectious keratitis were the leading initial diagnoses. Mooren's ulcer is an idiopathic peripheral ulcerative keratitis that is characterized by painful and progressive ulceration of the peripheral cornea in the absence of scleritis and systemic rheumatologic diseases, and is commonly seen in China^[19]. It is generally thought that Mooren's ulcer is an autoimmune disease that

targets the cornea, but its exact pathogenesis is not clear^[20], so despite many therapies recommended in previous reports, the recurrence of Mooren's ulcer is frequently encountered. The rate of recurrence was reported to be 25.6% in a series of 550 Chinese patients suffering Mooren's ulcer^[21], and the author thought ALK surgery is the most effective treatment of Mooren's ulcer, because ALK could remove antigenic targets of the cornea, prevent immunological reactions, reconstruct the anatomical structure, prevent it from perforating, and improve vision, besides, primary lamellar keratoplasty combined with topical cyclosporine. To achieve good results, the final cure rate was 95.6%, and the postoperative preservation rate of the eye globe was 99.7%. In our study, medication was given aggressively for patients with Mooren's ulcers before surgery, including 1% cyclosporine A or 0.1% tacrolimus eye drops, 0.1% dexamethasone, and antibacterial eye drops 4 times daily, along with tobramycin and dexamethasone ointment at night. Systemic use of corticosteroids and cyclophosphamide was implemented if the ulcer was not relieved by those first approaches. When the signs and symptoms of the disease showed no improvement despite the above interventions, surgical treatment was considered. When the ulcer invading the cornea had more than one half of the corneal thickness and occurred extensively along the limbus or toward the center, lamellar keratoplasty was performed, including crescent lamellar keratoplasty, donut-shaped lamellar keratoplasty, and lamellar keratoplasty with a large corneoscleral graft, depending on the morphology of the ulcer and the infiltration depth in the cornea. For eyes with corneal perforation, lamellar keratoplasty was also considered if the perforation was small, was located in the periphery, or was obstructed by prolapsed iris. Intraoperatively, a small perforation was repaired with Tenon's capsule before the corneal graft was placed on the recipient bed. The main treatment principle for recurrent ulcers was the same as that for the primary disease. Immunosuppressants were given for a longer period according to the severity of the disease^[22]. In this study, the recurrence rate of Mooren's ulcer after ALK was 33.3%, higher than previous report. A recent research found the use of corticosteroids and immunosuppressants guided by *in vivo* confocal microscopy may reduce the disease recurrence after corneal transplantation^[20].

Fungal keratitis is one of the most severe eye diseases worldwide that may lead to blindness, for uncontrollable or further aggravated infection, surgical interventions are suggested. In this study, fungal infections accounted for 81.8% of the infectious keratitis cases failed ALK surgery. Growth patterns of fungal pathogens may be an important factor for fungal recurrence after ALK. In cases of horizontal hyphal growth, the lesions are generally superficial at the early stage of the disease and can be excised thoroughly by ALK. However, the

perpendicular growth of fungal filaments such as *Aspergillus* species made the infection penetrate deep into the corneal layers in a short time such that the tissue could not be excised thoroughly with ALK, and the rudimentary fungi in the deep stroma may cause fungal recurrence postoperatively^[23]. DALK using the big bubble technique may be effective in the treatment of deep fungal keratitis, which can not only remove the mycetes in the deep corneal stroma, but also provide a clear interface between the recipient and the graft, achieving satisfactory visual acuities^[24]. In this study, we used manual deep lamellar keratoplasty for fungal corneal ulcers involving deep corneal stroma. The recurrence rate for these patients treated with steroids or immunosuppressants before surgery was significantly higher than not. Hypopyon, corneal infection expanding to limbus and lens infection are major risk factors for recurrence of fungal keratitis after corneal transplantation^[25]. The first two weeks after ALK is the critical period for the success or failure, and antifungal drugs should continue to be applied^[10]. Sometimes it is not easy to distinguish treatment failure from local inflammation after ALK for fungal keratitis, some ophthalmologists thought cases of treatment failure usually show the following characteristics: patients report increasing irritation and decreasing vision of the operated eyes; exudation in the anterior chamber aggravates, and hypopyon develops in some cases; the focus of infection demonstrates gray infiltration and expands rapidly in the transplanted cornea; antifungal medications are ineffective. Appropriate treatment methods were chosen according to the different sites of recurrence.

In summary, infectious keratitis and keratoconus are the main indications for ALK, of which fungal keratitis was the major cause of corneal infections. Recurrence of primary disease was the main reason of graft failure after ALK, in which the main primary diseases with graft failure are Mooren's ulcer and fungal keratitis.

ACKNOWLEDGEMENTS

Foundations: Supported by the National Natural Science Foundation of China (No.81500703); the Natural Science Foundation of Shandong Province (No.ZR2015YL027).

Conflicts of Interest: Wang Z, None; Tan XJ, None; Zhai HL, None; Cheng J, None; Gao Y, None; Xie LX, None.

REFERENCES

- 1 Chen G, Tzekov R, Li W, Jiang F, Mao S, Tong Y. Deep anterior lamellar keratoplasty versus penetrating keratoplasty: a Meta-analysis of randomized controlled trials. *Cornea* 2016;35(2):169-174.
- 2 Buzzonetti L, Ardia R, Petroni S, Petrocelli G, Valente P, Parrilla R, Iarossi G. Four years of corneal keratoplasty in Italian paediatric patients: indications and clinical outcomes. *Graefes Arch Clin Exp Ophthalmol* 2016;254(11):2239-2245.
- 3 Coster DJ, Lowe MT, Keane MC, Williams KA. A comparison of lamellar and penetrating keratoplasty outcomes: a registry study. *Ophthalmology* 2014;121(5):979-987.

Etiology and failure of ALK

- 4 de By TM. Shortage in the face of plenty: improving the allocation of corneas for transplantation. *Dev Ophthalmol* 2003;36:56-61.
- 5 Reinhart WJ, Musch DC, Jacobs DS, Lee WB, Kaufman SC, Shtein RM. Deep anterior lamellar keratoplasty as an alternative to penetrating keratoplasty a report by the american academy of ophthalmology. *Ophthalmology* 2011;118(1):209-218.
- 6 Zhang YM, Wu SQ, Yao YF. Long-term comparison of full-bed deep anterior lamellar keratoplasty and penetrating keratoplasty in treating keratoconus. *J Zhejiang Univ Sci B* 2013;14(5):438-450.
- 7 Shi WY, Xie LX. Focus on the clinical application of the first artificial bioengineered cornea in China. *Zhonghua Yan Ke Za Zhi* 2016;52(3):161-163.
- 8 Xie L, Zhong W, Shi W, Sun S. Spectrum of fungal keratitis in north China. *Ophthalmology* 2006;113(11):1943-1948.
- 9 Ghosh AK, Gupta A, Rudramurthy SM, Paul S, Hallur VK, Chakrabarti A. Fungal keratitis in North India: spectrum of agents, risk factors and treatment. *Mycopathologia* 2016;181(11-12):843-850.
- 10 Xie L, Shi W, Liu Z, Li S. Lamellar keratoplasty for the treatment of fungal keratitis. *Cornea* 2002;21(1):33-37.
- 11 Park CY, Lee JK, Gore PK, Lim CY, Chuck RS. Keratoplasty in the United States: a 10-year review from 2005 through 2014. *Ophthalmology* 2015;122(12):2432-2442.
- 12 Ting DS, Sau CY, Srinivasan S, Ramaesh K, Mantry S, Roberts F. Changing trends in keratoplasty in the West of Scotland: a 10-year review. *Br J Ophthalmol* 2012;96(3):405-408.
- 13 Zhang AQ, Rubenstein D, Price AJ, Côté E, Levitt M, Sharpen L, Slomovic A. Evolving surgical techniques of and indications for corneal transplantation in Ontario: 2000-2012. *Can J Ophthalmol* 2013;48(3):153-159.
- 14 Reinhart WJ, Musch DC, Jacobs DS, Lee WB, Kaufman SC, Shtein RM. Deep anterior lamellar keratoplasty as an alternative to penetrating keratoplasty. *Ophthalmology* 2011;118(1):209-218.
- 15 Söğütlü Sari E, Kubaloğlu A, Ünal M, Piñero Llorens D, Koytak A, Ofluoglu AN, Özertürk Y. Penetrating keratoplasty versus deep anterior lamellar keratoplasty: comparison of optical and visual quality outcomes. *Br J Ophthalmol* 2012;96(8):1063-1067.
- 16 Coster DJ, Lowe MT, Keane MC, Williams KA. A comparison of lamellar and penetrating keratoplasty outcomes: a registry study. *Ophthalmology* 2014;121(5):979-987.
- 17 Buzzonetti L, Petrocelli G, Valente P. Femtosecond laser and big-bubble deep anterior lamellar keratoplasty: a new chance. *J Ophthalmol* 2012;2012:264590.
- 18 Chen Y, Hu DN, Xia Y, Yang L, Xue C, Huang Z. Comparison of femtosecond laser-assisted deep anterior lamellar keratoplasty and penetrating keratoplasty for keratoconus. *BMC Ophthalmol* 2015;15:144.
- 19 Alhassan MB, Rabiou M, Agbabiaka IO. Interventions for Mooren's ulcer. *Cochrane Database Syst Rev* 2014;(1):CD006131.
- 20 Liu J, Shi W, Li S, Gao H, Wang T. Modified lamellar keratoplasty and immunosuppressive therapy guided by in vivo confocal microscopy for perforated Mooren's ulcer. *Br J Ophthalmol* 2015;99(6):778-783.
- 21 Chen J, Xie H, Wang Z, Yang B, Liu Z, Chen L, Gong X, Lin Y. Mooren's ulcer in China: a study of clinical characteristics and treatment. *Br J Ophthalmol* 2000;84(11):1244-1249.
- 22 Dong Y, Zhang Y, Xie L, Ren J. Risk factors, clinical features, and treatment outcomes of recurrent Mooren ulcers in China. *Cornea* 2017;36(2):202-209.
- 23 Xie L, Zhai H, Shi W, Zhao J, Sun S, Zang X. Hyphal growth patterns and recurrence of fungal keratitis after lamellar keratoplasty. *Ophthalmology* 2008;115(6):983-987.
- 24 Gao H, Song P, Echegaray JJ, Jia Y, Li S, Du M, Perez VL, Shi W. Big bubble deep anterior lamellar keratoplasty for management of deep fungal keratitis. *J Ophthalmol* 2014;2014:209759.
- 25 Shi W, Wang T, Xie L, Li S, Gao H, Liu J, Li H. Risk factors, clinical features, and outcomes of recurrent fungal keratitis after corneal transplantation. *Ophthalmology* 2010;117(5):890-896.