

Diagnostic ability of ganglion cell complex thickness to detect glaucoma in high myopia eyes by Fourier domain optical coherence tomography

Wei-Wei Wang¹, Huai-Zhou Wang², Jian-Rong Liu¹, Xi-Fang Zhang², Meng Li², Yan-Jiao Huo², Xin-Guang Yang¹

¹Department of Ophthalmology, Xi'an No. 4 Hospital, Shaanxi Ophthalmic Medical Center, Affiliated Guangren Hospital School of Medicine, Xi'an Jiaotong University, Xi'an 710004, Shaanxi Province, China

²Department of Ophthalmology, Beijing Tongren Hospital, Capital Medical University, Beijing 100730, China

Correspondence to: Huai-Zhou Wang. Department of Ophthalmology, Beijing Tongren Hospital, Capital Medical University, No. 1 Dongjiao Minxiang, Dongcheng District, Beijing 100730, China. trhz_wang@163.com

Received: 2018-01-17 Accepted: 2018-04-16

Abstract

• **AIM:** To evaluate the ability of macular ganglion cell complex (GCC) thickness using Fourier domain optical coherence tomography (FD-OCT) to detect glaucoma in highly myopic eyes.

• **METHODS:** Cross-sectional study. A total of 114 participants, consecutively were enrolled. Macular GCC thickness and peripapillary retinal nerve fiber layer (RNFL) thickness were obtained with RTVue FD-OCT. Receiver operating characteristics curves were constructed for each measurement parameter, and areas under the curves (AUCs) were compared.

• **RESULTS:** Both the average GCC and average RNFL thickness showed negative correlations with axial length ($r_{\text{GCC}}=-0.404$, $P=0.001$; $r_{\text{RNFL}}=-0.561$, $P<0.001$). The largest AUCs from GCC, and RNFL parameters were 0.968 [global loss volume (GLV)], and 0.855 (average RNFL), respectively. GLV was significantly better for detecting high myopic glaucoma than average RNFL ($P<0.001$).

• **CONCLUSION:** Macular GCC thickness has higher diagnostic power than peripapillary RNFL thickness to discriminate glaucoma patients from non-glaucoma subjects in high myopia.

• **KEYWORDS:** optical coherence tomography; glaucoma; high myopia; ganglion cell complex

DOI:10.18240/ijo.2018.05.12

Citation: Wang WW, Wang HZ, Liu JR, Zhang XF, Li M, Huo YJ, Yang XG. Diagnostic ability of ganglion cell complex thickness to detect glaucoma in high myopia eyes by Fourier domain optical coherence tomography. *Int J Ophthalmol* 2018;11(5):791-796

INTRODUCTION

Glaucoma is the leading cause of irreversible blinding disease, characterized by loss of retinal ganglion cells (RGCs) followed by visual field defects. Standard automated perimetry has become the clinical gold standard for diagnosis and follow-up of glaucoma. However, clinically detectable structural change can precede the onset of visual field loss by up to 5y^[1]. Peripapillary retinal nerve fiber layer (RNFL) measurements by optical coherence tomography (OCT) have been known as a good structural parameter to detect glaucoma^[2]. Nevertheless, the optic disc of high myopic eyes is often accompanied by tilting, and peripapillary atrophy, which hamper precise diagnosis of glaucoma^[3-5]. Furthermore, several studies have demonstrated that high myopic patients frequently tend to have thinner RNFL than the normal population, leading to inaccurate diagnosis of glaucoma^[6].

The macula is expected to be the best location to evaluate RGC changes, because more than 50% of all RGCs are concentrated and multilayered there and RGCs bodies are 10 to 20 times the diameter of their axons^[7-9]. Macular ganglion cell complex (GCC) includes three retinal layers: inner plexiform layer (IPL), ganglion cell layer (GCL), and the RNFL, representing dendrites of the RGCs, cell bodies and axons. RNFL and GCL become thinner as RGCs die from glaucoma. Therefore, macular GCC measurement may have a good ability to detect glaucoma^[7]. Recent studies showed conflicting results about the ability of macular GCC thickness to detect glaucoma in high myopic eyes. Shoji *et al*^[10-11] and Zhang *et al*^[12] reported that the GCC thickness was better to the RNFL thickness to detect glaucoma in high myopic eyes, while Kim *et al*^[13] and Choi *et al*^[14] found there was no significant difference in the detection ability between RNFL and GCC thickness. In the present study, we used RTVue Fourier domain optical coherence tomography (FD-OCT) to compare the ability of macular GCC thickness and peripapillary RNFL thickness to diagnose glaucoma in high myopic eyes.

SUBJECTS AND METHODS

Participants The patients of this cross-sectional study came from the outpatient service of Beijing Tongren Eye Center, China, between November 2015 and April 2016, who satisfied the inclusion and exclusion criteria. The participants were consecutively enrolled as they presented, and obtained informed consent. The study was approved by the Institutional Ethics Committee of Beijing Tongren Eye Center and complied with the tenets of the Declaration of Helsinki.

All subjects underwent an ophthalmologic examination, including assessment of visual acuity (VA), intraocular pressure (IOP), slit-lamp biomicroscopy, gonioscopy, axial length (Lenstar LS900, Haag-Streit, Koeniz, Switzerland), noncycloplegic refraction (Autorefractor KR-8900, Topcon Corporation, Tokyo, Japan), stereoscopic optic disc photography (WX-3D, Kowa Optimed, Tokyo, Japan), dilated fundus examination and RTVue FD-OCT. Automated visual field examinations (Humphrey visual field analyser, 750i, SITA fast 30-2, Carl Zeiss Meditec, Jena, Germany) were performed in glaucoma patients. Refraction data were converted to spherical equivalents. The subjects were divided by the spherical equivalents into a high myopic group (≤ -6.00 D) and a non-high myopic group (> -6.0 D). Glaucoma patients with a best-corrected visual acuity of 20/100 or better, and spherical equivalent ≤ -6.00 D were included. Subjects without glaucoma with a best-corrected visual acuity of 20/25 or better were included.

Participants were excluded if any evidence suggested ocular surgery history, other diseases (e.g. uveitis, trauma, neuro-ophthalmological diseases, or retinal and/or choroidal diseases). For the purpose of this study, subjects were classified into three groups: high myopic glaucomatous (HMG) group, high myopic normal (HMN) group, and non-high myopic normal (NHMN) group.

Glaucomatous eyes were defined as those with a glaucomatous visual field defect and the appearance of a glaucomatous optic disc irrespective of the level of IOP. In the pattern deviation plot, when presenting three or more significant ($P < 0.05$) contiguous points with at least one at the $P < 0.01$ level on the same side of the horizontal meridian, it means a field defect.

Normal eyes were defined as those with IOP < 21 mm Hg, no family history of glaucoma and intraocular surgery, and no retinal diseases, and no glaucomatous optic neuropathy. Two independent masked glaucomatous specialists defined normal appearance of the optic disc. In the case of a disagreement, a third specialist reviewed the stereo photographs and made a determination.

Optical Coherence Tomography Measurements The thickness of the RNFL and GCC was measured by RTVue FD-OCT (software version: 4.0), which acquires 26 000 A scans per second and has a 5 mm depth resolution in tissue.

The RNFL thickness was determined by the optic nerve head (ONH) protocol comprising 12 radial scans 3.4 mm in length and 13 concentric ring scans ranging from 1.3 to 4.9 mm in diameter, all centered on the optic disc. The GCC thickness was determined by the GCC protocol comprising 15 vertical lines at 0.5 mm intervals and one horizontal line. The center of the GCC scan is shifted 0.75 mm temporally to improve sampling of the temporal periphery. Images with signal strength indicator (SSI) < 40 (as suggested by the manufacturer) were excluded from the analysis.

Statistical Analysis Only the data of the left eye from each patient were used for analysis. Baseline characteristics were summarized in counts and proportions or mean \pm standard deviation (SD). χ^2 tests or unpaired *t*-tests were used for comparisons between groups. Receiver operating characteristic (ROC) curves were constructed for RNFL and GCC parameters to diagnose glaucomatous eyes by plotting sensitivity versus one-specificity. The area under each ROC curve [area under the curve (AUC)] was calculated. The parameters with the largest AUC were selected from RNFL and GCC algorithms to compare diagnostic ability. The method of DeLong *et al.*^[15] was used to compare the largest ROC curve. Statistical analysis was performed using SPSS for Windows (version 19.0.0). *P* values less than 0.05 were considered statistically significant.

RESULTS

During the enrollment period, a total of 157 eyes from 157 individuals who agreed to participate were examined. Ten eyes were excluded because of low signal strength scores. Sixteen eyes with high myopic were excluded owing to the presence of a macular hole ($n=1$) or epiretinal membrane ($n=2$) or macular retinoschisis ($n=13$). In the HMN group, seventeen eyes with axial length more than 29 mm were excluded from analysis. Thus, a total of 114 eyes of 114 participants were included in the analysis: 44 HMN subjects, 31 NHMN subjects, and 39 HMG patients. Table 1 summarizes the demographics and ocular characteristics of the subjects. The mean age among HMN subjects (29.6 ± 8.8 y) was significantly younger than that among HMG patients (36.9 ± 11.3 y; $P=0.002$). Between HMN group and HMG group, there was significant difference in sex ($P < 0.001$), besides, central corneal thickness, axial length, and refraction (spherical equivalent) revealed no significant differences. Between NHMN subjects and HMG patients, age, sex, and central corneal thickness showed no significant differences, and there were significant differences in axial length and refraction (spherical equivalent; $P < 0.001$). The mean defects of visual field were -1.6 ± 1.7 in the NHMN subjects, and were -12.3 ± 9.8 in the HMG patients, and the differences between the two groups were significant different ($P < 0.001$).

Table 1 Characteristics of subjects

Parameters	HMN (n=44)	NHMN (n=31)	HMG (n=39)	P		
				HMN vs HMG	NHMN vs HMG	HMN vs NHMN
Age (y)	29.6±8.8 (19-51)	37.7±6.7 (22-51)	36.9±11.3 (18-65)	0.002	0.730	<0.001
Female, n (%)	32 (72.7)	16 (51.6)	12 (30.8)	<0.001	0.077	0.061
Central corneal thickness (µm)	525.8±37.9 (460-590)	545.4±27.3 (505-600)	543.7±34.3 (485-630)	0.053	0.860	0.057
Axial length (mm)	27.1±1.1 (25.5-28.4)	23.5±0.7 (22.2-24.3)	26.9±0.8 (25.6-28.7)	0.695	<0.001	<0.001
Refraction (spherical equivalent; D)	-7.8±1.6 (-6.0 to -12.5)	-0.8±1.3 (0.5 to -4.0)	-7.9±1.9 (-6.0 to -14.0)	0.742	<0.001	<0.001

HMN: High myopic normal; NHMN: Non-high myopic normal; HMG: High myopic glaucomatous.

Table 2 Perimacular GCC and peripapillary RNFL thickness obtained using RTVue OCT

Parameters	HMN	NHMN	HMG	P		
				HMN vs HMG	NHMN vs HMG	HMN vs NHMN
GCC						
Average (µm)	94.17±5.65	100.28±4.45	73.38±12.81	<0.001	<0.001	<0.001
Superior (µm)	95.11±5.03	99.83±4.53	76.46±14.94	<0.001	<0.001	<0.001
Inferior (µm)	93.25±6.89	100.71±4.59	70.34±12.43	<0.001	<0.001	<0.001
FLV (%)	0.85±1.56	0.53±0.38	10.57±8.49	<0.001	<0.001	0.188
GLV (%)	4.48±3.97	1.02±0.74	27.14±11.21	<0.001	<0.001	<0.001
RNFL						
Average (µm)	94.04±8.74	109.55±6.53	75.68±13.88	<0.001	<0.001	<0.001
Superior (µm)	113.56±18.21	136.61±15.26	94.94±21.58	<0.001	<0.001	<0.001
Temporal (µm)	83.81±12.16	81.32±7.58	59.84±18.79	<0.001	<0.001	0.278
Inferior (µm)	113.81±18.47	139.81±13.71	88.27±19.62	<0.001	<0.001	<0.001
Nasal (µm)	65.11±12.28	79.29±14.83	60.18±14.17	0.097	<0.001	<0.001

GCC: Ganglion cell complex; RNFL: Retinal nerve fibre layer; FLV: Focal loss volume; GLV: Global loss volume; HMN: High myopic normal; NHMN: Non-high myopic normal; HMG: High myopic glaucomatous; OCT: Optical coherence tomography.

Both the average macular GCC thickness and average peripapillary RNFL thickness showed negative correlations with axial length ($r_{GCC}=-0.404$, $P=0.001$; $r_{RNFL}=-0.561$, $P<0.001$). Table 2 summarizes the distribution of GCC thickness and RNFL thickness in the three groups. In the HMG eyes, the average, superior, inferior GCC thickness were significantly thinner both than the HMN eyes and the NHMN eyes (all $P<0.001$). Focal loss volume (FLV) and global loss volume (GLV) were also significantly different compared with both the HMN eyes and the NHMN eyes (all $P<0.001$). When comparing GCC parameters between the HMN group and the NHMN group, except for focal loss volume, the others showed significant differences (all $P<0.001$).

In the HMG eyes, except nasal RNFL thickness, the average, superior, inferior, and temporal RNFL thickness were significantly thinner both than the HMN eyes and the NHMN eyes (all $P<0.001$). In the HMN eyes, except that the temporal RNFL thickness was thicker than that in the NHMN eyes ($P=0.278$), all the other parameters were significantly thinner than that in the NHMN eyes (all $P<0.001$).

Table 3 shows the AUCs and the values with 95% confidence interval (CI) for detection of glaucomatous eyes. When using

the HMN subjects as the normal control, the parameters with the largest AUC in GCC, and RNFL parameters were GLV (0.968), and average RNFL (0.855), respectively. The AUC of GLV was better than that of average RNFL ($P<0.001$). The ROC curves of these selected parameters (GLV, and average RNFL) are depicted in Figure 1. While using the NHMN subjects as the normal control, the AUC of GLV increased to 1.000 (increased by 0.032), and the AUC of average RNFL added up to 0.990 (increased by 0.135).

DISCUSSION

With the reduction of infectious ocular diseases, glaucoma has become an important cause of blindness in China^[16]. In this study, we confirmed that macular GCC thickness has better ability than that of peripapillary RNFL thickness to discriminate glaucoma patients from non-glaucoma subjects in high myopic subgroups.

Ten years ago, some studies have focused macula to detect glaucoma from normal subjects. Because of low discriminating power of time domain (TD)-OCT, those studies tested total macular thickness and showed that peripapillary RNFL were more advantageous than macular parameters. FD-OCT allows more detailed and precise quantitative assessment of

Ganglion cell complex thickness and glaucoma in high myopia

Table 3 AUC values with 95% CIs between normal and glaucomatous eyes

Parameters	AUC±SE (HMN)	95%CI	P	AUC±SE (NHMN)	95%CI	P
GCC						
Average (μm)	0.913±0.035	0.773-0.098	<0.001	0.971±0.020	0.932-1.000	<0.001
Superior (μm)	0.886±0.044	0.801-0.972	<0.001	0.927±0.036	0.856-0.998	<0.001
Inferior (μm)	0.938±0.027	0.886-0.991	<0.001	0.992±0.009	0.975-1.000	<0.001
FLV (%)	0.929±0.031	0.868-0.990	<0.001	0.945±0.031	0.884-1.000	<0.001
GLV (%)	0.968±0.017	0.934-1.000	<0.001	1.000±0.000	1.000-1.000	<0.001
RNFL						
Average (μm)	0.855±0.042	0.773-0.938	<0.001	0.990±0.010	0.971-1.000	<0.001
Superior (μm)	0.730±0.056	0.621-0.840	<0.001	0.942±0.025	0.892-0.991	<0.001
Temporal (μm)	0.853±0.042	0.770-0.935	<0.001	0.851±0.047	0.758-0.944	<0.001
Inferior (μm)	0.836±0.045	0.748-0.924	<0.001	0.978±0.016	0.948-1.000	<0.001
Nasal (μm)	0.633±0.063	0.509-0.707	0.037	0.872±0.044	0.786-0.958	<0.001

SE: Standard error; HMN: High myopic normal; NHMN: Non-high myopic normal; RNFL: Retinal nerve fibre layer; FLV: Focal loss volume; GLV: Global loss volume; AUC: Areas under the curve.

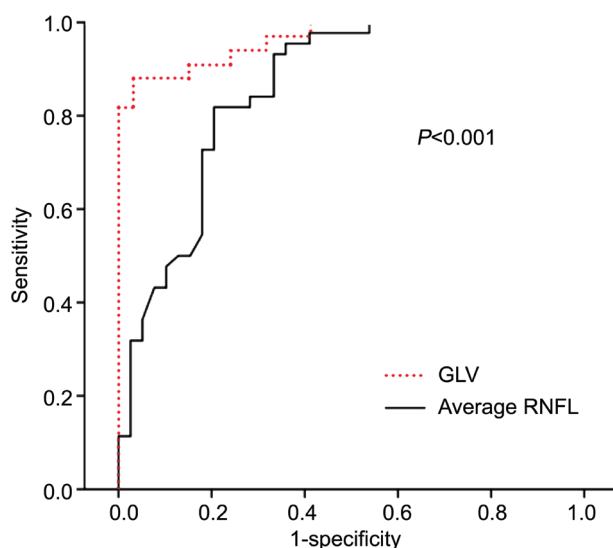


Figure 1 A comparison of areas under receiver operator characteristics curves of high myopic eyes in glaucoma for the GLV and average RNFL.

glaucomatous structural changes^[17]. FD-OCT make it possible to image and measure macular GCC. In glaucomatous eyes, macular thickness decline is believed to be due to the loss of RGCs. Recent studies have demonstrated that macular GCC thickness had comparable diagnostic power with peripapillary RNFL thickness for glaucoma detection^[18-19]. However, in high myopic eyes, the RNFL thickness was significantly affected by refractive errors, and its ability to detect glaucoma was inferior to that in emmetropic eyes. In our study, the average, superior, inferior, and nasal peripapillary RNFL along with all of the macular GCC thickness were significantly thinner in the HMN group than that in the NHMN group, although the HMN group included a younger population on average. It is established that the RNFL thickness and macular GCC thickness decrease with aging^[20]. Whereas the temporal RNFL was thicker in the HMN group than that in the NHMN group. These findings are

in agreement with previous reports^[13-14,21]. The possible reasons may be as follows. Myopia affects the distribution of the RNFL thickness around the optic disc^[13]. With raising myopia, the inferotemporal and superotemporal RNFL bundles tend to converge temporally^[8,22]. Therefore, GCC measurements may be theoretically superior to RNFL parameters in high myopic glaucoma. Our results validated this point. We found that AUCs for the GCC-GLV and average RNFL were 0.968 and 0.855, respectively, and the difference was statistically significant. The present study implies that the macular GCC thickness attained higher diagnostic power than peripapillary RNFL thickness to detect glaucoma in high myopic patients. This result was in line with other findings^[10-11].

The internal normative database in current OCT instrument didn't include high myopic eyes. The average RNFL thickness become thinner to distant to optic disc because of a magnification effect of longer axial length leading to scan larger area. Thus values of AUC for average RNFL were better in NHMN eyes than HMN eyes. Our results indicate that the use of RNFL thickness to detect HMG may lead to false positive diagnosis when using the internal database. These findings are consistent with previous observations^[23-24]. Therefore, using the internal database may lead to improper interpretation of RNFL thicknesses when evaluating glaucoma with high myopia.

As for the effect of myopia on the thickness of macular GCC measured by OCT, previous studies have obtained conflicting results. Ooto *et al*^[20] found that there was not a correlation between axial length and macular GCC thickness, whereas some studies^[25] including ours, showed a negative correlation between macular inner retinal layer thickness and axial length. We also found that there were significant differences in the average, superior, and inferior macular GCC thickness between the HMN and NHMN eyes. On one hand, retinal

thinning associated with the extension of the retinal surface due to axial elongation. On the other hand, retinal thinning also associated with the projection artifact of the scanning area of the OCT instruments in HMN eyes. The measured thickness may change if a larger area is scanned in eyes with longer axis length. However, the influence of high myopia on GCC may be less than that on RNFL parameters, which was consistent with Shoji's study^[10]. Shoji *et al*^[10] found that macular GCC thickness efficiently detected glaucoma in both high myopic and emmetropic eyes, and only peripapillary RNFL thickness had a decreased ability for glaucoma detection in high myopic eyes. Thus, it is very important to install a normal database from normal eyes with high myopia as internal data in OCT instruments.

In conclusion, the macular GCC thickness had better ability to detect glaucoma in high myopia than peripapillary RNFL thickness from FD-OCT, although both the macular GCC thickness and peripapillary RNFL thickness were related with axial length. Thus, GCC assessment might be one of the best parameters for diagnosing highly myopia glaucoma. It would be more precise for glaucoma detection in high myopic patients if a normal database in high myopic eyes was available.

ACKNOWLEDGEMENTS

The authors acknowledge Professor Ning-Li Wang in Department of Ophthalmology, Beijing Tongren Hospital, Capital Medical University, who gave us help to complete this study.

Foundation: Supported by the National Natural Science Foundation of China (No.81500719).

Conflicts of Interest: Wang WW, None; Wang HZ, None; Liu JR, None; Zhang XF, None; Li M, None; Huo YJ, None; Yang XG, None.

REFERENCES

- 1 Sommer A, Katz J, Quigley HA, Miller NR, Robin AL, Richter RC, Witt KA. Clinically detectable nerve fiber atrophy precedes the onset of glaucomatous field loss. *Arch Ophthalmol* 1991;109(1):77-83.
- 2 Akashi A, Kanamori A, Nakamura M, Fujihara M, Yamada Y, Negi A. The ability of macular parameters and circumpapillary retinal nerve fiber layer by three SD-OCT instruments to diagnose highly myopic glaucoma. *Invest Ophthalmol Vis Sci* 2013;54(9):6025-6032.
- 3 Kim MJ, Lee EJ, Kim TW. Peripapillary retinal nerve fibre layer thickness profile in subjects with myopia measured using the Stratus optical coherence tomography. *Br J Ophthalmol* 2010;94(1):115-120.
- 4 Shin HY, Park HY, Park CK. The effect of myopic optic disc tilt on measurement of spectral-domain optical coherence tomography parameters. *Br J Ophthalmol* 2015;99(1):69-74.
- 5 Holló G, Shu-Wei H, Naghizadeh F. Evaluation of a new software version of the RTVue optical coherence tomograph for image segmentation and detection of glaucoma in high myopia. *J Glaucoma* 2016;25(6):e615-e619.

- 6 Seol BR, Jeoung JW, Park KH. Glaucoma detection ability of macular ganglion cell-inner plexiform layer thickness in myopic preperimetric glaucoma. *Invest Ophthalmol Vis Sci* 2015;56(13):8306-8313.
- 7 Ishikawa H, Stein DM, Wollstein G, Beaton S, Fujimoto JG, Schuman JS. Macular segmentation with optical coherence tomography. *Invest Ophthalmol Vis Sci* 2005;46(6):2012-2017.
- 8 Tan O, Li G, Lu AT, Varma R, Huang D; Advanced Imaging for Glaucoma Study Group. Mapping of macular substructures with optical coherence tomography for glaucoma diagnosis. *Ophthalmology* 2008;115(6):949-956.
- 9 Sung KR, Wollstein G, Kim NR, Na JH, Nevins JE, Kim CY, Schuman JS. Macular assessment using optical coherence tomography for glaucoma diagnosis. *Br J Ophthalmol* 2012;96(12):1452-1455.
- 10 Shoji T, Sato H, Ishida M, Takeuchi M, Chihara E. Assessment of glaucomatous changes in subjects with high myopia using spectral domain optical coherence tomography. *Invest Ophthalmol Vis Sci* 2011;52(2):1098-1102.
- 11 Shoji T, Nagaoka Y, Sato H, Chihara E. Impact of high myopia on the performance of SD-OCT parameters to detect glaucoma. *Graefes Arch Clin Exp Ophthalmol* 2012;250(12):1843-1849.
- 12 Zhang Y, Wen W, Sun X. Comparison of several parameters in two optical coherence tomography systems for detecting glaucomatous defects in high myopia. *Invest Ophthalmol Vis Sci* 2016;57(11):4910-4915.
- 13 Kim NR, Lee ES, Seong GJ, Kang SY, Kim JH, Hong S, Kim CY. Comparing the ganglion cell complex and retinal nerve fibre layer measurements by Fourier domain OCT to detect glaucoma in high myopia. *Br J Ophthalmol* 2011;95(8):1115-1121.
- 14 Choi YJ, Jeoung JW, Park KH, Kim DM. Glaucoma detection ability of ganglion cell-inner plexiform layer thickness by spectral-domain optical coherence tomography in high myopia. *Invest Ophthalmol Vis Sci* 2013;54(3):2296-2304.
- 15 DeLong ER, DeLong DM, Clarke-Pearson DL. Comparing the areas under two or more correlated receiver operating characteristic curves: a nonparametric approach. *Biometrics* 1988;44(3):837-845.
- 16 Li X, Zhang S, Liang Q, Wang M, Hu A, Li X, Yang B, Zhang M, Wang N, Lu X. Molecular characteristics of the ompA gene of serotype B Chlamydia trachomatis in Qinghai Tibetan primary school students. *Sci China Life Sci* 2016;59(6):561-570.
- 17 Rao HL, Zangwill LM, Weinreb RN, Sample PA, Alencar LM, Medeiros FA. Comparison of different spectral domain optical coherence tomography scanning areas for glaucoma diagnosis. *Ophthalmology* 2010;117(9):1692-1699.
- 18 Firat PG, Doganay S, Demirel EE, Colak C. Comparison of ganglion cell and retinal nerve fiber layer thickness in primary open-angle glaucoma and normal tension glaucoma with spectral-domain OCT. *Graefes Arch Clin Exp Ophthalmol* 2013;251(3):831-838.
- 19 Ueda K, Kanamori A, Akashi A, Tomioka M, Kawaka Y, Nakamura M. Effects of axial length and age on circumpapillary retinal nerve fiber layer and inner macular parameters measured by 3 types of SD-OCT instruments. *J Glaucoma* 2016;25(4):383-389.
- 20 Ooto S, Hangai M, Tomidokoro A, Saito H, Araie M, Otani T, Kishi S, Matsushita K, Maeda N, Shirakashi M, Abe H, Ohkubo S, Sugiyama K,

Ganglion cell complex thickness and glaucoma in high myopia

- Iwase A, Yoshimura N. Effects of age, sex, and axial length on the three-dimensional profile of normal macular layer structures. *Invest Ophthalmol Vis Sci* 2011;52(12):8769-8779.
- 21 Akashi A, Kanamori A, Ueda K, Inoue Y, Yamada Y, Nakamura M. The ability of SD-OCT to differentiate early glaucoma with high myopia from highly myopic controls and nonhighly myopic controls. *Invest Ophthalmol Vis Sci* 2015;56(11):6573-6580.
- 22 Yamashita T, Kii Y, Tanaka M, Yoshinaga W, Yamashita T, Nakao K, Sakamoto T. Relationship between supernormal sectors of retinal nerve fibre layer and axial length in normal eyes. *Acta Ophthalmol* 2014;92(6):e481-e487.
- 23 Kim KE, Jeoung JW, Park KH, Kim DM, Kim SH. Diagnostic classification of macular ganglion cell and retinal nerve fiber layer analysis: differentiation of false-positives from glaucoma. *Ophthalmology* 2015;122(3):502-510.
- 24 Nakanishi H, Akagi T, Hangai M, Kimura Y, Suda K, Kumagai KK, Morooka S, Ikeda HO, Yoshimura N. Sensitivity and specificity for detecting early glaucoma in eyes with high myopia from normative database of macular ganglion cell complex thickness obtained from normal non-myopic or highly myopic Asian eyes. *Graefes Arch Clin Exp Ophthalmol* 2015;253(7):1143-1152.
- 25 Mwanza JC, Durbin MK, Budenz DL, Girkin CA, Leung CK, Liebmann JM, Peace JH, Werner JS, Wollstein G; Cirrus OCT Normative Database Study Group. Profile and predictors of normal ganglion cell-inner plexiform layer thickness measured with frequency-domain optical coherence tomography. *Invest Ophthalmol Vis Sci* 2011;52(11):7872-7879.