

Clinical outcomes after implantation of a new intrastromal corneal ring with 140-degree of arc in patients with corneal ectasia

Jordana Sandes¹, Larissa R. S. Stival¹, Marcos Pereira de Ávila¹, Paulo Ferrara², Guilherme Ferrara², Leopoldo Magacho¹, Luana P. N. Araújo³, Leonardo Torquetti⁴

¹Center of Reference in Ophthalmology (CEROF), Goiânia 64605-020, Brazil

²Paulo Ferrara Eye Clinic, Belo Horizonte-MG 30110-921, Brazil

³Fundação Altino Ventura, Recife-PE 50070-040, Brazil

⁴Center of Excellence in Ophthalmology, Pará de Minas 35660-017, Brazil

Correspondence to: Jordana Sandes. Street T-15, Sector Bueno, Number 715, Apartment 2601, Goiânia-GO 74230-010, Brazil. jordana.ofalmo@gmail.com

Received: 2017-09-08 Accepted: 2017-11-14

Abstract

• **AIM:** To evaluate the clinical and tomographic outcomes after implantation of a new intrastromal corneal ring segment (ICRS) with 140-degrees of arc in eyes with corneal ectasia.

• **METHODS:** We evaluated patients with corneal ectasia implanted with Ferrara 140° ICRS from April 2010 to February 2015. Outcome measures included preoperative and postoperative corrected distance visual acuity (CDVA), keratometry simulated (K) reading, tomographic astigmatism and asphericity. All patients were evaluated using the Pentacam Scheimpflug system.

• **RESULTS:** The study evaluated 58 eyes. The mean follow-up was 16.81±10.8mo. The CDVA (logMAR) improved from 0.5±0.20 (20/60) to 0.3±0.21 (20/40) ($P<0.01$). The average K reduced from 49.87±7.01 to 47.34±4.90 D ($P<0.01$). The asphericity changed from -0.60±0.86 to -0.23±0.67 D ($P<0.01$). The mean preoperative tomographic astigmatism decreased from -8.0±3.45 to -4.53±2.52 D ($P<0.01$).

• **CONCLUSION:** The new ICRS model with 140-degrees of arc effectively improve the visual acuity and reduce the high astigmatism usually found in patients with corneal ectasia.

• **KEYWORDS:** keratoconus; intrastromal corneal ring segment; corneal ectasia

DOI:10.18240/ijo.2018.05.14

Citation: Sandes J, Stival LRS, Ávila MP, Ferrara P, Ferrara G, Magacho L, Araújo LPN, Torquetti L. Clinical outcomes after implantation of a new intrastromal corneal ring with 140-degree of arc in patients with corneal ectasia. *Int J Ophthalmol* 2018;11(5):802-806

INTRODUCTION

Intrastromal corneal ring segments (ICRS) are an efficacious alternative in patients with clear corneas who have unsatisfactory corrected visual acuity with glasses or contact lens and contact lens intolerance^[1-5]. It acts according to Barraquer's postulate which states that tissue addition in corneal periphery leads to corneal flattening. The ring diameter (optical zone) determines how much the cornea will be flattened. The thicker and smaller the optical zone of the implanted segment, the more flattening effect and myopic reduction is achieved^[6-8]. The main advantages of this procedure are its safety, reversibility, and stability, as well as the fact that the segments do not affect the visual axis^[9-10].

There are different models of ICRS with varying sizes and arc thicknesses. Theoretically, a shorter segment induces a greater astigmatic correction and induces lesser asphericity change, comparing with long arch segments. The new model presents a short arc length of 140 degrees (140-ICRS) with the main advantage of astigmatism reduction. The primary indication is in keratoconus patients with high astigmatism^[11-12].

The intrastromal tunnel for ring implantation was initially manually constructed; however, complications such as epithelial defects, depth asymmetry and perforation, were reported^[13]. Femtosecond laser has recently been used to create the tunnel for ring implantation. This technique reportedly creates a tunnel with precise depth, width and location leading to faster visual recovery and less incidence of surgical complications^[14-15].

The main purpose of this study is to evaluate the clinical results of the implantation of 140-ICRS regarding its efficacy and capacity of corneal astigmatism reduction. Moreover we compared the clinical outcomes of patients implanted with the Ferrara 140-ICRS using the manual and femtosecond laser assisted technique.

SUBJECTS AND METHODS

This retrospective study included keratoconus eyes with high astigmatism that were intolerant to contact lens or disease progression and presented visual acuity worse than 0.2 logMAR (20/30). An informed consent was given to all eligible patients prior to data collection, requesting permission

for the research and use of data from their medical records relating to the pre and postoperative periods. All bioethical principles were considered in accordance with the Declaration of Helsinki and Brazilian regulations.

The same surgeon (Paulo Ferrara) performed all surgical procedures using the manual or femtosecond laser-assisted technique for ICRS implantation. Both techniques have been widely described in the literature^[2,5,13-15]. Patients were randomized to receive a manual or laser-assisted surgical technique.

The corneal depth of ICRS were 80% for all cases (manual and laser). In the manual technique, the surgery was performed under topical anesthesia, and the visual axis is marked; a 5-mm optical zone and incision side were aligned with the desired axis in which the incision would be made, in the steepest axis. The diamond blade was set at 80% of corneal depth at the incision site. After the incision, a stromal spreader creates a pocket on each side of the incision. Two semi-circular dissecting spatulas were consecutively inserted through the incision and gently pushed with some quick rotary back and forth movements. Following channel creation, the ring segments were implanted.

Using the femtosecond laser, LDV Z4 (Ziemer, Switzerland), tunnel depth is set at 80% of the thinnest corneal thickness within the probable ring track. The channel's inner diameter is set to 4.4 mm, the outer diameter 5.6 mm and the entry cut thickness was 1 µm (at the steepest topographic axis). The ring energy used for channel creation is 1.3 mJ. The femtosecond laser takes approximately 15s to create the channel. The segments are implanted immediately after channel creation before the disappearing of the bubbles, which reveals the exact tunnel location. The segments were placed in the final position with a Sinsky hook through a dialing hole at both ends of the segment^[14-16].

According to the Ferrara Ring nomogram, for 140-ICRS, the selection of the thickness of the segment to be implanted varies with the preoperative tomographic astigmatism. For asymmetric keratoconus a single segment was implanted and for symmetrical keratoconus 2 segments were implanted. Asymmetry means that, by dividing the cornea into two halves from the more curved meridian considering the anterior sagittal map of the pentacam, asymmetric corneas are those that the halves are unequal, and symmetrical corneas are those that the halves are very similar.

Descriptive analysis such as age, sex, technique and follow-up was collected for all patients. Statistical analysis included preoperative and postoperative, corrected distance visual acuity (CDVA), refractive astigmatism, tomographic astigmatism, keratometry simulated (K) readings, mean flattest axis (K1), mean steepest axis (K2) and asphericity. Corneal tomography and pachymetry were obtained using the software included within

Table 1 Segment thickness according to preoperative tomographic astigmatism

Tomographic astigmatism (D)	Segment thickness
Asymmetric keratoconus	
<4.00	1 segment 150 µm
>4.00 and <8.00	1 segment 200 µm
>8.00	1 segment 250 µm
Symmetric keratoconus	
<6.00	2 segments 150 µm
>6.00 and <10.00	2 segments 200 µm
>10.00	2 segments 250 µm

the Pentacam rotation Scheimpflug camera (Oculus Pentacam, Wetzlar, Germany). Statistical analysis was carried out using the Minitab software (Minitab Inc., Chicago, USA).

Analysis of Astigmatism The astigmatism results were analyzed arithmetically (nonvector analysis) and using vector analysis when concerning the cylindrical axis. Although observed changes in cylinders were commonly reported, they do not accurately reflect the actual nature of the change in the cylinder. The magnitude and axis of the cylinder are related to the spherical power. The vector analysis used for calculating surgically induced astigmatism change was a Doubled-Angle polar plot.

Due to astigmatism traverses an entire cycle in 180 degrees, the doubled-angle polar plot was described as the most appropriate plot for aggregating astigmatism data. In this method, the centroid is the mean of a set of *x* and *y* values. The standard deviation can be represented in a graphic by an area surrounding the centroid. The shape of this area will vary depending on the length of the major and minor axis. The shape factor (*p*) has been used to describe this relationship^[17].

Statistical Analysis Normality of data was evaluated with the Kolmogorov-Smirnov test. The analysis of primary outcome measures was based on a normal distribution of the data. Student's *t*-test for paired variables was used to compare pre and postoperative data considering a significance level of *P*<0.05. Graphic analysis was made using the Microsoft Excel 2007 (USA) and SPSS Sigma Plot 12.0 (USA).

RESULTS

Fifty eight eyes/patients were evaluated. The average follow-up was 16.81±10.8mo. The mean age was 33.3±13.2y. Forty six patients (79.3%) were male, and twelve patients (20.7%) were female. Considering the analysis by groups, in group 1 (17 eyes) 2 segments of 200 µm (140/200) were implanted; in group 2 (30 eyes) a single 150 µm segment (140/150) was implanted and in group 3 (11 eyes) a single 200 µm segment (140/200) was implanted (Table 1).

Last follow up, 12.2% of patients maintained the same CDVA, 13.7% of patients had the CDVA worsened, and 74.1% of patients had improvement in CDVA. The improved average

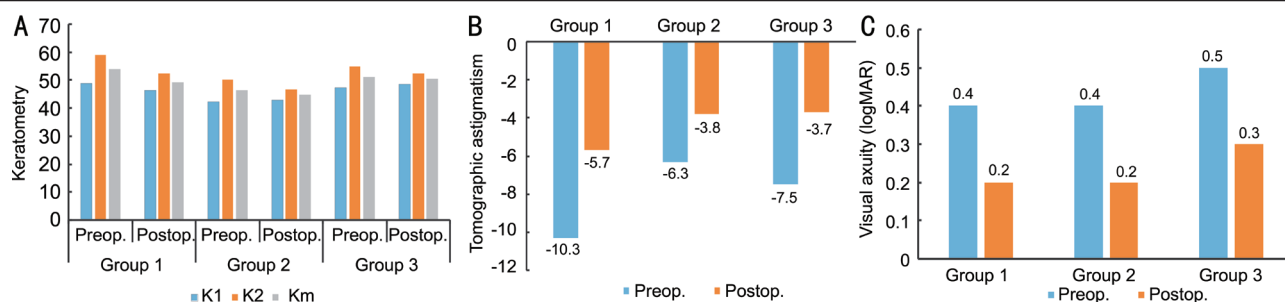


Figure 1 Pre- and post-operative K1, K2 and Km (A), tomographic astigmatism (B), CDVA (logMAR) (C) in the 3 groups.

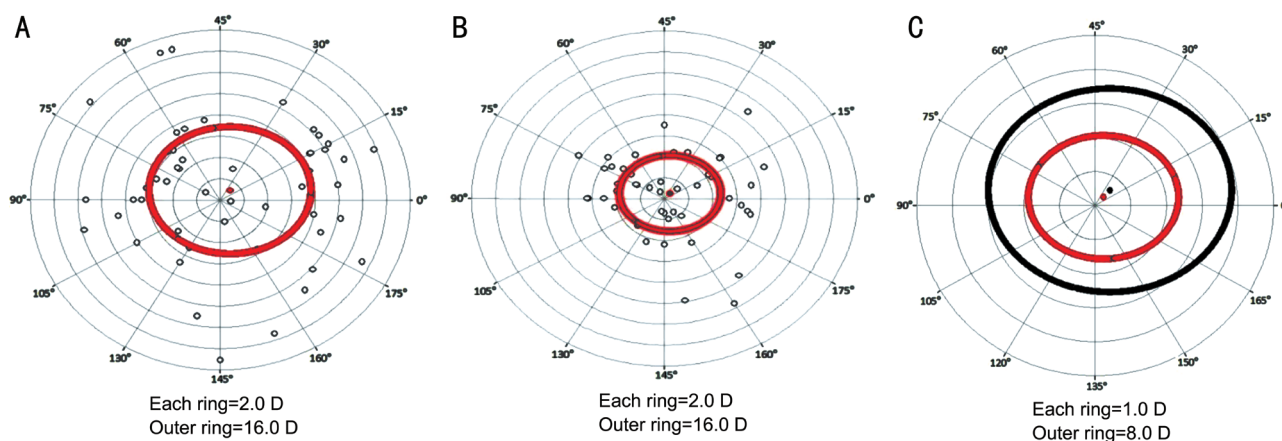


Figure 2 Doubled-angle plot of the pre- and post-operative keratometric cylinder at the corneal plane A: The preoperative centroid of the keratometric astigmatism was 1.22 D at 23.17°±6.39°, ρ=0.77; B: The postoperative centroid of the keratometric astigmatism was 0.68 D at 22.37°±3.91°, ρ=0.74; C: The relationship between the preoperative and postoperative keratometric astigmatism. There was a significant reduction in the keratometric astigmatism.

was four lines of vision (gain of 1 to 9 lines of vision), three patients lost two lines of vision, and five patients lost one line of vision (Table 2).

In group 1 (2 segments 140/200), the CDVA improved from 0.4±0.3 logMAR (20/50) to 0.2±0.1 logMAR (20/30) (*P*=0.02), K1 decreased from 48.8±6.4 to 46.4±4.3 D (*P*<0.01), K2 decreased from 59.1±7.1 to 52.2±4.4 D (*P*=0.05), average keratometry (Km) decreased from 54.4±6.6 to 49.3±4.3 D (*P*<0.01), asphericity changed from -1.1±0.6 to -0.5±0.6 (*P*<0.01). The tomographic astigmatism had a significant decrease from -10.3±2.9 to -5.7±1.8 D (*P*<0.01).

In group 2 (1 segment 140/150) the CDVA improved from 0.4±0.2 logMAR (20/50) to 0.2±0.1 logMAR (20/30) (*P*<0.01), K2 decreased from 50.0±7.4 to 46.6±3.6 D (*P*=0.01), the asphericity changed from 0.0±0.3 to 0.1±0.4 (*P*=0.01) and the tomographic astigmatism improved from -6.3±2.9 to -3.8±2.2 D (*P*<0.01).

In group 3 (1 segment 140/200) there was a statistically significant change only in K2 and tomographic astigmatism. The K2 decreased from 54.9±7.6 to 52.2±6.5 D (*P*<0.01) and the tomographic astigmatism decreased from -7.5±3.9 to -3.7±2.2 D (*P*<0.01; Figure 1).

The tomographic astigmatism using the manual technique decreased the average 3.7 D and femtosecond technique decreased 3.1 D (*P*>0.01). The refractive astigmatism

Table 2 Preoperative and postoperative data of all patients

Parameters	Preoperative	Postoperative	mean±SD	<i>P</i>
CDVA (logMAR)	0.5±0.20 (20/60)	0.3±0.21 (20/40)		<0.01
K1 (D)	45.49±6.38	45.14±5.10		0.35
K2 (D)	54.19±8.40	49.54±5.11		<0.01
Km (D)	49.87±7.01	47.34±4.90		<0.01
Asphericity (D)	-0.60±0.86	-0.23±0.67		<0.01
Tomographic astigmatism (D)	-8.00±3.45	-4.53±2.52		<0.01

CDVA: Corrected distance visual acuity; K1: Mean flattest axis; K2: Mean steepest axis; Km: Average keratometry.

improved in 1.7 D in manual technique and 2.9 D in femto technique (*P*>0.01). The Km using manual technique flattened -2.5 D and in femto technique flattened -2.4 D (*P*>0.01). The anterior asphericity improved in 0.4 in manual technique and 0.3 in femto technique (*P*>0.01).

Figure 2 shows the double-angle plots of the individual cylinders, providing an overview of the cylinder magnitude (diopter) and axis (degree) of each data point. The radius from the center of the plot to each point represents the magnitude of the cylinder. The centroid of preoperative keratometric astigmatism was 1.22 D at 23.17°±6.39°, ρ=0.77 and the postoperative centroid was 0.68 D at 22.37°±3.91°, ρ=0.74. The keratometric astigmatism centroid is 0.54 D closer to zero,

and the standard deviation of the astigmatism was reduced by a factor of 1.63 (6.39 D/3.91 D). The relocation of the centroid closer to the origin and the contraction of the ellipse on the doubled-angle plots demonstrate the amount of improvement.

DISCUSSION

The analysis of our results revealed that the implantation of 140-ICRS was efficacious and improved the visual acuity in most patients. Postoperatively, there was a significant decrease in Km, tomographic astigmatism and improvement of CDVA. In group 1 (2 segments 140/200) we observed a significant flattening effect, a marked improvement in asphericity and a substantial reduction of tomographic astigmatism; it seems to be a good option for cases of symmetrical cones with hyperprolate cornea, high keratometry and very high astigmatism. In group 2 (1 segment 140/150) and group 3 (1 segment 140/200), a significant reduction in astigmatism was observed. There was little change in asphericity and keratometry. This was in agreement with the effect needed in some cases of asymmetric cones with high astigmatism, corneal asphericity close to normal values and curvatures not significantly steep.

A study realized by Ruckhofer *et al*^[18] about correction of astigmatism with short arch segments showed a significant correction of low to moderate compound myopic astigmatism safely and predictably. However, the study evaluated healthy astigmatic corneas, not eyes with keratoconus. In our study, we analyzed corneas with ectasia and demonstrated proper correction of tomographic astigmatism with short arc length (140°) ICRS. These segments may provide a useful alternative for the surgical correction of astigmatism in corneal ectasia.

Many studies have confirmed the efficacy and safety of the ICRS in reducing spherocylindrical error and corneal steepening in keratoconus over the short and long term^[3-4], but most do not analyze astigmatism as a vector. They evaluate changes in the magnitude of astigmatism only. However, it is important to investigate variations in the axis of the cylinder and to determine whether the astigmatic correction was induced in the targeted meridian. Errors in the correction of the astigmatic axis could induce aberrations and lead to poor predictability of the spherocylindrical correction.

Our study demonstrated changes in astigmatism after ICRS implantation in patients with keratoconus using vectorial analysis^[19] and showed that despite the reduction of the magnitude of corneal astigmatism, not always the corrected meridian was the planned, with a tendency for undercorrection, especially in corneas with higher astigmatism. The importance of the vector analysis of astigmatism is to avoid incorrect or incomplete conclusions.

The use of femtosecond laser as a safe and accurate method for the creation of the intrastromal tunnel was recently

proposed^[14-15]. Studies comparing the manual technique with femtosecond technique found that there was no differences between the improve in visual acuity and decrease in keratectomy comparing both techniques, but the incidence of peroperative complications is less in femtosecond technique^[15]. Thus, the use of femtosecond laser may not provide better outcomes, but rather an easier and more reproducible technique for the surgeon. In this study, we did not find significant improvements in the results when comparing the manual technique with the femtosecond laser technique, considering an experienced surgeon.

In conclusion, there was a significant improvement of all parameters analyzed. The short arc intrastromal corneal ring segments seem to be a valuable treatment, which can provide satisfactory visual outcomes^[20]. A few potential limitations were apparent in this study as the small sample of treated eyes and the lack of a comparative group. Future larger, comparative studies are needed to confirm the results found in this study.

ACKNOWLEDGEMENTS

Conflicts of Interest: Sandes J, None; Stival LRS, None; Ávila MP, None; Ferrara P, Comercial interest in Ferrara ICRS; Ferrara G, Comercial interest in Ferrara ICRS; Magacho L, None; Araújo LPN, None; Torquetti L, None.

REFERENCES

- 1 Vega-Estrada A, Alio JL, Brenner LF, Javaloy J, Plaza Puche AB, Barraquer RI, Teus MA, Murta J, Henriques J, Uceda-Montanes A. Outcome analysis of intracorneal ring segments for the treatment of keratoconus based on visual, refractive, and aberrometric impairment. *Am J Ophthalmol* 2013;155(3):575-584.e1.
- 2 Alio JL, Vega-Estrada A, Esperanza S, Barraquer RI, Teus MA, Murta J. Intrastromal corneal ring segments: how successful is the surgical treatment of keratoconus? *Middle East Afr J Ophthalmol* 2014;21(1):3-9.
- 3 Vega-Estrada A, Alio JL. The use of intracorneal ring segments in keratoconus. *Eye Vis (Lond)* 2016;3:8.
- 4 Giacomini NT, Mello GR, Medeiros CS, Kiliç A, Serpe CC, Almeida HG, Kara-Junior N, Santhiago MR. Intracorneal ring segments implantation for corneal ectasia. *J Refract Surg* 2016;32(12):829-839.
- 5 Kiliç A, del Barrio JLA, Estrada AV. Intracorneal ring segments: types, indications and outcomes. In: Alió J. (eds) *Keratoconus: Essentials in Ophthalmology*. Springer:Cham 2017:195-208.
- 6 Chan K, Hersh PS. Removal and repositioning of intracorneal ring segments: improving corneal topography and clinical outcomes in keratoconus and ectasia. *Cornea* 2017;36(2):244-248.
- 7 Lyra JM, Lyra D, Ribeiro G, Torquetti L, Ferrara P, Machado A. Tomographic findings after implantation of ferrara intrastromal corneal ring segments in keratoconus. *J Refract Surg* 2017;33(2):110-115.
- 8 Barraquer JI. Modification of refraction by means of intracorneal inclusions. *Int Ophthalmol Clin* 1966;6(1):53-78.
- 9 Abdelmassih Y, El-Khoury S, Dirani A, Antonios R, Fadlallah A, Cherfan CG, Chelala E, Jarade EF. Safety and efficacy of sequential

A new intrastromal corneal ring with 140-degree arc in corneal ectasia

- intracorneal ring segment implantation and cross-linking in pediatric keratoconus. *Am J Ophthalmol* 2017;178:51-57.
- 10 Torquetti L, Ferrara G, Almeida F, Cunha L, Araujo LP, Machado A, Marcelo Lyra J, Merayo-Llodes J, Ferrara P. Intrastromal corneal ring segments implantation in patients with keratoconus: 10-year follow-up. *J Refract Surg* 2014;30(1):22-26.
- 11 Jabbarvand M, Hashemian H, Khodaparast M, Bazvand F, Beheshtnejad A. Outcome of complete intrastromal ring implantation using femtosecond laser in pellucid marginal degeneration. *Eye (Lond)* 2015;29(6):783-790.
- 12 Albertazzi R, Ferlini L, Rao G, Merayo-Llodes J, Alfonso J. Software-based assessment of intrastromal rings surgical plan for keratoconus. *Invest Ophthalmol Vis Sci* 2014;55(13):4225.
- 13 Tognon T, Campos M, Wengrzynowski JP, Barella KA, Pasqualotti A, de Brito Martins LA, Dos Santos Forseto A, de Sousa LB. Indications and visual outcomes of intrastromal corneal ring segment implantation in a large patient series. *Clinics* 2017;72(6):370.
- 14 Izquierdo L Jr, Orozco A, Henriquez MA. New technique of femtosecond laser-assisted intracorneal ring segment implantation. *Cornea* 2017;36(7):884-888.
- 15 Alió JL, Renna A. Insertion of intrastromal corneal ring segments (ICRS), femtosecond laser assisted. Rosenberg E, Nattis A, Nattis R. *Operative Dictations in Ophthalmology*. Springer: Cham 2017:75-78.
- 16 Sammour HM, Ismail MM, Abdelghany AI, Shafeek MA. Comparative study between myring and ferrara ring intracorneal implantation using femtosecond laser for treatment of keratoconus. *Egyptian Journal of Hospital Medicine* 2017;68:910-922.
- 17 Holladay JT, Dudeja DR, Koch DD. Evaluating and reporting astigmatism for individual and aggregate data. *J Cataract Refract Surg* 1998;24(1):57-65.
- 18 Ruckhofer J, Stoiber J, Twa MD, Grabner G. Correction of astigmatism with short arc-length intrastromal corneal ring segments: preliminary results. *Ophthalmology* 2003;110(3):516-524.
- 19 Piñero DP, Alió JL, Teus MA, Barraquer RI, Michael R, Jiménez R. Modification and refinement of astigmatism in keratoconic eyes with intrastromal corneal ring segments. *J Cataract Refract Surg* 2010;36(9):1562-1572.
- 20 Heikal MA, Abdelshafy M, Soliman TT, Hamed AM. Refractive and visual outcomes after Keraring intrastromal corneal ring segment implantation for keratoconus assisted by femtosecond laser at 6 months follow-up. *Clin Ophthalmol* 2017;11:81-86.