

# Choroidal neovascularization post macular surgery: a case series

Georgios Tsokolas, Benjamin Clarke, Hussein Almuhtaseb, Bhaskar Gupta

Eye Unit, University Hospital Southampton, Southampton, Hampshire SO16 6YD, United Kingdom

**Correspondence to:** Georgios Tsokolas. Southampton Eye Unit, University Hospitals Southampton NHS Foundation Trust, Southampton, Hampshire SO16 6YD, United Kingdom. gchoko1988@yahoo.com

Received: 2018-03-01 Accepted: 2018-05-28

DOI:10.18240/ijo.2018.08.28

**Citation:** Tsokolas G, Clarke B, Almuhtaseb H, Gupta B. Choroidal neovascularization post macular surgery: a case series. *Int J Ophthalmol* 2018;11(8):1425-1429

## Dear Editor,

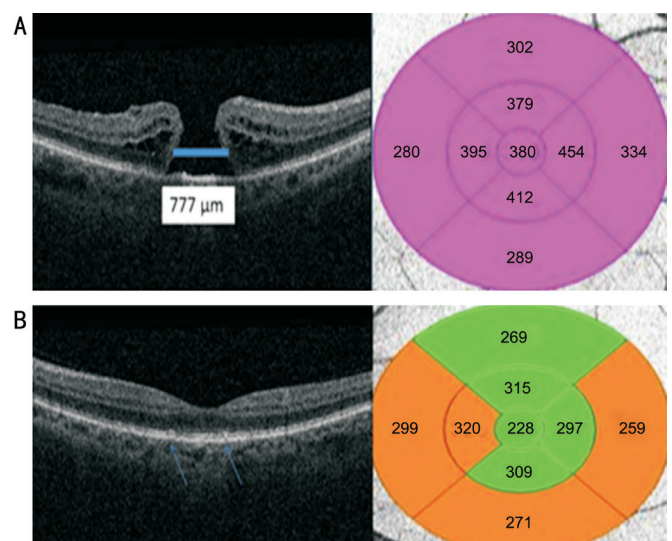
My name is Georgios Tsokolas and I am currently working as Medical Retina Research Fellow at the Eye Unit of Southampton General Hospital in United Kingdom. I am writing this letter to present three case series of choroidal neovascular (CNV) membrane after macular surgery, which responded poorly to intravitreal injections of anti-vascular endothelial growth factors (anti-VEGF).

This is an observational case series. The three cases were identified from our electronic medical record (Medisoft). Visual acuity assessment and complete ophthalmic examination including multimodal imaging were performed. Multimodal imaging included color fundus photographs, optical coherence tomography (OCT) and fundus fluorescein angiography (FFA). Fundus photography and the multimodal imaging investigations were obtained with a confocal scanning laser ophthalmoscope (Spectralis HRA-OCT; Spectralis HRA-FFA; Heidelberg Eye Explorer, Version 1.9.17.0, Heidelberg Engineering, Heidelberg, Germany).

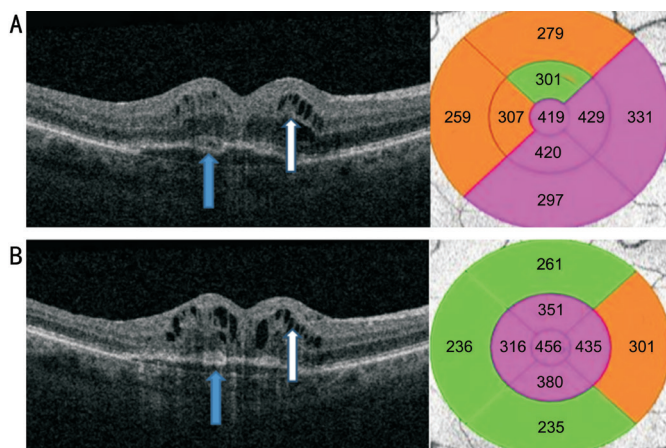
**Case 1** A 62 year-old female Caucasian patient (P1) was referred to the outpatient clinic with a 3-month history of a full thickness macular hole in her right eye (Figure 1A). The diameter of the hole was approximately 777  $\mu\text{m}$  (Figure 1A). The visual acuity in the right eye was logMAR 0.7. The fellow eye showed the presence of macular drusen without obvious CNV (Figure 1B). She underwent an uneventful combined pars plana vitrectomy, internal limiting membrane peel with Brilliant Blue G (BBG, concentration 0.025%), C2F6 gas injection and phacoemulsification with posterior intraocular lens implant. There were no intraoperative complications.

At routine post-operative review, the patient developed cystoid macular edema (CME) with the presence of pigment epithelial detachment. She was commenced on topical dexamethasone 0.1% and ketorolac 0.5% eye drops. Six weeks following the commencement of treatment, the CME persisted (Figure 2A) and the patient was listed for dexamethasone implant (Figure 2B). The implant was inserted in December 2016, 4mo after surgery. Despite this, there was no resolution of the CME at subsequent visits. The patient underwent FFA, which demonstrated a predominantly classic sub-foveal CNV (Figure 3A and 3B) and persistent CME on OCT (Figure 3C). The patient received a course of 3 intravitreal injections of ranibizumab 4wk apart (April 2017 to June 2017). She responded poorly to ranibizumab. She then received one intravitreal injection of aflibercept (July 2017), one month after the last ranibizumab injection. Despite the switch to a different anti-VEGF medication, the therapeutic outcome remained poor (Figure 4). There was no visual and anatomical outcome improvement and no further treatment was pursued with final vision of logMAR 1.1.

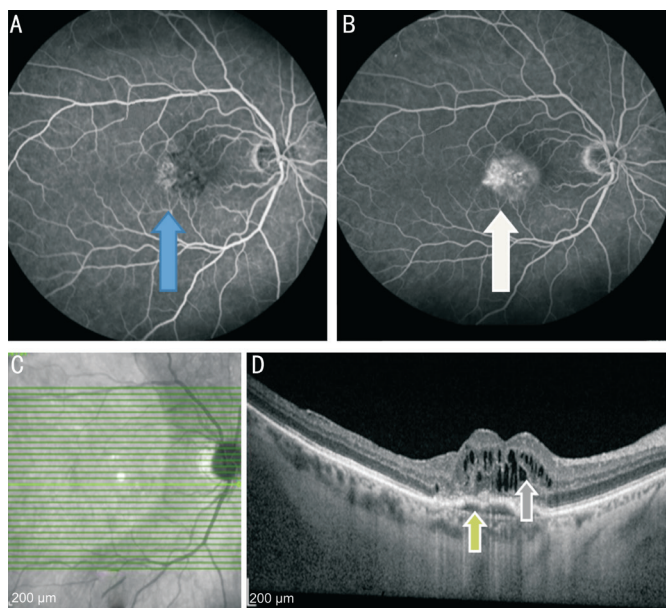
**Case 2** A 74 year-old Caucasian male (P2) was referred to the outpatient clinic with symptomatic epiretinal membrane (ERM) in his right eye (Figure 5A). The visual acuity in both



**Figure 1** P1's OCT scans prior to macular hole surgery A: Right eye full thickness macular hole in P1. The thickness map of the right macula is also attached next to the macular hole image; B: P1's left eye showing deposition of drusen (blue arrows) at the macular area without any obvious evidence of CNV. The thickness map of the left macula is also attached.

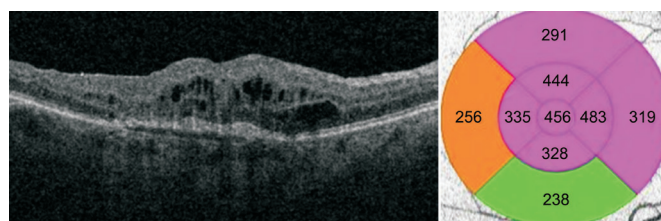


**Figure 2 New onset fluid post macular surgery** A: Right eye OCT post macular surgery in P1. Note the presence of intra-retinal fluid (white arrow) and pigment epithelial detachment (blue arrow). The macular thickness map shows an increase in the central retinal thickness after the macular hole repair; B: OCT after the intravitreal injection of dexamethasone implant showing persistence of CME (white arrow) and pigment epithelial detachment (blue arrow). There was a slight increase in the central retinal thickness as demonstrated by the thickness map.

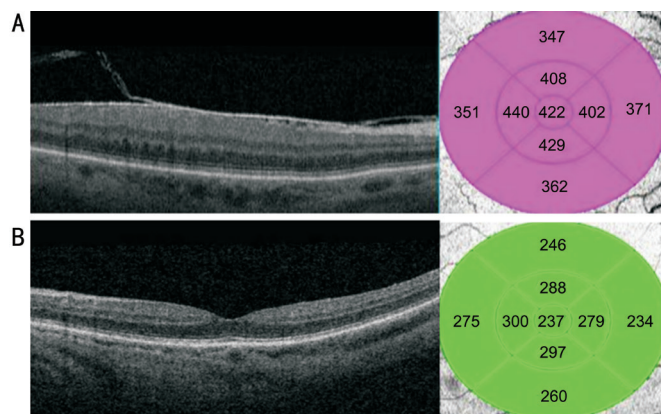


**Figure 3 FFA of P1's right eye** A: Early area of hyperfluorescence in P1's right macula (blue arrow) demonstrating a predominantly classic sub-foveal CNV; B: Area of late staining increasing in size and intensity over time (white arrow); C, D: Persistent intra-retinal fluid on OCT scans in P1 despite treatment with dexamethasone implant (grey arrow) and presence of pigment epithelial detachment indicating the presence of a predominantly classic sub-foveal CNV (green arrow).

eyes at that time was logMAR 0.38. There was no sign of age-related macular degeneration (AMD) in any of the two eyes (Figure 5). The patient was a low myope with pseudophakia and primary open angle glaucoma in both eyes. In addition, he had undergone glaucoma surgery approximately a decade ago and had ceased topical drops for the control of the intraocular



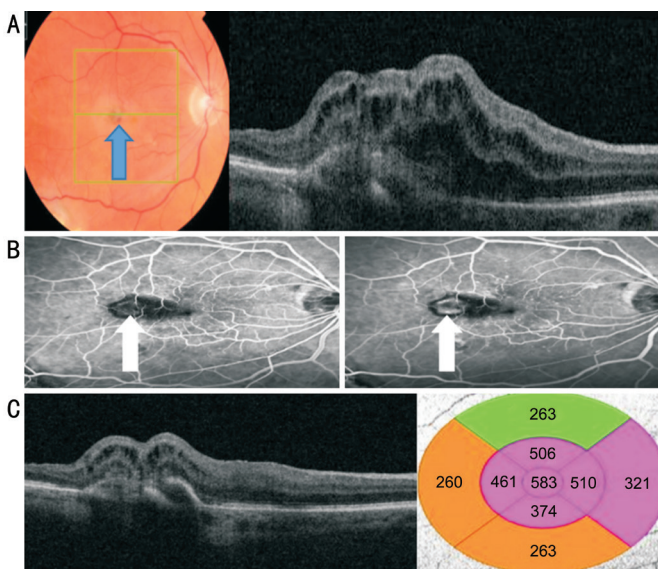
**Figure 4 Final OCT after anti-VEGF treatment** Note the presence of persistent intra-retinal fluid post ranibizumab×3 (April 2017 to June 2017) and aflibercept×1 (July 2017). As there was no response to intravitreal injection of anti-VEGF therapeutic agents, treatment was ceased. The central retinal thickness was persistently high despite treatment.



**Figure 5 P2's OCT scans prior to macular surgery** A: OCT scan from P2's right fundus. ERM noted but no signs of exudative maculopathy. Increased central retinal thickness due to the presence of ERM; B: OCT scan from P2's left fundus also shows no signs of AMD. Normal macular thickness.

pressures. The intraocular pressures pre-operatively were 17 and 16 mm Hg right and left respectively with Goldman applanation tonometry post-dilatation. He underwent an uneventful right pars plana vitrectomy and ERM peel without any intra-operative retinal trauma.

Four months after the macular surgery, the patient developed a well circumscribed sub-foveal CNV confirmed on OCT scan and FFA (Figure 6). The patient was listed for a loading dose of three intravitreal injections of ranibizumab, 4wk apart (May 2017 to July 2017). He did not respond to ranibizumab, and was switched to a year-long aflibercept protocol in September 2017. The first three intravitreal injections of aflibercept were administered 4wk apart (September 2017 to November 2017). The next two intravitreal injections of aflibercept were given 8wk apart (January 2018 and March 2018). His last intravitreal injection of aflibercept was in the end of March this year. To date, he has received 3 intravitreal lucentis and 6 intravitreal aflibercept injections, but there is still evidence of active CNV with significant amount of intra-retinal fluid. The visual acuity in the affected eye has dropped from 0.38 logMAR to 1.10 with persistent blurred vision and distortion. The fellow eye remains stable.

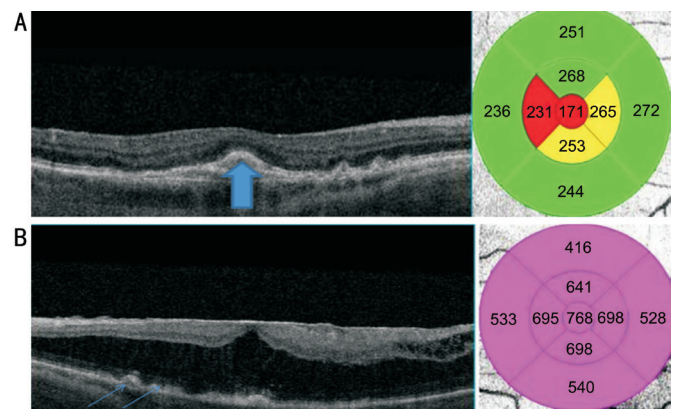


**Figure 6 Multimodal imaging post ERM peel** A: OCT scan of P2's right fundus showing a grey well circumscribed sub-foveal CNV (blue arrow) with presence of sub-retinal and intra-retinal fluid; B: Presence of an active type 2 classic sub-foveal CNV (white arrows); C: Persistence of CNV and fluid despite treatment with anti-VEGF therapeutic agents. The central retinal thickness has increased after the ERM peel.

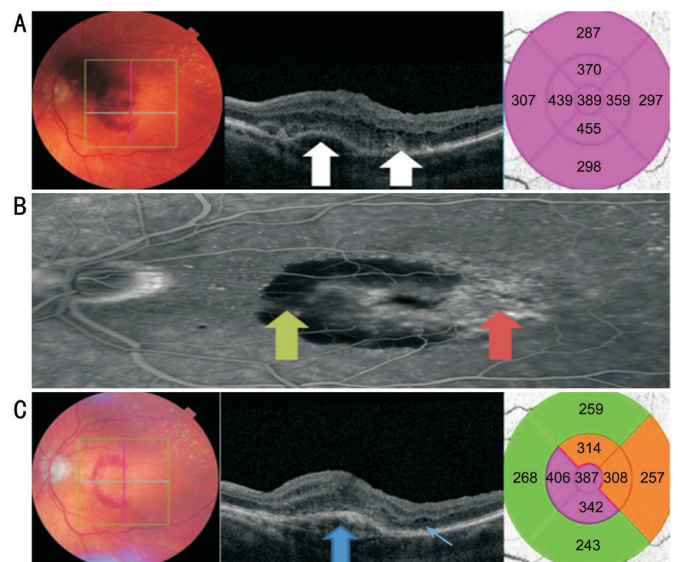
**Case 3** A 76 year-old female Caucasian patient (P3) was referred to the outpatient clinic due to a symptomatic ERM in her left eye causing macular schisis. Of note, she was known to suffer from wet AMD in her fellow eye and she was on a "treat-and-extend" protocol of intravitreal aflibercept injections. At that time, the right wet AMD was inactive (Figure 7A). On her left eye, she was noted to have a very thick ERM causing macular schisis but also drusen, which suggested concomitant presence of dry AMD (Figure 7B). She underwent a left eye combined pars plana vitrectomy, internal limiting membrane peel, phacoemulsification with posterior chamber intraocular lens implant and posterior capsulotomy in December 2017. Membrane blue was used for one minute's staining time. No intraoperative complications including retinal trauma were reported. Her pre-operative visual acuity in the left eye at the time of listing for surgery was logMAR 0.72. Two months after surgery, the patient developed a large new onset macular hemorrhage with a sub-foveal fibrovascular pigment epithelial detachment (Figure 8A). FFA showed extensive masking due to the macular hemorrhage and late staining (Figure 8B). She was commenced on a year-long aflibercept protocol. So far, the patient has received 3 intravitreal injections which have been administered in 4 weekly intervals. Despite treatment, the visual acuity in her last follow-up has reduced to logMAR 0.9 and there is still evidence of an active CNV in her left eye (Figure 8C).

**DISCUSSION**

The incidence of CNV in a wide range of ocular conditions has been well studied and reported. AMD remains most



**Figure 7 P3's OCT scans prior to macular surgery** A: OCT scan of P3's right fundus showing an inactive sub-foveal CNV (thick blue arrow) with presence of foveal atrophy as demonstrated on the thickness map; B: OCT scan of P3's left fundus. Note the presence of a thick ERM causing macular schisis. Also note the presence of drusen (thin blue arrows) suggesting the concomitant presence of dry AMD.



**Figure 8 Multimodal imaging post left eye ERM peel** A: OCT scan of P3's left fundus showing a large macular hemorrhage with a fibrovascular pigment epithelial detachment (white arrows) after ERM peeling; B: Late phase of the FFA of P3's left fundus. Note the presence of masking (green arrow) corresponding with the area of the macular hemorrhage. Also note the presence of late staining (red arrow) suggesting the concomitant presence of dry AMD changes; C: After 3 injections of aflibercept in 4 weekly intervals, the macular hemorrhage has reduced in size, but the fibrovascular pigment epithelial detachment (thick blue arrow) is still present and there are also still tiny pockets of intra-retinal fluid (thin blue arrow).

common cause of CNV worldwide (2.4%-3.2%)<sup>[1-4]</sup>, however other recognized causes include ocular inflammatory disease (2%)<sup>[5]</sup> and degenerative myopic maculopathy (5%-11%)<sup>[6]</sup>. Iatrogenically induced CNV is less common, at 0.1%, with most cases following retinal laser procedures<sup>[7]</sup>. To date, there is no report of the exact incidence of CNV post macular surgery.

All three of our patients developed CNV between two and four months post macular surgery. In the first case, the fellow eye had dry AMD changes but the eye with the macular hole did not. In the second case, no obvious clinical findings of dry or wet AMD were present at all. In the last case, there were dry AMD changes on the operated eye, whereas the fellow eye had inactive wet AMD.

Based on literature search, there have been seven reported cases in literature, where the patients developed CNV after ERM peeling<sup>[8-13]</sup> or post macular hole surgery<sup>[14-19]</sup>. We contribute to the literature by describing three more. The cause for the formation of CNV is yet to be determined. According to Warden *et al*<sup>[10]</sup> and Bae and Woo<sup>[13]</sup>, the most likely pathophysiological mechanism is intra-operative surgical trauma, although none of our patients had extensive outer retinal trauma as confirmed on postoperative OCT. In addition, the same papers suggest that there might be an element of age-related macular changes, which are not clinically evident at the time of surgery<sup>[10,13]</sup>. Surgery, along with the suspected retinal trauma, triggers a cascade of inflammation that leads to angiogenesis in a similar fashion to wet AMD<sup>[12]</sup>. Another potential risk factor is direct trypan blue or indocyanine green dye toxicity to the RPE and neurosensory retina<sup>[15,19]</sup> or direct light toxicity<sup>[20]</sup>. Membrane blue was used in both of our cases for one minute's staining time. In our cases, it is not entirely clear whether the development of CNV can be classified as truly iatrogenic, as all three patients underwent routine surgery with standard operating time and no obvious intraoperative complications (including retinal trauma). Therefore, we postulate that both patients had subclinical age related macular changes that became evident after surgery. Different treatment options have been tried with poor results<sup>[10,12]</sup>, except in one case described by Bae and Woo<sup>[13]</sup>, where the CNV was treated successfully with anti-VEGF injection of aflibercept.

It is further postulated that intraoperative surgical manipulation of the retinal surface alongside pre-existing RPE degeneration exerts significant oxidative stress on the retinal tissues<sup>[12]</sup>. As a result, production of VEGF is hyper-stimulated, leading to CNV formation, and possible resistance to conventional anti-VEGF therapeutic modalities<sup>[12]</sup>. This might account for the poor treatment outcomes of CNV post macular surgery irrespective of the type of surgery<sup>[12]</sup>.

No consensus exists about the treatment of CNV post macular surgery, as this is a very rare complication and a very limited number of cases have been reported so far in the literature. More studies with prolonged follow-up are required in order to elucidate the optimum management of such a rare complication of macular surgery.

These cases highlight the need of awareness of this complication, especially if there is presence of unusual CMO after macular surgery on OCT scans. Despite the fact that CNV post macular

surgery is rare, we suggest that it must be included in the consent process prior to surgery, as patients should be warned about potential guarded visual outcome. Thus, it may be beneficial to consider pre-operative fundus autofluorescence or OCT angiography imaging to exclude early or subclinical AMD disease. This would allow surgeons to better guide patients in the preoperative consultation, and potentially quantify risk of CNV when more data is available.

### ACKNOWLEDGEMENTS

**Conflicts of Interest:** Tsokolas G, None; Clarke B, None; Almuhtaseb H, None; Gupta B, None.

### REFERENCES

- Owen CG, Jarrar Z, Wormald R, Cook DG, Fletcher AE, Rudnicka AR. The estimated prevalence and incidence of late stage age related macular degeneration in the UK. *Br J Ophthalmol* 2012;96(5):752-756.
- Sources for macular degeneration: facts & figures. Available at: <http://www.brightfocus.org/sources-macular-degeneration-facts-figures>. Accessed on 28 Feb 2018.
- Wong WL, Su X, Li X, Cheung CM, Klein R, Cheng CY, Wong TY. Global prevalence of age-related macular degeneration and disease burden projection for 2020 and 2040: a systematic review and meta-analysis. *Lancet Glob Health* 2014;2(2):e106-e116.
- Pascolini D, Mariotti SP. Global estimates of visual impairment: 2010. *Br J Ophthalmol* 2012;96(5):614-618
- Patel AK, Newcomb CW, Liesegang TL, Pujari SS, Suhler EB, Thorne JE, Foster CS, Jabs DA, Levy-Clarke GA, Nussenblatt RB, Rosenbaum JT, Sen HN, Artornsombudh P, Kothari S, Kempen JH; Systemic Immunosuppressive Therapy for Eye Diseases Research Group. Risk of retinal neovascularisation in cases of uveitis. *Ophthalmology* 2016;123(3):646-654.
- Wong TY, Ferreira A, Hughes R, Carter G, Mitchell P. Epidemiology and disease burden of pathologic myopia and myopic choroidal neovascularization: an evidence-based systematic review. *Am J Ophthalmol* 2014;157(1):9-25.
- Lim JI. Iatrogenic choroidal neovascularization. *Surv Ophthalmol* 1999; 44(2):95-111.
- Korobelnik JF, Dureau P, Sarfati A, Chauvaud D, Hoang-Xuan T. Choroidal neovascularization complicating epiretinal membrane removal. *Acta Ophthalmol Scand* 1997;75(3):320-321.
- Graham K, D'Amico DJ. Postoperative complications of epiretinal membrane surgery. *Int Ophthalmol Clin* 2000;40(1):215-223.
- Warden SM, Pachydaki SI, Christoforidis JB, D'Amico DJ, Loewenstein JI. Choroidal neovascularization after epiretinal membrane removal. *Arch Ophthalmol* 2006;124(11):1652-1654.
- Ng EW, Bressler NM, Boyer DS, de Juan E Jr. Iatrogenic choroidal neovascularization occurring in patients undergoing macular surgery. *Retina* 2002;22:711-718.
- Goh YW, Ehrlich R, Welch S. Iatrogenic choroidal neovascularization following idiopathic epiretinal membrane peel. *Digit J Ophthalmol* 2013;19(1):9-12.

- 13 Bae KW, Woo SJ. Choroidal Neovascularization after membrane peeling. *Korean J Ophthalmol* 2015;29(6):439-440.
- 14 Banker AS, Freeman WR, Kim JW, Munguia D, Azen SP. Vision-threatening complications of surgery for full-thickness macular holes. Vitrectomy for Macular Hole Study Group. *Ophthalmology* 1997;104(9):1442-1452.
- 15 Natarajan S, Mehta HB, Mahapatra SK, Sharma S. A rare case of choroidal neovascularization following macular hole surgery. *Graefes Arch Clin Exp Ophthalmol* 2006;244(2):271-273.
- 16 Berinstein DM, Hassan TS, Williams GA, Margherio RR, Ruby AJ, Garretson BR. Surgical repair of full-thickness idiopathic macular holes associated with significant macular drusen. *Ophthalmology* 2000;107(12):2233-2239.
- 17 Tabandeh H, Smiddy WE. Choroidal neovascularization following macular hole surgery. *Retina* 1999;19(5):414-417.
- 18 Tabandeh H, Smiddy WE, Sullivan PM, Monshizadeh R, Rafiei N, Cheng L, Freeman W. Characteristics and outcomes of choroidal neovascularization occurring after macular hole surgery. *Retina* 2004;24(5):714-720.
- 19 Oh HN, Lee JE, Kim HW, Yang JW, Yun IH. Occult choroidal neovascularization after successful macular hole surgery treated with ranibizumab. *Clin Ophthalmol* 2012;6:1287-1291.
- 20 Kelly NE, Wendel RT. Vitreous surgery for idiopathic macular holes: results of a pilot study. *Arch Ophthalmol* 1991;109:654-659.