

Recurrent endophthalmitis caused by intraocular eyelashes

Jia-Wei Wang¹, Xiao-Yang Zhang^{1,2}, Jing Wang¹, Han Zhang¹

¹Eye Center of Shandong University, the Second Hospital of Shandong University, Shandong University, Jinan 250000, Shandong Province, China

²Jinan Aier Eye Hospital, Jinan 250000, Shandong Province, China

Correspondence to: Han Zhang. Eye Center of Shandong University, the Second Hospital of Shandong University, Shandong University, Jinan 250000, Shandong Province, China. han1_zhang@163.com

Received: 2018-08-04 Accepted: 2018-10-11

DOI:10.18240/ijo.2019.02.25

Citation: Wang JW, Zhang XY, Wang J, Zhang H. Recurrent endophthalmitis caused by intraocular eyelashes. *Int J Ophthalmol* 2019;12(2):346-347

Dear Editor,

The presence of intraocular eyelashes following a penetrating injury or surgical intervention is rarely encountered and is usually an incidental finding in clinic^[1-5]. There is significant individual difference in how the eye responds to intraocular eyelashes. These patients can present with acute endophthalmitis^[6] or delayed granulomatous inflammation^[4], or they can be asymptomatic with eyelashes remaining dormant in the eye. This report describes a unique case of intraocular eyelashes that caused recurrent endophthalmitis and were not found by routine examinations but identified during vitrectomy. Corresponding images are included.

A 43-year-old man with a history of ocular trauma was admitted to the hospital with blurred vision in his left eye. One month prior, the patient had presented to a local hospital following an ocular injury at work from a high-velocity iron projectile. Anterior segment evaluation revealed superior conjunctival laceration around 12 o'clock, and there was no evidence of a breach in the cornea, sclera, iris, or anterior lens capsule. X-ray, brightness scan (B-scan), and computed tomography (CT) scan were negative for intraocular foreign bodies. The patient received vancomycin injections on three occasions for recurrent intravitreal purulent inflammation during hospitalization. Intraocular inflammation recurred approximately one week after each intravitreal injection of vancomycin.

Two days after the third intravitreal vancomycin injection, the patient was referred to our hospital complaining of slight pain and severe vision loss. Right eye examination was unremarkable. His visual acuity was 1.0 in the right eye and 0.2 in the left eye with no improvement on manifest refraction, and intraocular pressure was 14 mm Hg and 15 mm Hg, respectively. Slit-lamp examination showed a quiet anterior chamber and incipient posterior subcapsular cataract of the left eye, and gonioscopy revealed a wide opening angle structure and no foreign bodies. On fundus examination, no obvious clinical signs or symptoms of endophthalmitis were detected. There was no vitreous hemorrhage or retinal detachment, but moderately dense vitreous opacities were detected, mostly in the superior quadrant. Considering the recurrent endophthalmitis is after eye injury, we believed the presence of intraocular foreign bodies in the left eye was unlikely. Therefore, we suggested a 25-gauge pars plana vitrectomy. Intraoperatively, three foreign bodies were found embedded in the pars plana around 12 o'clock (Figure 1A). The foreign bodies were identified along with eyelashes (Figure 1B, 1C). The patient was followed up for three months postoperatively and retained excellent vision (1.0) without recurrence of endophthalmitis.

Intraocular eyelashes are uncommon. Eyelashes can enter the eye as a result of ophthalmic surgery or a penetrating injury. Intraocular eyelashes following penetrating injury are extremely rare, constituting only 0.4% of all intraocular foreign bodies^[5]. Eyelashes can be discovered in the anterior chamber^[4,7], posterior chamber^[5], lens^[5], vitreous^[8], or retina^[1]. However, intraocular eyelashes embedded in the pars plana have not yet been reported. The study adhered to the provisions of the Declaration of Helsinki for research involving human subjects and was approved by the Ethical Review Committee of the Second Hospital of Shandong University. The patient had signed a consent form after a detailed explanation of the purpose of the study.

The eye's response to eyelashes can be varied and unpredictable. Intraocular eyelashes can be tolerated in the anterior chamber for as long as 50y without causing any ocular reaction^[7]. However, they can also result in corneal endothelium cell deficiency^[2], iris cyst^[4], granulomatous disease^[5], retinal detachment^[1], and severe intraocular inflammation^[5-6]. Therefore, the decision to remove intraocular eyelashes is controversial. For our patient, intraocular eyelashes caused

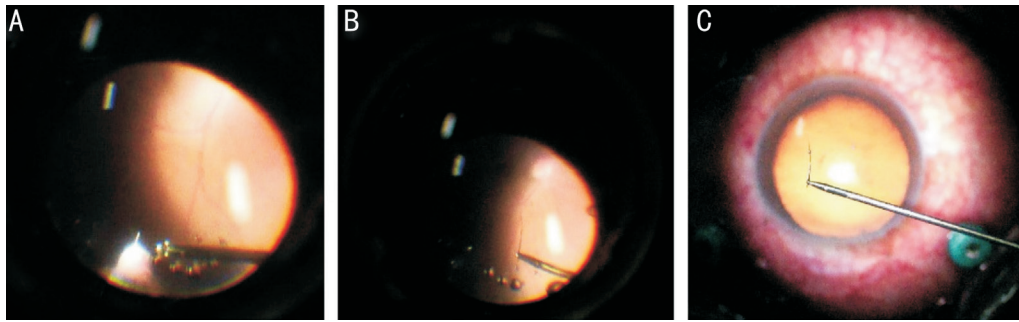


Figure 1 Foreign bodies embedded in the pars plaua (A) and the foreign bodies were identified as eyelashes (B, C).

recurrent endophthalmitis, which is different from other reports. Diagnosing the intraocular eyelashes was difficult because the CT scan, B-scan, and X-ray did not detect foreign bodies.

To our knowledge, this is the first reported case of intraocular eyelashes embedded in the pars plana associated with recurrent endophthalmitis. This rare case is a reminder that intraocular foreign bodies in the pars plana should be considered, even when routine examinations are negative for intraocular foreign bodies, and especially for patients with acute or chronic intraocular inflammation. As surgery advances, it becomes necessary to obtain visualization using vitrectomy and remove inciting agents to prevent intraocular inflammation.

ACKNOWLEDGEMENTS

Foundations: Supported by the National Natural Science Foundation of China (No.81700831); Natural Science Foundation of Shandong Province, China (No. ZR2017BH049).

Conflicts of Interest: Wang JW, None; Zhang XY, None; Wang J, None; Zhang H, None.

REFERENCES

- 1 Teo L, Chuah KL, Teo CH, Teoh SC. Intraocular cilia in retinal detachment. *Ann Acad Med Singap* 2011;40(10):477-479.
- 2 Liu W, Ji J, Liu H, Wei RH, Zhao SZ. Intraocular cilium causing corneal endothelium cell deficiency. *Can J Ophthalmol* 2013;48(2):e28-e29.
- 3 Bach A, Gold AS, Villegas VM, Wildner AC, Murray TG. Intraocular eyelash. *J Am Osteopath Assoc* 2015;115(2):115.
- 4 Sahu SB, Puri LR, Singh SK. Intraocular eyelashes and iris cyst in anterior chamber following penetrating eye injury: a case report. *Int Med Case Rep J* 2017;10:105-107.
- 5 Gopal L, Banker AS, Sharma T, Parikh S, Bhende PS, Chopra S. Intraocular cilia associated with perforating injury. *Indian J Ophthalmol* 2000;48(1):33-36.
- 6 Galloway GD, Ang GS, Shenoy R, Beigi B. Retained anterior chamber cilium causing endophthalmitis after phacoemulsification. *J Cataract Refract Surg* 2004;30(2):521-522.
- 7 Yalniz-Akkaya Z. Post-traumatic cilia remaining inert in the anterior chamber for 50 years: a case report. *J Med Case Rep* 2011;5:527.
- 8 Eckert S, Spraul CW. A rare intraocular foreign body after perforating injury. *Ophthalmologe* 2005;102(4):393-395.