

# Ab interno evisceration

Suppamong Tirakunwichcha<sup>1</sup>, Pear Pongsacharoennont<sup>2</sup>

<sup>1</sup>Oculoplastic Unit, Department of Ophthalmology, Faculty of Medicine, Chulalongkorn University and King Chulalongkorn Memorial Hospital, Thai Red Cross Society, Patumwan, Bangkok 10330, Thailand

<sup>2</sup>Vitreoretinal Research Unit, Department of Ophthalmology, Faculty of Medicine, Chulalongkorn University and King Chulalongkorn Memorial Hospital, Thai Red Cross Society, Patumwan, Bangkok 10330, Thailand

**Correspondence to:** Suppamong Tirakunwichcha. Department of Ophthalmology, Faculty of Medicine, Chulalongkorn University and King Chulalongkorn Memorial Hospital, Thai Red Cross Society, 1873 Rama IV Road, Patumwan, Bangkok 10330, Thailand. [suppamong@gmail.com](mailto:suppamong@gmail.com)

Received: 2018-06-21 Accepted: 2018-08-30

**DOI:10.18240/ijo.2019.03.28**

**Citation:** Tirakunwichcha S, Pongsacharoennont P. Ab interno evisceration. *Int J Ophthalmol* 2019;12(3):526-528

## Dear Editor,

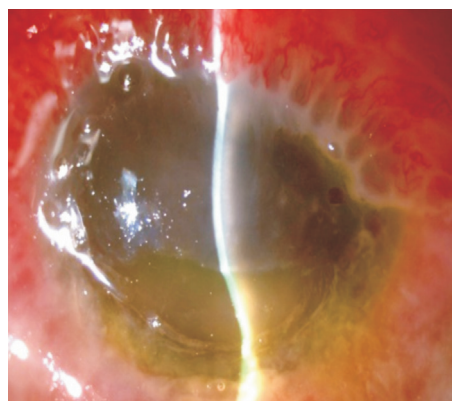
We intended to present a new concept of pars plana evisceration, doing an evisceration *via* pars plana, and avoid complications of standard evisceration such as exposure, extrusion, migration, and to maximize ocular motility.

Many innovative surgical techniques have been developed to address the problems including four-petal evisceration<sup>[1-2]</sup>, posterior sclerotomies<sup>[3]</sup>, two scleral flap evisceration<sup>[4]</sup>, and myoconjunctival attachment<sup>[5]</sup>. Both porous and non-porous implants can cause long-term complications<sup>[6-7]</sup>, but it remains unclear which is superior<sup>[8-9]</sup>. However, prosthesis motility is limited, and complete natural-looking, balanced motility has not been achieved.

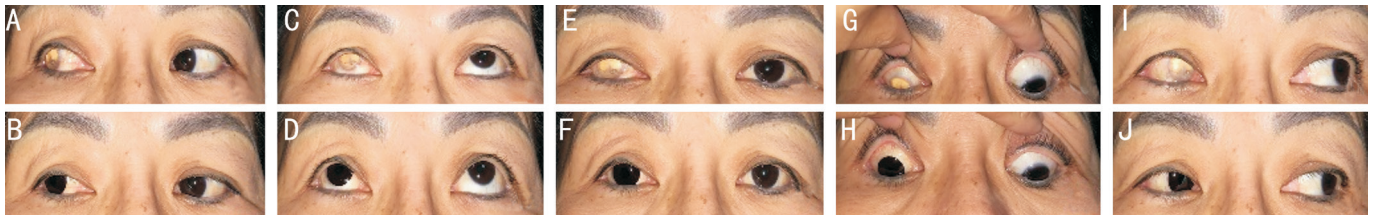
This study was approved by the Institutional Review Board of Faculty of Medicine, Chulalongkorn University, and adhered to the tenets of the Declaration of Helsinki. A female patient, aged 53y, presented with acute ocular pain, fever, and visual loss lasting 5d. She was firstly diagnosed as having diabetes mellitus (DM), and septicemia on admission. Ocular examination revealed visual acuity (VA) of hand motion, poor perception of light projection OD, 20/25-2 OS. Right eye demonstrated swollen, erythematous eyelid with tender, chemosis with yellowish discharge, corneal edema, fibrinoid reaction, and hypopyon in the anterior chamber (Figure 1).

Ultrasonography illustrated vitreous opacity and thicker retinochoroidal layer. Preoperative axial length (AL) was recorded. The proptosis value by Hertel exophthalmometry was 21 mm OD, 18 mm OS (base 110), congruent with the orbital CT scan. Panophthalmitis was diagnosed. Despite empirical intravenous and intraocular antibiotic treatment, infection progressed and the eye was no light perception. The information of surgery was given, ethical clearance and consent was obtained for the experimental surgical procedure. Instead of conventional enucleation, an ab interno evisceration was agreed upon.

The procedure was performed under general anesthesia. Standard 23G 3-port pars plana vitrectomy was performed with cannulas inserted 3 mm from the limbus, using a wide-field non-contact surgery viewing system. Pus in vitreous cavity and necrosed retina was found. A vitrectomy cut rate of 2500 cuts/min, and 400 mm Hg vacuum were used for pus removal. Subtotal vitrectomy was performed with 25 mm Hg infusion pressure; pressure was increased to 60 mm Hg for total retinectomy and maintained during diathermy. Starting with 360 degrees peripheral retinectomy, and outside in fashion was performed until reaching the optic nerve. Choroidectomy was done in the same fashioned. Scleral indentation was made 360 degrees to visualize the remained anterior retina and choroidal tissue. Vitrectomy probe with cutter was inserted until scleral touching at the edge of remnant tissue, then moved in the anterior direction for tissue removal until reaching the corneal limbus. After the choroid, uveal tissue, and lens were removed, electrocauterization at the optic nerve head, accompanied with 10min, 60 mm Hg pressure hemostasis was performed. The hemorrhage was not as extensive as expected, and can



**Figure 1** Pre-operative slit lamp picture of the right eye showed severe endophthalmitis.



**Figure 2** Pictures demonstrated the postoperative eye movement at 1-year follow-up period A, C, E, G, I showed right eye without tinted contact lens. B, D, F, H and J showed right eye with tinted contact lens.

certainly be controlled with the technique described. Following fluid-air exchange, 90% alcohol was injected through a port to denature the residual uveal tissue for 3min; this was followed by fluid-alcohol exchange. The scleral shell and cornea were intact, and not melted. The eyeball was filled with 5 mL of 1300 centistokes-silicone oil (SO) until it spilled over the port. Sclerostomy ports were sutured with 8/0 polyglycolic acid and dexamethasone was injected subconjunctivally.

Ultrasound biometry and imaging with B scan mode were used to determine AL at 1wk, 1, 3, 6mo, and sequential follow-up visit. The ultrasound velocity in the vitreous was changed from 1532 m/s to 940 m/s due to the SO properties. AL was measured (in mm) in the vertical axis from cornea to scleral layer. The preoperative AL was 20.50 mm OD. There were SO droplets in the subconjunctival space with intact corneal sensation on postoperative day 1.

At 1-week postoperative, AL was 20.08 mm, full extraocular movements (EOM) OU, and the margin reflex distance-1 (MRD1) was -2 mm OD, 3 mm OS. Levator function (LF) was 13 mm OD, 15 mm OS. Hertel measurement was 18 mm OU.

At 1-month postoperative, there was no ocular pain or discomfort, normal intraocular pressure (IOP), mild corneal haze with early neovascularization, intact corneal sensation, and a minimally congested conjunctiva with SO droplets. AL was 22.40 mm, and the proptosis value was 15 mm OD, 18 mm OS.

The AL was 18.08 mm at 3-month and 18.39 mm at 6-month postoperative with a proptosis value of 15 mm OD, 18 mm OS at 6-month. At 20-month postop, AL was 18.30 mm with a proptosis value of 13 mm OD, 18 mm OS, without any symptoms. At 32-month postop, AL was 16.90 mm with a proptosis value of 12 mm OD, 18 mm OS, others were unremarkable (Table 1). The patient was very satisfied. There was no sign of orbital discomfort, pain, proptosis or congested conjunctiva that indicated orbital inflammation from SO leakage. Band keratopathy was observed at postoperative 20-month visit, and was not bothersome to the patient.

With evisceration, attaining perfect prosthesis movement with balanced natural-looking motility remains an incompletely achieved goal. In the surgical technique proposed here, we removed all the intraocular contents ab interno, and completely filled the cavity with SO. This technique imitates pars plana

**Table 1** Comparison of axial length and proptosis values pre- and postoperative period mm

Time point	Axial length	Proptosis value by Hertel measurement	
		Right	Left
Preoperative	20.50	21	18
1wk postoperative	20.08	18	18
1mo postoperative	22.40	15	18
3mo postoperative	18.08	-	-
6mo postoperative	18.39	15	18
20mo postoperative	18.30	13	18
32mo postoperative	16.90	12	18

vitrectomy (PPV) with SO tamponade, which has been widely used in vitreoretinal surgery since the 1900s. Despite SO-related complications, it is used to prevent globe collapse, and proliferation of the intraocular membrane in severely complicated cases, as well as in surgical failure following vitrectomy<sup>[10]</sup>. Our case showed about 2.2 mm AL reduction between 3-20mo, and approximate 3.6 mm reduction at nearly 3y postoperative. This indicated eyeball shrinkage from natural healing process, and even reduced SO viscosity. Postoperative 22.40 mm-axial length at 1-month period was irrelevant to others should be measurement error. The proptosis value reduction after 1mo was in accordance with both eyeball shrinkage and enophthalmos regarding severe orbital infection. Even a majority of infective eyes have a corneal abnormality, and the scope of this approach is limited. In clear cornea, the technique still has the advantages of natural-looking eyeball motility, corneal curvature, and involves no complications from implant exposure/extrusion/migration, or fornix contracture (Figure 2). The intraorbital tissue has never been disturbed, and normal eyeball volume could be sustained with substitution materials. Some surgeons may concern about reduction of eyeball size more cosmetically than ocular/prosthesis motility, but in authors' viewpoint the ocular/prosthesis motility is more important since our ethnic's sunken orbits do not matter a little different in eyeball size. Indeed, the technique is similar to cornea-sparing evisceration, but without ocular implant can avoid associated complications. Cornea opacification is guaranteed, but can be addressed by tinted contact lenses or tattooing. If ptosis occurs with enophthalmos, volume

augmentation and ptosis correction can be performed. The technique can be moreover clinically applied in the condition of intraoperative inoperable vitrectomy, and maintained the natural ocular volume instead of doing standard enucleation or evisceration. However, the volume might slightly decrease as time elapses due to inability of full volume replacement by SO.

The technique has the same indications as standard evisceration. Panophthalmitis was treated on the concept of a consecutive orbital cellulitis from underlying endophthalmitis. Routine empirical antibiotics both intravenous and intraocular routes were firstly administered, followed by PPV. If the condition worsened, annihilation surgery cannot be avoided. With ab interno evisceration, there is equal surgical risks compared to the conventional technique, but more benefits gained. However, it cannot be performed in cases with severe corneal ulcer which obscured visualization. Because of volume decrement, more viscous 5500 centistokes-SO was conjectured to maintain the intraocular volume against contracture. Long-term scleral thinning, permanent chemical tamponade effect of SO, and SO-induced chronic orbital inflammation still needs to be observed in long term period. The procedure can be further improved, if an insoluble, bio-integrated supplant materials are available, and immediately replaced intraoperatively. Zheng *et al*<sup>[11]</sup> just reported in 2018 using injectable silicone rubber into the socket cavity in eviscerated animal model *via* paralimbal incision successfully. However, exploration of the safety data for intraocular usage is remained. Nevertheless, this ab interno technique is a viable alternative to standard evisceration, as well as in management of intraoperative inoperable retinal detachment for long-term cosmetic outcome, and avoids the innate complications.

#### **ACKNOWLEDGEMENTS**

Both authors' contributions to the work are equal. All authors attest that they meet the current ICMJE criteria for authorship. We would like to thank Editage (www.editage.com) for English language editing.

**Conflicts of Interest:** Tirakunwichcha S, None; Pongsacharoennont P, None.

#### **REFERENCES**

- 1 Sales-Sanz M, Sanz-Lopez A. Four-petal evisceration: a new technique. *Ophthalmic Plast Reconstr Surg* 2007;23(5):389-392.
- 2 Huang DP, Yu YY, Lu R, Yang HS, Cai JH. A modified evisceration technique with scleral quadrisection and porous polyethylene implantation. *Am J Ophthalmol* 2009;147(5):924-928.e1-3.
- 3 Kostick DA, Linberg JV. Evisceration with hydroxyapatite implant. Surgical technique and review of 31 case reports. *Ophthalmology* 1995;102(10):1542-1548; discussion 1548-1549.
- 4 Smith RJ, Prazeres S, Fauquier S, Malet T. Complications of two scleral flaps evisceration technique: analysis of 201 procedures. *Ophthalmic Plast Reconstr Surg* 2011;27(4):227-231.
- 5 Yadava U, Sachdeva P, Arora V. Myoconjunctival enucleation for enhanced implant motility. result of a randomised prospective study. *Indian J Ophthalmol* 2004;52(3):221-226.
- 6 Jung SK, Cho WK, Paik JS, Yang SW. Long-term surgical outcomes of porous polyethylene orbital implants: a review of 314 cases. *Br J Ophthalmol* 2012;96(4):494-498.
- 7 Lin CW, Liao SL. Long-term complications of different porous orbital implants: a 21-year review. *Br J Ophthalmol* 2017;101(5):681-685.
- 8 Schellini S, Jorge E, Sousa R, Burroughs J, El-Dib R. Porous and nonporous orbital implants for treating the anophthalmic socket: a meta-analysis of case series studies. *Orbit* 2016;35(2):78-86.
- 9 Schellini S, El Dib R, Silva LR, Farat JG, Zhang YQ, Jorge EC. Integrated versus non-integrated orbital implants for treating anophthalmic sockets. *Cochrane Database Syst Rev* 2016;11:CD010293.
- 10 Shen YD, Yang CM. Extended silicone oil tamponade in primary vitrectomy for complex retinal detachment in proliferative diabetic retinopathy: a long-term follow-up study. *Eur J Ophthalmol* 2007;17(6):954-960.
- 11 Zheng PF, You QS, Li Q, Deng HY, Wong IYH, Peng XY. Injectable silicone rubber for ocular implantation after evisceration. *PLoS One* 2018;13(3):e0193448.