

Increased intracranial pressure and macular thickening: is there a link?

Hamid Sajjadi^{1,2}, Hossein Poorsalman³, Mohammad-Ali Abtahi²

¹San Jose Eye and Laser Medical Center, Cupertino 95104, California, USA

²Department of Ophthalmology, Acacia Medical Center, Dubai 72298, UAE

³Department of Ophthalmology, Iranian Red Crescent hospital, Dubai 02330, UAE

Correspondence to: Hamid Sajjadi. Acacia Medical Centre, Suite 111, Al Shafar Bldg. 7, Al Wasl Rd. P.O Box: 72298, Dubai, UAE. hsajjadi@yahoo.com

Received: 2018-10-21 Accepted: 2019-01-02

DOI:10.18240/ijo.2019.06.29

Citation: Sajjadi H, Poorsalman H, Abtahi MA. Increased intracranial pressure and macular thickening: is there a link? *Int J Ophthalmol* 2019;12(6):1052-1055

Dear Editor,

I am Dr. Hamid Sajjadi, director of Neuro-Ophthalmology at San Jose Eye and Laser Medical Center in California USA and director of Department of Ophthalmology, Acacia Medical Center, Dubai, UAE. I write to present three cases of macular thickening (MT) and micro-papilledema associated with increased intracranial pressure (IICP).

Since retina is known as the anterior visible extension of the central nervous system, there is growing evidence that several brain disorders affect this complex tissue. In this regard, one of the best devices to detect early changes of central nervous system disorders is retinal and optic nerve head (ONH) optical coherence tomography (OCT)^[1].

The hallmark of IICP is the changes in the optic nerve that is called papilledema^[2]. However in almost all these cases there were no overt papilledema. Several authors have tried to not only grade the papilledema^[3] but also to describe other associated fundusoscopic signs of IICP^[4-5] [e.g. choroidal folds, macular star, macular hemorrhage and overt macular edema (ME)]. Because of anatomic variations in ONH, papilledema grading may not always have direct relation with the level of IICP^[6]. Hence, changes of the optic nerve may be asymmetric^[7] and even subtle^[8]. Recently, in a report we described a large series of spinal tap (ST) proven IICP cases without overt papilledema detected by ONH OCT^[9].

There are several causes associated with decreased vision in IICP^[10], among which MT/ME can be addressed^[5]. ME related to IICP may also be either overt (44% in overt papilledema in a report)^[6] or subtle^[11]. Subclinical macular changes (only detected by macular OCT) were first described as the cause of decreased vision in 7 out of 54 cases of papilledema in one report^[10].

We present 3 patients with decreased vision or other neurologic signs (headache, dizziness) that were referred to us. First, we should mention that we followed principles outlined in Declaration of Helsinki. Written informed consent was taken from all subjects after explaining the study. The first 2 cases are young female Caucasians and had a history of headache. The third one is older and African male. All 3 patients were referred with loss of best corrected visual acuity (BCVA) and 2 of them were obese [body mass index (BMI) more than 30]. Past medical history was negative in regard to causes of MT/ME (diabetes, hypertension, drugs, *etc.*). Macular and ONH OCT was performed, as a result MT along with ONH nerve fiber layer thickening suspicious to IICP (as we described in our previous article) was detected^[9]. Case 2 had a highly asymmetric ONH and 1+ relative afferent pupillary defect (RAPD) in right eye. Case 3 had a history of refractory ME labeled to be as a result of cataract surgery in both eyes 20 months ago. He had no improvement of vision despite months of topical dexamethasone and non-steroidal anti-inflammatory drugs and scheduled for intravitreal Ozurdex. Since all 3 patients had normal brain magnetic resonance imaging (MRI), we referred our patients to a neurologist and he did ST in lateral decubitus position. As a result, all 3 patients showed IICP, were diagnosed to have idiopathic intracranial hypertension (IIH) and were treated with oral acetazolamide (ACZ). After follow-up period (more than 1y in 2 first cases and about 6mo in case 3) they showed dramatic improvement in BCVA along with decrease in OCT thickness profiles both in macula and ONH. Along with improvement in ONH appearance in case 2 after only 3mo of treatment with ACZ, RAPD changed to negative. There are reports of RAPD in IIH patients with unequal pressure on optic nerves from IICP. This may be related to the size of optic nerve canal or anatomy of optic nerve at lamina cribrosa^[12]. Findings and treatment results are summarized in Table 1 and Figures 1-3.

Table 1 Summary of examinations and follow-up of 3 cases

Parameters	Case 1	Case 2	Case 3
Demographics	18-year-old Caucasian female	24-year-old Caucasian female	57-year-old African male
Presentation	Blurry vision and dizziness since 1 year ago	Decrease vision in right eye and severe headache	Blurry vision since 2 years ago; no DM, no HTN, no headaches
Past history	Severe headaches diagnosed as Migraine, since 4 years ago	Severe headache since 5 years ago	Uncomplicated cataract surgery 20mo before: no vision improvement
Ocular exam (presentation)	BCVA: 20/25 (she was insisting it was not as clear as it used to be); normal anterior segment; PCIOP: 20 mm Hg	BCVA 20/200 OD and 20/25 OS; normal anterior segment; PCIOP: 17 mm Hg OU; fundus: normal except papilledema-like optic nerve head in right eye and flat in left eye	BCVA: 20/200 OU; 2+ PCO OD & 1+ OS; PCIOP: 30 mm Hg; fundus exam: OD: congested ONH, 0.3 cupping, OS: 0.7 cupping, no foveal reflex
Other examinations	ONH OCT: Pattern 1: that raised suspicion to IICP; macular OCT: central foveal sparing MT with normal structure; BMI:37.5; normal MRI; ST: 400 mm H ₂ O	ONH OCT: overt papilledema OD, pattern 2 OS; macular OCT: MT in right eye more than in left eye with normal structure and central foveal sparing; BMI:24; normal brain MRI; ST: 310 mm H ₂ O	ONH OCT: overt IICP pattern OD and Pattern 1 specific to IICP OS; macular OCT: MT OU, the fluid pattern was pointing toward optic nerve with more prominence in temporal macula; BMI:31; normal brain MRI; ST: 270 mm H ₂ O
Treatment	Oral ACZ (1 gram daily)	Oral ACZ (1 gram daily)	At presentation: Cosopt <i>b. i. d.</i> , Alphagan-P 0.1% <i>b. i. d.</i> and Xalatan in OU; Then ACZ was started (1 g daily) and the Cosopt and Xalatan were discontinued.
Follow-up, final exam	15mo F/U: BCVA improved :20/20 (patient stating that her previous sharp vision had returned); ONH and macular OCT showed thickness improvement; headaches totally improved; loss of 9 kg in 15mo	1.5y F/U: BCVA improved :20/25 OU; resolution of micro-papilledema and MT	6mo F/U: CMT improved dramatically, from 324 and 278 μ m to 278 and 212 μ m respectively

ONH: Optic nerve head; OCT: Optical coherence tomography; IICP: Increased intracranial pressure; ST: Spinal tap; MT: Macular thickening; ME: Macular edema; BCVA: Best corrected visual acuity; IOP: Intraocular pressure; BMI: Body mass index; MRI: Magnetic resonance imaging; ACZ: Acetazolamide; IIH: Idiopathic intracranial hypertension; RAPD: Relative afferent pupillary defect; CME: Cystoid macular edema; PCIOP: Pachymetry corrected intraocular pressure; CMT: Central macular thickness; PCO: Posterior capsule opacification; IV: Intravitreal; OD: Right eye; OS: Left eye; OU: Both eyes; NSAID: non-steroidal anti-inflammatory drugs; F/U: Follow-up; DM: Diabetes mellitus; HTN: Hypertension.

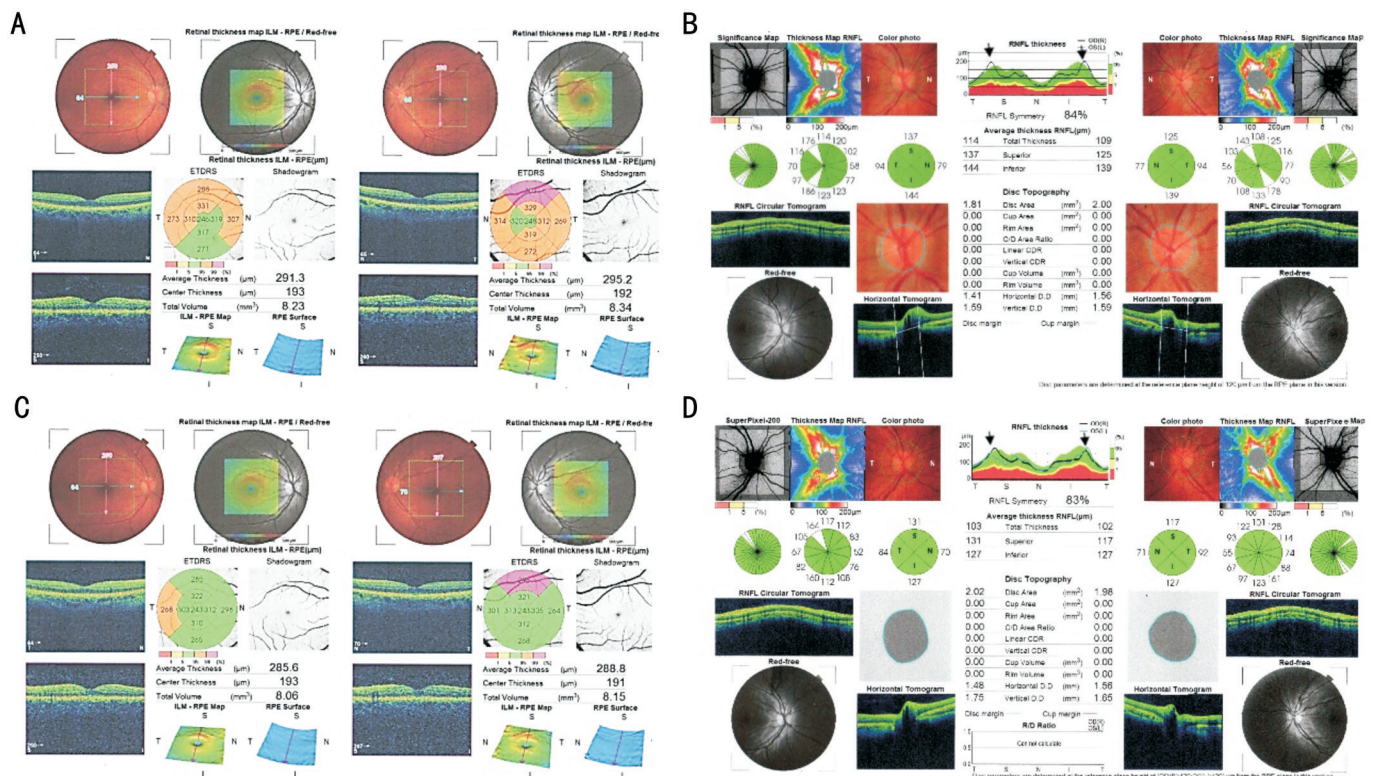


Figure 1 Case 1 A: Macula before treatment April 2016 showing foveal sparing thickening (orange and pink in average thickness profile); B: Optic nerves before treatment (elevation in nerve fiber layer is indicated by black arrow); C: Macula after 15mo of treatment showing decreased thickness (green thickness profile in most parts); D: Optic nerves 15mo after treatment with Acetazolamide showing less papilledema and sharper optic nerve heads (indicated by black arrows).

Although an overt papilledema may indicate IICP, the severity of papilledema may not have a direct relationship with the level of ICP^[6]. This notion relies on of variations in width of CSF space surrounding the optic nerve as a rout of communication between the optic canal and the intracranial space^[11]. There

are several reports regarding IICP without papilledema in adults^[8] and children^[2]. We have recently reported 171 cases of IICP-suspects diagnosed by OCT before imaging and or ST. Study consisted of 3 tumors and 148 IIH cases diagnosed by OCT; 144 without overt papilledema^[9]. We defined 4 patterns

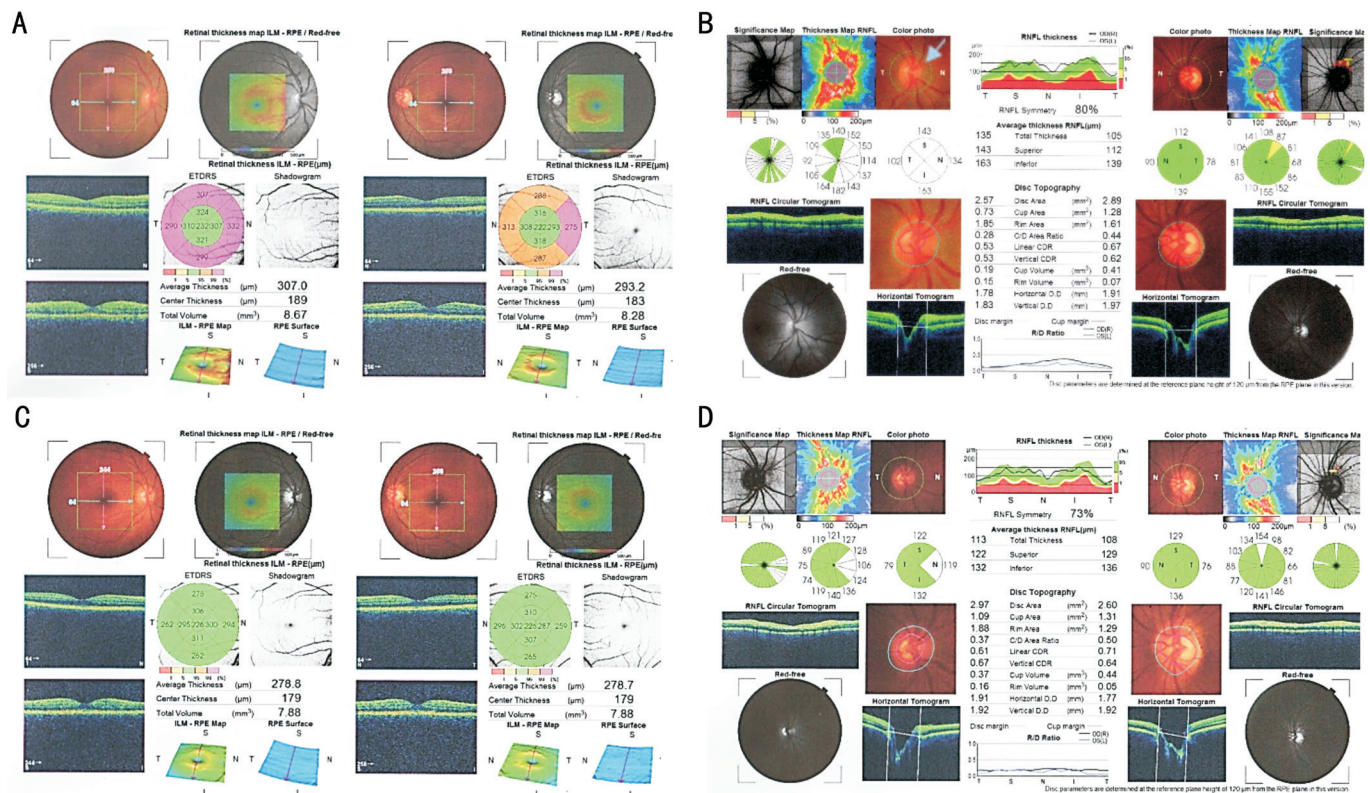


Figure 2 Case 2 A: Macula before treatment February 2014, central foveal sparing thickening is seen OU (pink and orange colors in thickness profile); B: Optic nerve before treatment (overt papilledema in right eye: blue arrow); C: Macula 30mo after starting Acetazolamide (resolution of macular thickening in both eyes); D: Optic nerves 30mo after treatment showing less papilledema and sharper optic nerve head. Increased cupping is secondary to decreased CSF in optic nerve head.

of micro-papilledema, among which the most specific type was pattern 1 (raised temporal and depressed nasal wings of the ONH). We suggested that IICP could be detected in the absence of overt papilledema with the help of OCT device. Macular changes have been reported to be associated with elevated intracranial pressure and papilledema^[4-5]. To our knowledge, the first paper that evaluated MT/ME in association with papilledema with the aid of first generation OCT^[10], mentioned that the cases did not show overt ME but decreased vision. Therefore, they performed OCT for evaluation of macula. The authors believed that decreased vision that may be present in some patients with papilledema and IICP can be attributed to subclinical macular changes. Another common point between our and this case report was rapid resolution of MT/ME in response to oral ACZ^[10]. This is completely in agreement with a recent cohort in which measured average total peri-papillary retinal thickness, ONH volume and the ganglion cell plus inner plexiform layer thickness (macula) by OCT in patients with overt papilledema and IICP. Results were dramatically lower in ACZ therapy group compared to placebo in 6mo follow-up^[6]. There is another common interesting point that all 3 cases share a common pattern of thickening, which is more prominent in peripapillary region and spares the central foveal region. Despite this doughnut shaped pattern that spares central fovea, all three patients had decreased BCVA. In this

regard we think that thickening of retinal layers mainly sparing central fovea in association of decreased vision or headache may be considered one of the harbingers of IICP. There is a theory about origin of this MT/ME. In one report, authors suggested that the origin of this fluid may originate from cerebrospinal fluid (CSF)^[10]. We are proposing that because of the high ICP flow of the CSF is slowed down and therefore axonal flow in the optic nerve neurons are slowed and thus cause a thickening of the perimacular retina where it is the richest in ganglion cell layers. In this regard, we could name this type of MT/ME as CSFME. This highlights the need for further studies to evaluate subtle changes associated with IICP. The OCT of macula alone can be a sign of increased ICP in early cases and it will show thinning in advanced cases or after treatment. This is a substantial new finding that may indicate the future of early neurological diagnosis may be in the macular OCT of the eyes.

ACKNOWLEDGEMENTS
 We should thank Dr. Habib Dezhagahah by his contribution in adding some new concepts to the manuscript.

Authors' contributions: Sajjadi H and Poorsalman H visited the patients and did the follow-up of the patients. Abtahi MA and Sajjadi H had a major contribution in writing the manuscript. All authors read and approved the final manuscript.

Conflicts of Interest: Sajjadi H, None; Poorsalman H, None; Abtahi MA, None.

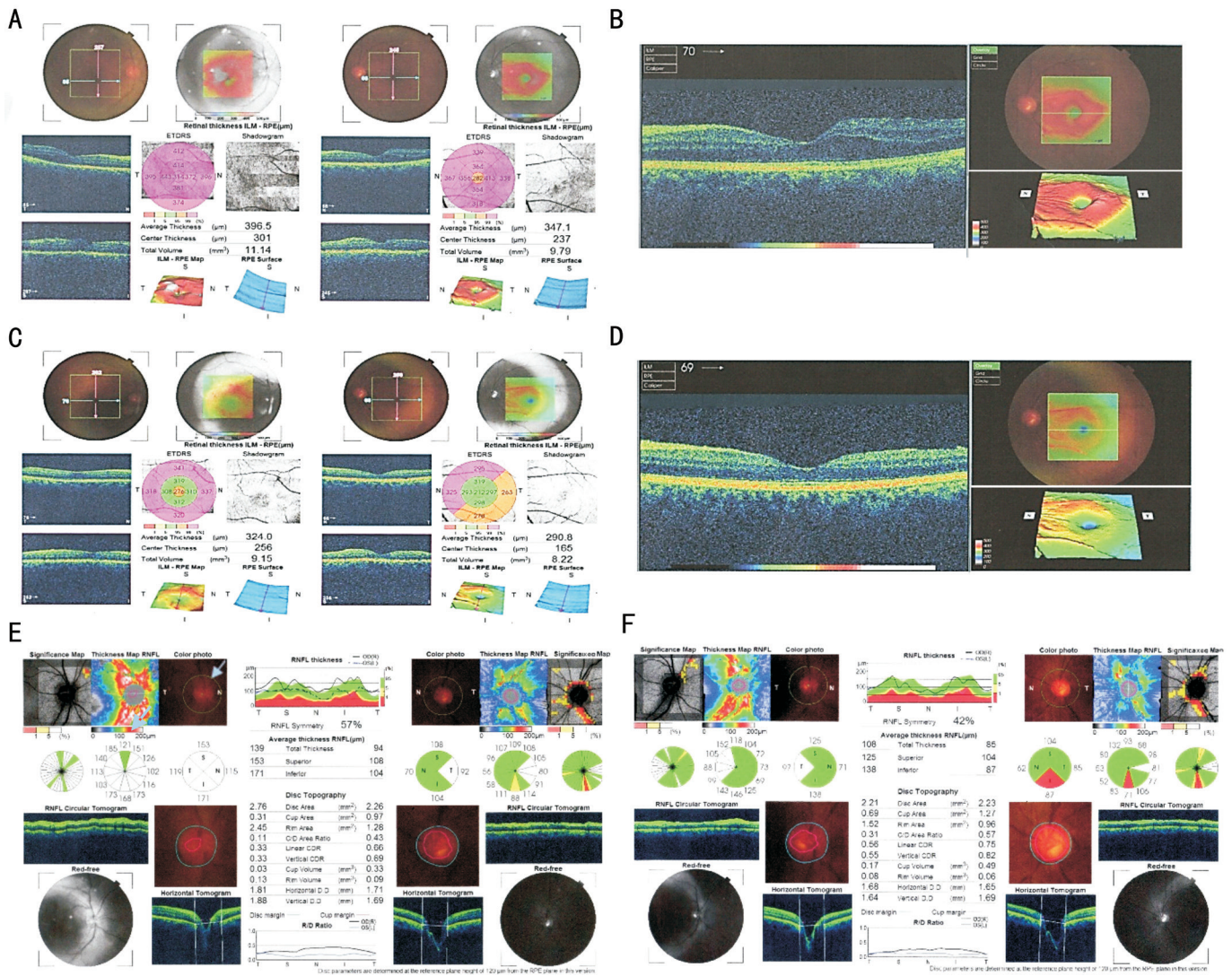


Figure 3 Case 3 A: Macular OCT before treatment November 2016, showing overall macular thickening in pink colors; B: Enlarged OCT of left macula showing thickening of macula sparing the foveolar region in red color; C: Macular OCT 6mo after treatment with Acetazolamide showing significant decrease in macular thickness; D: Enlarged OCT of the left macula after 6mo shows resolution of temporal increased thickness and continuation of nasal increased thickness; E: OCT of optic nerve November 2016 before treatment showed micro-papilledema (blue arrow) in right eye and flat disc with large cup left eye; F: After 6mo of treatment with Acetazolamide NFL thickness significantly decreased significantly.

REFERENCES

- 1 London A, Benhar I, Schwartz M. The retina as a window to the brain—from eye research to CNS disorders. *Nat Rev Neurol* 2013;9(1):44-53.
- 2 Beri S, Gosalakal JA, Hussain N, Balky AP, Parepalli S. Idiopathic intracranial hypertension without papilledema. *Pediatr Neurol* 2010;42(1):56-58.
- 3 Sinclair AJ, Burdon MA, Nightingale PG, Matthews TD, Jacks A, Lawden M, Sivaguru A, Gaskin BJ, Rauz S, Clarke CE, Ball AK. Rating papilloedema: an evaluation of the Frisén classification in idiopathic intracranial hypertension. *J Neurol* 2012;259(7):1406-1412.
- 4 Gittinger JW Jr, Asdourian GK. Macular abnormalities in papilledema from pseudotumor cerebri. *Ophthalmology* 1989;96(2):192-194.
- 5 Talks SJ, Mossa F, Elston JS. The contribution of macular changes to visual loss in benign intracranial hypertension. *Eye (Lond)* 1998;12(Pt 5):806-808.
- 6 Optical Coherence Tomography Substudy Committee, NORDIC Idiopathic Intracranial Hypertension Study Group. Papilledema outcomes from the optical coherence tomography substudy of the idiopathic intracranial hypertension treatment trial. *Ophthalmology* 2015;122(9):1939-1945.e2.

- 7 Bidot S, Bruce BB, Saindane AM, Newman NJ, Biousse V. Asymmetric papilledema in idiopathic intracranial hypertension. *J Neuroophthalmol* 2015;35(1):31-36.
- 8 Favoni V, Pierangeli G, Toni F, Cirillo L, La Morgia C, Abu-Rumeileh S, Messina M, Agati R, Cortelli P, Cevoli S. Idiopathic intracranial hypertension without papilledema (IIHWOP) in chronic refractory headache. *Front Neurol* 2018;9:503.
- 9 New predictive value of optical coherence tomography analysis in the diagnosis of idiopathic intracranial hypertension. *J Contemp Med Sci* 2017;3(10):197-207.
- 10 Schirmer CM, Hedges TR. Mechanisms of visual loss in papilledema. *Neurosurg Focus* 2007;23(5):E5.
- 11 Hoyer VJ 3rd, Berrocal AM, Hedges TR 3rd, Amaro-Quireza ML. Optical coherence tomography demonstrates subretinal macular edema from papilledema. *Arch Ophthalmol* 2001;119(9):1287-1290.
- 12 Passi N, Degnan AJ, Levy LM. MR imaging of papilledema and visual pathways: effects of increased intracranial pressure and pathophysiologic mechanisms. *AJNR Am J Neuroradiol* 2013;34(5):919-924.