

Fundus manifestations and HIV viral loads of AIDS patients before and after HAART

Yu Di¹, Xin-Yu Zhao¹, Jun-Jie Ye¹, Bing Li¹, Nan Ma²

¹Department of Ophthalmology, Peking Union Medical College Hospital, Chinese Academy of Medical Sciences, Beijing 100730, China

²Department of Ophthalmology, Beijing Tongren Hospital, Capital Medical University, Beijing 100730, China

Correspondence to: Jun-Jie Ye. Department of Ophthalmology, Peking Union Medical College Hospital, Chinese Academy of Medical Sciences, Beijing 100730, China. yejunjie_xh@163.com

Received: 2019-04-05 Accepted: 2019-06-21

Abstract

• **AIM:** To investigate the fundus manifestations and human immunodeficiency virus (HIV) viral loads of acquired immune deficiency syndrome (AIDS) patients before and after highly active antiretroviral therapy (HAART).

• **METHODS:** This retrospective study included 21 AIDS patients (42 eyes) who presented to the Department of Ophthalmology, Peking Union Medical College Hospital, from 2007 to 2011. Among the patients, 16 showed a good response to HAART, 3 presented drug resistance and 2 were pre-HAART. All patients underwent comprehensive ophthalmic examinations. The HIV viral loads and the CD4⁺ T-cell counts were also determined.

• **RESULTS:** The best-corrected visual acuity (BCVA) of 38 eyes (19 patients) was improved, and cytomegalovirus retinitis (CMVR) in 5 eyes (3 patients) regressed after HAART. Furthermore, 16 patients treated with effective HAART had decreased plasma HIV viral loads (<78 copies/mL) and increased CD4⁺ T-cell counts (343±161 cells/μL, $P<0.005$), but the HIV viral load in tears was still detected at 2404 copies/mL. The CD4⁺ T-cell count was lower in the CMVR group than in the non-CMVR group ($P=0.022$), but the HIV viral load in the tears was not significantly different between the two groups ($P=0.439$).

• **CONCLUSION:** Most patients with AIDS show a good viral response with a decreased HIV viral load and an increased CD4⁺ T-cell count in plasma after HAART. However, the HIV viral load remain quite high in the tear samples. Based on our results, we suggest that AIDS patients undergo long-term HAART that should not be interrupted.

• **KEYWORDS:** acquired immune deficiency syndrome; cytomegalovirus retinitis; highly active antiretroviral therapy; human immunodeficiency virus viral loads; tears

DOI:10.18240/ijo.2019.09.11

Citation: Di Y, Zhao XY, Ye JJ, Li B, Ma N. Fundus manifestations and HIV viral loads of AIDS patients before and after HAART. *Int J Ophthalmol* 2019;12(9):1438-1443

INTRODUCTION

Acquired immune deficiency syndrome (AIDS) is a fatal disease that causes a wide spectrum of diseases. Since its discovery in 1981, AIDS has become one of the world's greatest public health concerns^[1]. Human immunodeficiency virus (HIV) targets CD4⁺ T-cells, causing a steady decline in the absolute number of these cells with progressive immune deficiency as a result. AIDS patients are prone to developing ocular opportunistic infections and malignancies, and the eye is one of the most commonly affected organs. Cytomegalovirus retinitis (CMVR) is the most common and severe retinal infection in patients with HIV. The disease classically occurs when the CD4⁺ T-cell count is lower than 100 cells/μL^[2]. Currently, highly active antiretroviral therapy (HAART) can effectively reduce the plasma HIV viral load and restore the immune function of AIDS patients to avoid the development of ocular complications. However, HIV is not completely eliminated from the body after treatment. In the 1980s, Fujikawa *et al*^[3] found that HIV was sequestered in various tissues of the eye, including the conjunctiva, cornea, and aqueous humor.

To investigate HIV prevalence in the eyes of AIDS patients before and after HAART, we performed a retrospective investigation. HIV viral loads (tears and plasma), CD4⁺ T-cell counts and changes in fundus manifestations before and after HAART were analyzed.

SUBJECTS AND METHODS

Ethical Approval The study followed the tenets of the Declaration of Helsinki and was approved by the Institutional Review Board/Ethics Committee of Peking Union Medical College Hospital (No.S-K698). This study was exempt from obtaining informed consent as it was a retrospective study and data analyses were performed anonymously.

Patients This study was retrospective in nature. Twenty-one consecutive patients with AIDS were recruited at Peking Union Medical College (PUMC) Hospital between 2007 and 2011. All patients were referred from the PUMC Hospital Department of Infectious Disease and presented to the Department of Ophthalmology directly for ocular complication screening. Among the 21 AIDS patients, 16 patients had a good response with an undetectable plasma HIV viral load after HAART, 3 patients were drug resistant and had a high plasma HIV viral load after HAART and 2 patients were pre-HAART.

Patient Assignment The 19 AIDS patients who received HAART were classified into two groups based on the presence or absence of CMVR: the CMVR group ($n=3$, with 5 eyes) and the non-CMVR group (normal fundus; $n=17$, with 33 eyes). We found that 1 patient had CMV retinitis associated with AIDS in both eyes and 2 patients had CMVR unilaterally.

Ophthalmic Examinations and Laboratory Assessments

All patients underwent complete ophthalmic examinations, which included measurements of best-corrected visual acuity (BCVA) with Snellen's visual acuity chart, intraocular pressure evaluations by noncontact tonometry, and pupillary reflex tests. An ocular adnexa examination and ocular motility evaluation were performed. An anterior segment examination for ocular motility was performed using slit-lamp biomicroscopy, and details of the posterior segment were visualized using indirect ophthalmoscopy. In addition, the imaging of each eye was performed by color fundus photography. HIV microangiopathy was diagnosed in the presence of cotton-wool spots or intraretinal hemorrhages, and CMVR was clinically diagnosed in by the presence of characteristic dense, full-thickness, yellow-white lesions along the vascular distribution with irregular granules at the border and hemorrhage on the retinal surface.

For the qualitative HIV viral assay with tears, tear samples were collected directly from the patients' eyes into a sterile tube. Total RNA from the tear and plasma samples was extracted, and reverse transcription-polymerase chain reaction targeting long terminal repeats and integrase was performed. Quantitative assays for plasma and tears to determine the HIV RNA viral load was measured by either a bDNA Analyzer System 340 (Siemens, Munich, Germany) or COBAS Ampliprep/TaqMan 48 assay (Roche, Indianapolis, Indiana, USA) according to the manufacturer's instructions. The CD4⁺ T-cell count was determined by flow cytometry (three-color EPICS-XL flow cytometer, Beckman-Coulter Inc., Miami, Florida, USA).

Statistical Analyses Data were expressed as the mean±standard deviation (SD) when normally distributed and as the median when not normally distributed. A Kolmogorov-Smirnov test

was used to test the parameter distribution. A paired *t*-test was used to compare the CD4⁺ T-cell count of AIDS patients ($n=19$, 38 eyes) before and after HAART. An independent sample *t*-test was used to compare the CD4⁺ T-cell count and HIV viral load in tears of the CMVR group and non-CMVR group. All statistical analyses were performed using SPSS 23.0 software (SPSS Inc., Chicago, IL, USA). The differences in data were reported with 95% confidence intervals (CIs). A *P* value <0.05 was considered statistically significant.

RESULTS

Clinical Data Among the 21 AIDS patients, 13 patients were male, and 8 patients were female. We found that 1 patient had CMVR associated with AIDS in both eyes and 2 patients had CMV retinitis unilaterally. The median age was 40y (range: 22-63y), and the mean follow-up time was 27±14.3mo (range: 3-45mo; Table 1).

Ophthalmic Manifestations Before and After HAART The baseline BCVA values of 42 eyes of 21 patients before HAART in the Department of Ophthalmology were as follows: light perception (LP) 1 eye; 0.01 to 0.2, 2 eyes; 0.3 to 0.7, 2 eyes; and equal or better than 0.8, 35 eyes. Additionally, there were 3 eyes with anterior chamber cells and keratic precipitates and 5 eyes with CMVR, with typical lesions appearing as dense, full-thickness, yellow-white lesions along the vascular distribution with irregular granules at the border and hemorrhage on the retinal surface (Figure 1). Finally, there were 2 eyes with HIV retinopathy that included characteristics such as cotton-wool spots, microangioma, and small hemorrhages in the posterior pole of the fundus.

The BCVA values of 38 eyes of 19 patients were improved after HAART. The improved values were as follows: 0.01 to 0.2, 4 eyes; 0.3 to 0.7, 2 eyes; and equal or better than 0.8, 32 eyes. All anterior segment inflammations disappeared, and the fundus lesions regressed after HAART (Figure 1).

Plasma HIV Viral Loads and CD4⁺ T-cell Counts Before and After HAART

Before HAART (baseline), the plasma HIV viral load was 145620.6±187542.6 copies/mL (NA-1 500 000), and the CD4⁺ T-cell count was 131±117.4 cells/μL (12-417). Nineteen patients were subjected to HAART to obtain viral loads before and after HAART for comparison. Of these patients, 16 showed successful suppression of the HIV viral load after HAART. Of these 16 patients, there were 14 with a positive viral response showing undetectable HIV viral loads in plasma (<50 copies/mL) and 2 with a reduction to 55 copies/mL and 78 copies/mL. However, the quantitative assay that targeted *Gag* and *Pol* in tears showed a viral load of 2883±2062.82 copies/mL (214-23294) of them. The average CD4⁺ T-cell count was significantly increased by 343±161 cells/μL (56-560) in the after-treatment group compared to that in the before-treatment group ($P<0.005$). For the remaining

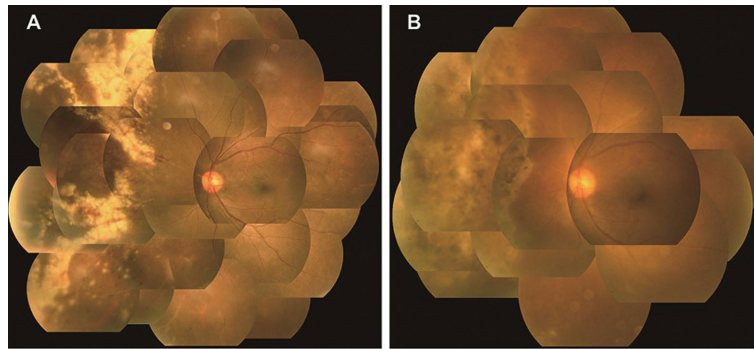


Figure 1 Color fundus photography of the left eye of a 36-year-old male patient with CMVR associated with AIDS before and after HAART treatment A: The lesions of CMVR with dense, full-thickness, yellow-white lesions along the vascular distribution with irregular granules at the border and hemorrhage on the retinal surface of the nasal retina before HAART; B: The lesions of CMVR regressed and hemorrhage clearly resolved, and some retinal pigmentation remained after HAART.

Table 1 The HIV viral loads and CD4⁺ T-cell counts of 21 patients before and after HAART

HAART	Case No.	Gender	Age (y)	Therapy (mo)	Plasma HIV viral load		Tears HIV viral load		Plasma CD4 ⁺ T-cell count	
					Before HAART	After HAART	bDNA	Taq Man	Before HAART	After HAART
Long-term HAART	1	M	50	30	4010	78	3776	4087	208	489
	2	M	58	09	36670	<50	21170	NA	165	261
	3	M	63	33	19006	<50	2537	NA	110	395
	4	M	33	27	14144	<50	2404	1896	266	356
	5	F	36	45	28459	<50	214	411	133	521
	6	F	35	09	390	<50	454	2633	29	217
	7	M	43	15	NA	<50	713	NA	25	56
	8	M	33	39	>500000	<50	1536	NA	110	547
	9	M	55	03	NA	<50	1152	NA	25	237
	10	F	40	06	444	<50	389	630	89	124
	11	F	33	30	>500000	<50	2178	NA	18	440
	12	M	52	42	991	<50	23294	NA	151	560
	13	F	48	39	14045	<50	11058	NA	131	224
	14	M	39	45	194533	<50	4938	NA	16	396
	15	M	42	30	58867	<50	6990	NA	240	496
	16	F	35	33	NA	55	225	553	19	170
Drug resistance	17	M	36	NA	297133	3744	4730	5589	12	209
	18	F	35	NA	277309	2622	637	NA	254	197
	19	M	48	NA	>500000	20483	3132	NA	13	126
HAART naive	20	F	35	NA	139173	371	13400	NA	325	536
	21	M	40	NA	26997	24740	552	NA	417	463

M: Male; F: Female; HIV: Human immunodeficiency virus; HAART: Highly active antiretroviral therapy; DNA: Deoxyribonucleic acid; NA: Not available.

3 drug-resistant patients, the median plasma HIV viral load was 3744 copies/mL, the HIV viral load in tears was 2883±2062.82 copies/mL (637-4730), and the CD4⁺ T-cell count was 177.33±44.86 cells/μL (126-209; Table 1).

Plasma HIV Viral Loads and the CD4⁺ T-cell Counts of the CMVR and non-CMVR Groups before and after HAART Both the CMVR and the non-CMVR groups showed a notable positive plasma HIV viral load, with a median of 444 copies/mL and 32564.5 copies/mL, respectively. For CD4⁺ T-cell counts, the concentration in the CMVR group

was 42.00±41.22 cells/μL (12-89), and there was no difference from that in the non-CMVR group [118.00±91.29 cells/μL (12-325; *P*=0.182)].

With long-term HAART, the plasma HIV viral load of the CMVR group and the non-CMVR group decreased significantly with a median of <50 copies/mL for both. However, the HIV viral load was still high in tear samples, and there was no difference between the CMVR group [1944.00±2418.18 copies/mL (389-4630)] and the non-CMVR group [5330.94±7184.06 copies/mL (214-23294); *P*=0.439].

Table 2 The HIV viral loads and CD4⁺ T-cell counts of the CMVR and non-CMVR groups before and after HAART

Test index	CMVR group (n=5 eyes)	Non-CMVR group (n=33 eyes)	P
Before HAART			
Plasma HIV viral load (copies/mL) ^a	444	32564.5	
CD4 ⁺ T-cell count (/mm ³) ^b	42.00±41.22	118.00±91.29	0.182
After HAART			
Plasma HIV viral load (copies/mL) ^a	<50	<50	
Tears HIV viral load (copies/mL) ^a	713	2470.5	0.434
CD4 ⁺ T-cell count (/mm ³) ^b	129.67±76.66	352.00±147.25	0.022

CMVR: Cytomegalovirus retinitis; HIV: Human immunodeficiency virus; HAART: Highly active antiretroviral therapy. ^aMedian (interquartile range); ^bMean±Standard deviation.

However, we found that the CD4⁺ T-cell count of the CMVR group [129.67±76.66 cells/μL (56-209)] was significantly lower than that of the non-CMVR group [352.00±147.25 cells/μL (126-560)] ($P=0.022$; Table 2).

DISCUSSION

HIV/AIDS was discovered in the United States in 1981, and it has since been identified worldwide. In recent years, there has been a notable increase in morbidity due to HIV in China. According to the data of the AIDS epidemic report in China, the total number of people with HIV/AIDS was 57.5 million at the end of 2015. Of that population, 23.40 million were AIDS patients. For this reason, it has been one of the world's greatest public health concerns in recent years^[4]. During the development of HIV/AIDS, the eye is one of the most commonly affected organs. One percent to 2% of patients present ophthalmic disease as the first manifestation, CMVR is the most common ocular opportunistic infection^[5]. HAART (introduced in 1996), which includes a combination of antiretroviral drugs to decrease HIV replication and stimulate the recovery of the CD4⁺ T-cell count, is typically applied in such cases. However, the virus cannot be eliminated from the body completely with current treatment methods as it can sequester in various tissues^[6]. In 2005, Ye *et al*^[7] found that AIDS patients still had detectable HIV viral loads in the aqueous humor after HAART, even though the HIV viral load in plasma was undetectable after treatment. In daily life and interactions, it easy to come in contact with the tears of AIDS patients. In particular, ophthalmologists have contact with patient tears almost daily. Our study aimed to analyze the changes in fundus manifestations, HIV viral loads (tears and plasma), and CD4⁺ T-cell counts in 21 AIDS patients before and after HAART.

Common Ocular Manifestations in HIV-Infected Patients

The advanced stage of HIV infection, clinically termed AIDS, is defined by a profound decrease in the CD4⁺ T-cell count (<200 cells/μL). Ocular manifestations are among the

most common clinical features of HIV-infected patients, with various clinical phenotypes affecting the structure of the eye almost completely^[8]. Moreover, clinical phenotypes of ocular manifestations can be initial signs of underlying HIV disease. Of these manifestations, CMVR is the most common opportunistic ocular infection in AIDS patients. Before the development of HAART, CMVR affected 30%-40% of HIV patients, and they often died within 1-2y after the definitive diagnosis of CMVR. Although morbidity was significantly reduced after the application of HAART, CMVR continues to be the major AIDS-related ocular opportunistic infectious disease^[9-10]. In a previous study by Acharya *et al*^[11] that evaluated ophthalmic complications in AIDS patients, HIV microvasculopathy was found in 25%-50% of the studied AIDS-affected patients; however, CMVR, was found in only 2.53% of patients. In our study, five eyes (11.9%) presented CMV retinitis and two eyes (4.7%) presented HIV microvasculopathy. It is important to note that these results may be related to different populations, regions, and the time of diagnosis. Additionally, other studies showed that HIV microvasculopathy was linked to the occurrence of CMVR^[12-15]. When immunodeficiency is combined with HIV microvasculopathy, it becomes easier for opportunistic infections to invade the body, especially CMVR.

HIV Viral Loads in Plasma and Tears after HAART

HIV can be detected in the aqueous humor and vitreous of HIV/AIDS patients, as well as in the cornea, conjunctiva, retina, optic nerve, and even the corneal contact lens. Li^[16] proposed that a large number of lymphocytes, including CD4⁺ T-cells, exist in the lacrimal glands of AIDS patients and that these cells can be transferred from other lymphoid tissues to the lacrimal gland. In our study, the obtained results showed that the HIV viral load in tears was notably present, even though the plasma HIV viral load was undetectable after long-term HAART. We also found that the HIV viral load in tears of both the CMVR and the non-CMVR groups after HAART was positive and that

there was no significant difference between them. Furthermore, after long-term HAART, fundus lesions regressed and the visual acuity improved in 5 eyes with CMVR. However, the HIV viral load was quite high in the tear sample. Although fundus lesions were effectively controlled with long-term HAART, HIV was still detected in tears. Based on these results, we hypothesize that ocular HIV viral reservoirs might exist in AIDS patients.

CD4⁺ T-cell Counts and Ocular Manifestations Ocular manifestations occur throughout the HIV illness with a progressive loss of CD4⁺ T-cells^[17]. Kim *et al*^[18] found that CD4⁺ T-cell count was an independent risk factor for developing ocular manifestation. For instance, Lai *et al*^[9] proposed that a CD4⁺ T-cell count of less than 100 cells/ μ L are associated with a high risk for ocular HIV-related opportunistic infections, such as retinal microangiopathy, conjunctival microvasculopathy, keratoconjunctivitis sicca, varicella zoster virus retinitis (VZVR), and CMVR. In addition, Nishijima *et al*^[19] recommended regular ophthalmologic screenings by ophthalmologists for AIDS patients with a CD4⁺ T-cell count lower than 200/ μ L in a source-rich setting. Shah *et al*^[20] proposed CD4⁺ T-cell count <50 μ L as enrollment criteria for CMVR screening. In our study, CMV retinitis affected three AIDS patients with a CD4⁺ T-cell count lower than 200 cells/ μ L; counts in these patients were 25, 89, and 12 cells/ μ L. We also compared the CD4⁺ T-cell counts between the CMVR group and the non-CMVR group before and after HAART. The results showed that the CD4⁺ T-cell count of the CMVR group was significantly less than that of the non-CMVR group after HAART. As such, we propose that the CD4⁺ T-cell count of the CMVR group increased after a long-term HAART; however, the immune systems of the CMVR patients was still worse than those of the non-CMVR group. This weakened immunity might account for the CD4⁺ T-cell count difference between the two groups after long-term HAART.

In conclusion, this study showed that the fundus lesions of all AIDS patients clearly regressed after a long-term HAART. Furthermore, most patients had a good viral response with an undetectable plasma HIV viral load and a good immunological response with an increased CD4⁺ T-cell count. However, the concentrations of the HIV viral loads in tear samples was still quite high. This suggests that HAART should not be interrupted and is essential to avoid iatrogenic infection in ophthalmologists.

ACKNOWLEDGEMENTS

Foundation: Supported by the National Key Technologies R&D Program for the 11th Five-year Plan (No.2008ZX10001-006)

Conflicts of Interest: Di Y, None; Zhao XY, None; Ye JJ, None; Li B, None; Ma N, None.

REFERENCES

- 1 Wang L, Wang L, and Ding ZW. Trend analysis of hiv sentinel testing for HIV infection prevalence from 1995 to 2009 in China. *Chinese Journal of Epidemiology* 2011;32(1):20-24.
- 2 Chiotan C, Radu L, Serban R, Cornăcel C, Cioboata M, Anghel A. Cytomegalovirus retinitis in HIV/AIDS patients. *J Med Life* 2014;7(2): 237-240.
- 3 Fujikawa LS, Salahuddin SZ, Palestine AG, Masur H, Nussenblatt RB, Gallo RC. Isolation of human T-lymphotropic virus type III from the tears of a patient with the acquired immunodeficiency syndrome. *Lancet* 1985;2(8454):529-530.
- 4 The Ministry of Health of the People's Republic of China, the United Nations Programme on HIV/AIDS (unaids), the World Health Organization. China's AIDS epidemic estimated in 2015. *China's AIDS Sexually Transmitted Diseases* 2016;2(22):69-69.
- 5 Geng S, Ye JJ, Liu LQ, Xu HY, Wang WW, Wang SR. Diagnosis and treatment of eye diseases associated with HIV infection and AIDS. *Zhonghua Yan Ke Za Zhi* 2009;45(12):1093-1098.
- 6 Fujikawa LS, Salahuddin SZ, Ablashi D, Palestine AG, Masur H, Nussenblatt RB, Gallo RC. HTLV-III in the tears of AIDS patients. *Ophthalmology* 1986;93(12):1479-1481.
- 7 Ye JJ, Zhao JL, Liu XW, Wang WW, *et al*. A case of human immunodeficiency virus was detected in aqueous humor in a patient with acquired immunodeficiency syndrome. *Zhonghua Yan Ke Za Zhi* 2011;47(5):458-459.
- 8 Liu XW, Ye JJ, Geng S, Xu HY, Zhao JL, Min HY, *et al*. Basic and clinical research related to ocular complications in human immunodeficiency virus infection/acquired immunodeficiency syndrome patients. *Medical Journal of Peking Union Medical College Hospital* 2016;7(1):8-12.
- 9 Lai TY, Wong RL, Luk FO, Chow VW, Chan CK, Lam DS. Ophthalmic manifestations and risk factors for mortality of HIV patients in the post-highly active anti-retroviral therapy era. *Clin Exp Ophthalmol* 2011;39(2):99-104.
- 10 Stewart MW. Ophthalmologic disease in HIV infection: recent changes in pathophysiology and treatment. *Curr Infect Dis Rep* 2017;19(12):47.
- 11 Acharya PK, Venugopal KC, Karimsab DP, Balasubramanya S. Ocular manifestations in patients with HIV infection/AIDS who were referred from the ART Centre, Hassan, Karnataka, India. *J Clin Diagn Res* 2012;6(10):1756-1760.
- 12 Holland GN, Pepose JS, Pettit TH, Gottlieb MS, Yee RD, Fooks RY. Acquired immune deficiency syndrome. Ocular manifestations. *Ophthalmology* 1983;90(8):859-873.
- 13 Hodge WG, Boivin JF, Shapiro SH, Lalonde RG, Shah KC, Murphy BD, Dionne MA, Goela A. Clinical risk factors for cytomegalovirus retinitis in patients with AIDS. *Ophthalmology* 2004;111(7):1326-1333.
- 14 Sugar EA, Jabs DA, Ahuja A, Thorne JE, Danis RP, Meinert CL. Incidence of cytomegalovirus retinitis in the era of highly active

antiretroviral therapy. *Am J Ophthalmol* 2012;153(6):1016-1024.e5.

15 Iwasaki Y, Yamamoto N, Kawaguchi T, Ozaki N, Tomita M, Ajisawa A, Mochizuki M, Murakami K. Human immunodeficiency virus-related retinal microangiopathy and systemic cytomegalovirus disease association. *Jpn J Ophthalmol* 2013;57(4):372-378.

16 Li ZJ. Lacrimal gland of Immunology. *New progress of Ophthalmology* 2003;23(1):1-4.

17 Abu EK, Abokyi S, Obiri-Yeboah D, Ephraim RK, Afedo D, Agyeman LD, Boadi-Kusi SB. Retinal microvasculopathy is common in HIV/AIDS patients: a cross-sectional study at the cape coast teaching hospital, Ghana. *J Ophthalmol* 2016;2016:8614095.

18 Kim YS, Sun HJ, Kim TH, Kang KD, Lee SJ. Ocular manifestations of acquired immunodeficiency syndrome. *Korean J Ophthalmol* 2015;29(4):241-248.

19 Nishijima T, Yashiro S, Teruya K, Kikuchi Y, Katai N, Oka S, Gatanaga H. Routine eye screening by an ophthalmologist is clinically useful for HIV-1-infected patients with CD4 count less than 200/ μ L. *PLoS One* 2015;10(9):e0136747.

20 Shah JM, Leo SW, Lee TL, Tan XL, Pan JC, Wong EP, Yong VK, Lim TH, Teoh SC. A cytomegalovirus retinitis screening program: evaluation of enrollment criteria for HIV patients in Singapore. *Ocul Immunol Inflamm* 2015;23(5):362-370.