

Beneficial effects of vincamine with thioctic acid and lutein on retinal and optic nerve functions in an opaque media

Mona Abdelkader, Sameh Saleh, Tharwat Mokbel, Hossam Abouelkheir, Ayman Abd El Ghafar

Mansoura Ophthalmic Center, Mansoura Medicine Hospital, Faculty of Medicine, Mansoura University, Mansoura 35516, Egypt

Correspondence to: Sameh Saleh. Ophthalmology Center, Faculty of Medicine, Mansoura University, Mansoura 35516, Egypt. yohaahmed12@yahoo.com

Received: 2019-02-24 Accepted: 2019-06-26

Abstract

• **AIM:** To detect whether the combination of vincamine, thioctic acid and lutein will improve the retina and optic nerve functions in cases of an opaque media with an optic nerve and/or a retinal defect or not.

• **METHODS:** Totally 2000 patients (2000 eyes) of corneal opacities with defects in the optic nerve or/and the retinal functions were studied. Every patient received three types of drugs: thioctic acid with cyanocobalamine, vincamine, and lutein. The drugs were given daily for 3-12mo according to patient's responses. Full field flash electroretinogram (ERG) and flash visual evoked potential (VEP) were done before treatment and at 1, 3, 6, and 12mo sequentially. Patients were followed up for 12mo.

• **RESULTS:** In the 2000 eyes, 1000 eyes had both moderate optic nerve and retinal function defects; and 840 eyes out of the 1000 improved with the medical treatment. Another 500 eyes out of the 2000 eyes had extinguished retinal function with normal optic nerve function and only 125 eyes of them improved. The 290 out of the 2000 eyes had severe defects in optic nerve with normal retinal function and 130 of them improved. Another 210 eyes have mild optic nerve and retinal function defects and 194 improved.

• **CONCLUSION:** The combination of vincamine, thioctic acid with cyanocobalamine, and lutein improved both retina and optic nerve functions mainly in mild and moderate defect than in severe cases.

• **KEYWORDS:** retina; optic nerve; opaque media; thioctic acid with cyanocobalamine; vincamine; lutein

DOI:10.18240/ijo.2019.09.13

Citation: Abdelkader M, Saleh S, Mokbel T, Abouelkheir H, Abd El Ghafar A. Beneficial effects of vincamine with thioctic acid and

lutein on retinal and optic nerve functions in an opaque media. *Int J Ophthalmol* 2019;12(9):1450-1455

INTRODUCTION

There are few studies on the effects of medical drugs on the retina and optic dysfunctions that trigger the author to study the effect of a specific combination of drugs on the retina and optic nerve functions. Also, oxidative stress participates in the pathogenesis of several retinal disorders and the role of oxidants remains unclear.

The retina is an extension of the brain, shaped from neural tissues and is connected to the brain properly by the optic nerve. Age-related macular degeneration (AMD) is one of the leading causes of severe central visual acuity loss in elderly people and seems to be an economic problem. Lutein is the most essential carotenoid present in certain selective tissues of the human body, mainly at the level of the retina, macula and lens. Antioxidant on the other hand removes free radicals and thereby terminates the chain reactions that can damage cells.

Antioxidants and lutein administration have been shown to improve visual function of vision-threatening eye diseases, AMD and diabetes^[1-2]. Visual evoked potential (VEP) is a visually evoked electrophysiological signal extracted from visual cortex activity. It measures the electrical signal generated at visual cortex in response to visual stimulation. VEP depends on integrity of central vision at any level of visual pathway^[3]. Full field flash electroretinogram (ERG) gives a mass-response of the retina to flashlight. The resultant response is the total response of the retina^[4]. ERG gives information about treatment toxicity and safety^[5].

The aim of this study was to evaluate the effect of a combined therapy that consisted of vincamine, thioctic acid with cyanocobalamine, and lutein on the visual function in cases of an opaque media with retina and/or optic nerve pathology.

SUBJECTS AND METHODS

Ethical Approval All subjects were carried out in accordance with the tenets of the Declaration of Helsinki (1989) of the world medical association. The study was approved by Mansoura International Review Board (IRB) Ethics Committee. Each patient signed a written consent before joining the study without any stipend.

Table 1 Demographic characteristics among groups

Groups	Eyes	Age (mean±SD), y	Sex (F/M)	Optic nerve function	Retinal function
Group 1	1000	50±10	450/550	Moderate defect	Moderate defect
Group 2	500	55±13	350/150	Normal	Severe defect
Group 3	290	46±15	90/200	Severe defect	Normal
Group 4	210	44±12	135/75	Mild defect	Mild defect

There were no statistical significant difference between groups in age and sex.

Subjects This study was carried out on patients attending the Outpatient's Clinic of Mansoura Ophthalmic Center from February 2008 to July 2018. The study included 2000 patients (2000 eyes) of dense corneal opacities with defects in the optic nerve or/and the retinal functions. The choice of patients was randomized. About 300 (15%) patients had type 1 diabetes mellitus, 500 (25%) patients had type 2 diabetes mellitus and 470 (23.5%) patients had hypertension. The subjects were divided into four groups. Group 1 comprised of 1000 patients (550 males and 450 females, aged 50±10y) with moderate defects in both optic nerve and retinal functions. Group 2 comprised of 500 patients (350 females, 150 males, aged 55±11y) with severe (extinguished) retinal function defect and normal optic nerve function. Group 3 comprised of 290 patients (200 male, 90 female aged 48±15y) that had severe optic nerve defects and normal retinal function and Group 4 comprised of 210 patients (135 females, 75 males, aged 55±9y) with mild defects in both optic nerve and retinal functions. Moderate defect means reduction of normal values by about 50%. Severe defect means reduction of normal values by more than 70%. Mild defect means the reduction of normal values by less than 30%. Patients with clear cornea, retinal detachment, vitreous hemorrhage, and glaucoma were exclusive.

Eye Examination All patients were examined on the first day before medical treatment after the first month, and this was done every three months for 12mo. The examination include visual acuity assessment, ultrasound to detect retinal detachment, vitreous haemorrhage, and any other surgical condition, ERG, and VEP. ERG and VEP were recorded using Roland Consult (Germany), and were done according to international standard for clinical electrophysiology and vision (ISCEV) standards^[6-7].

Full Field Flash Electroretinogram After topical corneal anesthesia (benoxinate hydrochloride 4%), positive electrode [Dawson, Trick and Iitzkow (DTL) electrode] was placed just contact with corneal limbus; ground electrode was installed on the forehead; and negative electrode was placed near orbital rim temporarily. The recording was monocular. After dark adaptation for 20min, ERG was recorded in 5 steps: scotopic rod response, scotopic combined response, oscillatory potential, then light adaptation for 10min, following photopic cone response, and flicker response recording.

Table 2 Causes of corneal opacities among groups

Groups	Trauma	Bacterial infection	Fungal infection
Group 1	865	104	31
Group 2	144	356	0
Group 3	208	89	3
Group 4	57	134	9

Flash Visual Evoked Potential Patients were instructed to wash their hair with shampoo (for oil free scalp) on the day of the investigation to reduce skin impedance for better recording of VEP. Standard silver chloride electrodes of 1 cm diameter were used for recording. Positive electrode was connected to the midline of the head two fingers breadth above the inion (projection at the back of the head). A ground electrode was connected to the midline of the head at the level of the ear lobule. Negative electrodes were connected to the middle of the forehead. The sites of the electrodes were cleaned with cleaning cream before putting the electrodes. The electrodes (silver, cup-shaped) were filled with connecting gel before application. For each eye, two recordings were obtained. Patients were asked to fix their gaze on the flash generated in Ganzfeld. They were watched for any gross eye movement or attention lapse during the procedure through the camera in the monitor. Two trails were given for each eye.

Medical Treatment Each patient was administered the combination of lutein 6 mg (I Care capsule, Sigma industry), thioctic acid 600 mg with cyanocobalamine 500 mg (Thioacid compound 600, Eva Pharma), vincamine 30 mg (Oxybral, Glaxo Company). Each patient was given these combination daily for 6 to 12mo according to ERG and VEP responses. When the improvement reached maximum, the combination was stopped and the patient continued on lutein only for the next 3mo

RESULTS

The study included 2000 patients (2000 eyes) with dense corneal opacity. Of them 1025 patients were female (51.25%) and 975 (48.75%) were male (Table 1). The causes of corneal opacities were included in Table 2.

In Group 1, patients have moderate reduction in the optic nerve and retinal function. There was improvement of both retina and optic nerve functions in 840 out of the 1000 eyes

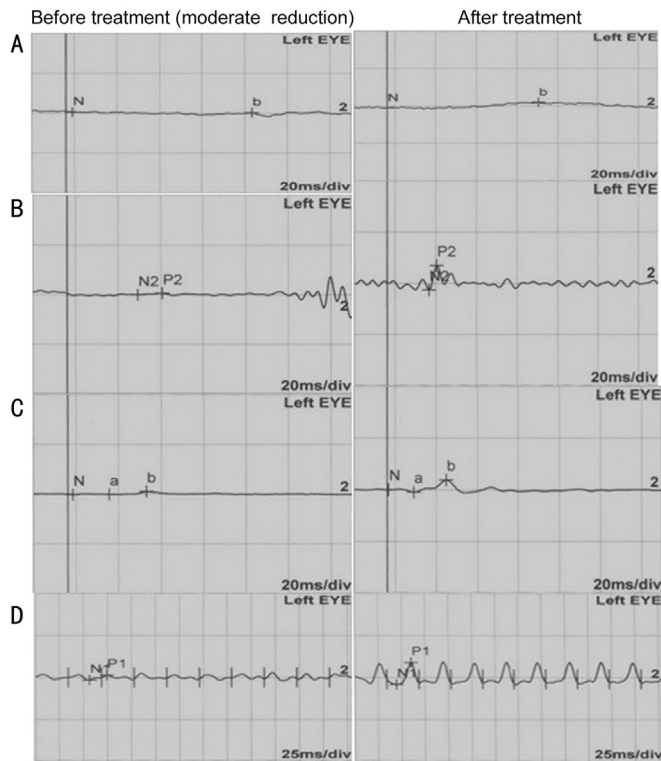


Figure 1 ERG before and after treatment Scotopic ERG (A), oscillatory potential ERG (B), photopic ERG (C), and flicker ERG (D) which reduction in amplitude and delay in latency are improved after treatment.

(84%). Among them 600 eyes (60%) of the 840 improved after 6mo, while the other 240 eyes (24%) improved after 9mo (Figures 1 and 2). There was an increase in the amplitudes of both scotopic rod and photopic cone responses and there was reduction in their latencies. There was also an increase in the amplitudes of both oscillatory potential and flicker responses.

In Group 2, there were severe reductions in retinal function with normal optic nerve function. There was an improvement in only 125 eyes (25%) patients. Seventy-four eyes improved after 9mo (74/125) and 51 eyes (51/125) improved after 12mo (Table 3). In Group 3, there was a severe reduction in the optic nerve with normal retinal function. There was an improvement of 130 eyes (44.8%) out of 290 eyes. Thirty eyes improved after 6mo (30/130), 43 eyes (43/130) improved after 9mo and 57 eyes (57/130) improved after 12mo. There was an increase in the amplitude of P100 with a reduction in latency (Table 4).

In Group 4, there was a mild reduction of both optic nerve and retina functions. There was improvement in 194 out of 210 (92.3%) patients. The improvement took place after 6mo (Tables 5 and 6).

Complication of Medical Treatment Fifty patients (50/2000, 2.5%) complained about abdominal disturbance like nausea, vomiting, but this symptom was controlled by digestion regulator drug (domperidone, motilium capsule, Gansing company). Other patients were well tolerated.

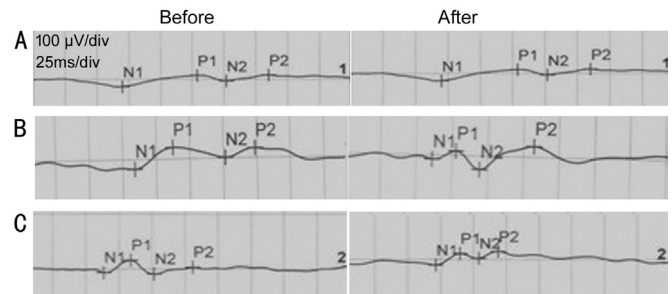


Figure 2 The change of P100 latency after treatment A: Severe delay in N2 and P2 latency did not improve after treatment; B: Severe delay in N2 and P2 latency improved with treatment; C: Moderate delay in N2 and P2 latency improved after treatment.

Table 3 Full field flash electroretinogram changes in Group 2 after treatment

ERG	Before treatment	After treatment	P
Scotopic			
Rod amplitude	45±12	55±7	0.001
Latency	80±6	69±4	0.004
Combined			
Amplitude of b wave	125±20	188±25	0.008
Latency	45±9	40±6	0.005
Oscillatory potential			
Amplitude	15±8	20±4	0.001
Latency	37±3	25±5	0.01
Photopic			
Amplitude	40±8	55±10	0.007
Latency	39±4	31±2	0.002
Flicker			
Amplitude	42±9	58±11	0.005
Latency	69±5	60±4	0.003

Table 4 Full field flash electroretinogram changes in Group 3 after treatment

ERG	Before treatment	After treatment	P
Scotopic rod			
Amplitude	10±11	40±10	0.008
Latency	88±6	73±7	0.005
Combined			
Amplitude	90±19	150±29	0.004
Latency	50±6	40±5	0.002
Oscillatory potential			
Amplitude	6±4	17±7	0.008
Latency	40±9	30±4	0.009
Photopic			
Amplitude	15±6	39±13	0.005
Latency	43±3	39±2	0.007
Flicker			
Amplitude	20±5	43±5	0.006
Latency	70±14	66±10	0.008

Table 5 Visual evoked potential P100 latency changes among groups

Groups	Before treatment	After treatment	P
Group 1	101±45	125±8	0.005
Group 2	110±5	110±2	0.9
Group 3	177±16	140±5	0.001
Group 4	125±9	116±4	0.008

Table 6 ERG changes in Group 4 after treatment

ERG	Before treatment	After treatment	P
Scotopic rod			
Amplitude	50±7	68±10	0.005
Latency	70±6	60±7	0.007
Combined			
Amplitude	188±21	210±11	0.006
Latency	40±5	35±3	0.004
Oscillatory potential			
Amplitude	22±5	26±4	0.007
Latency	30±7	21±3	0.004
Photopic			
Amplitude	50±6	60±10	0.006
Latency	29±7	25±5	0.008
Flicker			
Amplitude	50±9	60±6	0.005
Latency	60±6	53±4	0.003

DISCUSSION

This study shows that oral supplementation with a new combination of lutein 6 mg, vincamine 30 mg, thioctic acid 600 mg and cyanocobalamine 500 mg daily to patients with retina and optic nerve pathologies increased both retina and optic function when measured using full field flash ERG and VEP. There is an increasing possibility of the effect of macular pigment on visual performance which is concentrated within foveal and macular pigment that is composed of lutein^[8], and oxidative damage is one of the pathogenesis of several retinal and optic nerve pathologies. These motivated the author to study the effects of the combination of vincamine, thioctic acid, cyanocobalamine and lutein on the visual function in an opaque media with retinal and/or optic nerve pathology.

Different studies have shown that an increase in serum lutein elevate lutein density in the retina^[9-11]. Lutein is a dietary carotenoid derived from green vegetables and yellow fruits. It was hypothesized that it protects against eye disorders by its physical blue light filtration properties and local antioxidant activity (It protects against light-induced oxidative damage)^[12-13]. Also, lutein has anti-inflammatory antiangiogenic properties and free radical scavenging^[14-15]. The macular carotenoids lutein has neuroprotective and visual performance benefits once deposited in retinal tissues^[16]. Sustained lutein consumption, either through diet or supplementation contribute to reducing burden several ocular diseases^[17-18].

Xu and Lin^[19] found that malondialdehyde content increased in the retina of rat induced by photic injury, and the increase was protected significantly by lutein treatment. The activities of peroxide dismutase and glutathione peroxidase was decreased in rats treated with lutein. The expression of c-fos protein was significantly higher in the retina of blue light injury than that in lutein-treated groups. Neuron nitricoxide synthase was not significant different between treated and untreated groups^[19].

Alpha-lipoic acid is both water and fat soluble that permit to work in every cell in the body in contrast to other antioxidant either water or fat soluble^[20]. Alpha-lipoic acid is a necessary cofactor for mitochondrial α -ketoacid dehydrogenases, and thus serves a critical role in mitochondrial energy metabolism. It elicits a unique set of biochemical activities with potential pharmacotherapeutic value against a host of pathophysiologic insults^[21]. It is capable of quenching reactive oxygen species and reactive nitrogen species such as hydroxyl radicals, peroxy radicals, superoxide, hypochlorous acid and peroxynitrite, thus they prevent singlet oxygen-induced DNA damage^[22]. It also, elicits an array of cellular actions, ranging from a potent antioxidant to a metal chelator to a mediator of cell signaling pathways^[20-21].

Thioctic acid may be transformed during metabolic process to its reduced form. Both reduced and oxidized forms have strong antioxidant and detoxification effect. They protect the cell against free radicals. Also, they scavenge superoxide radical and hydroxyl radical and prevent lipid peroxidation. Thioctic acid protects the neurons from the ischemic damage by the prevention of the accumulation of free radicals^[23]. Cyanocobalamine (vitamin B12) is important for nucleic acid synthesis and essential for nerves.

Yildirim and Emmez^[24] showed that thioctic acid protects from ischemia-reperfusion injuries to the retina in general and to ganglion cells in particular. He said that increased lipid level in retina is responsible for the high vulnerability of eye to oxidative stress and peroxidative damage of membrane lipids allow severe damage. Thus, lipid peroxidation may be the major biochemical alteration in many diseases. He suggested that exogenous thioctic acid delays the ischemia-reperfusion injury process of eye by means of its free radical scavenging effects and inflammation^[24]. Thioctic acid may cause allergy and rash in some cases^[20]. In our study, there was no case recorded.

Vincamine is an indole alkaloid that has neuroprotective attributes and enhancement of vascular blood flow^[23]. Vincamine is natural alkaloid derived from the plant vinca minor. Vincamine affects aggeration of blood and plasma and change viscosity of whole blood. Its vasoactive property increases selectively cerebral blood flow. Vincamine is

nootropic supplement and peripheral vasodilator. It is able to increase blood flow and oxygen of the brain. Although the mechanism of action has not been fully elucidated, it has been established that it has a relatively high affinity for human muscarinic receptors^[25]. One of drawback of vincamine is that it is poor soluble in water and intestinal tract^[25].

The use of this combination will be beneficial because of the combined effects of the increased visual performance of using lutein, the antioxidant effect and the protection from free radical by using thiocetic acid, the vasodilator effect and the protection from ischaemic stress by using vincamine and an increase in amino acid formation by the use of vitamin B12. The combined drugs were tolerated with the patients. There were only mild gastric disturbances in 2.5% that was controlled.

In this study, there was an increase in the retina and optic nerve functions as evaluated by ERG and VEP. There was an improvement of rod and cone functions and an increase in optic nerve function and retino-cortical transmission in most of the patients with mild reduction of retinal and optic nerve dysfunction (95%) in Group 4 and a moderate reduction in retina and optic nerve dysfunctions (90%) in Group 1. There was also an improvement in the minority of patients with a severe reduction in retinal function (20%) in Group 2 and severe reduction of optic nerve function (66.6%) in Group 3. In summary, the combination of vincamine, thiocetic acid and lutein are effective in the improvement of both the retina and optic nerve dysfunctions especially in mild and moderate reduction of retinal function.

ACKNOWLEDGEMENTS

Conflicts of Interest: Abdelkader M, None; Saleh S, None; Mokbel T, None; Abouelkheir H, None; Abd El Ghafar A, None.

REFERENCES

- 1 Chous AP, Richer SP, Gerson JD, Kowluru RA. The Diabetes Visual Function Supplement Study (DiVFuSS). *Br J Ophthalmol* 2016;100(2): 227-234.
- 2 Age-Related Eye Disease Study Research Group. A randomized, placebo-controlled, clinical trial of high-dose supplementation with vitamins C and E, beta carotene, and zinc for age-related macular degeneration and vision loss: AREDS report no. 8. *Arch Ophthalmol* 2001;119(10):1417-1436.
- 3 Odom JV, Bach M, Brigell M, Holder GE, McCulloch DL, Tormene AP, Vaegan. ISCEV standard for clinical visual evoked potentials (2009 update). *Doc Ophthalmol* 2010;120(1):111-119.
- 4 Marmor MF, Fulton AB, Holder GE, Miyake Y, Brigell M, Bach M; International Society for Clinical Electrophysiology of Vision. ISCEV Standard for full-field clinical electroretinography (2008 update). *Doc Ophthalmol* 2009;118(1):69-77.

- 5 Maturi RK, Bleau LA, Wilson DL. Electrophysiologic findings after intravitreal bevacizumab (Avastin) treatment. *Retina* 2006;26(3):270-274.
- 6 McCulloch DL, Marmor MF, Brigell MG, Hamilton R, Holder GE, Tzekov R, Bach M. ISCEV Standard for full-field clinical electroretinography (2015 update). *Doc Ophthalmol* 2015;131(1):1-12.
- 7 Odom JV, Bach M, Brigell M, Holder GE, McCulloch DL, Mizota A, Tormene AP, International Society for Clinical Electrophysiology of Vision. ISCEV standard for clinical visual evoked potentials: (2016 update). *Doc Ophthalmol* 2016;133(1):1-9.
- 8 Loughman J, Nolan JM, Howard AN, Connolly E, Meagher K, Beatty S. The impact of macular pigment augmentation on visual performance using different carotenoid formulations. *Investig Ophthalmol Vis Sci* 2012;53(12):7871-7880.
- 9 Brazionis L, Rowley K, Itsiopoulos C, O'Dea K. Plasma carotenoids and diabetic retinopathy. *Br J Nutr* 2009;101(2):270-277.
- 10 Burke JD, Curran-Celentano J, Wenzel AJ. Diet and serum carotenoid concentrations affect macular pigment optical density in adults 45 years and older. *J Nutr* 2005;135(5):1208-1214.
- 11 Crosby-Nwaobi R, Hykin P, Peto T, Sivaprasad S. An exploratory study evaluating the effects of macular carotenoid supplementation in various retinal diseases. *Clin Ophthalmol* 2016;10:835-844.
- 12 Jia YP, Sun L, Yu HS, Liang LP, Li W, Ding H, Song XB, Zhang LJ. The pharmacological effects of lutein and zeaxanthin on visual disorders and cognition diseases. *Molecules* 2017;22(4):E610.
- 13 Bellezza I. Oxidative stress in age-related macular degeneration: Nrf2 as therapeutic target. *Front Pharmacol* 2018;9:1280.
- 14 Wu J, Cho E, Willett WC, Sastry SM, Schaumberg DA. Intakes of lutein, zeaxanthin, and other carotenoids and age-related macular degeneration during 2 decades of prospective follow-up. *JAMA Ophthalmol* 2015;133(12):1415-1424.
- 15 Xue CY, Rosen R, Jordan A, Hu DN. Management of ocular diseases using lutein and zeaxanthin: what have we learned from experimental animal studies? *J Ophthalmol* 2015;2015:523027.
- 16 Stringham JM, Stringham NT. Serum and retinal responses to three different doses of macular carotenoids over 12 weeks of supplementation. *Exp Eye Res* 2016;151:1-8.
- 17 Buscemi S, Corleo D, Di Pace F, Petroni ML, Satriano A, Marchesini G. The effect of lutein on eye and extra-eye health. *Nutrients* 2018;10(9): E1321.
- 18 Bernstein PS. The role of lutein and zeaxanthin in protection against age-related macular degeneration. *Acta Horti* 2015(1106):153-160.
- 19 Xu X, Lin X. Molecular mechanism of the protective effect of lutein against retinal damage induced by blue-light in rats. *J Hyg Res* 2010;39(6):689-692.
- 20 Smith AR, Shenvi SV, Widlansky M, Suh JH, Hagen TM. Lipoic acid as a potential therapy for chronic diseases associated with oxidative stress. *Curr Med Chem* 2004;11(9):1135-1146.
- 21 Suh JH, Shenvi SV, Dixon BM, Liu HL, Jaiswal AK, Liu RM, Hagen TM. Decline in transcriptional activity of Nrf2 causes age-related loss of

glutathione synthesis, which is reversible with lipoic acid. *Proc Natl Acad Sci U S A* 2004;101(10):3381-3386.

22 Morikawa T, Yasuno R, Wada H. Do mammalian cells synthesize lipoic acid? Identification of a mouse cDNA encoding a lipoic acid synthase located in mitochondria. *FEBS Lett* 2001; 498(1):16-21.

23 Torres MJ, Fierro A, Pessoa-Mahana CD, Romero-Parra J, Cabrera G, Faúndez M. Effect of alpha lipoic acid on leukotriene A₄ hydrolase. *Eur J*

Pharmacol 2017;799:41-47.

24 Yildirim Z, Emmez H, Kale A. Protective effect of alpha-lipoic acid against ischemia-reperfusion injury in retina. *Oxidation Communications* 2014;37(2):555-562.

25 Hasa D, Perissutti B, Grassi M, Chierotti MR, Gobetto R, Ferrario V, Lenaz D, Voinovich D. Mechanochemical activation of vincamine mediated by linear polymers: assessment of some "critical" steps. *Eur J Pharm Sci* 2013;50(1):56-68.