

Treatment of upper and lower lacrimal punctal occlusion using retrograde canaliculotomy and punctoplasty

Ai Zhuang^{1,2}, Jing Sun^{1,2}, Wo-Dong Shi^{1,2}

¹Department of Ophthalmology, Shanghai Ninth People's Hospital, Shanghai Jiao Tong University School of Medicine, Shanghai 200011, China

²Shanghai Key Laboratory of Orbital Diseases and Ocular Oncology, Shanghai 200011, China

Co-first authors: Ai Zhuang and Jing Sun

Correspondence to: Wo-Dong Shi. Department of Ophthalmology, Shanghai Ninth People's Hospital, Shanghai Jiao Tong University School of Medicine, Shanghai Key Laboratory of Orbital Diseases and Ocular Oncology, 639 Zhi Zao Ju Road, Shanghai 200011, China. siwodo@hotmail.com

Received: 2018-09-04 Accepted: 2019-02-26

Abstract

• This is a retrospective, noncomparative analysis of a case series to explore the safety and effectiveness of retrograde canaliculotomy and punctoplasty for treating epiphora due to upper and lower lacrimal punctal occlusion. During the procedure, the horizontal portion of the normal lower canaliculus was identified; the corresponding punctum was reconstructed *via* retrograde canaliculotomy and punctoplasty. Intubation was performed to prevent postoperative reocclusion. Patients were followed up for 12 to 24mo. A total of 16 patients with unilateral upper and lower lacrimal punctal occlusion were included. Satisfactory outcomes were achieved: all 16 patients exhibited improvement of epiphora; 31 rebuilt punctal openings and canaliculi achieved recanalization. Only one upper punctal opening could not be reconstructed because the corresponding canaliculus exhibited severe injury. No significant complications occurred as a result of the treatments. Retrograde canaliculotomy and punctoplasty appears to effective, safe, and minimally invasive for treatment of upper and lower punctal occlusion.

• **KEYWORDS:** punctal occlusion; retrograde canaliculotomy; punctoplasty; intubation

DOI:10.18240/ijo.2019.09.20

Citation: Zhuang A, Sun J, Shi WD. Treatment of upper and lower lacrimal punctal occlusion using retrograde canaliculotomy and punctoplasty. *Int J Ophthalmol* 2019;12(9):1498-1502

INTRODUCTION

Lacrimal punctal occlusion can be caused by trauma, inflammation, congenital anomalies, or surgical intervention^[1-3]. Soft tissues or scars close the punctum, obstructing tear drainage through the canaliculus into the nasal cavity^[4]. Thus, patients may experience severe epiphora and report low quality of life. For patients with punctal stenosis alone or minimal and superficial punctal scars, direct punctoplasty and silicone tube intubation can be used for treatment^[5-6]. For patients with complete upper or lower punctal occlusion, some clinicians have reported the use of a pigtail probe from the normal punctum through the canalicular system to identify and repair the occluded punctum^[7]. For those with simultaneous upper and lower lacrimal punctal occlusion, lacrimal bypass with a conjunctivodacryocystorhinostomy (CDCR) may be an option, although it carries the known risks of displacement, recurrent stenosis, conjunctival granuloma, and backflow from the nasal cavity to the eye^[8]. Here, we chose retrograde canaliculotomy and punctoplasty to treat simultaneous upper and lower lacrimal punctal occlusion. By incising the canaliculus from the grey line and the conjunctival surface, then travelling backwards to reconstruct the punctal opening, we achieved satisfactory outcomes in sixteen patients.

SUBJECTS AND METHODS

Ethical Approval The study followed the tenets of the Declaration of Helsinki and was approved by the Ethics Committee of Shanghai Ninth People's Hospital, Shanghai Jiao Tong University School of Medicine. Written informed consent for participation in the study was obtained from participants or their guardians. Permission was obtained for the use of patients' images.

Overview This is a retrospective, non-comparative analysis of a case series. We included patients who presented to the hospital between September 2015 and September 2016 for treatment of upper and lower lacrimal punctal occlusion. We reviewed patient records, including outpatient and inpatient medical records, as well as follow-up data and photos recorded by the surgeon (Shi WD). In the affected eyes, normal punctal structures could not be found with the naked eye and *via* slit lamp examination (Figure 1). In accordance with Kashkouli *et al's*^[9] visual grading system, punctal occlusion was scored as Grade 0. All patients presented with prominent epiphora

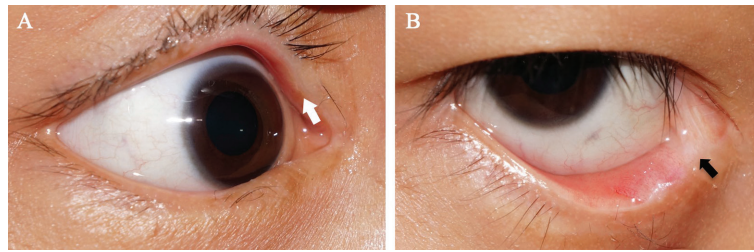


Figure 1 Upper and lower punctal occlusion in a single patient A: The original upper punctal opening was undetectable (white arrow); B: The lower punctal opening was replaced by white scar tissues (black arrow).

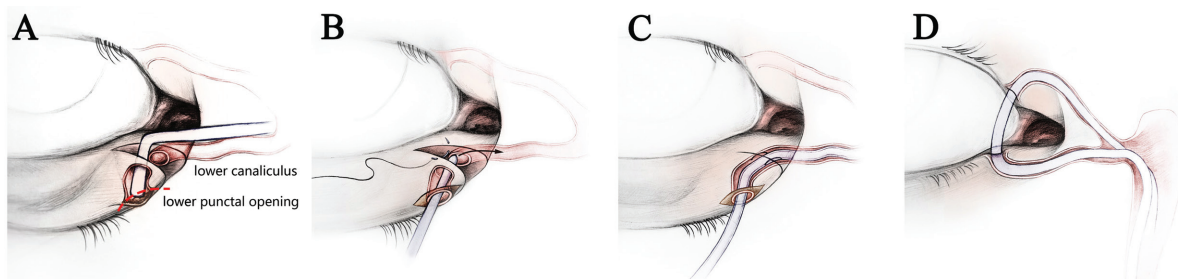


Figure 2 Graphic drawings of the surgical procedure A: After exposing the horizontal canalculus, a Bowman probe was inserted backward to tent the occluded punctal area, and then a punctal opening was made; B: A silicone stent was intubated through the new opening and lacrimal canalculus, eventually reaching the nasal cavity; C: The incision was closed with 8-0 absorbable sutures; D: Bicanalicular nasolacrimal duct intubation with the silicone stent was done.

either indoor or outdoor, and suffered inconvenience from wiping away tears from time to time. Patients with any of the following concomitant conditions were excluded: additional lacerations or obstructions involving the lacrimal sac and/or nasolacrimal duct, craniofacial fractures, injuries of the optic nerve or the globe, prior surgery involving the lacrimal system, or a combination thereof. All patients underwent retrograde canalculotomy and punctoplasty to reconstruct the punctal opening and canalculus. We recorded patient age, sex, etiology (congenital/acquired), affected side, duration of time from onset to surgery, and concomitant conditions. Epiphora (frequency and indoor/outdoor characteristics), tear drainage function, punctal opening shape, and complications were assessed in the retrospective analysis.

Surgical Procedure The patients underwent general or local anesthesia. Each patient was placed in the supine position. The surgery was performed under the OPMI Visu 150 surgical microscope (ZEISS, Germany, 5× magnification). Direct probing and dilation of potential upper and lower punctal sites was attempted to ensure that they were imperforate. A small incision of the gray line perpendicular to the lid margin was made approximately 4 mm medial to the typical location of normal lower punctum. Sharp dissection was carefully performed from the palpebral conjunctival incision to deep soft tissues; this exposed the horizontal canalculus, which lay 2-3 mm deep from the grey line, between the palpebral conjunctiva and the tarsus. Occasionally, the canalculus could not be found within 3 mm from the grey line; therefore, an additional 1-2 mm

was explored under the assumption that the canalculus might have been pushed deeper by fibrous tissues after trauma. When the canalculus was identified, the following procedures were performed.

If the identified canalculus was unobstructed, lacrimal irrigation was performed to ensure that the distal lacrimal system was patent. A Vannas scissor was used to incise the canalculus, and a Bowman probe was inserted backward into the proximal canalculus, such that the tip of the probe tented the occluded punctal area. Then a punctal opening was made, approximately 1 mm in diameter; this was intubated through the new opening with a silicone tube that was 1 mm in diameter, 20 cm in length, with a probe at both heads (FREDA, Shandong, China). The silicone tube was then passed through the lacrimal canalculus and nasolacrimal duct, eventually reaching the nasal cavity. An identical procedure was then performed on the corresponding upper punctal area. Both heads of the silicone tube were extracted from the nasal cavity to form square knots. The canalculus incision was then closed with 8-0 absorbable sutures (Vicryl, Johnson & Johnson, New Brunswick, NJ, USA) (Figure 2).

If the identified canalculus was occluded, an incision was made in a more medial location, in order to identify the canalculus lumen. If a single canalculus was completely occluded, the corresponding upper or lower punctum and canalculus was reconstructed. Thus, only one head of the silicone tube was extracted from the nasal cavity; together with the other head from the reconstructed punctal opening, it

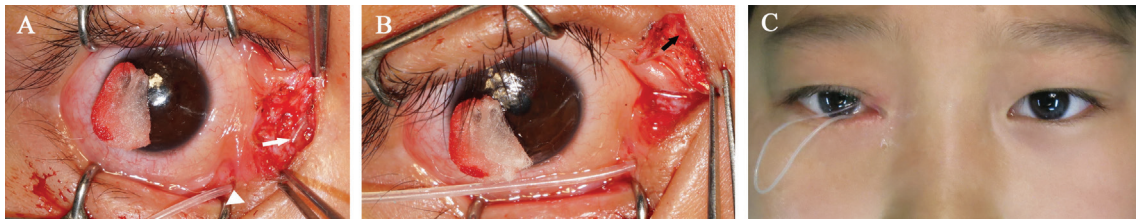


Figure 3 Retrograde canaliculotomy and punctoplasty A: The lower punctal opening (white triangle) was reconstructed, and a silicone stent was inserted from the reconstructed punctum, through the canaliculus (white arrow) and nasolacrimal duct, eventually reaching the nasal cavity; B: The horizontal part of the upper canaliculus (black arrow) was identified; C: A silicone stent was intubated from both the reconstructed upper and lower punctal openings to prevent postoperative reocclusion.

was used to form square knots and was then fixed in the nasal cavity. The incisions were repaired with 8-0 absorbable sutures. If both upper and lower canaliculi were completely occluded, lacrimal bypass with a CDCR was performed instead.

Furthermore, concomitant conditions were also treated. For symblepharon, the adhesion was dissected and covered with amniotic membrane. For bilateral lower eyelid entropion and trichiasis, the modified Hotz procedure was performed^[10-11]. For the lower eyelid ectropion, the rotation flap was used for correction. Because the upper eyelid coloboma exhibited a small size, the eyelid was reconstructed by suturing the defected tarsal plate, trimming the skin, and suturing the eyelid margin.

Postoperative Follow-up Visits Follow-up visits were scheduled 1wk, 1, 3, 6, and 12mo after surgery. At each visit, the shape of the newly formed punctal opening was examined via slit lamp; the symptomatic epiphora and lacrimal irrigation outcomes were recorded. Additionally, the silicone tube was examined at both the puncta and the nasal cavity during the first 3mo. The silicone tube remained in the canaliculi for at least 3mo before ultimate removal.

RESULTS AND DISCUSSION

A total of 16 patients (16 upper punctum and 16 lower punctum) with unilateral upper and lower lacrimal punctal occlusion were included in the study. Among these 16 patients, there were eight males and eight females with a mean age of 27.3y (range, 5-74y). Causes included congenital anomaly ($n=7$, 43.75%) and heat burn ($n=9$, 56.25%). The median time interval from onset to surgery was 5y (range, 4mo to 23y). All patients exhibited prominent epiphora of the sick eye, especially outdoors in cold weather. The normal punctal structures of the affected eye could not be found with the naked eye or *via* slit lamp examination. Prior to undergoing the present surgical procedure, 13 patients had received topical eye drops (*e.g.* levofloxacin, tobramycin, or sodium hyaluronate) to relieve the symptoms; three patients had not previously received any related treatment. Concomitant conditions included symblepharon ($n=3$), lower eyelid ectropion ($n=2$), upper eyelid coloboma ($n=1$), and bilateral lower eyelid entropion and trichiasis ($n=2$).

All patients underwent retrograde canaliculotomy and punctoplasty to reconstruct the puncta and canaliculi. In 15 of 16 patients (93.75%), successful reconstruction of both upper and lower punctal openings was achieved (Figure 3). In one patient, the upper canaliculus was severely injured and could not be found, despite extension of the first incision and creation of an additional incision toward the common lacrimal canaliculus. Fortunately, the lower canaliculus was found; lower punctum and canaliculus reconstruction and intubation were then successfully performed.

The median follow-up period was 15mo (range, 12-24mo). At 1 and 3mo, all puncta remained smooth and well-formed; all 16 patients exhibited good tear drainage function with patent lacrimal passages by lacrimal irrigation. However, 5 patients complained of occasional epiphora (less than 5 times per day). At 6mo, all 16 patients exhibited symptomatic improvement of epiphora; 4 patients reported complete elimination of epiphora both indoors and outdoors, while 12 patients reported continuing epiphora outdoors in cold weather. At the final follow-up visit, there were fewer changes in the lacrimal passage conditions than at 6mo after surgery. No recurrent adhesion or occlusion was found, and recanalization was verified by irrigation from 31 rebuilt punctal openings (Table 1). In addition, the concomitant conditions of symblepharon (No.2, No.3, and No.6), ectropion (No.2 and No.9), eyelid coloboma (No.4), and entropion and trichiasis (No.10 and No.12) were successfully repaired or corrected.

The lacrimal punctum is the beginning point of the lacrimal system. The definition of punctal occlusion is not universally agreed upon. In our study, we made a diagnosis of punctal occlusion when a punctal opening could not be found with the naked eye and the slit lamp^[12]. Punctal occlusion can lead to severe epiphora and require surgical correction, especially when ipsilateral upper and lower puncta are both involved^[13]. In contrast to external punctal stenosis, no open punctum is available in punctal occlusion. Therefore, the following methods are not suitable in this situation: direct punctal dilation and canaliculotomy; 1-snip, 2-snip, or 3-snip punctoplasty; punctoplasty with laser or electrocauterization;

Table 1 Follow-up outcomes

No.	Epiphora		State of affected punctum		Lacrimal irrigation	
	Preop.	Final follow-up	Preop.	Final follow-up	Preop.	Final follow-up
1	Y	Improved	Occluded	Well-formed	-	Patent
2	Y	Improved	Occluded	Well-formed	-	Patent
3	Y	Improved	Occluded	Well-formed	-	Patent
4	Y	Improved	Occluded	Well-formed (LLP)	-	Patent (LLC)
5	Y	Eliminated	Occluded	Well-formed	-	Patent
6	Y	Improved	Occluded	Well-formed	-	Patent
7	Y	Improved	Occluded	Well-formed	-	Patent
8	Y	Eliminated	Occluded	Well-formed	-	Patent
9	Y	Improved	Occluded	Well-formed	-	Patent
10	Y	Improved	Occluded	Well-formed	-	Patent
11	Y	Improved	Occluded	Well-formed	-	Patent
12	Y	Eliminated	Occluded	Well-formed	-	Patent
13	Y	Improved	Occluded	Well-formed	-	Patent
14	Y	Improved	Occluded	Well-formed	-	Patent
15	Y	Eliminated	Occluded	Well-formed	-	Patent
16	Y	Improved	Occluded	Well-formed	-	Patent

Preop.: Preoperative; Y: Yes; LLP: Lower lacrimal punctum; LLC: Lower lacrimal canaliculus. The symbol of “-” means “unable for lacrimal irrigation”.

and punch ampullectomy^[6,13-17]. Some clinicians have reported the use of a pigtail probe to treat the punctal occlusion, by passing the probe through lacrimal canaliculi and tenting the accurate position of the occluded punctum with the probe tip. However, this method is difficult to apply to patients with congenital anomalies, such as canalicular agenesis or simultaneous upper and lower punctal occlusion^[7]. Retrograde intubation of the canaliculi during dacryocystorhinostomy is a new solution; however, this procedure increases scarring of the inner canthus skin^[18]. CDCR with insertion of a Jones tube is not a suitable first choice because of the potential difficulty in maintaining the tube's position and patency, and the tear flow outflow rate^[19-20].

In this study, we performed retrograde canaliculotomy at the horizontal part of the canaliculus. The critical stage of the procedure is exploration of the horizontal part of the canaliculus, in order to locate the punctal area. Within the first 4 mm from the punctum, the horizontal part of the canaliculus lies between the conjunctiva and the palpebral tarsus^[21-22]. The normal canaliculus mucosa usually lay 2-3 mm deep under the palpebral margin. To search for the canaliculus, we incised along the grey line, approximately 4 mm medial to the typical punctal area, for three reasons. Firstly, incision closer to the punctum increased the risk of failing to find intact canalicular mucosa, because the vertical part of the canaliculus is closer to the palpebral margin; thus, it is more likely to be affected by burn or trauma. Secondly, an incision too close to the inner canthus risks requiring a larger incision and more dissection to find the horizontal part, because the canaliculus travels deeper into the orbicularis oculi muscle in this area. Thirdly, anastomosis of the canalicular cut ends, 4 to 7 mm medial to

the punctal area, can largely avoid postoperative canalicular occlusion^[23].

Rather than using a tear drainage tube implant, such as the Jones tube, our method uses the original lacrimal passage; thus, it follows the original anatomy and avoids the risks of rejection. Additionally, the middle canalicular incision was meticulously closed with microsurgical techniques, thereby reducing the incidence of incision obstruction^[21]. In our study, 31 of 32 (96.9%) occluded puncta and canaliculi were successfully reconstructed with this method. In a single patient, the upper canaliculus could not be found, despite two incisions at the horizontal part, each 5-mm deep. This failure occurred because the proximal upper canaliculus was severely injured with extensive scarring, such that normal canalicular mucosal tissues could not be found. Fortunately, we were able to find the lower canaliculus; thus, we successfully performed lower punctum and canaliculus reconstruction and intubation. Considering that the lower canaliculus demonstrates approximately 75% of the tear drainage function, we discontinued further intervention of the upper punctum and canaliculus after discussion with the patient^[24]. Five patients complained of occasional epiphora at 1 and 3-month follow-up visits; however, all patients achieved improvement of symptomatic epiphora after removal of the silicone tube. Therefore, the symptoms might have been caused by temporary iatrogenic lacrimal stenosis of the intubation. At the final follow-up visit, despite sufficient reconstruction of the punctal opening and canaliculus, 12 patients continued to exhibit epiphora outdoors in cold weather. This outcome suggests that our method failed to reconstruct the punctal

sphincter, such that punctal function could not be fully restored. Therefore, patients remain at risk of insufficient tear drainage under some conditions. Notably, occasional epiphora was reported by the patient in whom the upper canaliculus could not be found. Nonetheless, the patient considered the outcome to be acceptable, and there was no requirement for further intervention.

A limitation of this method is that it is only suitable for patients with relatively normal common canaliculus, lacrimal sac, and nasolacrimal duct. However, for patients with both upper and lower punctal occlusion, it is difficult for clinicians to perform preoperative evaluation of the distal part of the lacrimal duct. When attempting the procedure, an alternative method, such as CDCR, should be available in case the distal lacrimal duct is occluded. We note that the small sample size is also a limitation of this study. In conclusion, retrograde canaliculotomy and punctoplasty is a relatively simple method that uses the original lacrimal system and can adjust the tear outflow rate. It appears to be a safe and effective method for treating upper and lower lacrimal punctal occlusion.

ACKNOWLEDGEMENTS

We thank Ryan Chastain-Gross, Ph.D., from Liwen Bianji, Edanz Group China (www.liwenbianji.cn/ac), for editing the English text of a draft of this manuscript.

Authors' contributions: Zhuang A analyzed and interpreted the patient data. Sun J reviewed and revised the manuscript. Shi WD performed the surgeries, and was a major contributor in writing the manuscript. All the authors read and approved the final manuscript.

Foundations: Supported by the National Natural Science Foundation of China (No.81600766; No.31600971); Shanghai Key Laboratory of Orbital Diseases and Ocular Oncology, the Science and Technology Commission of Shanghai (No.17DZ2260100); Shanghai Young Doctor Training Program.

Conflicts of Interest: **Zhuang A**, None; **Sun J**, None; **Shi WD**, None.

REFERENCES

- 1 LaPiana FG. Management of occult atretic lacrimal puncta. *Am J Ophthalmol* 1972;74(2):332-333.
- 2 Pratt DV, Patrinely JR. Reversal of iatrogenic punctal and canalicular occlusion. *Ophthalmology* 1996;103(9):1493-1497.
- 3 Hur MC, Jin SW, Roh MS, Jeong WJ, Ryu WY, Kwon YH, Ahn HB. Classification of lacrimal punctal stenosis and its related histopathological feature in patients with epiphora. *Korean J Ophthalmol* 2017;31(5):375-382.
- 4 Ali MJ, Mishra DK, Baig F, Lakshman M, Naik MN. Punctal stenosis: histopathology, immunology, and electron microscopic features-a step toward unraveling the mysterious etiopathogenesis. *Ophthalmic Plast Reconstr Surg* 2015;31(2):98-102.
- 5 Mathew RG, Olver JM. Mini-monoka made easy: a simple technique for mini-monoka insertion in acquired punctal stenosis. *Ophthalmic Plast*

- Reconstr Surg* 2011;27(4):293-294.
- 6 Kim SE, Lee SJ, Lee SY, Yoon JS. Outcomes of 4-snip punctoplasty for severe punctal stenosis: measurement of tear *Meniscus height* by optical coherence tomography. *Am J Ophthalmol* 2012;153(4):769-773.e1-2.
- 7 Koh CH, La TY. Treatment of punctal occlusion using pigtail probe. *Ophthalmic Plast Reconstr Surg* 2013;29(2):139-142.
- 8 Mombaerts I, Colla B. Modified Jones' lacrimal bypass surgery with an angled extended Jones' tube. *Ophthalmology* 2007;114(7):1403-1408.
- 9 Kashkouli MB, Nilforushan N, Nojomi N, Rezaee R. External lacrimal punctum grading: reliability and interobserver variation. *Eur J Ophthalmol* 2008;18(4):507-511.
- 10 Hotz FC. A new operation for entropion and trichiasis. *Arch Ophthalmol* 1879;8(6):249-263.
- 11 Asamura S, Kakizaki H, Shindou E, Itani Y, Isogai N. What is the best strategy for Asians with involutional entropion? *J Craniofac Surg* 2014;25(3):972-975.
- 12 Nesaratnam N, Emeriewen K, Smith J, David B, Wawrzynski J, Sharma A, Saleh GM. Scaling the punctum and canaliculus in patients undergoing punctoplasty surgery: a prospective cohort study. *Orbit* 2017; 36(6):436-440.
- 13 Awan KJ. Laser punctoplasty for the treatment of punctal stenosis. *Am J Ophthalmol* 1985;100(2):341-342.
- 14 Ali MJ, Ayyar A, Naik MN. Outcomes of rectangular 3-snip punctoplasty in acquired punctal stenosis: is there a need to be minimally invasive? *Eye (Lond)* 2015;29(4):515-518.
- 15 Caesar RH, McNab AA. A brief history of punctoplasty: the 3-snip revisited. *Eye (Lond)* 2005;19(1):16-18.
- 16 Fein W. Cautery applications to relieve punctal stenosis. *Arch Ophthalmol* 1977;95(1):145-146.
- 17 Kashkouli MB, Beigi B, Astbury N. Acquired external punctal stenosis: surgical management and long-term follow-up. *Orbit* 2005;24(2):73-78.
- 18 Wearne MJ, Beigi B, Davis G, Rose GE. Retrograde intubation dacryocystorhinostomy for proximal and midcanalicular obstruction. *Ophthalmology* 1999;106(12):2325-2328; discussion 2328-2329.
- 19 Na J, Lee S, Park J, Lee H, Baek S. Surgical outcomes of endonasal conjunctivodacryocystorhinostomy according to Jones tube location. *J Craniofac Surg* 2017;28(5):e500-e503.
- 20 Bagdonaite L, Pearson AR. Twelve-year experience of lester Jones tubes: results and comparison of 3 different tube types. *Ophthalmic Plast Reconstr Surg* 2015;31(5):352-356.
- 21 Shi W, Fan X. Incidence of postoperative obstruction at different sites of lacrimal canalicular injury. *Plast Reconstr Surg* 2012;129(4):731e-733e.
- 22 Zhuang A, Jin X, Li Y, Fan X, Shi W. A new method for locating the proximal lacerated bicanalicular ends in Chinese preschoolers and long-term outcomes after surgical repair. *Medicine (Baltimore)* 2017;96(33):e7814.
- 23 Hwang K. Surgical anatomy of the lower eyelid relating to lower blepharoplasty. *Anat Cell Biol* 2010;43(1):15-24.
- 24 Struck HG. Lacrimal system lacerations and their surgical repair. *Ophthalmologie* 2009;106(3):223-228.