

Mutation analysis of *FBN1* gene in two Chinese families with congenital ectopia lentis in northern China

Su-Zhen Tang¹, Ya-Ning Liu¹, Shao-Hua Hu¹, Hao Chen¹, Hui Zhao², Xue-Mei Feng¹, Xiao-Jing Pan³, Peng Chen¹

¹Department of Human Anatomy, Histology and Embryology, School of Basic Medicine, Qingdao University, Qingdao 266071, Shandong Province, China

²The 971 Hospital of the Chinese People's Liberation Army Navy, Qingdao 266071, Shandong Province, China

³Qingdao Eye Hospital, Shandong Eye Institute, Shandong First Medical University & Shandong Academy of Medical Sciences, Qingdao 266071, Shandong Province, China

Co-first authors: Su-Zhen Tang and Ya-Ning Liu

Correspondence to: Peng Chen. Department of Human Anatomy, Histology and Embryology, School of Basic Medicine, Qingdao University, 308 Ningxia Road, Qingdao 266071, Shandong Province, China. chenpeng599205@126.com; Xiao-Jing Pan. Qingdao Eye Hospital, Shandong Eye Institute, Shandong First Medical University & Shandong Academy of Medical Sciences, 5 Yan'er dao Road, Qingdao 266071, Shandong Province, China. panxjcrystal@163.com

Received: 2018-12-06 Accepted: 2019-06-12

Abstract

• **AIM:** To summarize the phenotypes and identify the underlying genetic cause of the *fibrillin-1* (*FBN1*) gene responsible for congenital ectopia lentis (EL) in two Chinese families in northern China.

• **METHODS:** A detailed family history and clinical data from all participants were collected by clinical examination. The candidate genes were captured and sequenced by targeted next-generation sequencing, and the results were confirmed by Sanger sequencing. Haplotyping was used to confirm the mutation sequence. Real-time PCR was used to determine the *FBN1* messenger ribonucleic acid (mRNA) levels in patients with EL and in unaffected family members.

• **RESULTS:** The probands and other patients in the two families were affected with congenital isolated EL. A heterozygous *FBN1* mutation in exon 21 (c.2420_IVS20-8 delTCTGAAACAinsCGAAAG) was identified in FAMILY-1. A heterozygous *FBN1* mutation in exon 14 (c.1633C>T, p.R545C) was identified in FAMILY-2. Each mutation cosegregated with the affected individuals in the family and did not exist in unaffected family members and 200 unrelated normal controls.

• **CONCLUSION:** The insertion-deletion mutation (c.2420 IVS20-8delTCTGAAACA insCGAAAG) in the *FBN1* gene is first identified in isolated EL. The mutation (c.1633C>T) in the *FBN1* gene was a known mutation in EL patient. The variable phenotypes among the patients expand the phenotypic spectrum of EL in a different ethnic background.

• **KEYWORDS:** congenital ectopia lentis; autosomal dominant; targeted next-generation sequencing; *FBN1*; fibrillin-1

DOI:10.18240/ijo.2019.11.02

Citation: Tang SZ, Liu YN, Hu SH, Chen H, Zhao H, Feng XM, Pan XJ, Chen P. Mutation analysis of *FBN1* gene in two Chinese families with congenital ectopia lentis in northern China. *Int J Ophthalmol* 2019;12(11):1674-1679

INTRODUCTION

Ectopia lentis (EL; OMIM 129600) is characterized by a displacement or malposition of the optic lens from its normal location and the zonular filaments are stretched or discontinued^[1]. Most EL cases are associated with Marfan syndrome (MFS; OMIM 154700), an autosomal dominant disease that includes cardiovascular, skeletal, and ocular system abnormalities^[2].

The clinical manifestations of isolated EL are mild or severe. The main symptoms include refractive error, amblyopia, complex glaucoma or retinal detachment. EL seriously affects visual quality. It is the second most frequent cause of lens surgery in juveniles^[3].

FBN1 is located on chromosome 15q21.1. Mutations in *FBN1* can cause isolated or predominant EL^[4]. Fibrillin 1 is a cysteine-rich glycoprotein that is broadly distributed in elastic and nonelastic connective tissues^[5-6].

Both syndromic and isolated EL have strong genetic heterogeneity. Pathogenic variants in *FBN1*^[7] can cause connective tissue disorders such as MFS and autosomal dominant EL. To date, the Universal Mutation Database (UMD)-*FBN1* database (<http://www.umd.be/FBN1/>) have registered over 600 *FBN1* mutations^[8]. It is vital to isolate EL and its related diseases by genotype and phenotype correlations. The study of molecular genetics of *FBN1*

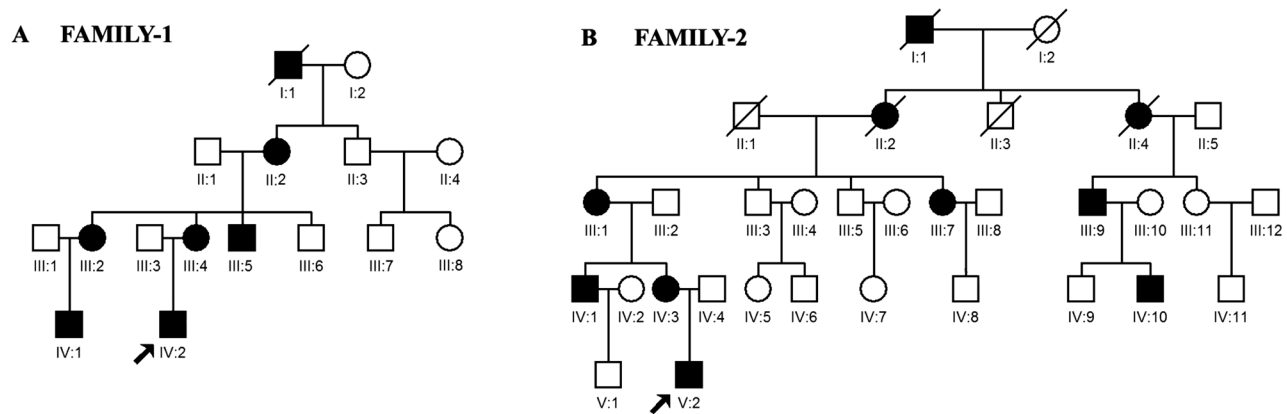


Figure 1 Pedigrees of the two Chinese families with autosomal dominant congenital ectopia lentis. Squares indicates males, and circles indicates females. The affected members are represented by filled symbols. Slashes (/) indicate the deceased individuals.

contributes to the development of prenatal diagnosis of this gene-related disease, and also contributes to the early diagnosis and risk prediction of high-risk patients.

Isolated EL pedigree has been reported many times in different races^[7-10]. Isolated EL may be an independent subtype caused by specific *FBNI* mutations or other regulatory factors. We recruited two Chinese pedigrees affected with isolated EL. Mutation in the *FBNI* gene (c.1633C>T) was reported in different races^[9]. The mutation (c.2420_IVS20-8delTCTGAAACA insCGAAAG) in *FBNI* was first discovered in EL patients. We conducted clinical and molecular genetic assessments in two Chinese families. However, the correlation between phenotype and genotype is important for understanding the pathogenesis of the disease, and the relevance of the two needs to be further clarified.

SUBJECTS AND METHODS

Ethical Approval The study was conducted in accordance with the principles of the Declaration of Helsinki. Informed consent was obtained from all the participants.

Clinical Examination The two autosomal dominant EL families came from Qingdao (Shandong Province, China). All family members included in the study had received comprehensive medical history review, ophthalmic examination. Two hundred individuals in the control group were healthy.

FAMILY-1 (four generations) had sixteen individuals (seven affected and nine unaffected, ten males and six females). There were thirty-two individuals in FAMILY-2 (five generations, ten affected and twenty-two unaffected, nineteen males and thirteen females). FAMILY-1 and FAMILY-2 family members do not have diseases of other systems other than the visual system.

Targeted Next-generation Sequencing Whole blood genomic DNA extraction was performed with DNA extraction kit (Tiangen, Beijing, China) from venous blood. Inheritable genetic vision system-related genes were captured as described^[10]. The probands (IV:2 in FAMILY-1, V:2 in FAMILY-2) underwent next-generation sequencing of the gene panel.

The biotinylated capture probes were used to enrich the exon regions of these 523 genes.

Variant Analysis and Verification According to the reference genome, data were analyzed and provided as described^[10]. After variant annotation, we primarily analyzed the nonsynonymous variants, coding indels, splice site variants. Exome data were filtered by the public databases (1000 Genomes Project, dbSNP, YH database, and HapMap 8 database).

Sanger sequencing was used to sequence the mutation sites selected by the filtration. Haplotyping was used to confirm the mutation sequence as described^[10].

Ribonucleic Acid Extraction and Real-time Polymerase Chain Reaction Real-time PCR was performed using SYBR Premix Ex Taq kit (Tiangen). *FBNI* primer sequences were 5'-CGCAACGCCGAATGCATCAA-3' (forward) and 5'-TGCAGCGGCAGTTGAAGGAA-3' (reverse). Glyceraldehyde-3-phosphate dehydrogenase (*GAPDH*) was assessed as described^[11].

RESULTS

Clinical Findings The two families in this study lived in northern China. FAMILY-1 was an autosomal dominant four-generation family with a total of 16 members, of which 6 were affected by bilateral congenital EL (Figure 1A, Figure 2). The right eye of II:2 had bullous keratopathy (Figure 2). Cataract were present in the left eyes of II:2 and III:2 and the right eye of III:4 (Figure 2). The onset age of patients with EL was around 8 to 15y. None of the affected members displayed cardiovascular or skeletal abnormalities, and other Marfan-related syndromes.

We identified another five-generation family with ten confirmed individuals affected with autosomal dominant EL (Figure 1B). Bilateral nasal dislocations were detected in the seven living patients (Figure 3). The onset age of patients with EL was around 6 to 17y.

Associated Gene *FBNI* A total of 523 inheritable genes were captured and sequenced by targeted next-generation

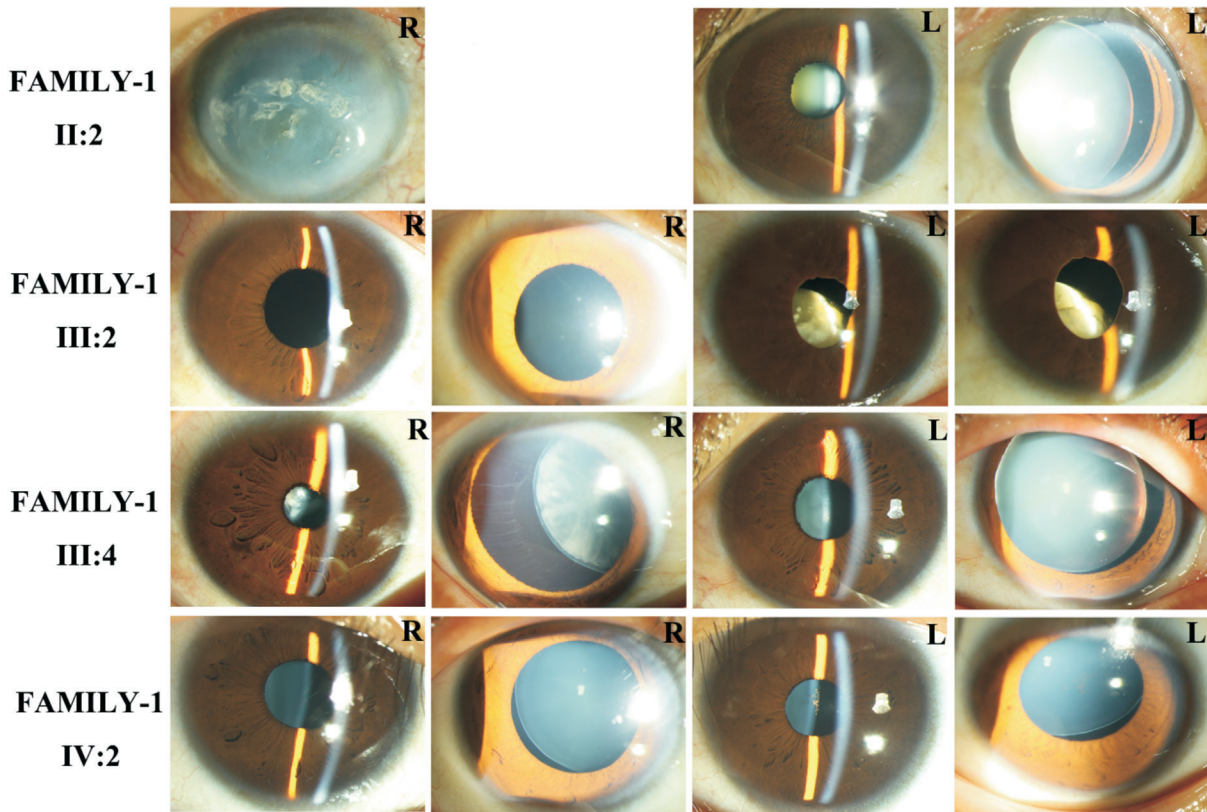


Figure 2 Photographs of patients in FAMILY-1 R: Right eye; L: Left eye.

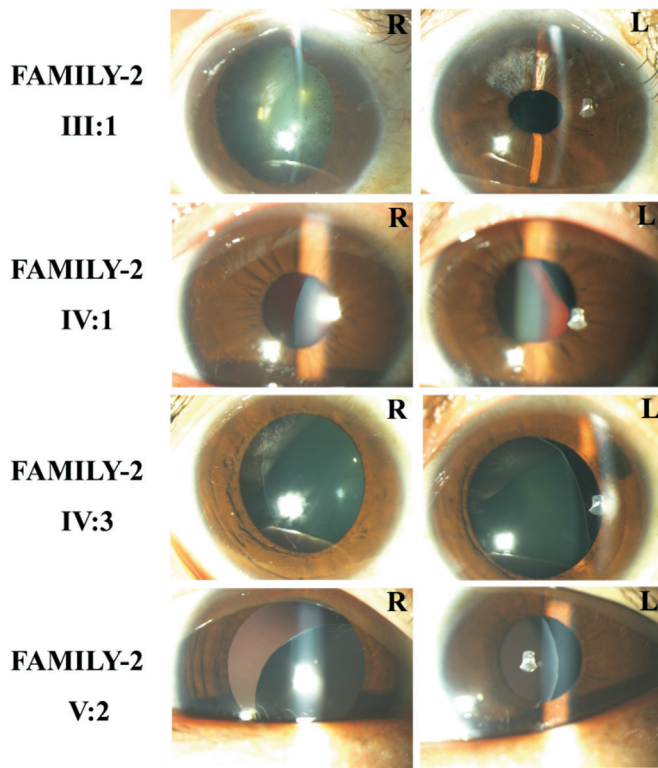


Figure 3 Photographs of the patients in FAMILY-2 R: Right eye; L: Left eye.

sequencing in the two probands (IV:2 in FAMILY-1, V:2 in FAMILY-2). The reads were mapped and analyzed by BWA (Burrows-Wheeler Alignment). IV:2 in FAMILY-1 had a mean depth of 54.1% and 84.52% of the exome sequences

were covered at 10× or more in the captured panel. V:2 in FAMILY-2 had a mean depth of 85.89% and 94.8% of the exome sequences were covered at 10× or more in the captured panel. There were 37 non-synonymous SNPs, 2 indels, and 4 splicing sites in IV:2 of FAMILY-1. There were 29 non-synonymous SNPs and 8 indels in V:2 of FAMILY-2.

Verification of Candidate Gene *FBN1* by Sanger Sequencing Only a heterozygous mutation (c.2420-IVS20-8delTCTGAAACAinsCGAAAG) was detected in exon 21 of the six affected individuals in FAMILY-1 (Figure 4) by using Sanger sequencing. Only a heterozygous mutation (c.1633C>T) was detected in exon 14 of the seven affected individuals in FAMILY-2 (Figure 5). The mutation resulted in the substitution of a arginine codon for a cysteine codon (p.Arg545Cys).

c.2420-IVS20-8delTCTGAAACAinsCGAAAG and c.1633C>T mutations were not detected in the normal family members and the 200 control subjects from the same ethnic background. Thus, the heterozygous c.2420-IVS20-8delTCTGAAACAinsCGAAAG and c.1633C>T mutation in *FBN1* were co-segregated with the dominant GL phenotype in their families.

***FBN1* Gene Expression in Patients with EL in FAMILY-1** *FBN1* mRNA expression was detected in EL patients and normal members in FAMILY-1. The level of *FBN1* mRNA in EL patients is 52% of that of unaffected members in the family ($P=0.01$).

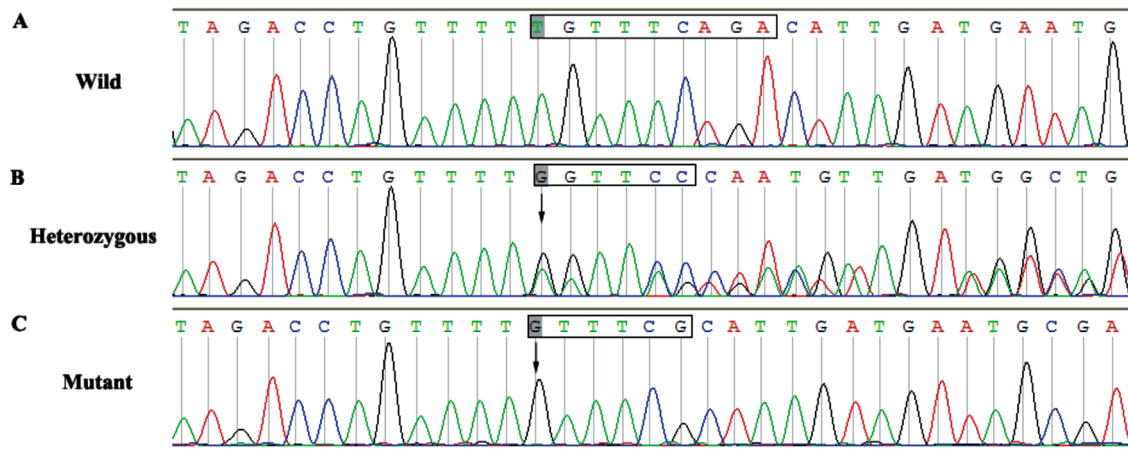


Figure 4 Sequence chromatograms of the detected fibrillin 1 mutations in FAMILY-1 A: The normal sequence of III:6; B: The heterozygous reading frame shift of IV:2; C: The haplotype sequence of the mutant sequence.

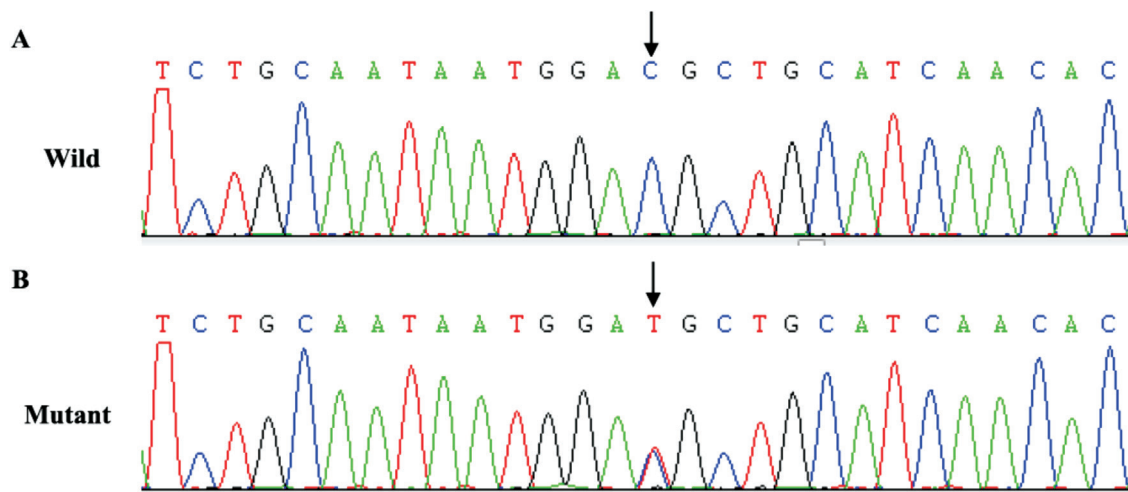


Figure 5 Sequence chromatograms of the detected fibrillin 1 mutations in FAMILY-2 A: The normal sequence of V:1; B: The heterozygote sequence of proband V:2.

DISCUSSION

It is suggested that lens ectopicity may not be an independent diagnosis, but may be a mild manifestation of a broad clinical symptom spectrum of MFS^[12-14]. In some cases, ectopic lens may be one of the signs of some syndromes, so metabolic screening and DNA testing have developed into an effective diagnostic method for distinguishing isolated EL from syndromes^[15-16]. By using next generation sequencing (NGS), multiple genes can be analyzed simultaneously and with high precision. The cost of this targeted approach has been greatly reduced, and the advantages of rapid detection and analysis are currently being used in standard clinical diagnostics. Differential diagnosis of EL and syndromic EL has important clinical significance, including patient prognosis, monitoring and prevention of potentially life-threatening complications. Moreover, genetic diagnosis of EL is critical to determining the genetic pattern and risk of recurrence of family members. In addition, a clear genetic diagnosis can help patients to

consider reproductive options, and help relatives to perform pre-symptomatic DNA testing. This study was performed in two EL families in northern China by using NGS.

A novel insertion deletion mutation (c.2420_IVS20-8 delTCTGAAACAinsCGAAAG, a heterozygous mutation) in *FBNI* gene in FAMILY-1 was reported in a Chinese family in this study. The insertion site found in FAMILY-1 is located in the cbEGF domain of *FBNI* protein, leading to early termination of translation and possibly affecting the binding of calcium to cbEGF. The clinical significance of this mutation is currently unknown, and further pedigree analysis and functional studies are needed to verify whether it is a pathogenic mutation. However, according to previous reports, the mutation has a high probability of pathogenicity. In addition, no similar nucleotide changes were detected in normal individuals in the family and 200 normal Chinese controls. And the mutation was filtered by the *FBNI* SNP database. Many *FBNI* mutations have been reported in the

Chinese population^[17], and the clinical phenotypes caused by various *FBN1* mutations are different. The missense mutation c.1633C>T in the *FBN1* gene has been reported in various ethnic backgrounds^[9,18].

In a MFS family, people with this mutation have three different cardinal phenotypes (aortic dissection, EL and unaffected)^[19].

FBN1, located on chromosome15q21, encodes a fibrinogen protein with a molecular weight of approximately 350-kDa. Fibrin-1 encoded by *FBN1* is the major structural element in the lens suspensory ligament. Fibrin-1 is involved in the formation of the lens suspensory ligament^[20], which is mainly secreted by non-pigment cells in the ciliary body.

FBN1 mutations can cause type 1 fibrillinopathies and MFS. Type 1 fibrillinopathies include Marchesani syndrome (MASS), isolated EL, isolated skeletal features of MFS, and thoracic aortic aneurysms^[21]. To date, over 600 mutations in *FBN1* have been reported. In addition to neonatal MFS, no correlation has been identified between genotypes/phenotypes^[22].

In addition, recent studies have shown that cysteine substitutions, rather than the location of amino acids in protein sequences, are closely related to isolated or predominant EL^[23].

In conclusion, we found a novel insertion deletion mutation (c.2420-IVS20-8delTCTGAAACA insCGAAAG, a heterozygous mutation) in *FBN1* gene in FAMILY-1 with congenital EL and a known point mutations (c.1633C>T). The results will provide a theoretical basis for expanding the spectrum of congenital EL and clarifying the relationship between EL genotype and phenotype.

ACKNOWLEDGEMENTS

Foundations: Supported by Natural Science Foundation of Shandong Province (No.ZR2018MH016); China Postdoctoral Science Foundation Funded Project (No.2017M612211); Medical Program of Shandong Province (No.2016WS0265); Qingdao Postdoctoral Application Research Project (No.40518060071); Qingdao Science and Technology Plan (No.16-6-2-14-nsh).

Conflicts of Interest: Tang SZ, None; Liu YN, None; Hu SH, None; Chen H, None; Zhao H, None; Feng XM, None; Pan XJ, None; Chen P, None.

REFERENCES

- 1 Dietz HC, Pyeritz RE. Mutations in the human gene for fibrillin-1 (FBN1) in the Marfan syndrome and related disorders. *Hum Mol Genet* 1995;4(suppl_1):1799-1809.
- 2 von Kodolitsch Y, Robinson PN. Marfan syndrome: an update of genetics, medical and surgical management. *Heart* 2007;93(6):755-760.
- 3 Simon MA, Origlieri CA, Dinallo AM, Forbes BJ, Wagner RS, Guo SQ. New management strategies for ectopia lentis. *J Pediatr Ophthalmol Strabismus* 2015;52(5):269-281.
- 4 Dietz HC, Cutting GR, Pyeritz RE, Maslen CL, Sakai LY, Corson GM,

Puffenberger EG, Hamosh A, Nanthakumar EJ, Curristin SM. Marfan syndrome caused by a recurrent de novo missense mutation in the fibrillin gene. *Nature* 1991;352(6333):337-339.

5 Robinson PN, Godfrey M. The molecular genetics of Marfan syndrome and related microfibrilopathies. *J Med Genet* 2000;37(1):9-25.

6 Schrenk S, Cenzi C, Bertalot T, Conconi MT, Di Liddo R. Structural and functional failure of fibrillin-1 in human diseases (review). *Int J Mol Med* 2018;41(3):1213-1223.

7 Hayward C, Brock DJ. Fibrillin-1 mutations in Marfan syndrome and other type-1 fibrillinopathies. *Hum Mutat* 1997;10(6):415-423.

8 Stheneur C, Collod-Bérout G, Faivre L, Buyck JF, Gouya L, Le Parc JM, Moura B, Muti C, Grandchamp B, Sultan G, Claustres M, Aegerter P, Chevallier B, Jondeau G, Boileau C. Identification of the minimal combination of clinical features in probands for efficient mutation detection in the FBN1 gene. *Eur J Hum Genet* 2009;17(9):1121-1128.

9 Aalberts JJ, van Tintelen JP, Meijboom LJ, Polko A, Jongbloed JD, van der Wal H, Pals G, Osinga J, Timmermans J, de Backer J, Bakker MK, van Veldhuisen DJ, Hofstra RM, Mulder BJ, van den Berg MP. Relation between genotype and left-ventricular dilatation in patients with Marfan syndrome. *Gene* 2014;534(1):40-43.

10 Du XL, Chen P, Sun DP. Mutation analysis of TGFBI and KRT12 in a case of concomitant keratoconus and granular corneal dystrophy. *Albrecht Von Graefes Arch Fur Klinische Und Exp Ophthalmol* 2017;255(9):1779-1786.

11 Sun DP, Dai YH, Pan XJ, Shan T, Wang DQ, Chen P. A Chinese family with Axenfeld-Rieger syndrome: report of the clinical and genetic findings. *Int J Ophthalmol* 2017;10(6):847-853.

12 Pepe G, Lapini I, Evangelisti L, Attanasio M, Giusti B, Lucarini L, Fattori R, Pellicanò G, Scrivanti M, Porciani MC, Abbate R, Gensini GF. Is ectopia lentis in some cases a mild phenotypic expression of Marfan syndrome? Need for a long-term follow-up. *Mol Vis* 2007;13:2242-2247.

13 Chandra A, Aragon-Martin JA, Hughes K, Gati S, Reddy MA, Deshpande C, Cormack G, Child AH, Charteris DG, Arno G. A genotype-phenotype comparison of ADAMTSL4 and FBN1 in isolated ectopia lentis. *Invest Ophthalmol Vis Sci* 2012;53(8):4889-4896.

14 Loeys BL, Dietz HC, Braverman AC, Callewaert BL, De Backer J, Devereux RB, Hilhorst-Hofstee Y, Jondeau G, Faivre L, Milewicz DM, Pyeritz RE, Sponseller PD, Wordsworth P, De Paepe AM. The revised Ghent nosology for the Marfan syndrome. *J Med Genet* 2010;47(7):476-485.

15 Cruysberg JR, Boers GH, Trijbels JM, Deutman AF. Delay in diagnosis of homocystinuria: retrospective study of consecutive patients. *BMJ* 1996;313(7064):1037-1040.

16 Zadeh N, Bernstein JA, Niemi AK, Dugan S, Kwan A, Liang D, Hyland JC, Hoyme HE, Hudgins L, Manning MA. Ectopia lentis as the presenting and primary feature in Marfan syndrome. *Am J Med Genet A* 2011;155A(11):2661-2668.

17 Peng Q, Deng Y, Yang Y, Liu HM. A novel fibrillin-1 gene missense mutation associated with neonatal Marfan syndrome: a case report and review of the mutation spectrum. *BMC Pediatr* 2016;16:60.

- 18 Robinson DO, Lin F, Lyon M, Raponi M, Cross E, White HE, Cox H, Clayton-Smith J, Baralle D. Systematic screening of FBN1 gene unclassified missense variants for splice abnormalities. *Clin Genet* 2012;82(3):223-231.
- 19 Li YP, Xu JH, Chen MJ, Du BB, Li QL, Xing QH, Zhang YZ. A FBN1 mutation association with different phenotypes of Marfan syndrome in a Chinese family. *Clin Chim Acta* 2016;460:102-106.
- 20 Whiteman P, Handford PA. Defective secretion of recombinant fragments of fibrillin-1: implications of protein misfolding for the pathogenesis of Marfan syndrome and related disorders. *Hum Mol Genet* 2003;12(7):727-737.
- 21 Sakai LY, Keene DR, Renard M, De Backer J. FBN1: the disease-causing gene for Marfan syndrome and other genetic disorders. *Gene* 2016;591(1):279-291.
- 22 Tiecke F, Katzke S, Booms P, Robinson PN, Neumann L, Godfrey M, Mathews KR, Scheuner M, Hinkel GK, Brenner RE, Hövels-Gürich HH, Hagemeyer C, Fuchs J, Skovby F, Rosenberg T. Classic, atypically severe and neonatal Marfan syndrome: twelve mutations and genotype-phenotype correlations in FBN1 exons 24-40. *Eur J Hum Genet* 2001;9(1):13-21.
- 23 Faivre L, Collod-Beroud G, Loeys BL, *et al.* Effect of mutation type and location on clinical outcome in 1, 013 probands with Marfan syndrome or related phenotypes and FBN1 mutations: an international study. *Am J Hum Genet* 2007;81(3):454-466.