

Primary implantation of non-valved glaucoma-drainage-device in sulcus in iridocorneal endothelial syndrome

Vanita Pathak Ray¹, Divya P Rao², Isha Gulati²

¹Centre For Sight, Banjara Hills, Hyderabad 500034, India

²L V Prasad Eye Institute, Banjara Hills, Hyderabad 500034, India

Correspondence to: Vanita Pathak Ray. Centre For Sight, Road No.2, Banjara Hills, Hyderabad 500034, India. vpathakray@gmail.com

Received: 2019-02-14 Accepted: 2019-03-07

DOI:10.18240/ijo.2019.11.23

Citation: Pathak Ray V, Rao DP, Gulati I. Primary implantation of non-valved glaucoma-drainage-device in sulcus in iridocorneal endothelial syndrome. *Int J Ophthalmol* 2019;12(11):1809-1811

Dear Editor,

Iridocorneal endothelial syndrome (ICE) is a rare, usually unilateral, acquired condition, hypothesized to be secondary to a viral etiology^[1]. It affects females more often than males and comprises of three distinct clinical types related to endothelial proliferation and its structural abnormalities. Proliferation of endothelium over the iridocorneal angle leads to progressive secondary angle closure and that over the iris leads to typical changes of polycoria and atrophy. Three clinical entities included in the syndrome are Chandlers (predominant corneal involvement), progressive iris atrophy (predominant iris involvement with polycoria and 'holes') and Cogan Reese (iris nodules with loss of stromal features). No matter what the clinical type, it is a progressive condition and controlling intraocular pressure (IOP) and maintaining corneal clarity in the long term is usually a challenge.

When glaucoma becomes medically refractory, as it frequently does, then surgical management is indicated. Trabeculectomy with anti-fibrotics have been tried; one study reported failure in one-third and loss of corneal clarity in half of the cohort consisting of 16 eyes, with an average of 1.3 (SD 0.5) glaucoma surgeries per eye^[2]. Yet others have met with a little more success (8 out of 10 eyes)^[3]. Nonetheless Doe *et al*^[4] have reported a decline in success rate to 29% at 5y (vs 73% at 1y) in the group receiving trabeculectomy with anti-fibrotics; in the same study success rate was almost double in the group that had a glaucoma drainage device (GDD) implanted (53% at 5y).

Each eye in our small series presented with uncontrolled IOP and corneal edema and were referred for combined glaucoma and corneal surgery. Presence of corneal edema precluded acquisition of specular image of the endothelium. Nonetheless, we chose to use our above-mentioned approach (primary non-valved GDD surgery, tube implanted in the sulcus), having counselled each patient for possible need of a second procedure (keratoplasty). We implanted Aurolab Aqueous Drainage Implant (AADI, Aurolab, India) which is a relatively new, affordable non-valved GDD, the design inspiration of which is the Baerveldt Glaucoma Device 350 mm². Lens extraction with in-the-bag IOL was also performed for eyes with cataract. All patients gave informed consent for the surgery and ethical principles as laid down by the tenets of the Declaration of Helsinki, were adhered to.

Routine non-valved AADI surgery was performed^[5]; notably tube was occluded with non-permanent 6/0 polyglactin suture and 4 pairs of fenestrating vents were made anterior to the occlusive ligature. All plates were positioned in the supero-temporal pocket and fixed to the sclera 10 mm from the limbus; entry into the posterior chamber (PC) was made 2 mm posterior to the limbus and parallel to the iris. A corneal or scleral patch graft was then either glued or sutured and conjunctiva closed.

A total of 7 eyes of 6 patients of ICE with corneal edema and uncontrolled IOP, underwent AADI with sulcus placement of tube in the study period of July 2014 to January 2017. However, 3 eyes had previous filtration surgery and were therefore excluded. Four eyes of 3 patients with primary AADI surgery with tube placed in sulcus, were included with a median follow up of 14mo. All were females and one had bilateral ICE (Figure 1A, 1B).

Median age was 45y (Q1 32.7, Q3 48; IQR 15.3). One eye was pseudophakic, whereas the rest presented with early cataract, so underwent routine phaco surgery with in-the-bag IOL for unhindered positioning of the tube in the sulcus. The pre-operative uncontrolled median IOP 45 mm Hg [Q1 36, Q3 47; IQR 11, 95%CI (29.2, 54.8)] on median 4 [Q1 4, Q3 5; IQR 1, 95%CI (2.2, 5.3)] number of anti-glaucoma medication (AGM) was significantly lower at last follow-up -11.5 mm Hg [Q1 5, Q3 9; IQR 14, 95%CI (5.77, 20.73)] on median 0 AGM [Q1 0, Q 1.5; IQR 1.5, 95%CI (-1.2, 1.2)] ($P<0.001$). No intra-operative or postoperative complications occurred. One eye

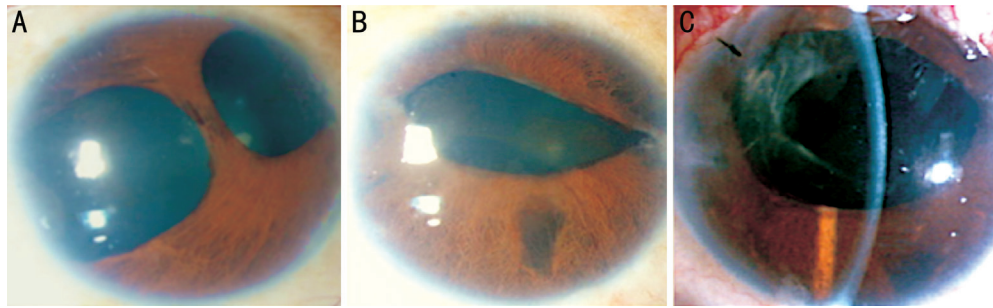


Figure 1 Bilateral ICE with bilateral corneal edema, more in left eye (A, B); postoperative (3wk) clear cornea of same eye as 1B, with AADI tube in sulcus (C).

had hypertensive phase at 3mo; bleb was tense around plate with increased IOP requiring AGM.

Although, median logMAR best corrected visual acuity (BCVA) remained unchanged ($P=0.5$) both eyes of the patient with bilateral ICE (Figure 1) with very advanced glaucoma had preservation of central vision (count fingers and hand movements in right and left eye respectively), but BCVA of the rest two eyes improved.

BCVA of the eye in Figure 2 improved from 20/30 to 20/20; contributory factors for improvement were resolved corneal edema with controlled IOP and cataract extraction. Humphrey Field Analysis (HFA) 24-2 was done pre-operatively and Mean deviation (MD) was recorded as -18.29 in this eye. Visual acuity in the pseudophakic eye with ICE improved from 20/200 to 20/50. This improvement was attributed to resolution of corneal edema with control of IOP. HFA 24-2 was done pre-operatively and MD was recorded as -9.9. Visual field remained stable post-surgery for both these eyes.

We did not encounter blockage, retraction or migration of tube and there were no re-procedures or tube revision surgeries required in these cases. Most notably, corneal edema resolved in all eyes (Figures 1C and Figure 2).

In the study reported by Doe *et al*^[4], the group that received GDD had 6 eyes with primary tube surgery, and though not analysed separately by the authors themselves, 5 eyes had IOP control with clear cornea at last follow-up. Therefore, intuitively, it would appear that a GDD may be a better option but success in terms of IOP control alone may not translate into one that encompasses corneal clarity too. This was the experience of Kim *et al*^[6] who had 70% success rate at 55mo with GDD surgery, albeit with a few tube revisions but they found that maintaining corneal clarity was a challenge. The 60% of eyes in their series decompensated; of a further 3 eyes which had grafts, one failed. All eyes in their series were phakic and all tubes were placed in the anterior chamber (AC) and 80% patients in their cohort had previous trabeculectomy, 60% with anti-fibrotics.

In view of these findings we hypothesized that a primary implantation of GDD in sulcus may not just have the advantage

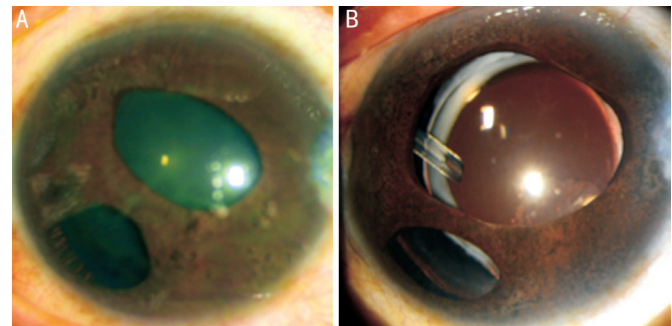


Figure 2 Essential iris atrophy of ICE A: Pre-operative corneal edema with hazy details of the iris; B: AADI tube in sulcus and clear cornea (2y postoperative).

of IOP control but could also serve the following purposes. It would be farthest away from the corneal endothelium, as far as possible by an anterior approach, thereby retarding loss of endothelial cells compared to one placed in the AC. Furthermore, in the PC, it would also be away from the proliferating endothelium, minimizing any chance of significant retraction or migration with subsequent need for repositioning, as reported by Doe *et al*^[4] and Kim *et al*^[6].

As IOP rise in ICE is chronic in nature, it is commonly believed that loss of corneal clarity prior to any intervention is likely due to endothelial failure. Yet with control of IOP alone we achieved and maintained clear corneas in all cases till last follow-up. This not only helped avoid unnecessary surgery in the first instance, but also deferred keratoplasty indefinitely. We, therefore, strongly recommend surgical control of IOP first and foremost with primary GDD surgery with tube in sulcus. The eye needs to be pseudophakic for this purpose and presence of cataract in phakic eyes, in our series, aided the process. We realise that this may become a contentious issue should cataract not be present.

Our series of ICE eyes with uncontrolled IOP and corneal edema, referred for combined glaucoma and corneal surgery, did well with control of IOP alone with non-valved GDD in sulcus as primary surgery. We recognise that our series is very small with limited follow-up. Nonetheless, it is a significant small and successful step, hitherto unreported, in a relatively rare condition known to be difficult-to-treat.

ACKNOWLEDGEMENTS

Conflicts of Interest: Pathak Ray V, None; Rao DP, None; Gulati I, None.

REFERENCES

- 1 Walkden A, Au L. Iridocorneal endothelial syndrome: clinical perspectives. *Clin Ophthalmol* 2018;12:657-664.
- 2 Chandran P, Rao HL, Mandal AK, Choudhari NS, Garudadri CS, Senthil S. Outcomes of primary trabeculectomy with mitomycin-C in glaucoma secondary to iridocorneal endothelial syndrome. *J Glaucoma* 2016;25(7):e652-e656.
- 3 Lanzl IM, Wilson RP, Dudley D, Augsburger JJ, Aslanides IM, Spaeth GL. Outcome of trabeculectomy with mitomycin-C in the iridocorneal endothelial syndrome. *Ophthalmology* 2000;107(2):295-297.
- 4 Doe EA, Budenz DL, Gedde SJ, Imami NR. Long-term surgical outcomes of patients with glaucoma secondary to the iridocorneal endothelial syndrome. *Ophthalmology* 2001;108(10):1789-1795.
- 5 Pathak Ray V, Rao DP. Surgical outcomes of a new affordable non-valved glaucoma drainage device and Ahmed glaucoma valve: comparison in the first year. *Br J Ophthalmol* 2018;bjophthalmol-bjophtha 2017-311716.
- 6 Kim DK, Aslanides IM, Schmidt CM Jr, Spaeth GL, Wilson RP, Augsburger JJ. Long-term outcome of aqueous shunt surgery in ten patients with iridocorneal endothelial syndrome. *Ophthalmology* 1999;106(5):1030-1034.