

# The effects of implantable collamer lens implantation on higher order aberrations

Belma Kayhan<sup>1,2</sup>, Efehan Coskunseven<sup>1</sup>, Onurcan Sahin<sup>1,3</sup>, Ioannis Pallikaris<sup>1,3</sup>

<sup>1</sup>Dunyagoz Hospital Group, Istanbul 34337, Turkey

<sup>2</sup>Department of Ophthalmology, Sultan Abdulhamid Han Training and Research Hospital, the University of Saglik Bilimleri, Istanbul 34668, Turkey

<sup>3</sup>Institute of Vision and Optics, University of Crete, Heraklion 70013, Greece

**Correspondence to:** Belma Kayhan. Department of Ophthalmology, Sultan Abdulhamid Han Training and Research Hospital, Tibbiye Street, Selimiye, Uskudar, Istanbul 34668, Turkey. drbelmakayhan@gmail.com

Received: 2019-02-26 Accepted: 2019-04-30

## Abstract

• **AIM:** To evaluate the changes in higher order aberrations (HOAs) after implantable collamer lens (ICL; Staar Surgical, Nidau, Switzerland) implantation.

• **METHODS:** Totally 30 eyes of 18 patients with myopia were included in this study with an average age of 25.77y (min: 21, max: 40). Refraction, uncorrected distance visual acuity (UDVA), corrected distance visual acuity (CDVA), HOAs (entire, corneal and internal) were evaluated preoperatively and three months postoperatively. Ocular aberrations were measured by using iTrace (Tracey Technology, Houston, Texas, USA). SPSS (IBM Corp. Released 2013. IBM SPSS Statistics for Windows, Version 22.0. Armonk, NY: IBM Corp) was used for the statistical analysis and the interpretation of the data. *P* values of less than 0.05 were considered statistically significant.

• **RESULTS:** The preoperative mean spherical power was -9.01 D (min: -5.00, max: -13.00) and the mean cylindrical error was -2.40 D (min: -0.50, max: -4.75). The postoperative mean residual spherical power was -0.73 D (min: -0.20, max: -1.75) and the mean cylindrical error was -0.89 D (min: -0.18, max: -2.09). Analyses were made on root mean square (RMS) values of total HOAs (tHOAs), spherical aberration, coma and trefoil as entire, corneal and internal components. The differences in entire tHOAs and in internal tHOAs were significant. There was no significant change found in spherical aberrations. The differences in entire coma and in internal coma were significant. There was no significant change found in corneal coma. With respect to trefoil, the only significant difference was in internal trefoil.

• **CONCLUSION:** The ICL implantation corrects the refractive error successfully and changes entire and internal HOAs of the eye.

• **KEYWORDS:** implantable collamer lens; myopia; aberrations

**DOI:10.18240/ijo.2019.12.05**

**Citation:** Kayhan B, Coskunseven E, Sahin O, Pallikaris I. The effects of implantable collamer lens implantation on higher order aberrations. *Int J Ophthalmol* 2019;12(12):1848-1852

## INTRODUCTION

Uncorrected refractive error is the leading cause of visual impairment in the world<sup>[1]</sup>. Studies revealed that the prevalence of myopia continues to increase<sup>[2]</sup>. Therefore, the treatment of this refractive error is very important. Corneal refractive surgery is the most preferred treatment for the low and moderate myopia. However, the high myopia and the moderate myopia with corneas which are not suitable for corneal refractive surgery because of thickness and/or keratometric values, can be treated with the phakic intraocular lens (IOL) implantation. The popularity of the phakic IOLs is increasing as many studies have shown very good refractive outcomes, predictability and safety<sup>[3-6]</sup>. Visian implantable collamer lens (ICL; Staar Surgical, Nidau, Switzerland) is the widely used posterior chamber phakic IOL which is also approved by the Food and Drug Administration (FDA).

Several studies reported that higher order aberrations (HOAs) play a major role in the visual quality<sup>[7-11]</sup>. In the evaluation of the outcomes of the refractive treatments, correction of refractive error and changes of HOAs have been taken into consideration for satisfaction. These data led to customized corneal refractive treatments such as wavefront-guided, wavefront-optimized ablations to induce lower HOAs. With ICL implantation, we add a new optical component to internal optics of the eye. While this new component changes the refraction of the eye, it probably changes other optical properties of the visual system. By using Ray Tracing technology (iTrace, Tracey Technology, Houston, Texas, USA), we are able to measure entire eye aberrations, corneal aberrations and internal aberrations, which are obtained by subtracting corneal aberrations from entire eye aberrations. In this study, we aimed to investigate the effects of ICL

implantation on HOAs of cornea, internal ocular optics as well as entire eye, by applying Ray Tracing technology.

## SUBJECTS AND METHODS

**Ethical Approval** This retrospective study was conducted in accordance with the Declaration of Helsinki (2008) and was approved by the Institutional Ethics Review Committee of Dunyagoz Hospital Group. Written informed consent was obtained from all participating individuals.

This retrospective study comprised 30 eyes of 18 patients which underwent ICL implantation for myopia at Dunyagoz Etiler Hospital, Istanbul, Turkey, in 2016. Both eyes of 12 patients and one eye of 6 patients (3 eyes were right, 3 eyes were left) were included in the study. The data were obtained preoperatively and 3mo after the operation. Preoperative ophthalmic examinations consisted of detailed medical history, manifest and cycloplegic refractions, uncorrected distance visual acuity (UDVA) and corrected distance visual acuity (CDVA) measurements by using Snellen chart, anterior segment examination with slit-lamp biomicroscopy and detailed fundus examination. In addition to these routine examinations, Orbscan (Bausch & Lomb, Rochester, New York, USA) was used for corneal topographic, horizontal white to white (WTW) distance and anterior chamber depth (ACD) measurements. The SP 3000P specular microscope (Topcon Corporation, Tokyo, Japan) was used for endothelial cell count. Corneal thickness was measured by Pentacam (Oculus Optikgeräte, Wetzlar, Germany).

The inclusion criteria of the study were the age older than 21 years old, stable refraction at least 1y, endothelial cell count of greater than 2400 endothelial cells/mm<sup>2</sup>, no iris abnormality and no pupil dysfunction, ACD greater than 2.8 mm and mesopic pupil smaller than 5 mm. Refractive instability, active corneal diseases, irregular cornea on topography, lens opacities, active, recurrent or chronic uveitis, glaucoma, previous corneal or intraocular surgery, history of ocular trauma, systemic diseases and age younger than 21y were criteria for the exclusion.

Ocular aberrations were measured by using iTrace (Tracey Technology, Houston, Texas, USA) before surgery and three months after surgery by the same person. Zernike coefficients in 3 mm pupil diameters were evaluated for comparison.

The STAAR Surgical Customer Service Department formula was used to calculate the ICL power. ACD calculated from the corneal endothelium, central corneal thickness, mean corneal keratometry, refraction measured 12 mm away from corneal vertex, and horizontal WTW distance were parameters for this formula.

Nd:YAG laser peripheral iridotomies were done 1d before ICL implantation as the surgeon preferred this timing to clean the iris particules during surgery with anterior chamber washing.

The 11- and 1-o'clock positions in the iris were chosen for iridotomies which were 0.5 to 1 mm away from the limbus. Pilocarpine 2% solution was instilled 3 times with 10min intervals during 30min before the laser procedure.

All surgeries were performed by the same surgeon (Coskunseven E). The operations were performed under general anesthesia with the same disinfecting, draping, and eye stabilizing techniques of cataract surgery. Two side port incisions were made and cohesive ophthalmic viscosurgical device of sodium hyaluronate 1.0% was injected. A 2.8 mm main incision was made on the temporal side. The ICL was injected through the tunnel by cartridge and footplates were inserted behind the iris in the correct position. The ophthalmic viscosurgical device was irrigated by cannula. Following acetylcholine chloride injection, incision edges were hydrated. One 250 mg acetazolamide tablet was given at the second hour of surgery. The intraocular pressure follow-up was made at 2<sup>nd</sup> and 4<sup>th</sup> hours as a regular procedure. Postoperative medication was topical moxifloxacin and dexamethasone four times a day.

**Statistical Analysis** SPSS (IBM Corp. Released 2013. IBM SPSS Statistics for Windows, Version 22.0. Armonk, NY: IBM Corp) was used for the statistical analysis and the interpretation of the data. Kolmogorov-Smirnov and Shapiro-Wilk test for testing the normal distribution and Levene's test for testing the equality of variances were used. Furthermore, two-tailed paired samples *t*-test (For normally distributed data) and Wilcoxon signed rank test (Not normally distributed data) were applied for analyses differences for the comparison of the results across the pre and the post operation. *P* values of less than 0.05 were considered statistically significant.

## RESULTS

The preoperative mean spherical power was -9.01 D (min: -5.00, max: -13.00, SD: 2.18) and the mean cylindrical error was -2.40 D (min: -0.50, max: -4.75, SD: 1.22). The postoperative mean residual spherical power was -0.73 D (min: -0.20, max: -1.75, SD: 0.48) and the mean cylindrical error was -0.89 D (min: -0.18, max: -2.09, SD: 0.50). The mean difference of spherical power was 8.72 D and the difference was statistically significant ( $t=21.69$ ,  $P<0.001$ ). The mean difference of cylindrical power was 1.51 D and the difference was statistically significant ( $t=6.63$ ,  $P<0.001$ ).

Visual acuity was recorded as decimal units. The mean preoperative UDVA was 0.05 (range 0.025 to 0.1) and the mean postoperative UDVA was 0.8 (range 0.5 to 1.0). At the 3<sup>rd</sup> month, 93% of patients had a UDVA of 0.6 or better and 46% had 0.8 or better. The mean preoperative CDVA was 0.8 (0.4 to 1.0) and the mean postoperative CDVA was 0.9 (range 0.6 to 1.0). At the 3<sup>rd</sup> month, 90% of patients had a CDVA of 0.8 or better and 56% had 1.0 or better (Figure 1).

**Table 1 tHOAs**

Parameters	Entire tHOAs Preop./3 <sup>rd</sup> month	Corneal tHOAs Preop./3 <sup>rd</sup> month	Internal tHOAs Preop./3 <sup>rd</sup> month
Paired samples statistics			
Mean	0.159/0.097	0.064/0.079	0.165/0.107
<i>n</i>	30/30	30/30	30/30
SD	0.095/0.038	0.032/0.069	0.088/0.056
Standart error mean	0.017/0.007	0.006/0.013	0.016/0.010
Correlation	0.370	0.064	0.430
Significance	0.044	0.736	0.018
Paired samples test			
Mean difference	0.062	-0.014	0.058
<i>t</i>	3.824	-1.066	3.893
Degrees of freedom	29	29	29
Significance (2-tailed)	0.001	0.295	0.001

tHOAs: Total higher order aberrations; SD: Standard deviation.

**Table 2 Coma**

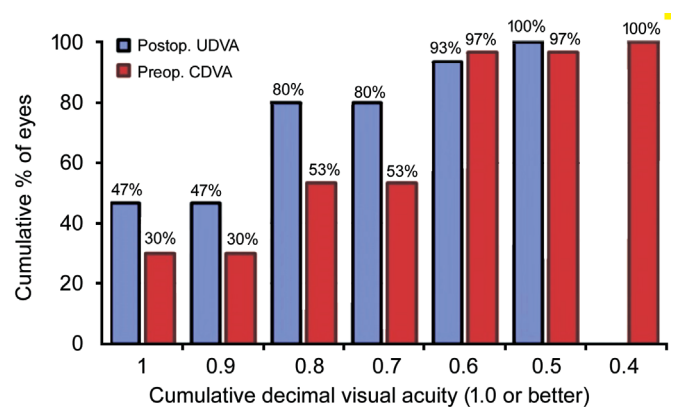
Parameters	Entire coma Preop./3 <sup>rd</sup> month	Corneal coma Preop./3 <sup>rd</sup> month	Internal coma Preop./3 <sup>rd</sup> month
Paired samples statistics			
Mean	0.091/0.052	0.034/0.045	0.120/0.061
<i>n</i>	30/30	30/30	30/30
SD	0.075/0.032	0.022/0.038	0.158/0.046
Standart error mean	0.014/0.006	0.004/0.007	0.029/0.008
Correlation	0.342	-0.085	-0.033
Significance	0.064	0.656	0.863
Paired samples test			
Mean difference	0.039	-0.011	0.060
<i>t</i>	3.042	-1.320	1.965
Degrees of freedom	29	29	29
Significance (2-tailed)	0.005	0.197	0.044

SD: Standard deviation.

Analyses of HOAs were made on root mean square (RMS) values of total HOAs (tHOAs), spherical aberration, coma and trefoil as entire, corneal and internal components. The differences in entire tHOAs and in internal tHOAs were significant. There was no significant change found in corneal tHOAs (Table 1).

There were no statistically significant differences between the spherical aberration values. The difference between total spherical aberrations was 0.01 ( $P>0.112$ ), corneal spherical aberrations 0.0009 ( $P>0.689$ ), internal spherical aberrations 0.001 ( $P>0.806$ ) respectively. The differences in entire coma and in internal coma were significant. There was no significant change found in corneal coma (Table 2).

In terms of trefoil, the only significant difference was in internal trefoil. There was no significant change found in entire and corneal trefoil (Table 3).



**Figure 1** Thirty eyes (plano target) 3mo postoperative UDVA.

**DISCUSSION**

Our study demonstrated very good outcomes of ICL implantation in the correction of moderate and high myopic and astigmatic refractive disorder and supported other similar

**Table 3 Trefoil**

Parameters	Entire trefoil Preop./3 <sup>rd</sup> month	Corneal trefoil Preop./3 <sup>rd</sup> month	Internal trefoil Preop./3 <sup>rd</sup> month
Paired samples statistics			
Mean	0.079/0.052	0.044/0.052	0.089/0.054
<i>n</i>	30/30	30/30	30/30
SD	0.071/0.029	0.028/0.056	0.064/0.035
Standart error mean	0.013/0.005	0.005/0.010	0.012/0.006
Correlation	-0.086	0.174	0.266
Significance	0.650	0.356	0.156
Paired samples test			
Mean difference	0.027	-0.008	0.036
<i>t</i>	1.877	-0.744	3.009
Degrees of freedom	29	29	29
Significance (2-tailed)	0.071	0.463	0.005

SD: Standard deviation.

studies<sup>[12-18]</sup>. Up to -13.00 D spherical and -4.75 D cylindrical errors were successfully corrected with the postoperative mean residual spherical power of -0.73 D and the mean cylindrical error of -0.89 D.

Besides the correction of the refractive error, the quality of vision is a matter of patient satisfaction as well. Our main purpose for this study was to evaluate the changes in HOAs after implantation of ICL, which has unique impact on the visual image quality. There are studies investigating changes induced by ICL implantation. Pérez-Vives *et al*<sup>[19]</sup> pointed that the myopic ICLs had negative spherical aberration. In their *in vitro* study, when the refractive power increased, spherical aberration was more negative for myopic ICLs and the values of other aberrations evaluated were minimal. Several *in vivo* studies also showed an increase in spherical aberrations after ICL implantation. In our study, we couldn't find any statistically significant difference between spherical aberration values. However, we found significant change in internal trefoil. In a study designed by Kim *et al*<sup>[20]</sup> ICL implanted eyes were divided into two groups: eyes with the small superior incision group (<3.2 mm) and eyes with the large superior incision group (3.2-4.5 mm). In the small incision group, they found significant trefoil and spherical aberration changes. In the large incision group, they detected significant tHOAs changes in addition to trefoil and spherical aberration. They explained these changes with incision size and negative spherical aberration in ICL. Shin *et al*<sup>[21]</sup> observed an increase in entire ocular and corneal trefoil-y in their study where they made a 3 mm clear corneal incision and they correlated these results to other studies reporting increase in trefoil due to incision size after Artisan and Artiflex Phakic IOL implantations. The study using adaptive-optics visual simulator compared the visual and optical quality between

the small incision and the large incision in 3 different powers of ICLs and stated that ICL provided good optical and visual quality, but these outcomes decreased with large incision surgery because of the increase of aberrations<sup>[22]</sup>. In our study, 2.8 mm temporal incision was made by the same surgeon in all eyes and in terms of trefoil, the only significant difference was in internal trefoil. There were no significant changes found in entire and corneal trefoil. This can be explained that our incision didn't affect corneal aberrations and internal trefoil change could be related to ICL itself or its positioning.

Igarashi *et al*<sup>[23]</sup> found that coma-like aberrations and tHOAs increased significantly in eyes undergoing ICL implantation and they assumed that these changes could be related to 3 mm corneal incision. In another study designed to compare HOAs between ICL implantation and wavefront guided LASIK, Liu *et al*<sup>[24]</sup> reported that none of HOAs parameters in the ICL group statistically changed after the operation at either 4 mm-pupil or 6 mm-pupil, except some higher order components such as trefoil, tetrafoil and 2<sup>nd</sup> astigmatism increased at 6 mm-pupil and they supposed that these changes were probably because of the relatively small optical zone of V4c model of ICL. Hashemian *et al*<sup>[25]</sup> stated no significant changes in HOAs after ICL implantation with the exception of significantly increased spherical aberration and they assumed that lens structure was responsible for this outcome. In our study, we evaluated aberration changes in cornea and in internal optics separately and found no corneal aberration changes. Therefore, significant changes in internal coma and internal tHOAs could be related to ICL itself and/or its positioning as in internal trefoil change.

Our study demonstrated changes in tHOAs, coma and trefoil in entire and internal components. With these outcomes, we can evaluate the optical effects of ICL implantation in detail. The

limitations of our study may be the subject number and the evaluation of the HOAs in only one pupil diameter.

### ACKNOWLEDGEMENTS

Presented in part at the Annual Meeting of American Academy of Ophthalmology (AAO) 2016, Chicago and at the XXXIV Congress of European Society of Cataract and Refractive Surgeons (ESCRS) 2016, Copenhagen.

**Conflicts of Interest:** Kayhan B, None; Coskunseven E, None; Sahin O, None; Pallikaris I, None.

### REFERENCES

- 1 Naidoo KS, Leasher J, Bourne RR, Flaxman SR, Jonas JB, Keeffe J, Limburg H, Pesudovs K, Price H, White RA, Wong TY, Taylor HR, Resnikoff S. Global vision impairment and blindness due to uncorrected refractive error, 1990-2010. *Optom Vis Sci* 2016;93(3):227-234.
- 2 Dolgin E. The myopia boom. *Nature* 2015;519(7543):276-278.
- 3 Sanders DR, Doney K, POCO M. ICL in Treatment of Myopia Study Group. United States Food and Drug Administration clinical trial of the implantable collamer lens (ICL) for moderate to high myopia: three-year follow-up. *Ophthalmology* 2004;111(9):1683-1692.
- 4 Elies D, Alonso T, Puig J, Gris O, Güell JL, Coret A. Visian toric implantable collamer lens for correction of compound myopic astigmatism. *J Refract Surg* 2010;26(4):251-258.
- 5 Coskunseven E, Kavadarli I, Sahin O, Kayhan B, Pallikaris I. Refractive outcomes of 20 eyes undergoing ICL implantation for correction of hyperopic astigmatism. *J Refract Surg* 2017;33(9):604-609.
- 6 Mirafteb M, Hashemi H, Asgari S. Matched optical quality comparison of 3-year results of PRK-MMC and phakic IOL implantation in the correction of high myopia. *Eye (Lond)* 2015;29(7):926-931.
- 7 Sharma M, Wachler BS, Chan CC. Higher order aberrations and relative risk of symptoms after LASIK. *J Refract Surg* 2007;23(3):252-256.
- 8 Chalita MR, Chavala S, Xu M, Krueger RR. Wavefront analysis in post-LASIK eyes and its correlation with visual symptoms, refraction, and topography. *Ophthalmology* 2004;111(3):447-453.
- 9 Li X, Wang Y, Dou R. Aberration compensation between anterior and posterior corneal surfaces after Small incision lenticule extraction and femtosecond laser-assisted laser *in situ* keratomileusis. *Ophthalmic Physiol Opt* 2015;35(5):540-551.
- 10 Shetty R, Matalia H, Nandini C, Shetty A, Khamar P, Grover T, Sinha Roy A. Wavefront-guided LASIK has comparable ocular and corneal aberrometric outcomes but better visual acuity outcomes than SMILE in myopic eyes. *J Refract Surg* 2018;34(8):527-532.
- 11 Tuan KM, Chernyak D, Feldman ST. Predicting patients' night vision complaints with wavefront technology. *Am J Ophthalmol* 2006;141(1):1-6.
- 12 Chen H, Liu Y, Feng X, Niu G, Fan Y. Long-term clinical observation of posterior chamber phakic intraocular lens implantation in young population. *Eye Contact Lens* 2018;44(Suppl 2):S365-S369.
- 13 Rayner SA, Bhikoo R, Gray T. Spherical implantable collamer lenses for myopia and hyperopia: 126 eyes with 1-year follow up. *Clin Exp Ophthalmol* 2010;38(1):21-26.
- 14 Kamiya K, Shimizu K, Igarashi A, Kitazawa Y, Kojima T, Nakamura T, Oka Y, Matsumoto R. Posterior chamber phakic intraocular lens implantation: comparative, multicentre study in 351 eyes with low-to-moderate or high myopia. *Br J Ophthalmol* 2018;102(2):177-181.
- 15 Fernández-Vega-cueto L, Lisa C, Esteve-Taboada JJ, Montés-Micó R, Alfonso J. Implantable collamer lens with central hole: 3-year follow-up. *Clin Ophthalmol* 2018;12:2015-2029.
- 16 Chen X, Wang XY, Zhang X, Chen Z, Zhou XT. Implantable collamer lens for residual refractive error after corneal refractive surgery. *Int J Ophthalmol* 2016;9(10):1421-1426.
- 17 Moya T, Javaloy J, Montés-Micó R, Beltrán J, Muñoz G, Montalbán R. Implantable collamer lens for myopia: assessment 12 years after implantation. *J Refract Surg* 2015;31(8):548-556.
- 18 Lee J, Kim Y, Park S, Bae J, Lee S, Park Y, Lee J, Lee JE. Long-term clinical results of posterior chamber phakic intraocular lens implantation to correct myopia. *Clin Exp Ophthalmol* 2016;44(6):481-487.
- 19 Pérez-Vives C, Domínguez-Vicent A, Ferrer-Blasco T, Madrid-Costa D, Montés-Micó R. Optical quality of hyperopic and myopic phakic intraocular lenses. *Indian J Ophthalmol* 2014;62(4):437-441.
- 20 Kim SW, Yang H, Yoon G, Lee YJ, Kweon MN, Kim JK, Seo KY. Higher-order aberration changes after implantable collamer lens implantation for myopia. *Am J Ophthalmol* 2011;151(4):653-662.e1.
- 21 Shin JY, Ahn H, Seo KY, Kim EK, Kim TI. Comparison of higher order aberrations after implantable collamer lens implantation and wavefront-guided LASEK in high myopia. *J Refract Surg* 2012;28(2):106-111.
- 22 Pérez-Vives C, Ferrer-Blasco T, Domínguez-Vicent A, García-Lázaro S, Montés-Micó R. Optical and visual quality of the visian implantable collamer lens using an adaptive-optics visual simulator. *Am J Ophthalmol* 2013;155(3):499-507.e1.
- 23 Igarashi A, Kamiya K, Shimizu K, Komatsu M. Visual performance after implantable collamer lens implantation and wavefront-guided laser *in situ* keratomileusis for high myopia. *Am J Ophthalmol* 2009;148(1):164-170.e1.
- 24 Liu HT, Zhou Z, Luo WQ, He WJ, Agbedia O, Wang JX, Huang JZ, Gao X, Kong M, Li M, Li L. Comparison of optical quality after implantable collamer lens implantation and wavefront-guided laser *in situ* keratomileusis. *Int J Ophthalmol* 2018;11(4):656-661.
- 25 Hashemian SJ, Farrokhi H, Foroutan A, Jafari ME, Hashemian SM, Alemzadeh SA, Hashemian MS. Ocular higher-order aberrations changes after implantable collamer lens implantation for high myopic astigmatism. *J Curr Ophthalmol* 2018;30(2):136-141.