

Chorioretinal response to intravitreal aflibercept injection in acute central serous chorioretinopathy

Byung Ju Jung, Kook Lee, Jin Hyung Park, Jae Hyung Lee

Department of Ophthalmology and Visual Science, Seoul St. Mary's Hospital, College of Medicine, the Catholic University of Korea, Seoul 06591, Korea

Correspondence to: Jae Hyung Lee. Department of Ophthalmology and Visual Science, Seoul St. Mary's Hospital, College of Medicine, the Catholic University of Korea, 505 Banpo-dong, Seocho-ku, Seoul 06591, Korea. voilaju@nate.com

Received: 2019-03-07 Accepted: 2019-06-13

Abstract

• **AIM:** To evaluate chorioretinal responses to intravitreal aflibercept injection (IAI) in patients with acute central serous chorioretinopathy (CSC).

• **METHODS:** Seventy-one eyes from 71 patients with symptomatic CSC for less than six months were included. Thirty-five eyes received a single IAI and 36 eyes were observed without treatment. Best-corrected visual acuity (BCVA), central subfield foveal thickness (CSFT), and subfoveal choroidal thickness (SFCT) were assessed at baseline and at 1, 2, and 3mo.

• **RESULTS:** The mean SFCT in the IAI group decreased at 1mo, rebounded at 2mo and remained stable at 3mo compared to the baseline, while significant change was not noted in the observation group. The mean CSFT decreased significantly during the 3-month study period in both groups, and was significantly lower in the IAI group at 1mo ($P<0.001$). A rebound of CSFT between 1 and 2mo was noted in 14 eyes (40.0%) in the IAI group and in 1 eye (2.8%) in the observation group ($P<0.001$). The significant visual improvement was achieved from 1mo in the IAI group, and from 2mo in the observation group. The rate of complete absorption of subretinal fluid at 3mo did not differ between the two groups. (45.7% vs 41.7%, $P=0.813$).

• **CONCLUSION:** A single IAI for acute CSC induce a transient decrease in SFCT and CSFT, which implies that IAI may have a pharmacological effect on the underlying hyperpermeable choroid in acute CSC.

• **KEYWORDS:** aflibercept; acute central serous chorioretinopathy; anti-vascular endothelial growth factor; choroidal hyperpermeability; choroidal thickness

DOI:10.18240/ijo.2019.12.08

Citation: Jung BJ, Lee K, Park JH, Lee JH. Chorioretinal response to intravitreal aflibercept injection in acute central serous chorioretinopathy. *Int J Ophthalmol* 2019;12(12):1865-1871

INTRODUCTION

Central serous chorioretinopathy (CSC) is characterized by serous neurosensory retinal detachment at the posterior pole of the retina by the retinal pigment epithelium (RPE) leakage^[1]. It was previously thought that the leakage from the RPE after a breakdown of the outer blood-retinal barrier was primarily involved in the pathophysiology of CSC. However, indocyanine-green angiography (ICGA) findings in CSC, which are characterized as delayed choroidal infusion, choroidal vascular hyperpermeability, and choroidal venous dilation suggest that the choroid is primarily involved in the pathophysiology^[2-3]. Studies using enhanced-depth imaging optical coherence tomography (OCT) have shown that subfoveal choroidal thickness (SFCT) in eyes with CSC was significantly larger than that of the unaffected eyes, or healthy normal controls^[4]. Additionally, topographic studies have shown a high level of correlation between thickened choroid on OCT and choroidal hyperfluorescence on ICGA^[5-6].

Although CSC usually resolves spontaneously within several months, some patients may progress chronic CSC, which can cause photoreceptor degeneration and RPE atrophy, resulting in irreversible anatomical and functional damage^[7]. Photodynamic therapy (PDT) has been effective in resolving subretinal fluid in recurrent or chronic CSC^[8-11]; however, potential side effects of PDT hinder its extensive application for acute CSC^[12]. Several studies posit that anti-vascular endothelial growth factor (VEGF) therapy may also lead to the decrease of subretinal fluid in CSC by reducing choroidal vascular hyperpermeability, based on its anti-permeability properties^[13-14]. Although clinical results with bevacizumab and ranibizumab were acceptable for the treatment of chronic CSC, they were not promising compared to the anatomic resolution of low-fluence PDT treatment in prospective comparative studies^[15]. It seems that these anti-VEGF drugs cannot fully address leakage from hyperpermeable choroidal vessels to induce complete absorption of subretinal fluid, as PDT does.

Aflibercept has been reported to have higher VEGF-binding affinity, and induce greater decreases in SFCT in eyes with

neovascular age-related macular degeneration (AMD) than ranibizumab^[16-17]. Additionally, evidence suggests that aflibercept induced a further reduction in choroidal and retinal thickness in AMD patients who responded insufficiently to either ranibizumab or bevacizumab^[18-19]. These results imply that aflibercept may have more influence on choroidal vasculature than previous anti-VEGF drugs. Based on these results, aflibercept's superior potency in reducing leakage from hyperpermeable choroidal vessels could be applied to the treatment of CSC. Indeed, Pitcher *et al*^[20] reported that repeated aflibercept injections resulted in a significant decrease in SFCT in chronic CSC. However, there are currently no published studies evaluating the changes of subretinal fluid and choroidal thickness after aflibercept injection in acute CSC. On the basis of laboratory and clinical data, significant biological activity of aflibercept (2.0 mg) is estimated to persist for 4 to 8wk after a single intravitreal administration. Our hypothesis is that, if aflibercept can have pharmacologic effect on the underlying choroid and lead to the reduction of subretinal fluid in acute CSC, fluctuation of subretinal fluid may be observed as the effects of aflibercept diminishes after a single injection. Indeed, the fluctuating pattern of retinal thickness was seen noted when injection frequency was spaced from 4 to 8wk in the VIEW studies. In the current pilot study, we aimed to investigate the short-term response to intravitreal aflibercept injection in patients with acute CSC by focusing on chorioretinal changes.

SUBJECTS AND METHODS

Ethical Approval We conducted a retrospective review of the medical records of patients diagnosed with acute unilateral CSC between January 2015 and August 2017 at the Seoul St. Mary's Hospital of the Catholic University of Korea in South Korea. This nonrandomized, retrospective, comparative, interventional case series was approved by the Institutional Review Board of the Catholic Medical Center, and was conducted according to the tenets of the Declaration of Helsinki. Informed consent was obtained from all patients before IAI and included mentions about other possible treatment options such as observation, focal photocoagulation, PDT, and mineralocorticoid blockers.

Inclusion criteria were as follows: 1) visual symptoms for less than six months; 2) subretinal fluid involving the fovea, with or without RPE detachment, on spectral-domain (SD) OCT; 3) presence of active focal leakage on fluorescein angiography (FA). Patients with a history of previous treatment, including intravitreal anti-VEGF injection, laser photocoagulation, or PDT, were excluded. Patients who had evidence of chronic CSC (diffuse RPE change including atrophic dependent tracks and diffuse hyperfluorescent leakage on FA), concomitant choroidal neovascularization, polypoidal choroidal

vasculopathy (PCV), or any other maculopathy causing subretinal fluid accumulation, were also excluded. Patients divided into 2 groups: a single intravitreal aflibercept injection (IAI group) and observation group.

Each patient was scheduled for a monthly follow-up examination until 3mo after baseline visit. All patients underwent complete ocular examinations at the baseline and at each subsequent visit, which included the Snellen best-corrected visual acuity (BCVA) test, dilated fundus examination with slit-lamp biomicroscopy, and OCT. Spectralis OCT (Heidelberg Engineering, Heidelberg, Germany) was used to evaluate the presence of fluid and central subfield foveal thickness (CSFT). CSFT was defined as the mean retinal thickness in the 1 mm central macular subfield. Enhanced depth imaging-OCT was used to determine the SFCT of the affected eye and fellow eye. The SFCT and subfoveal fluid height was determined using the digital caliper function to measure the distance from the inner border of the choroido-scleral interface to the hyper-reflective RPE, and from the hyper-reflective RPE to the photoreceptor outer segments under the fovea. ICGA (Heidelberg Retina Angiograph, Heidelberg Engineering, Heidelberg, Germany) were performed within three months prior to aflibercept injection.

The main outcome measures include changes of CSFT, SFCT and BCVA, from baseline and across visits. The proportion of eyes achieving complete resolution of subretinal fluid at each follow-up visits was assessed. Also, we evaluated the proportion of eyes that showed significant changes in CSFT between each visit. For statistical analysis, Snellen visual acuity was converted to the logarithm of the minimal angle of resolution (logMAR). A repeated-measures analysis of variance (rmANOVA) with Bonferroni's correction for multiple comparisons was used to assess the time course of changes in the CSFT, SFCT and BCVA over time. The unpaired *t*-test and Chi-square test were used to compare continuous and categorical variables between the two groups, respectively. SPSS for Windows ver. 20 (SPSS, Chicago, IL, USA) was used for statistical analyses. The data are expressed as mean±standard deviation; a *P* value less than 0.05 was considered significant.

RESULTS

Among the 84 eligible patients (84 eyes), 13 patients were excluded due to missed follow-ups or missing data. Thus, we evaluated the clinical data from 71 patients, with 35 patients in the IAI group and 36 patients in the observation group. The mean age of the subjects was 49.7±9.6y (range: 31 to 66y), and the mean duration of symptoms before study entry was 2.7±1.9mo (range: one to six months). On baseline FA, all 71 eyes showed active focal fluorescein leakage. Choroidal

Table 1 Baseline demographic and clinical characteristics of the both study population

Parameters	Aflibercept group (n=35)	Observation group (n=36)	P
Age (y)	51.3±9.5	48.1±9.4	0.149 ^a
Gender (M/F)	29/6	24/12	0.173 ^b
Duration of symptoms (mo)	3.0±1.9	2.5±1.8	0.216 ^a
No. of previous episodes	0.26±0.51	0.22±0.49	0.767 ^a
BCVA (logMAR)	0.30±0.20	0.24±0.19	0.231 ^a
Central subfield foveal thickness (µm)	445±121	450±106	0.860 ^a
Subfoveal choroidal thickness (µm)	444±100	426±95	0.440 ^a
Subfoveal choroidal thickness of unaffected eye (µm)	362±92	369±82	0.752 ^a
Choroidal hyperpermeability on ICGA, n (%)	27 (77.1)	25 (69.4)	0.594 ^b

BCVA: Best-corrected visual acuity; logMAR: Logarithm of the minimal angle of resolution; ICGA: Indocyanine-green angiography. Data are mean±standard deviation unless otherwise noted. ^aUnpaired *t*-test. ^bChi-square test.

Table 2 Anatomic and functional outcomes after aflibercept injection or observation for the treatment of acute CSC

Parameters	Aflibercept group (n=35)	Observation group (n=36)	P
Central subfield foveal thickness (µm)			
Baseline	445±121	449±106	0.860 ^a
1mo	276±62 (<0.001) ^d	358±70 (<0.001) ^d	<0.001 ^a
2mo	289±78 (<0.001) ^d	318±92 (<0.001) ^d	0.160 ^a
3mo	293±82 (<0.001) ^d	303±92 (<0.001) ^d	0.641 ^a
Subfoveal choroidal thickness (µm)			
Baseline	444±100	426±95	0.440 ^a
1mo	426±105 (<0.001) ^d	425±93 (1.000) ^d	0.983 ^a
2mo	440±101 (0.918) ^d	424±99 (0.632) ^d	0.483 ^a
3mo	437±101 (0.190) ^d	423±90 (0.093) ^d	0.543 ^a
Mean BCVA (logMAR)			
Baseline	0.300	0.241	0.231 ^a
1mo	0.222 (0.017) ^d	0.191 (0.120) ^d	0.459 ^a
2mo	0.211 (0.016) ^d	0.163 (0.015) ^d	0.253 ^a
3mo	0.188 (0.006) ^d	0.152 (0.004) ^d	0.386 ^a
No. of eyes rebound of central subfield foveal thickness compared to the previous visit (%)			
1mo	0 (0)	3 (8.3)	0.239 ^c
2mo	14 (40.0)	1 (2.8)	<0.001 ^b
3mo	4 (11.4)	2 (5.6)	0.429 ^c
No. of eyes with complete fluid absorption at 3mo (%)			
	16 (45.7)	15 (41.7)	0.813 ^b

BCVA: Best-corrected visual acuity; logMAR: Logarithm of the minimal angle of resolution; CSC: Central serous chorioretinopathy. ^aUnpaired *t*-test; ^bChi-square test; ^cFisher's exact test; ^dPaired *t*-test (compared with baseline).

hyperpermeability was seen on ICGA in 27 eyes (77.1%) in the IAI group and 25 eyes (69.4%) in the observation group. Table 1 summarizes the baseline characteristics of the patients in the two groups. There were no significant differences in age, sex, duration of symptoms, number of previous episodes, logMAR BCVA, CSFT, or SFCT between the two groups. Table 2 summarizes the anatomical and visual outcomes of the two groups. The mean CSFT changed significantly during the 3-month study period in both groups ($P < 0.001$, $P < 0.001$, rmANOVA). The mean CSFT in the IAI group decreased from 445±121 µm at baseline to 276±62 µm at 1mo, 289±78 µm at 2mo, and 293±82 µm at 3mo. The mean CSFT in the observation group also decreased from 449±106 µm at baseline to 358±70 µm

at 1mo, 318±92 µm at 2mo, and 303±92 µm at 3mo. CFST at each follow-up were all significantly smaller than that at baseline in both groups ($P < 0.001$ in all comparison). In comparison of CFST between the two groups at each follow-up, the mean CFST was significantly lower in the IAI group at 1mo ($P < 0.001$), but did not differ between the two groups at 2mo ($P = 0.160$) and 3mo ($P = 0.641$). In the IAI group, intraocular complications including endophthalmitis, cataract formation, intraocular pressure changes, and rhegmatogenous retinal detachment were not notified. All eyes showed a significant decrease of CSFT at 1mo compared to baseline. However, an increase of CSFT more than 7% was noted in 14 of 35 eyes (40.0%) between

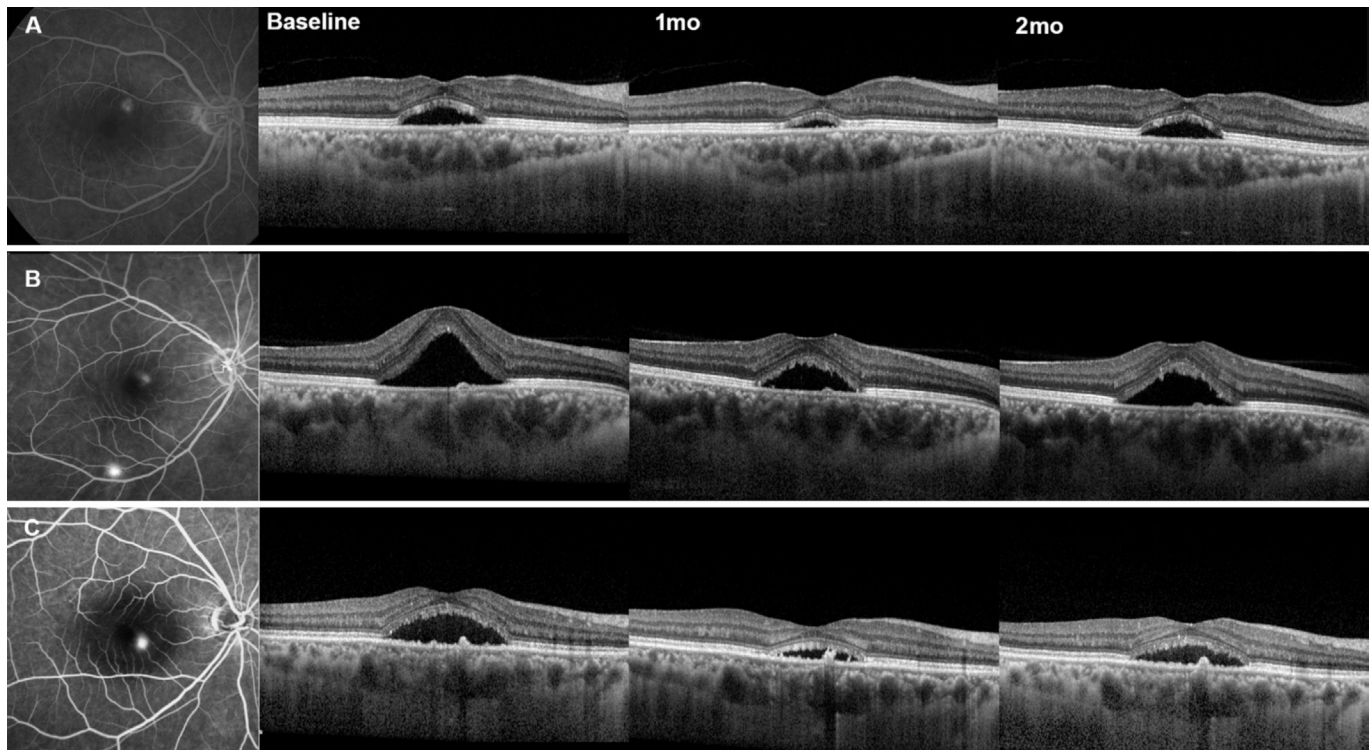


Figure 1 Representative three cases with acute CSC treated with intravitreal aflibercept injection. After single intravitreal aflibercept injection, all eyes showed a transient decrease in SFCT and CSFT at 1mo, and showed rebounding tendency at 2mo.

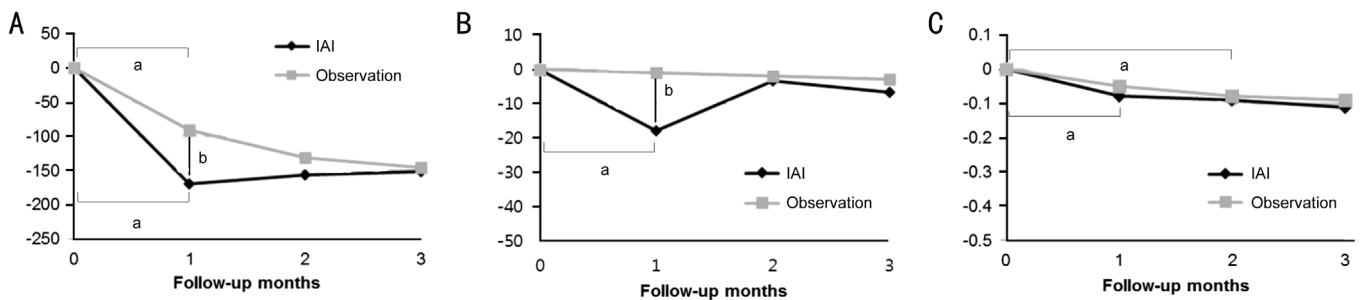


Figure 2 Graphs showing treatment outcomes in the study. A: Mean change in CSFT; B: Mean change in SFCT; C: Mean change in BCVA. ^a $P < 0.05$ compared with baseline. ^b $P < 0.05$ compared between the two groups.

1 and 2mo. In 4 eyes (11.4%), CSFT increased significantly between 2 and 3mo. In the observation group, an increase of CSFT more than 7% compared to the previous visit was noted in 3 eyes (8.3%) at 1mo, 1 eye (2.8%) at 2mo, and 2 eyes (5.6%) at 3mo. The proportion of eyes that showed a rebound of CSFT was significantly higher in the IAI group at 2mo ($P < 0.001$).

The mean SFCT in the IAI group changed significantly during the 3-month study period. Compared with the baseline value of $444 \pm 100 \mu\text{m}$, the mean SFCT in the IAI group decreased to $426 \pm 105 \mu\text{m}$ at 1mo ($P < 0.001$), rebounded to $440 \pm 101 \mu\text{m}$ at 2mo ($P = 0.918$) and remained stable at 3mo ($437 \pm 101 \mu\text{m}$, $P = 0.190$). The SFCT in the observation group was $426 \pm 95 \mu\text{m}$ at baseline, $425 \pm 93 \mu\text{m}$ at 1mo, $424 \pm 99 \mu\text{m}$ at 2mo, and $423 \pm 90 \mu\text{m}$ at 3mo, and the change was not significant ($P = 0.254$, rmANOVA). The representative cases are shown in Figure 1. The mean logMAR BCVA changed significantly during the

3-month study period in the IAI ($P < 0.001$, rmANOVA) and observation groups ($P = 0.001$, rmANOVA). In the IAI group, the visual improvement was statistically significant from 1mo (0.22 ± 0.16 , Snellen equivalent of 20/33) compared with baseline values (0.30 ± 0.20 , Snellen equivalent of 20/40) ($P = 0.017$). In the observation group, the visual improvement was statistically significant from 2mo (0.16 ± 0.18 , Snellen equivalent of 20/29) compared with baseline values (0.24 ± 0.21 , Snellen equivalent of 20/35; $P = 0.015$). At 3mo, complete absorption of subretinal fluid was noted in 16 of 35 eyes (45.7%) in the IAI group, and in 15 of 36 eyes (41.7%) in the observation group ($P = 0.813$). The changes in SFCT, CSFT, and logMAR BCVA are shown in Figure 2.

DISCUSSION

CSC is commonly classified into acute and chronic cases, but the underlying ICGA abnormality of both types is choroidal vascular hyperpermeability. PDT directly targets choroidal

circulation and damages the choriocapillaris, leading to decreased choroidal vascular hyperpermeability that is represented as a decrease in choroidal thickness on OCT^[21-22]. Zhao *et al*^[23] reported a significant decrease in choroidal thickness in chronic CSC patients who received 50%-dose PDT. But in patients who received 30%-dose PDT, the results were inferior in resolving subretinal fluid. Furthermore, recent studies have demonstrated that SFCT increased toward baseline values at recurrence after either PDT or bevacizumab injection, and the extent of the SFCT reduction was associated with the rate of recurrence in chronic CSC^[22,24]. Therefore, choroidal thickness changes may be used as a relevant parameter in the assessment of treatment effects, and monitoring exudative activity of CSC. In the current study, a single IAI induced a significant decrease in SFCT at 1mo then rebounded at 2mo. The mean CSFT also significantly decreased at 1mo, and an increase of CSFT was noted at 2 and 3mo in about half of the patients in the IAI group. The exudation from the choroid in eyes with acute CSC seems to be transiently controlled after a single IAI. This implies that choroidal hyperpermeability in CSC may potentially be VEGF mediated, and that aflibercept indeed causes choroidal thinning.

A decrease in choroidal thickness, and subsequent decrease in subretinal fluid, in CSC could be explained by anti-VEGF drugs inducing choroidal vasoconstriction by decreasing levels of nitric oxide, or by anti-VEGF drugs reducing choroidal fenestrations^[25]. VEGF plays a crucial role in choriocapillaris maintenance, and the choriocapillaris has been shown to be vulnerable to VEGF inhibition. Experimental studies using monkeys demonstrated a reduction in the number of fenestrations and choriocapillaris endothelium thickness after one injection of ranibizumab and aflibercept, but showed a more pronounced reduction after aflibercept treatment^[25-26]. Blockade of VEGF-A, and/or simultaneous inhibition of multiple molecules in the VEGF family, such as VEGF-B and placental growth factor (PIGF)^[27], may explain the prominent effect of aflibercept on the choroid. Additionally, this may be the reason as to why aflibercept appears to be more effective in diseases associated with a thicker choroid and choroidal vascular hyperpermeability, such as PCV and CSC^[16,20].

It is interesting that the effect of a single IAI did not last up to 2mo in this study. Aflibercept is known to maintain significant intravitreal VEGF-binding activity for 10-12wk after a single injection, as predicted by a mathematical model^[28], which is further supported by major clinical trials^[29-30]. The predicted biological activity of a therapeutic macromolecule depends to a large degree on both its intraocular half-life and its binding affinity. The binding affinity for VEGF of aflibercept is about 100 times higher than that of ranibizumab or bevacizumab^[27]. The half-life of aflibercept (molecular weight: 115 kDa) in

human eyes has not yet been studied. Since the intraocular half-life of a macromolecule is primarily determined by its molecular size, aflibercept may be estimated to have a half-life between ranibizumab (molecular weight: 48 kDa) and bevacizumab (molecular weight: 149 kDa)^[31]. Therefore, the main reason for the longer action of aflibercept could be explained by a large increase in binding affinity, rather than similar elimination half-times. A recent study demonstrated VEGF concentrations in aqueous humor were decreased below the lower limit of quantification after intravitreal aflibercept injections for about 10wk^[32]. In contrast, in patients with CSC, the aqueous humor level of VEGF was not significantly increased compared to the healthy controls^[33]. Therefore, binding affinity to VEGF may not be the major decisive factor in determining the biological activity of the anti-VEGF drug in CSC. We believe that the level of VEGF in CSC may be insufficient for the molecules of aflibercept to bind and demonstrate longer biologic activity, compared to that of ranibizumab or bevacizumab.

The mean SFCT of the IAI group returned to its baseline level at 2mo, and the mean CSFT at 2 and 3mo and the rate of complete absorption of subretinal fluid at 3mo did not differ between the IAI group and the observation group. The rates of our study are similar to the results from previous comparative studies; the reported rate of complete resolution of subretinal fluid ranged from 18.2% to 21.1% at 1mo, and from 27.3% to 44.0% at 3mo^[34-36]. This may imply that aflibercept can suppress hyperpermeable choroidal vessels only temporarily. This may lead to faster resolution of subretinal fluid and higher rate of complete fluid resolution. Further comparative studies with prospective designs are warranted to confirm this hypothesis.

There are some limitations to our study, including a short follow-up period and the small number of patients. The change in SFCT was measured manually, which carries the inherent possibility of under- or overestimation. However, a similar rebound was noted at 2mo after a single IAI in SFCT changes and automatically measured CSFT. We observed a pharmacologic effect of aflibercept on the choroid by measuring choroidal thickness on OCT, and angiographic improvements, such as a cessation of leakage on FA or a decrease of choroidal hyperpermeability on ICGA was not assessed. However, it was not feasible to routinely perform angiography after IAI, and OCT seems to be a better modality for quantifying transient and subtle changes in choroid. Finally, in this pilot study, the patients in the IAI group did not receive 3 loading injections due to the economic burden, which might have been more effective to assess the efficacy of aflibercept in acute CSC. However, the purpose of this study was to investigate whether aflibercept can suppress the

exudation from the hyperpermeable choroid in acute CSC, and we did not aim to evaluate the efficacy of aflibercept in the treatment of acute CSC. The rebound of SFCT and CSFT after a single IAI observed in this study can clearly demonstrate that aflibercept injection has pharmacologic effect temporarily on the underlying choroid.

To our knowledge, our study is the first to report anatomic and visual changes after aflibercept injection in acute CSC. A transient decrease in choroidal thickness followed by a significant decrease in subretinal fluid was observed after a single aflibercept injection. Although anatomic and visual improvement was noted up to three months, definitive conclusions cannot be made as to whether these improvements would be significantly different from those of simple observation in acute CSC. However, this pilot study demonstrates that hyperpermeable choroidal vessels in acute CSC indeed respond to aflibercept. The results of our study lend credence to the need for further comparative studies with protocols involving repeated injections and longer follow-up periods to explore the possible role of IAI in the treatment of acute CSC.

ACKNOWLEDGEMENTS

Conflicts of Interest: Jung BJ, None; Lee K, None; Park JH, None; Lee JH, None.

REFERENCES

- 1 Wang M, Munch IC, Hasler PW, Prunte C, Larsen M. Central serous chorioretinopathy. *Acta Ophthalmol* 2008;86(2):126-145.
- 2 Prunte C, Flammer J. Choroidal capillary and venous congestion in central serous chorioretinopathy. *Am J Ophthalmol* 1996;121(1):26-34.
- 3 Guyer DR, Yannuzzi LA, Slakter JS, Sorenson JA, Ho A, Orlock D. Digital indocyanine green videoangiography of central serous chorioretinopathy. *Arch Ophthalmol* 1994;112(8):1057-1062.
- 4 Imamura Y, Fujiwara T, Margolis R, Spaide RF. Enhanced depth imaging optical coherence tomography of the choroid in central serous chorioretinopathy. *Retina* 2009;29(10):1469-1473.
- 5 Jirarattanasopa P, Ooto S, Tsujikawa A, Yamashiro K, Hangai M, Hirata M, Matsumoto A, Yoshimura N. Assessment of macular choroidal thickness by optical coherence tomography and angiographic changes in central serous chorioretinopathy. *Ophthalmology* 2012;119(8):1666-1678.
- 6 Razavi S, Souied EH, Cavallero E, Weber M, Querques G. Assessment of choroidal topographic changes by swept source optical coherence tomography after photodynamic therapy for central serous chorioretinopathy. *Am J Ophthalmol* 2014;157(4):852-860.
- 7 Levine R, Brucker AJ, Robinson F. Long-term follow-up of idiopathic central serous chorioretinopathy by fluorescein angiography. *Ophthalmology* 1989;96(6):854-859.
- 8 Dhirani NA, Yang YL, Somani S. Long-term outcomes in half-dose verteporfin photodynamic therapy for chronic central serous retinopathy. *Clin Ophthalmol* 2017;11:2145-2149.
- 9 Sartini F, Figus M, Nardi M, Casini G, Posarelli C. Non-resolving,

recurrent and chronic central serous chorioretinopathy: available treatment options. *Eye (Lond)* 2019;33(7):1035-1043.

10 Sheptulin V, Purtskhvanidze K, Roider J. Half-time photodynamic therapy in treatment of chronic central serous chorioretinopathy. *Graefes Arch Clin Exp Ophthalmol* 2018;256(11):2027-2034.

11 Son BK, Kim K, Kim ES, Yu SY. Long-term outcomes of full-fluence and half-fluence photodynamic therapy for chronic central serous chorioretinopathy. *Ophthalmologica* 2019;241(2):105-115.

12 Lee PY, Kim KS, Lee WK. Severe choroidal ischemia following photodynamic therapy for pigment epithelial detachment and chronic central serous chorioretinopathy. *Jpn J Ophthalmol* 2009;53(1):52-56.

13 Inoue M, Kadonosono K, Watanabe Y, Kobayashi S, Yamane S, Arakawa A. Results of one-year follow-up examinations after intravitreal bevacizumab administration for chronic central serous chorioretinopathy. *Ophthalmologica* 2011;225(1):37-40.

14 Artunay O, Yuzbasioglu E, Rasier R, Sengul A, Bahcecioglu H. Intravitreal bevacizumab in treatment of idiopathic persistent central serous chorioretinopathy: a prospective, controlled clinical study. *Curr Eye Res* 2010;35(2):91-98.

15 Bae SH, Heo J, Kim C, Kim TW, Shin JY, Lee JY, Song SJ, Park TK, Moon SW, Chung H. Low-fluence photodynamic therapy versus ranibizumab for chronic central serous chorioretinopathy: one-year results of a randomized trial. *Ophthalmology* 2014;121(2):558-565.

16 Hata M, Oishi A, Tsujikawa A, Yamashiro K, Miyake M, Ooto S, Tamura H, Nakanishi H, Takahashi A, Yoshikawa M, Yoshimura N. Efficacy of intravitreal injection of aflibercept in neovascular age-related macular degeneration with or without choroidal vascular hyperpermeability. *Invest Ophthalmol Vis Sci* 2014;55(12):7874-7880.

17 Koizumi H, Kano M, Yamamoto A, Saito M, Maruko I, Kawasaki R, Sekiryu T, Okada AA, Iida T. Short-term changes in choroidal thickness after aflibercept therapy for neovascular age-related macular degeneration. *Am J Ophthalmol* 2015;159(4):627-633.

18 Mazaraki K, Fassnacht-Riederle H, Blum R, Becker M, Michels S. Change in choroidal thickness after intravitreal aflibercept in pretreated and treatment-naive eyes for neovascular age-related macular degeneration. *Br J Ophthalmol* 2015;99(10):1341-1344.

19 Hirakata T, Fujinami K, Watanabe K, Sasaki M, Noda T, Akiyama K. One-year outcome of intravitreal aflibercept injection for age-related macular degeneration resistant to ranibizumab: rapid morphologic recovery and subsequent visual improvement. *Clin Ophthalmol* 2016;10:969-977.

20 Pitcher JD 3rd, Witkin AJ, DeCroos FC, Ho AC. A prospective pilot study of intravitreal aflibercept for the treatment of chronic central serous chorioretinopathy: the CONTAIN study. *Br J Ophthalmol* 2015;99(6):848-852.

21 Chan WM, Lam DS, Lai TY, Tam BS, Liu DT, Chan CK. Choroidal vascular remodelling in central serous chorioretinopathy after indocyanine green guided photodynamic therapy with verteporfin: a novel treatment at the primary disease level. *Br J Ophthalmol* 2003;87(12):1453-1458.

- 22 Kim YK, Ryoo NK, Woo SJ, Park KH. Choroidal thickness changes after photodynamic therapy and recurrence of chronic central serous chorioretinopathy. *Am J Ophthalmol* 2015;160(1):72-84.e1.
- 23 Zhao MW, Zhang F, Chen YX, Dai H, Qu JF, Dong CY, Kang XP, Liu YL, Yang L, Li YB, Zhou P, Pan CT, Zhang LJ, Liu PP, Zhou HY, Jiao X, Xiong Y, Tian R, Lu YY, Yu XB, Li XX. A 50% vs 30% dose of verteporfin (photodynamic therapy) for acute central serous chorioretinopathy: one-year results of a randomized clinical trial. *JAMA Ophthalmol* 2015;133(3):333-340.
- 24 Kim DY, Joe SG, Yang HS, Lee JY, Kim JG, Yoon YH. Subfoveal choroidal thickness changes in treated idiopathic central serous chorioretinopathy and their association with recurrence. *Retina* 2015;35(9):1867-1874.
- 25 Peters S, Heiduschka P, Julien S, Ziemssen F, Fietz H, Bartz-Schmidt KU, Tübingen Bevacizumab Study Group, Schraermeyer U. Ultrastructural findings in the primate eye after intravitreal injection of bevacizumab. *Am J Ophthalmol* 2007;143(6):995-1002.
- 26 Julien S, Biesemeier A, Taubitz T, Schraermeyer U. Different effects of intravitreally injected ranibizumab and aflibercept on retinal and choroidal tissues of monkey eyes. *Br J Ophthalmol* 2014;98(6):813-825.
- 27 Stewart MW. Aflibercept (VEGF Trap-eye): the newest anti-VEGF drug. *Br J Ophthalmol* 2012;96(9):1157-1158.
- 28 Stewart MW, Rosenfeld PJ. Predicted biological activity of intravitreal VEGF Trap. *Br J Ophthalmol* 2008;92(5):667-668.
- 29 Heier JS, Brown DM, Chong V, Korobelnik JF, Kaiser PK, Nguyen QD, Kirchhof B, Ho A, Ogura Y, Yancopoulos GD, Stahl N, Vittori R, Berliner AJ, Soo Y, Anderesi M, Groetzbach G, Sommerauer B, Sandbrink R, Simader C, Schmidt-Erfurth U, VIEW and VIEW Study Groups. Intravitreal aflibercept (VEGF trap-eye) in wet age-related macular degeneration. *Ophthalmology* 2012;119(12):2537-2548.
- 30 Ogura Y, Roeder J, Korobelnik JF, Holz FG, Simader C, Schmidt-Erfurth U, Vittori R, Berliner AJ, Hiemeyer F, Stemper B, Zeitz O, Sandbrink R, GALILEO Study Group. Intravitreal aflibercept for macular edema secondary to central retinal vein occlusion: 18-month results of the phase 3 GALILEO study. *Am J Ophthalmol* 2014;158(5):1032-1038.
- 31 Stewart MW. Pharmacokinetics, pharmacodynamics and pre-clinical characteristics of ophthalmic drugs that bind VEGF. *Expert Rev Clin Pharmacol* 2014;7(2):167-180.
- 32 Fauser S, Schwabecker V, Muether PS. Suppression of intraocular vascular endothelial growth factor during aflibercept treatment of age-related macular degeneration. *Am J Ophthalmol* 2014;158(3):532-536.
- 33 Lim JW, Kim MU, Shin MC. Aqueous humor and plasma levels of vascular endothelial growth factor and interleukin-8 in patients with central serous chorioretinopathy. *Retina* 2010;30(9):1465-1471.
- 34 Chan WM, Lai TY, Lai RY, Liu DT, Lam DS. Half-dose verteporfin photodynamic therapy for acute central serous chorioretinopathy: one-year results of a randomized controlled trial. *Ophthalmology* 2008;115(10):1756-1765.
- 35 Ratanasukon M, Bhurayanontachai P, Jirattanasopa P. High-dose antioxidants for central serous chorioretinopathy; the randomized placebo-controlled study. *BMC Ophthalmol* 2012;12:20.
- 36 Kim KS, Lee WK, Lee SB. Half-dose photodynamic therapy targeting the leakage point on the fluorescein angiography in acute central serous chorioretinopathy: a pilot study. *Am J Ophthalmol* 2014;157(2):366-373.e1.