

# Corneal graft melting: a systematic review

Bin-Bin Zhu, Jie Zhou, Jiao Zheng, Yue Zhang, Ting Wan, Xiao-Dan Huang, Lin Lin, Xiu-Ming Jin

Eye Center, the Affiliated Second Hospital, School of Medicine, Zhejiang University, Hangzhou 310009, Zhejiang Province, China

**Correspondence to:** Xiu-Ming Jin. Eye Center, the Affiliated Second Hospital, School of Medicine, Zhejiang University, 88 Jiefang Road, Hangzhou 310009, Zhejiang Province, China. lzyjxm@zju.edu.cn

Received: 2018-10-25 Accepted: 2019-12-20

## Abstract

• Corneal graft melting is a severe complication of keratoplasty. This review is to summarize the incidence, the pathogenesis, the risk factors, the prognosis and the prevention of corneal graft melting after keratoplasty. We systematically searched PubMed, Web of Science and WanFang database to retrieve potentially eligible articles about relevant clinical reports and animal experiments. We read the full texts to identify eligible articles. The selection of studies and data extraction were performed independently by two reviewers. In conclusion, the pathogenesis of corneal graft melting is complicated, and many risk factors are closely related to corneal graft melting. Analysis of pathogenesis and risk factors of corneal graft melting can facilitate the development of targeted therapies to better guide clinical practice.

• **KEYWORDS:** corneal graft melting; keratoplasty; incidence; complication

**DOI:10.18240/ijo.2020.03.19**

**Citation:** Zhu BB, Zhou J, Zheng J, Zhang Y, Wan T, Huang XD, Lin L, Jin XM. Corneal graft melting: a systematic review. *Int J Ophthalmol* 2020;13(3):493-502

## INTRODUCTION

Despite the increasing success of keratoplasty, it still remains many complications including immune rejection, corneal graft melting, secondary glaucoma, and the recurrence of primary disease, *etc*<sup>[1]</sup>. Corneal graft melting is a severe problem, which leads to irregular astigmatism, photophobia, corneal perforation, the loss of vision and even endophthalmitis<sup>[2]</sup>. The risk factors are vital to provide information for treatment of corneal graft melting. Until now,

only some of that information are available about this topic, which limited the ability to draw clear conclusions for the guideline of clinical therapy. Based on the above, we review and compare the published articles of corneal graft melting after keratoplasty with regard to the incidence, the pathogenesis, the risk factors, the prognosis and the prevention.

## METHODS

**Searching Process** We searched PubMed, Web of Science and WanFang database by using the keywords “keratoplasty”, “corneal transplantation”, “corneal graft melting” and “complication” to retrieve potentially eligible articles about relevant clinical reports and animal experiments. The selection of studies and data extraction were performed independently by two reviewers.

**Inclusion Criteria and Exclusion Criteria** We collected eligible articles according to the following criteria: reported on incidence, the risk factors, the pathogenesis, the prognosis or the prevention of corneal graft melting following keratoplasty. Duplicate publication and reports that the full context could not be acquired were excluded. We read the full texts to identify the eligible articles.

## RESULTS

**Incidence of Corneal Graft Melting** Corneal graft melting is a relatively rare complication of keratoplasty. It is difficult to make a precise evaluate of incidence and demographics of corneal graft melting for some reason. Published articles are often small trials or case reports offering a single incidence, which the size of population and completeness of coverage is uncertain. Moreover, it is difficult to conduct large-sample prospective studies. Until now, the exact incidence of corneal graft melting is uncertain. The several case series of keratoplasty outlined significantly different incidences of corneal graft melting.

In a study by Krisik *et al*<sup>[3]</sup>, 17 (36.2%) of 47 eyes occurred graft melting following penetrating keratoplasty (PKP), 8 with infection, 7 with autoimmune, and 2 with trauma. A large retrospective in Kingdom of Saudi Arabia reported that 2 (0.03%) of 6752 eyes suffered from endophthalmitis associated with graft melting after PKP while no cases after lamellar keratoplasty (LKP) between 1990 and 2007<sup>[4]</sup>.

A small case series performed by Patel *et al*<sup>[5]</sup> reported 4 (44.4%) of 9 cases with stromal melting after LKP. Sun *et al*<sup>[6]</sup>

reported that unhealed corneal epithelium and aseptic corneal stromatolysis occurred in 5 (1.82%) eyes in 274 cases of LKP. In the setting of autoimmune diseases, such as rheumatoid arthritis (RA), Thomas and Pflugfelder<sup>[7]</sup> proposed that a high rate of corneal graft melting is expected in PKP (>30%) and LKP (24%).

In 2009, Shan *et al*<sup>[8]</sup> first reported 2 cases of corneal melting following Descemet stripping endothelial keratoplasty. Later, Lee *et al*<sup>[9]</sup> reported 2 cases following endothelial keratoplasty were associated with conditions leading to corneal graft melting, which was similar to the case reported by Ortiz-Gomariz *et al*<sup>[10]</sup>.

A study by Zhang *et al*<sup>[11]</sup> reported 4 (8.5%) eyes with corneal graft melting in 47 eyes implanted with an acellular porcine cornea. In addition, a study of Boston keratoprosthesis (B-Kpro) type I in children, conducted by Fung *et al*<sup>[12]</sup>, reported a high rate of keratoprosthesis (KPro)-related melting that 5 (45.5%) of 11 eyes occurred. Chan *et al*<sup>[13]</sup> revealed 20 (15.6%) of 128 eyes developed KPro-related corneal melting.

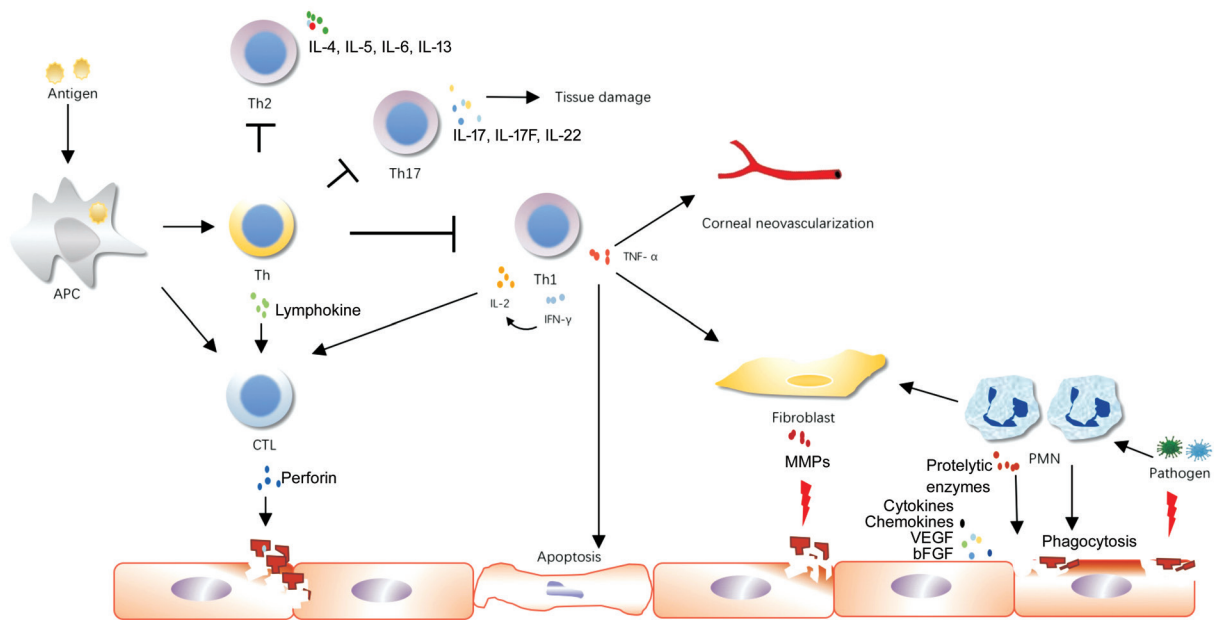
Based on the published literature, it is inferred that the incidence of corneal graft melting after varies from 0.03% to 45.5%. The difference can be explained by variability in surgical method, graft materials, the sample size, follow-up duration and other variables. The incidence of corneal graft melting of KPro seems a bit higher than that of other graft materials. Comparing data from studies, the larger the sample size, the lower incidence which is more accurate. In a review of corneal melting following B-KPro type I, Robert and Dohlman<sup>[14]</sup> reported the incidence was closely associated with follow-up duration and the time to appearance vary 1.7% of patients underwent graft melting under one year, while increasing to 7% with 1-2y follow-up and 11% more than 2y. Infection and conjunctival defect can shorten the time between surgery and the appearance of graft melting<sup>[13]</sup>.

In addition, corneal graft melting often occurs in the periphery of graft<sup>[15]</sup>. Besides, infectious graft melting commonly occurs in the area of the infection-induced corneal epithelial defect or corneal infiltration<sup>[13-14,16-17]</sup>. Moreover, infectious corneal graft melting is mainly caused by recurrence of infection. In 2016, Peng *et al*<sup>[18]</sup> estimated the recurrence rate in 221 cases undergoing PKP for treatment of infectious keratitis. The data showed that fungal infection was highest (20%, 31/155), which is followed by virus (3.6%, 1/28) and bacteria (3.3%, 1/30). *Candida(C.) albicans* accounts for a majority of fungal infections<sup>[19]</sup>.

**Pathogenesis** The pathogenesis of corneal graft melting is complex that infection and immune response play a key role. Pathogens break through the ocular surface defense and penetrate the cornea<sup>[20]</sup>. Fungi, as common pathogen, can release valinomycin and proteolytic enzymes to damage the

cornea<sup>[21]</sup>. Then, fungal invasion induces immune response, which in turn is involved in pathogenesis of corneal graft melting<sup>[22]</sup>. Polymorphonuclear neutrophils (PMNs) are the predominant inflammatory cells, which is the first line of defense against infection. Many experiments have shown that PMNs mainly release proteolytic enzymes, reactive oxygen species (ROS) and matrix metalloproteinases (MMPs), and the subsequent inflammatory events come to cause corneal graft melting. Proteolytic enzymes degrade extracellular matrix (ECM), while ROS induce oxidative damage<sup>[23-24]</sup>. MMPs play an important role in the process of corneal graft melting. They damage the corneal epithelial cells, degrade corneal epithelial basement membrane and corneal stroma, and participate in angiogenesis<sup>[25-27]</sup>. MMP-9 is a widely studied enzyme of the MMP family, which is positively associated with inflammation, infiltration of immune components, and the intensity of the graft rejection. MMP-9 can degrade gelatin, IV and V type collagen, and elastin. The expression of MMP-9 is significantly increased in the corneal graft<sup>[28]</sup>. Similar to other MMPs, MMP-2 damages the corneal stroma<sup>[29]</sup>. Firstly, MMP-2 activates protein cleavage reactions. Secondly, it destroys the junctions between keratocytes. Thirdly, it affects the adhesion of ECM. All these events lead to bad corneal epithelial healing, stromal edema, and corneal melting<sup>[30-31]</sup>. A study by Eaton *et al*<sup>[32]</sup> revealed that the chances for the survival of the graft improve significantly by inhibiting the expression of MMPs.

It has long been established that T cells are involved in the pathogenesis of multiple immune diseases. T-cell-mediated immune response can be triggered by keratoplasty, which leads to the initiation of delayed-type hypersensitivity (DTH), corneal graft rejection and subsequent corneal graft melting. During the priming of T cell response, antigen presenting cell (APC) prime helper T (Th) cells and cytotoxic T cells (CTLs). The importance of Th cells in corneal graft melting is widely accepted. Th cells differentiate into Th1, Th2, and Th17<sup>[33]</sup>. Th1 cells release interleukin (IL)-2, interferon (IFN)- $\gamma$ , and tumor necrosis factor (TNF)- $\alpha$ <sup>[34-35]</sup>. IL-2 is involved in the generation of CTL. TNF- $\alpha$  is a proinflammatory cytokine, which plays a key role in the negative regulation of keratoplasty. First, TNF- $\alpha$  induces MMPs and the apoptosis of the corneal endothelium mediated by TNF- $\alpha$  induced protein-8-like 2 (TIPE<sub>2</sub>) during graft rejection<sup>[36]</sup>. Then, TNF- $\alpha$ -induced intercellular cell adhesion molecule (ICAM)-1 may be related to impaired immune response in NF- $\kappa$ B-dependent manner<sup>[37]</sup>. Wang *et al*<sup>[38]</sup> found the proangiogenic role of TNF- $\alpha$  in age-related macular degeneration by upregulating the expression of vascular endothelial growth factor (VEGF) *via* ROS-dependent signaling. However, the evidence for TNF- $\alpha$ -induced neovascularization in corneal graft melting is unclear. Th1 cells are not the sole mediators, and there is the



**Figure 1 Major pathogenesis of corneal graft melting** A variety of inflammatory cytokines, polymorphonuclear neutrophils, T cells participate in the progress of corneal graft melting.

involvement of many effector pathways, such as Th2 cells and Th17 cells<sup>[39]</sup>. Th2 cells are associated with tolerance by producing IL-4, IL-5, IL-6, IL-13<sup>[33]</sup>. Th17 cells produce IL-17, IL-17F and IL-22, contributing to corneal graft rejection<sup>[40]</sup>. Both Th1 and Th17 cells can activate myeloid cells including macrophage. During the priming of T cell response, CTLs attack the target cell<sup>[41]</sup>. In contrast, it has been proposed by Boisgerault *et al*<sup>[42]</sup> that CTLs have no ability to damage the graft. Furthermore, keratoplasty disturbs the balance between proangiogenic factors and antiangiogenic factors, which induces lymphangiogenesis and angiogenesis<sup>[43]</sup>. Angiogenesis is driven by many proangiogenic factors including MMPs, VEGF, basic fibroblast growth factor (bFGF)<sup>[41]</sup>. And members of the VEGF family drive lymphangiogenesis and angiogenesis<sup>[44-45]</sup>. Therefore, corneal immune privilege is disrupted (Figure 1).

**Risk Factors** Infection, various graft and host factors, and drug factors contribute to an increased risk of corneal graft melting. Major risk factors are listed in the following.

**Infection** Several studies have identified recurrence of infection as a main factor for infectious corneal graft melting after keratoplasty. Unskilled surgical techniques and tiny lesions may lead to the incomplete removal of the lesion, resulting in recurrence of infection<sup>[43,46]</sup>.

In a recent study, Broniek *et al*<sup>[47]</sup> reported that 32 (4.4%) in 725 samples of corneal preservation fluid were detected positively in microbiological culture. They thought that corneal preservation fluid containing rich nutrients could be contaminated by bacteria or fungi. Moreover, Baer *et al*<sup>[48]</sup> showed that the addition of antibiotics in cornea preservation

fluids could not effectively eliminate the contamination. In addition, suture-related infection also is associated with corneal graft melting<sup>[49-51]</sup>.

#### Graft Factors

**Corneal edema** It has been proposed that corneal edema may lead to corneal graft melting<sup>[6]</sup>. In this situation, corneal collagen was degraded by collagenase<sup>[52]</sup>. Corneal stromal edema destroys a favorable growth microenvironment for epithelial cells, which induces conjunctivalization and corneal scarring. Continuous corneal edema, coupled with inflammation, eventually leads to corneal graft melting and perforation<sup>[53]</sup>. When inflammation and corneal edema reduced, early suture loosening can induce secondary infection and immune rejection<sup>[54]</sup>.

A study by Hong *et al*<sup>[55]</sup> found that corneal graft shrinkage created a gap between graft bed and the cornea. Thus, the nerve and keratocytes were unable to grow into the graft leading to neurotrophic melting.

**Graft materials** At present, the B-KPro is widely used. The B-KPro type I is made of polymethylmethacrylate (PMMA), a kind of impermeable biological material, and did not facilitate the access of epithelial cells and ECM to the device. In addition, DTH is partly associated with KPro materials with a high expression of inflammatory cytokines<sup>[56]</sup>. Due to the incompatibility of graft material and the absence of innervation, the necrosis and melting often occur around the stem of the device, and then create a gap between the cornea and the device which induces secondary infection<sup>[57]</sup>. Collagenase secreted by corneal epithelium plays a role in corneal graft melting, and collagenase inhibitors can inhibit

this process. Thanks to great advances to the design of the device and the surgical techniques that enables the device obtain better nutrition, the incidence of corneal melting has decreased<sup>[58-59]</sup>.

The central optic area and a biointegrating anchoring skirt of AlphaCor or KPros are made of poly(2-hydroxyethyl methacrylate) (PHEMA). Although PHEMA has better properties than PMMA, such as better flexibility and higher water content, melting still occurs at the graft-host junction<sup>[60]</sup>. Kanayama *et al*<sup>[61]</sup> found that PHEMA released tissue factor in response to the postoperative reaction. Furthermore, Jiraskova *et al*<sup>[60]</sup> reported that many inflammatory cytokines and enzymes entered in the device, suggesting graft melting was mediated by immune response.

Nonwoven polypropylene and polyurethane as scaffolds have poor healing effects for the cornea. Although keratocytes can grow into the scaffold, they still fail to prevent the host tissue from melting<sup>[62]</sup>. Recently, a study has shown that the design of stem of KPro with a titanium ring enhance the adherence between the device and the cornea, reducing the rate of keratolysis<sup>[63]</sup>.

The main materials used for tissue-engineered corneal scaffolds include acellular porcine cornea, collagen, amniotic membrane, and chitosan. In most of studies, acellular porcine corneas are prepared by the decellularization reagents including many proteases and chemical reagents. These reagents change the microstructure and mechanical properties of acellular porcine corneas<sup>[64-67]</sup>. A previous study showed that the properties of acellular porcine corneas would become weak after rehydration. The rehydrated acellular porcine corneas were unable to withstand suturing manipulation in some cases. Thirty days after surgery, part of the acellular porcine corneas melted<sup>[68]</sup>. It has been revealed that collagen is degraded rapidly by collagenase after surgery<sup>[69]</sup>. Liu *et al*<sup>[70]</sup> reported that the rough surface of the graft bed and the suture loosening are responsible for the melting of the amnion membrane. However, it has not been reported in detail.

**Preservation of corneal graft** Preservation methods and preservation time are related to the outcome of keratoplasty.

Glycerol preservation is a method of long-term storage of the cornea. Glycerol-preserved cornea lose active cells and reduce the sensitivity of MHC-II antigens, and thus it is unable to active T cells<sup>[71]</sup>. In addition to glycerin-preserved graft, graft rejection rate is lower by the use of glycerol cryopreserved cornea compared to fresh corneal graft<sup>[72]</sup>. Furthermore, several studies has shown that the progress of fresh graft melting is slower than that of the glycerin-preserved graft, which allows time for healing<sup>[73-74]</sup>.

A study by Niu *et al*<sup>[75]</sup> showed that the rejection time was related to preservation methods. The onset of rejection time for chamber-preserved cornea was shorter, which might be related

to the existence of human leukocyte antigens on the cornea. They recommended corneal cryopreservation as an ideal preservation method.

### **Host Factors**

**Dry eye** The characteristics of dry eye include reduced tear secretion, reduced tear film stability, and increased tear evaporation. Patients with ocular disorders including traumatic, congenital eyelid defects, hyperthyroidism, trigeminal nerve paralysis or lagophthalmos manifest dry eye, corneal epithelial defect, and even corneal ulcer<sup>[11]</sup>. It was found that tear film break-up time (BUT) was shorter and the tear film became unstable after keratoplasty<sup>[76]</sup>. The possible reasons are as follows: 1) The corneal nerve is mechanically damaged by the cornea ring drill. A study by Jie *et al*<sup>[77]</sup> found that nerve regeneration was very slow after keratoplasty. There was lower density of nerve in the graft compared to the healthy cornea<sup>[78]</sup>. Furthermore, the slow recovery of corneal sensation is closely associated with the abnormal morphology and low density of regenerated nerve. Therefore, blink reflex and tear secretion are disturbed, and these events lead to corneal epithelial defect and bad healing. The epitheliums of the graft shed off, and the collagenase will dissolve the cornea<sup>[79]</sup>. 2) Surgery affects the regularity of the cornea. Surgery disturbs the mucins secretion of the conjunctival goblet cells, and tear film stability<sup>[76]</sup>. It takes time to recover the ocular surface. 3) Glucocorticoids and immunosuppressants change corneal collagen by suppressing the recovery of corneal epithelium after surgery. It aggravates corneal graft melting<sup>[80-81]</sup>. Several studies have proved that the corneal epithelial healing time is longer in patients who has lower Schirmer I test scores, resulting in a high risk of necrosis and melting of the graft<sup>[79,82]</sup>.

**Autoimmune disease** Several studies have reported that the intensity of keratopathy is related to the intensity and activity of the autoimmune disease<sup>[74]</sup>. Corneal melting is an ocular complication of some autoimmune diseases. And some studies have revealed a high rate of recurrence of corneal graft melting after keratoplasty. Cytokines, chemotaxis, collagenases, proteases, and MMPs are involved in the process of corneal graft melting<sup>[7,74]</sup>. In addition to autoimmune response, it is also related to immune-induced vaso-occlusive diseases<sup>[74]</sup>. Until now, its pathogenesis remains unclear<sup>[83]</sup>.

For example, the etiology of Mooren's ulcer (MU) is unknown, but it is proposed to be an autoimmune disease due to increased antibodies and immune components, high ratio of CD4<sup>+</sup>/CD8<sup>+</sup> T cells, and decreased suppressor T cells<sup>[84]</sup>. Xie *et al*<sup>[85]</sup> reported higher level of autoantibody soluble protein in the corneal stroma and serum. The denatured soluble protein diffused to the limbus, and its antigenicity induced humoral immunity and cell immunity, resulting in the damage of the cornea and subsequent corneal graft melting<sup>[86]</sup>.

**Immune rejection** A previous study by Newman *et al*<sup>[52]</sup> reported that corneal graft rejection was related to corneal melting. Corneal graft rejection was mediated by T cells, which attacked keratocytes and led to corneal edema and corneal melting. Moreover, corneal edema aggravated immune-mediated corneal graft melting.

In addition, graft versus host disease (GVHD) occurs in many organs that the eye is one of the most target organs<sup>[87]</sup>. Cornea, conjunctive, lacrimal glands, meibomian glands, lids and sclera are commonly involved in ocular GVHD<sup>[88]</sup>. Reduced mucins, and increased inflammation in the conjunctiva may be important factors of corneal graft melting, similar to dry eye<sup>[89-90]</sup>. Another contributing factor is immune response to host antigens. Moreover, decreased nerve density and corneal sensation also play a role in corneal graft melting<sup>[91]</sup>. Therefore, GVHD patients are prone to corneal graft melting after keratoplasty<sup>[79]</sup>.

#### **Drug Factors**

**Non-steroidal anti-inflammatory eye drops** Several studies have proven that non-steroidal anti-inflammatory drugs (NSAIDs) can cause corneal melting<sup>[92-93]</sup>. The reasons of NSAIDs-induced corneal graft melting are as follows: 1) NSAIDs inhibit cyclooxygenase (COX) so that COX is unable to catalyze arachidonic acid to prostaglandins. Therefore, arachidonic acid is converted to leukotriene. Leukotriene is involved in the recruitment of leukocytes to the cornea. Degranulation of leukocytes also contributes to graft melting<sup>[94]</sup>. 2) NSAIDs disturb the balance of MMPs involved in the deposition and degeneration of ECM<sup>[95]</sup>. Increased expression of MMPs was observed in the cornea in NSAIDs group compared to the control group<sup>[96]</sup>. 3) NSAIDs decrease corneal sensitivity by inhibiting the neuronal ion pathway. A study by Lin *et al*<sup>[97]</sup> reported that using NSAIDs after surgery resulted in the destruction of corneal sensitivity. 4) NSAIDs have a toxic effect on the cornea<sup>[98-100]</sup>. NSAIDs can induce apoptosis which has been proved in animal models<sup>[95]</sup>. *In vitro* study, diclofenac sodium can decrease cell viability. Drug concentration and contact time are closely correlated with drug toxicity. Moreover, electrolyte composition, the pH and osmolarity, and the preservatives used in ophthalmic solutions affect the ocular surface<sup>[101]</sup>.

**Corticosteroid eye drops** Corticosteroid eye drops are commonly used to suppress inflammation and immune rejection after keratoplasty. However, they may contribute to corneal graft melting. The reasons are as follows: 1) Corticosteroid has a toxic effect on cells in a time- and dose-dependent manner. Due to decreased cell viability, the proliferation of fibroblasts and corneal re-epithelialization are inhibited<sup>[102]</sup>. 2) Corticosteroid can activate collagenase and suppress the synthesis of collagen and proteoglycan<sup>[103-104]</sup>.

These events delay corneal healing and induce persistent corneal epithelial defect. 3) The above-mentioned changes of the ocular surface increase the risk of corneal infection. In severe cases, it develops to corneal ulcer, corneal graft melting, and perforation<sup>[105-106]</sup>.

**Rare case by drug abuse** Wu *et al*<sup>[107]</sup> reported a rare case of corneal graft melting as a Mooren-like ulcer due to drug abuse (lidocaine and glucocorticoid). Topical anesthetic decreases corneal sensitivity which makes patients ignore eye discomfort. In this situation, it may develop to keratitis, corneal necrosis, melting and perforation. Recent studies have reported that topical anesthetic may alter antigens which mediates immune response to attack the cornea<sup>[107-108]</sup>.

#### **DISCUSSION**

**Prevention** As mentioned above, the pathogenesis of corneal graft melting is complicated. There are many risk factors of corneal graft melting after keratoplasty. Therefore, combination therapy is very important. Due to graft materials and preservation of corneal graft contributing to graft melting, proper donor graft should be emphasized to the patients. As for the patients with autoimmune diseases, accurate preoperative assessment and adaptive indication are crucial to protect the cornea from graft melting.

#### **Medication**

**Artificial tears and trophic factors** For dry eye and mild graft melting, patients can be treated with artificial tears and autologous serum tears. Autologous serum tears contain some trophic factors which may promote the regeneration of corneal epithelium, stroma and nerve<sup>[109]</sup>. In addition to their nutritional effect, they also show a immunosuppressive activity<sup>[110]</sup>.

**Anti-microbiological drugs** Some patients with corneal graft melting are caused by infection. Regarding bacterial infection, broad-spectrum antibiotics are adopted, such as fluoroquinolone, cephalosporin and aminoglycoside<sup>[111]</sup>. Antibiotic treatment is adjusted according to the results of microbial detection. No study has proven the effectiveness of preventive antimicrobial usage<sup>[112]</sup>.

For fungal infection and viral infection, combination of oral and topical therapies is more adopted than monotherapy. Antifungal drugs include voriconazole, itraconazole, amphotericin B and natamycin. Antiviral drugs include acyclovir, famciclovir, ganciclovir and valaciclovir<sup>[113]</sup>.

**Anti-inflammatory drugs** Despite the fact that corticosteroid eye drops and NSAIDs induce corneal graft melting, they are widely used to suppress inflammation after keratoplasty. Corticosteroid eye drops also is commonly accepted to inhibit corneal neovascularization.

**Immunosuppressants** Cyclosporine A and tacrolimus (FK506) are macrolide with a potent immunosuppressive activity. They suppress T cell activation and the production

of immune components including IL-2, TNF- $\alpha$ , IFN- $\gamma$ <sup>[114-115]</sup>. Thus, the function of CTLs and Th cell is inhibited. Topical cyclosporine A is used for treatment of ocular GVHD, corneal graft rejection and dry eye<sup>[116-118]</sup>. For patients with autoimmune diseases, immunosuppressants should be administered before and after surgery to control the primary diseases and prevent possible postoperative melting<sup>[119]</sup>.

**Vascular endothelial growth factor inhibitors** VEGF inhibitors are used for treatment of corneal neovascularization<sup>[120]</sup>. Bevacizumab has been used as eye drops for inhibiting graft rejection and corneal neovascularization in patients with keratoplasty<sup>[121]</sup>. Subconjunctival injection of VEGF inhibitors is more effective to reduce neovascularization compared to eye drops<sup>[122]</sup>.

**Matrix metalloproteinases inhibitors** MMPs are responsible for corneal graft melting, suggesting they can be therapeutic target. Low dose doxycycline has been proven to inhibit MMPs<sup>[123]</sup>. However, the effectiveness of doxycycline in the treatment of corneal graft melting remains unreported.

**TNF- $\alpha$  inhibitors** TNF- $\alpha$  plays an important role in corneal graft melting. Topical infliximab, a TNF- $\alpha$  inhibitor, may protect the cornea from further melting<sup>[124]</sup>.

**Keratoplasty** If corneal graft melting cannot be managed with medical treatments, artificial cornea exchange or therapeutic keratoplasty will be required<sup>[125]</sup>. Due to the special characteristics of the herpes simplex virus and fungi, the lesions, hypopyon and the fibrous exudative membrane must be completely removed to prevent recurrence of infection<sup>[2]</sup>.

**Other therapies** For the patients with poor corneal healing, amniotic membrane transplantation may be an effective method to promote corneal epithelial healing. Lacrimal punctal occlusion and bandage contact lens are also effective to improvement in sign and symptoms. They prolong the retention of tear on the ocular surface, and thereby reduce the loss of the corneal epithelium<sup>[126]</sup>. The treatments, such as tarsorrhaphy, amniotic membrane covering, autogenous conjunctival flap covering, and corneal limbal stem cell autograft transplantation, can be considered in patients with chemical injury<sup>[6,127]</sup>.

**Gene therapy** In recent years, gene therapy has become an innovative method. Gene therapy can ensure the accurate localization of DNA and the sustained expression of the gene by integrating DNA into the target cells. Avoiding immune response and reducing pathogenicity may come true by transporting the carrier to the donor grafts<sup>[128]</sup>.

**Prognosis** More than half of patients achieved corneal epithelialization by medication, bandage contact lens, amniotic membrane covering, autogenous conjunctival flap covering and tarsorrhaphy<sup>[6,129]</sup>. Some severe patients needed repeat keratoplasty<sup>[130]</sup>. In addition, half of patients with KPro-

related melting accepted artificial corneal exchange<sup>[131-133]</sup>. A few patients experienced endophthalmitis, and ended up in an enucleation<sup>[2,6]</sup>.

In conclusion, the pathogenesis of corneal graft melting is complicated, and many risk factors are closely related to corneal graft melting. Analysis of pathogenesis and risk factors of corneal graft melting can facilitate the development of targeted therapies to better guide clinical practice.

#### ACKNOWLEDGEMENTS

**Foundations:** Supported by National Natural Science Foundation of China (No.81870558; No.81870624; No.81700802); Major Science and Technology Projects of Zhejiang Province (No.2017C03046).

**Conflicts of Interest:** Zhu BB, None; Zhou J, None; Zheng J, None; Zhang Y, None; Wan T, None; Huang XD, None; Lin L, None; Jin XM, None.

#### REFERENCES

- 1 Huber KK, Maier AK, Klamann MK, Rottler J, Özlügedik S, Rosenbaum K, Gonnermann J, Winterhalter S, Jousen AM. Glaucoma in penetrating keratoplasty: risk factors, management and outcome. *Graefes Arch Clin Exp Ophthalmol* 2013;251(1):105-116.
- 2 Zhao G, Jiang N, Hu L, Che C. Penetrating keratoplasty for treatment of high-risk fungal keratitis. *Journal of Clinical Rehabilitative Tissue Engineering Research* 2009;13(18):3597-3600.
- 3 Krysik K, Wroblewska-Czajka E, Lyssek-Boron A, Wylegala EA, Dobrowolski D. Total penetrating keratoplasty: indications, therapeutic approach, and long-term follow-up. *J Ophthalmol* 2018;2018:9580292.
- 4 Alharbi SS, Alrajhi A, Alkahtani E. Endophthalmitis following keratoplasty: incidence, microbial profile, visual and structural outcomes. *Ocul Immunol Inflamm* 2014;22(3):218-223.
- 5 Patel AK, Scorgia V, Kadyan A, Lapenna L, Ponzin D, Busin M. Microkeratome-assisted superficial anterior lamellar keratoplasty for anterior stromal corneal opacities after penetrating keratoplasty. *Cornea* 2012;31(1):101-105.
- 6 Sun L, Chen W, Ma H, Li J, Zhao Z. Complications and treatment for deep anterior lamellar keratoplasty. *Chinese Journal of Optometry Ophthalmology and Visual Science* 2012;14(11):684-687.
- 7 Thomas JW, Pflugfelder SC. Therapy of progressive rheumatoid arthritis-associated corneal ulceration with infliximab. *Cornea* 2005;24(6):742-744.
- 8 Shan SJ, Wu EI, Akpek EK. Sterile corneal melt after descemet stripping endothelial keratoplasty in patients with previously undiagnosed Sjogren syndrome. *Arch Ophthalmol* 2009;127(2):219-220.
- 9 Lee WB, Foster JB, Kozarsky AM, Zhang Q, Grossniklaus HE. Interface fungal keratitis after endothelial keratoplasty: a clinicopathological report. *Ophthalmic Surg Lasers Imaging* 2011;42 Online:e44-e48.
- 10 Ortiz-Gomariz A, Higuera-Esteban A, Gutiérrez-Ortega ÁR, González-Méijome JM, Arance-Gil A, Villa-Collar C. Late-onset Candida keratitis after Descemet stripping automated endothelial

- keratoplasty: clinical and confocal microscopic report. *Eur J Ophthalmol* 2011;21(4):498-502.
- 11 Zhang MC, Liu X, Jin Y, Jiang DL, Wei XS, Xie HT. Lamellar keratoplasty treatment of fungal corneal ulcers with acellular porcine corneal stroma. *Am J Transplant* 2015;15(4):1068-1075.
- 12 Fung SSM, Jabbour S, Harissi-Dagher M, Tan RRG, Hamel P, Baig K, Ali A. Visual outcomes and complications of type I Boston keratoprosthesis in children: a retrospective multicenter study and literature review. *Ophthalmology* 2018;125(2):153-160.
- 13 Chan CC, LoVerde L, Qiang J, Nordlund ML, Holland EJ. Incidence, risk factors, and surgical management of Boston type 1 keratoprosthesis corneal melts, leaks, and extrusions. *Cornea* 2016;35(8):1049-1056.
- 14 Robert MC, Dohlman CH. A review of corneal melting after Boston Keratoprosthesis. *Semin Ophthalmol* 2014;29(5-6):349-357.
- 15 Krysik K, Dobrowolski D, Lyssek-Boron A, Jankowska-Szmul J, Wylegala EA. Differences in surgical management of corneal perforations, measured over six years. *J Ophthalmol* 2017;2017:1582532.
- 16 Chan CC, Holland EJ. Infectious keratitis after Boston type 1 keratoprosthesis implantation. *Cornea* 2012;31(10):1128-1134.
- 17 Kim MJ, Yu F, Aldave AJ. Microbial keratitis after Boston type I keratoprosthesis implantation: incidence, organisms, risk factors, and outcomes. *Ophthalmology* 2013;120(11):2209-2216.
- 18 Peng X, Zhao G, Li J, Lin J, Hu L, Jiang N, Wang Q, Qu J, Wang X. Comparison and analysis of therapeutic effect of penetrating keratoplasty for severe infectious keratitis caused by different pathogens. *Chin J Exp Ophthalmol* 2016;34(2):150-154.
- 19 Spadea L, Abbouda A, Abicca I, Paroli MP. Aspergillus flavus endophthalmitis after penetrating keratoplasty combined with cataract phacoemulsification and IOL implantation. *Int Ophthalmol* 2015;35(1):145-148.
- 20 Jackson BE, Wilhelmus KR, Mitchell BM. Genetically regulated filamentation contributes to *Candida albicans* virulence during corneal infection. *Microb Pathog* 2007;42(2-3):88-93.
- 21 Feng Y. An analysis of corneal ulcer debridement combined with conjunctiva flap covering in treatment of fungal corneal ulcer. *Guide of China Medicine* 2015;(11):13-14.
- 22 Yuan X, Wilhelmus KR, Matoba AY, Alexandrakis G, Miller D, Huang AJ. Pathogenesis and outcome of *paecilomyces* keratitis. *Am J Ophthalmol* 2009;147(4):691-696.e3.
- 23 Alizadeh H, Neelam S, Niederkorn JY. Effect of immunization with the mannose-induced *Acanthamoeba* protein and *Acanthamoeba* plasminogen activator in mitigating *Acanthamoeba* keratitis. *Invest Ophthalmol Vis Sci* 2007;48(12):5597-5604.
- 24 Leal SM Jr, Vareecheon C, Cowden S, Cobb BA, Latgé JP, Momany M, Pearlman E. Fungal antioxidant pathways promote survival against neutrophils during infection. *J Clin Invest* 2012;122(7):2482-2498.
- 25 Isnard N, Robert L, Renard G. Effect of sulfated GAGs on the expression and activation of MMP-2 and MMP-9 in corneal and dermal explant cultures. *Cell Biol Int* 2003;27(9):779-784.
- 26 Yang Y, Tong L, Xing Y, Li F. Expression of matrix metalloproteinase 9 and tissue inhibitor of metalloproteinase 1 in mouse cornea with alkali burn. *Rec Adv Ophthalmol* 2006;26(7):499-503.
- 27 Ren M, Zhou J. Matrix metalloproteinases/tissue inhibitors of metalloproteinase system and diabetic ocular complications. *Chin J Exp Ophthalmol* 2014;32(9):860-864.
- 28 Rigal-Sastourné JC, Tixier JM, Renard JP, Maurin JF, Pouliquen Y, Legeais JM. Corneal burns and matrix metalloproteinases (MMP-2 and -9): the effects of human amniotic membrane transplantation. *J Fr Ophtalmol* 2002;25(7):685-693.
- 29 Kožák I, Klisenbauer D, Juhás T. UV-B induced production of MMP-2 and MMP-9 in human corneal cells. *Physiol Res* 2003;52(2):229-234.
- 30 Lafleur MA, Forsyth PA, Atkinson SJ, Murphy G, Edwards DR. Perivascular cells regulate endothelial membrane type-1 matrix metalloproteinase activity. *Biochem Biophys Res Commun* 2001;282(2):463-473.
- 31 Li L, Zhou D, Wang XM, Wang XP, Cui FZ, Lu YJ, Huang YF. Expression of matrix metalloproteinases and inhibitor on the cornea tissue in rabbit after implantation of modified titanium skirt for keratoprosthesis. *Zhonghua Yan Ke Za Zhi* 2012;48(1):20-26.
- 32 Eaton VL, Lerret NM, Velásquez-Lopera MM, John R, Caicedo M, DeCresce RP, Jaramillo A. Enhanced allograft survival and modulation of T-cell alloreactivity induced by inhibition of MMP/ADAM enzymatic activity. *Am J Transplant* 2008;8(3):507-516.
- 33 Hegde S, Beauregard C, Mayhew E, Niederkorn JY. CD4(+) T-cell-mediated mechanisms of corneal allograft rejection: role of Fas-induced apoptosis. *Transplantation* 2005;79(1):23-31.
- 34 Sano Y, Osawa H, Sotozono C, Kinoshita S. Cytokine expression during orthotopic corneal allograft rejection in mice. *Invest Ophthalmol Vis Sci* 1998;39(10):1953-1957.
- 35 Li S, Yu J, Guo CG, Jie Y, Pan ZQ. The balance of Th1/Th2 and LAP+Tregs/Th17 cells is crucial for graft survival in allogeneic corneal transplantation. *J Ophthalmol* 2018;2018:5404989.
- 36 Na J, Bak DH, Im SI, Choi H, Hwang JH, Kong SY, No YA, Lee Y, Kim BJ. Anti-apoptotic effects of glycosaminoglycans via inhibition of ERK/AP-1 signaling in TNF- $\alpha$ -stimulated human dermal fibroblasts. *Int J Mol Med* 2018;41(5):3090-3098.
- 37 Shibuya T, Takei Y, Hirose M, Ikejima K, Enomoto N, Maruyama A, Sato N. A double-strand decoy DNA oligomer for NF-kappaB inhibits TNF $\alpha$ -induced ICAM-1 expression in sinusoidal endothelial cells. *Biochem Biophys Res Commun* 2002;298(1):10-16.
- 38 Wang Q, Zhao X, Wang Z. Study of high-risk corneal transplantation rejection and the expression of VEGF-C/D. *Guoji Yanke Zazhi* 2016;16(10):1812-1815.
- 39 Hargrave SL, Hay C, Mellon J, Mayhew E, Niederkorn JY. Fate of MHC-matched corneal allografts in Th1-deficient hosts. *Invest Ophthalmol Vis Sci* 2004;45(4):1188-1193.
- 40 Chen HY, Wang WL, Xie HY, Xu X, Wu J, Jiang ZJ, Zhang ML, Zhou L, Zheng SS. A pathogenic role of IL-17 at the early stage of corneal allograft rejection. *Transpl Immunol* 2009;21(3):155-161.

- 41 Becking K, Haarman BCM, Grosse L, Nolen WA, Claes S, Arolt V, Schoevers RA, Drexhage HA. The circulating levels of CD4+ T helper cells are higher in bipolar disorder as compared to major depressive disorder. *J Neuroimmunol* 2018;319:28-36.
- 42 Boisgerault F, Liu Y, Anosova N, Dana R, Benichou G. Differential roles of direct and indirect allorecognition pathways in the rejection of skin and corneal transplants. *Transplantation* 2009;87(1):16-23.
- 43 Liu H, Liu J, Zhang X. Investigation about the use of drug after keratoplasty complications. *Keji Feng* 2016(3):55-59.
- 44 Al-Debasi T, Al-Bekairy A, Al-Katheri A, Al Harbi S, Mansour M. Topical versus subconjunctival anti-vascular endothelial growth factor therapy (Bevacizumab, Ranibizumab and Aflibercept) for treatment of corneal neovascularization. *Saudi J Ophthalmol* 2017;31(2):99-105.
- 45 Johnson KE, Wilgus TA. Vascular endothelial growth factor and angiogenesis in the regulation of cutaneous wound repair. *Adv Wound Care (New Rochelle)* 2014;3(10):647-661.
- 46 Lyall DA, Tarafdar S, Gilhooly MJ, Roberts F, Ramaesh K. Long term visual outcomes, graft survival and complications of deep anterior lamellar keratoplasty in patients with herpes simplex related corneal scarring. *Br J Ophthalmol* 2012;96(9):1200-1203.
- 47 Broniek G, Langwińska-Wośko E, Sybiliska M, Szaflik J, Szaflik JP, Wróblewska M. Prevalence of bacteria and fungi in samples of cornea preservation fluid. *Arch Med Sci* 2018;14(3):541-546.
- 48 Baer JC, Nirankari VS, Glaros DS. Streptococcal endophthalmitis from contaminated donor corneas after keratoplasty. Clinical and laboratory investigations. *Arch Ophthalmol* 1988;106(4):517-520.
- 49 Li SW, Liu C, Chen TH, Ning JH, Zhang T, Lyu FJ, Xu M. Clinical effects of pediatric penetrating keratoplasty for congenital corneal opacity. *Zhonghua Yan Ke Za Zhi* 2017;53(12):941-946.
- 50 Arora R, Jain P, Jain P, Manudhane A, Goyal J. Results of deep anterior lamellar keratoplasty for advanced keratoconus in children less than 18 years. *Am J Ophthalmol* 2016;162:191-198.e2.
- 51 Karimian F, Feizi S. Deep anterior lamellar keratoplasty: indications, surgical techniques and complications. *Middle East Afr J Ophthalmol* 2010;17(1):28-37.
- 52 Newman DK, Isaacs JD, Watson PG, Meyer PA, Hale G, Waldmann H. Prevention of immune-mediated corneal graft destruction with the anti-lymphocyte monoclonal antibody, CAMPATH-1H. *Eye (Lond)* 1995;9(Pt 5):564-569.
- 53 Wu LS, Chen JS, Xu JT, Ding Y, Tang GX, Zheng PE, Lei ZM. Cat xenogeneic lamellar keratoplasty for re-construction of corneal surface after severe corneal alkali burn in rabbits. *Rec Adv Ophthalmol* 2010;30(2):105-108.
- 54 Crawford AZ, Krishnan T, Ormonde SE, Patel DV, McGhee CN. Corneal transplantation in new zealand 2000 to 2009. *Cornea* 2018;37(3):290-295.
- 55 Hong J, Peng RM, Hao YS, Qu HQ. Post operation complications analysis and their treatment of Descemet's stripping automated endothelium keratoplasty. *Zhonghua Yan Ke Za Zhi* 2014;50(4):254-260.
- 56 Coassin M, Zhang C, Green WR, Aquavella JV, Akpek EK. Histopathologic and immunologic aspects of alphacor artificial corneal failure. *Am J Ophthalmol* 2007;144(5):699-704.
- 57 Salvador-Culla B, Kolovou PE. Keratoprosthesis: a review of recent advances in the field. *J Funct Biomater* 2016;7(2):E13.
- 58 Kirkham SM, Dangel ME. The keratoprosthesis: improved biocompatibility through design and surface modification. *Ophthalmic Surg* 1991;22(8):455-461.
- 59 Behlau I, Martin KV, Martin JN, Naumova EN, Cadorette JJ, Sforza JT, Pineda RII, Dohlman CH. Infectious endophthalmitis in Boston keratoprosthesis: incidence and prevention. *Acta Ophthalmol* 2014;92(7):e546-e555.
- 60 Jiraskova N, Werner L, Mamalis N, Rozsival P. Histologic evaluation of AlphaCor keratoprosthesis explanted following various complications. *Biomed Pap Med Fac Univ Palacky Olomouc Czech Repub* 2014;158(1):50-55.
- 61 Kanayama S, Garty S, Kim B, Shen TT. Histological study of graft failure in AlphaCor transplantation. *Int Ophthalmol* 2011;31(6):501-504.
- 62 Ruijie M, Yan L, Zhulin H. Research progress on scaffold materials and biocompatibility of keratoprosthesis. *International Review of Ophthalmology*. 2016;40(4):217-221.
- 63 Salvador-Culla B, Jeong KJ, Kolovou PE, Chiang HH, Chodosh J, Dohlman CH, Kohane DS. Titanium coating of the Boston keratoprosthesis. *Transl Vis Sci Technol* 2016;5(2):17.
- 64 Hashimoto Y, Funamoto S, Sasaki S, Honda T, Hattori S, Nam K, Kimura T, Mochizuki M, Fujisato T, Kobayashi H, Kishida A. Preparation and characterization of decellularized cornea using high-hydrostatic pressurization for corneal tissue engineering. *Biomaterials* 2010;31(14):3941-3948.
- 65 Li Q, Wang HM, Dai ZY, Cao YC, Jin C. Preparation and biomechanical properties of an acellular porcine corneal stroma. *Cornea* 2017;36(11):1343-1351.
- 66 Zhu J, Zhang K, Sun Y, Gao X, Li YC, Chen ZJ, Wu XY. Reconstruction of functional ocular surface by acellular porcine cornea matrix scaffold and limbal stem cells derived from human embryonic stem cells. *Tissue Eng Part A* 2013;19(21-22):2412-2425.
- 67 Lynch AP, Ahearn M. Strategies for developing decellularized corneal scaffolds. *Exp Eye Res* 2013;108:42-47.
- 68 Liu XN, Zhu XP, Wu J, Wu ZJ, Yin Y, Xiao XH, Su X, Kong B, Pan SY, Yang H, Cheng Y, An N, Mi SL. Acellular ostrich corneal stroma used as scaffold for construction of tissue-engineered cornea. *Int J Ophthalmol* 2016;9(3):325-331.
- 69 Du Q. Preparation and biocompatibility of chitosan-collagen corneal repair materials. *Chinese Journal of Tissue Engineering Research* 2015;19(52):8433-8437.
- 70 Liu J, Wu LB, Xu DL, Zhou JC. Analysis of the failure reason of amniotic membrane transplantation in treatment of pterygium. *Guoji Yanke Zazhi* 2011;11(7):1282-1283.
- 71 Chen W, Lin Y, Zhang XB, Wang LH, Liu MM, Liu JB, Ye Y, Sun L, Ma HX, Qu J. Comparison of fresh corneal tissue versus glycerin-



- cryopreserved corneal tissue in deep anterior lamellar keratoplasty. *Invest Ophthalmol Vis Sci* 2010;51(2):775-781.
- 72 Ding L. Clinical and confocal microscopic observations of deep anterior lamellar keratoplasty with glycerin cryopreserved corneal tissue. *Journal of Clinical Ophthalmology* 2013;21(6):516-518.
- 73 Kremer I, Ehrenberg M, Weinberger D. Fresh-tissue corneolimbal covering graft for large corneal perforation following childhood trachoma. *Ophthalmic Surg Lasers Imaging* 2009;40(3):245-250.
- 74 Livny E, Mimouni M, Bahar I, Molad Y, Gershoni A, Kremer I. Corneal melting in rheumatoid arthritis patients treated with a tectonic reinforcing corneolimbal graft: an interventional case series. *Int Ophthalmol* 2018;38(3):1317-1324.
- 75 Niu XX, Hong J, Li YF, Zhan LY. Comparative study on the correlation of penetrating keratoplasty rejection with different cornea preservation methods. *Guoji Yanke Zazhi* 2014;14(6):1005-1008.
- 76 Pan YJ, Jia H. Research progress on dry eye after keratoplasty. *Rec Adv Ophthalmol* 2015;35(11):1094-1098.
- 77 Jie Y, Wang Y, Li S, Ruan F, Pan Z. Characteristics of nerve regeneration after penetrating keratoplasty observed by confocal microscopy. *Journal of Capital Medical University* 2016;37(3):370-375.
- 78 Wang D, Song P, Wang ST, Sun DP, Wang YX, Zhang YY, Gao H. Laser scanning *in vivo* confocal microscopy of clear grafts after penetrating keratoplasty. *Biomed Res Int* 2016;2016:5159746.
- 79 Zou L. Treatment and prevention of corneal graft melting after keratoplasty. *Ophthalmology in China* 2009;18(3):148-149.
- 80 Wu N, Zhang R, Sun F, Tang D. Dry eye syndrome after penetrating keratoplasty. *Journal of Injuries and Occupational Diseases of the Eye with Ophthalmic Surgeries* 2013;35(3):215-217.
- 81 Yang DQ, Hong J. Research on the tear film function after keratoplasty. *Guoji Yanke Zazhi* 2008;8(6):1200-1202.
- 82 Sun X, Shi W, Wang T, Wang S. Factors associated with delayed epithelial healing in early stage after lamellar keratoplasty. *Journal of Clinical Ophthalmology* 2013;21(2):97-100.
- 83 Zou L. Importance of recognition of ocular surface manifestation of rheumatic diseases. *Ophthalmology in China* 2006;15(3):159-160.
- 84 Yeo JH, Kim KW, Kim JC. Mooren's ulcerative keratitis after systemic pegylated interferon alpha2a in chronic hepatitis C. *Can J Ophthalmol* 2017;52(5):e163-e167.
- 85 Xie HP, Chen JQ, Gu XF. A primary study on soluble protein and soluble antigen of corneal stroma in Mooren's ulcer patients. *Zhonghua Yan Ke Za Zhi* 2002;38(6):360-362.
- 86 Xing Z, Liu F, Yuan J. Research advance in immunological mechanism after corneal alkali burns. *Chinese Ophthalmic Research* 2010;28(8):796-799.
- 87 Shikari H, Antin JH, Dana R. Ocular graft-versus-host disease: a review. *Surv Ophthalmol* 2013;58(3):233-251.
- 88 Dietrich-Ntoukas T, Cursiefen C, Westekemper H, Eberwein P, Reinhard T, Bertz H, Nepp J, Lawitschka A, Heiligenhaus A, Seitz B, Messmer EM, Meyer-ter-Vehn T, Basara N, Greinix H, Datiles MB, Lee SJ, Pavletic SZ, Wolff D. Diagnosis and treatment of ocular chronic graft-versus-host disease: report from the German-Austrian-Swiss Consensus Conference on Clinical Practice in chronic GVHD. *Cornea* 2012;31(3):299-310.
- 89 Tatematsu Y, Ogawa Y, Shimmura S, Dogru M, Yaguchi S, Nagai T, Yamazaki K, Kameyama K, Okamoto S, Kawakami Y, Tsubota K. Mucosal microvilli in dry eye patients with chronic GVHD. *Bone Marrow Transplant* 2012;47(3):416-425.
- 90 He JL, Yamane M, Shibata S, Fukui M, Shimizu E, Yano T, Mukai S, Kawakami Y, Li SW, Tsubota K, Ogawa Y. Ocular surface and tear film characteristics in a sclerodermatous chronic graft-versus-host disease mouse model. *Cornea* 2018;37(4):486-494.
- 91 Tepelus TC, Chiu GB, Maram J, Huang JY, Chopra V, Satta SR, Lee OL. Corneal features in ocular graft-versus-host disease by *in vivo* confocal microscopy. *Graefes Arch Clin Exp Ophthalmol* 2017;255(12):2389-2397.
- 92 Liu Z, Zou W. The mechanisms of rejection happening in the corneal transplantation and its treatment. *Chin J Ophthalmol Otorhinolaryngol* 2006;6(5):277-280.
- 93 Isawi H, Dhaliwal DK. Corneal melting and perforation in Stevens Johnson syndrome following topical bromfenac use. *J Cataract Refract Surg* 2007;33(9):1644-1646.
- 94 Qu ML, Wang Y, Yang LL, Zhou QJ. Different cellular effects of four anti-inflammatory eye drops on human corneal epithelial cells: independent in active components. *Mol Vis* 2011;17:3147-3155.
- 95 Li J, Zou H, Tong J, Liu X. The Relationship between the corneal melting and nonsteroidal anti-inflammatory drug after excision of pterygium. *Medical Information* 2014;27(1):72.
- 96 Reviglio VE, Rana TS, Li QJ, Ashraf MF, Daly MK, O'Brien TP. Effects of topical nonsteroidal anti-inflammatory drugs on the expression of matrix metalloproteinases in the cornea. *J Cataract Refract Surg* 2003;29(5):989-997.
- 97 Lin JC, Rapuano CJ, Laibson PR, Eagle RC Jr, Cohen EJ. Corneal melting associated with use of topical nonsteroidal anti-inflammatory drugs after ocular surgery. *Arch Ophthalmol* 2000;118(8):1129-1132.
- 98 Zhao X, Yan X. Nonsteroidal anti-inflammatory eyedrops and corneal melting. *International Review of Ophthalmology* 2006;30(6):394-397.
- 99 Zhang Y, Zhang S, Cai J, Wang Q. Ultrastructural pathological alterations of corneal organization by local application of corticosteroid and NSAIDs in rabbits. *Chinese Journal of Practical Ophthalmology* 2011;29(3):281-284.
- 100 Qu M, Duan H, Wang Y, Wang Q, Zhou Q. Cytotoxicity research of three non-steroidal anti-inflammatory eye drops in human corneal epithelial cells. *Chin J Exp Ophthalmol* 2015;33(7):627-632.
- 101 Lee JS, Kim YH, Park YM. The toxicity of nonsteroidal anti-inflammatory eye drops against human corneal epithelial cells *in vitro*. *J Korean Med Sci* 2015;30(12):1856-1864.
- 102 Sun X, Bu X, Cheng D. Clinical analysis of six cases of scleral melting after pterygium surgery. *Chinese Journal of Ocular Trauma and Occupational Eye Disease* 2015;37(9):711-713.

- 103 Piper SL, Laron D, Manzano G, Pattnaik T, Liu X, Kim HT, Feeley BT. A comparison of lidocaine, ropivacaine and dexamethasone toxicity on bovine tenocytes in culture. *J Bone Joint Surg Br* 2012;94(6):856-862.
- 104 Zhang JZ, Krenzer KL, López FJ, Ward KW. Comparative effects of besifloxacin and other fluoroquinolones on corneal reepithelialization in the rabbit. *J Cataract Refract Surg* 2010;36(6):1049-1050.
- 105 Wang LC, Zhou W. Prevention and therapy progress in allograft rejection of high-risk corneal transplantation. *Guoji Yanke Zazhi* 2014;14(8):1413-1416.
- 106 Fasolo A, Pedrotti E, Passilongo M, *et al.* Safety outcomes and long-term effectiveness of *ex vivo* autologous cultured limbal epithelial transplantation for limbal stem cell deficiency. *Br J Ophthalmol* 2017;101(5):640-649.
- 107 Wu H, Hu Y, Shi XR, Xu FH, Jiang CY, Huang R, Jia H. Keratopathy due to ophthalmic drug abuse with corneal melting and perforation presenting as Mooren-like ulcer: a case report. *Exp Ther Med* 2016;12(1):343-346.
- 108 Khakshoor H, Moshirfar M, Simpson RG, Gharaee H, Vejdani AH, Christiansen SM, Edmonds JN, Behunin NL. Anesthetic keratopathy presenting as bilateral Mooren-like ulcers. *Clin Ophthalmol* 2012;6:1719-1722.
- 109 Phasukkijwatana N, Lertrit P, Liammongkolkul S, Prabhasawat P. Stability of epitheliotropic factors in autologous serum eye drops from chronic Stevens-Johnson syndrome dry eye compared to non-autoimmune dry eye. *Curr Eye Res* 2011;36(9):775-781.
- 110 Azari AA, Rapuano CJ. Autologous serum eye drops for the treatment of ocular surface disease. *Eye Contact Lens* 2015;41(3):133-140.
- 111 Kam KW, Yung W, Li GKH, Chen LJ, Young AL. Infectious keratitis and orthokeratology lens use: a systematic review. *Infection* 2017;45(6):727-735.
- 112 Davila JR, Mian SI. Infectious keratitis after keratoplasty. *Curr Opin Ophthalmol* 2016;27(4):358-366.
- 113 Cabrera-Aguas M, Robaei D, McCluskey P, Watson S. Clinical translation of recommendations from randomized trials for management of herpes simplex virus keratitis. *Clin Exp Ophthalmol* 2018;46(9):1008-1016.
- 114 Kim DW, Lee SH, Shin MJ, Kim K, Ku SK, Youn JK, Cho SB, Park JH, Lee CH, Son O, Sohn EJ, Cho SW, Park JH, Kim HA, Han KH, Park J, Eum WS, Choi SY. PEP-1-FK506BP inhibits alkali burn-induced corneal inflammation on the rat model of corneal alkali injury. *BMB Rep* 2015;48(11):618-623.
- 115 Li F, Li Y, Xiong Y. Effects of cyclosporin A on aqueous fluid inflammatory cytokines in high-risk corneal transplantation patients. *Journal of Clinical Ophthalmology* 2016;24(3):203-206.
- 116 Utine CA, Stern M, Akpek EK. Clinical review: topical ophthalmic use of cyclosporin A. *Ocul Immunol Inflamm* 2010;18(5):352-361.
- 117 Abudou M, Wu TX, Evans JR, Chen XY. Immunosuppressants for the prophylaxis of corneal graft rejection after penetrating keratoplasty. *Cochrane Database Syst Rev* 2015(8):CD007603.
- 118 Dastjerdi MH, Hamrah P, Dana. High-frequency topical cyclosporine 0.05% in the treatment of severe dry eye refractory to twice-daily regimen. *Cornea* 2009;28(10):1091-1096.
- 119 van der Meulen IJ, van Rooij J, Hazes JW, van Cleynenbreugel H, Geerards AJ, Remeyer L. Corneal melting after ocular surgery in patients with auto-immune disorders. *Ned Tijdschr Geneesk* 2007;151(16):920-923.
- 120 Hosseini H, Nowroozadeh MH, Salouti R, Nejabat M. Anti-VEGF therapy with bevacizumab for anterior segment eye disease. *Cornea* 2012;31(3):322-334.
- 121 Patsoukis N, Sari D, Boussiotis VA. PD-1 inhibits T cell proliferation by upregulating p27 and p15 and suppressing Cdc25A. *Cell Cycle* 2012;11(23):4305-4309.
- 122 Agarwal S, Angayarkanni N, Iyer G, Srinivasan B, Natarajan R, Charola S, Arumugam S, Padmanabhan P. Clinico-biochemical correlation of the effect of subconjunctival bevacizumab for corneal neovascularization. *Cornea* 2014;33(10):1016-1021.
- 123 Shih KC, Lun CN, Jhanji V, Thong BY, Tong L. Systematic review of randomized controlled trials in the treatment of dry eye disease in Sjogren syndrome. *J Inflamm (Lond)* 2017;14:26.
- 124 Robert MC, Črnež A, Shen LQ, Papaliadis GN, Dana, Foster CS, Chodosh J, Dohlman CH. Influximab after Boston keratoprosthesis in Stevens-Johnson syndrome: an update. *Ocul Immunol Inflamm* 2017;25(3):413-417.
- 125 Utine CA, Tzu JH, Akpek EK. Clinical features and prognosis of Boston type I keratoprosthesis-associated corneal melt. *Ocul Immunol Inflamm* 2011;19(6):413-418.
- 126 Zarei-Ghanavati M, Avadhanam V, Vasquez Perez A, Liu C. The osteo-odonto-keratoprosthesis. *Curr Opin Ophthalmol* 2017;28(4):397-402.
- 127 Huang YF, Wang LQ, Wang FX. Clinical application of keratoprosthesis for corneal opacity unsuitable for keratoplasty. *Zhonghua Yan Ke Za Zhi* 2003;39(10):578-581.
- 128 Zhang D, Zhang H. Gene therapy of corneal graft rejection. *Medical Recapitulate* 2016;22(2):216-220.
- 129 Di Zazzo A, Kheirkhah A, Abud TB, Goyal S, Dana. Management of high-risk corneal transplantation. *Surv Ophthalmol* 2017;62(6):816-827.
- 130 Wang Y, Wang D, Zhang Y, Wang J, Jia Y, Gao H. The regularity of recurrent and immune rejection after large-diameter penetrating keratoplasty for the treatment of fungal keratitis. *Chin J Optom Ophthalmol Vis Sci* 2015;17(11):685-689.
- 131 Wang LQ, Bai H, Huang YF. Analysis of clinic results and complication associated with Boston I keratoprosthesis. *Zhonghua Yan Ke Za Zhi* 2015;51(9):673-676.
- 132 Zhu L, Wang L, Zhang Y, He Y, Li J, Zhao D, Yang J, Li B. Long-term outcomes of Boston type I keratoprosthesis for Chinese severe corneal blindness. *Chin J Exp Ophthalmol* 2015;33(10):930-934.
- 133 Bouhout S, Robert MC, Deli S, Harissi-Dagher M. Corneal melt after Boston keratoprosthesis: clinical presentation, management, outcomes and risk factor analysis. *Ocul Immunol Inflamm* 2018;26(5):693-699.