

Anterior segment optical coherence tomography-guided transepithelial phototherapeutic keratectomy for scarring of the central cornea following pterygium excision

Sloan W. Rush^{1,2}, Ryan B. Rush^{1,2,3}

¹Panhandle Eye Group, Amarillo, TX 79106, USA

²Texas Tech University Health Science Center, Amarillo, TX 79106, USA

³Southwest Retina Specialists, Amarillo, TX 79106, USA

Correspondence to: Ryan B. Rush. Southwest Retina Specialists, 7411 Wallace Blvd. Amarillo, TX 79106, USA. Ryanbradfordrush21@hotmail.com

Received: 2019-02-16 Accepted: 2019-11-07

Abstract

• **AIM:** To report the outcomes of patients undergoing anterior segment optical coherence tomography-guided transepithelial phototherapeutic keratectomy (ASOCT T-PTK) for central corneal scarring after pterygium excision.

• **METHODS:** The charts of 11 eyes of 10 patients that underwent ASOCT T-PTK following excision of visual axis-involving pterygia were retrospectively reviewed from a single private practice institution. The visual outcomes and corneal topographic findings were evaluated 4±1mo after pterygium excision and 6±2mo after transepithelial phototherapeutic keratectomy (T-PTK).

• **RESULTS:** All 11 eyes tolerated both the pterygium excision and T-PTK procedure well without any significant intraoperative or postoperative complications. Uncorrected distance visual acuity (UDVA) and manifest refraction corrected distance visual acuity (CDVA) improved after pterygium excision ($P=0.03$ and $P=0.05$, respectively). The UDVA and CDVA improved further after T-PTK ($P=0.004$ and $P=0.002$, respectively). The topographic surface asymmetry index, topographic surface regularity index, and topographic projected visual acuity significantly improved after T-PTK ($P=0.0092$, $P=0.0022$, and $P=0.0002$, respectively). None of the subjects lost any lines of CDVA, developed recurrence of pterygia or required keratoplasty during the postoperative period.

• **CONCLUSION:** ASOCT T-PTK can provide excellent visual and anatomic outcomes in patients with central corneal scarring after excision of visual axis-involving pterygia.

• **KEYWORDS:** pediatric; penetrating eye injury; traumatic endophthalmitis; pars plana vitrectomy

DOI:10.18240/ijo.2020.03.20

Citation: Rush SW, Rush RB. Anterior segment optical coherence tomography-guided transepithelial phototherapeutic keratectomy for scarring of the central cornea following pterygium excision. *Int J Ophthalmol* 2020;13(3):503-508

INTRODUCTION

The incidence of pterygia in some parts of the world has been reported to be as high as 2.1 per 1000, where up to 0.8 per 1000 have undergone pterygium excision^[1]. Many different techniques and adjunctive measures have been described for removal of both primary and recurrent pterygia^[2]. When the pterygium involves the visual axis, the vision can be decreased not only by the irregular astigmatic refractive aberrations induced on the corneal topography, but also by directly obscuring the central visual axis^[3]. Recent studies have shown that a successful pterygium excision will still result in variable amounts of anterior corneal scarring^[4]. Long-term data from these same studies have shown that, while the density of the anterior opacity will diminish over time, the central and posterior portions of the opacity will persist^[5].

In an attempt to mitigate the ill-effects of anterior corneal stromal scarring following pterygium excision, several investigators have described phototherapeutic keratectomy (PTK) application to the newly debrided wound during the same procedure as the pterygium excision^[6-8]. PTK performed at a later date has also been reported to manage residual astigmatism following pterygium excision^[9]. Now with the advent of anterior segment optical coherence tomography (ASOCT), not only can the pterygium be visualized separating the corneal epithelium from Bowman's layer^[10], but ASOCT can effectively guide transepithelial phototherapeutic keratectomy (T-PTK) during the treatment of corneal opacities associated with irregular astigmatism^[11]. The authors previously described a T-PTK technique in which an ASOCT-measured treatment depth computation was applied to address an irregularly shaped Bowman's layer^[12]. In this study, the authors report on this ASOCT T-PTK technique in patients with central corneal scarring following visual axis-involving pterygium excision.

SUBJECTS AND METHODS

Ethical Approval An Institutional Review Board (SRS-IRB9122) authorized this retrospective case study of patients with central corneal scarring after pterygium excision who underwent ASOCT T-PTK from July 2013 through July 2017 at an ophthalmology practice facility in Amarillo, TX, USA. All research components were performed in adherence to the Declaration of Helsinki principles and in harmony with human study regulations.

Patients that underwent ASOCT T-PTK using the Wavelight EX500 platform (Alcon, TX, USA) for the management of scarring involving the central cornea after visual axis-involving pterygium excision were included into the study. A visual axis-involving pterygium was defined as the leading edge of the pterygium located within 3 mm of the center of the pupil on slit lamp examination. Corneal scarring after pterygium excision was defined according to the presence of an abnormal Bowman's layer in the central cornea. An abnormal Bowman's layer was determined according to the following features: ASOCT (Cirrus HD-OCT; Meditec, USA) of the central 3 mm of the cornea had a hyper-intense signal that matched the opacity observed on clinical examination, and the epithelial thickness was at least 33% greater than the baseline epithelial thickness (*i.e.*, epithelial cratering effect at the location of the opacity at its deepest measured depth is at minimum 33% thicker than epithelial thickness measured at a healthy portion of the central cornea). The baseline data collected from each subject was subject age (y), gender (M/F), operative eye (OD/OS), lens status (phakic/pseudophakic), pterygium characteristics, uncorrected distance visual acuity (UDVA), best corrected distance visual acuity (CDVA) with manifest refraction and tomographic-measured indices on the TMS-4N Topographer (Tomey; USA), which included corneal cylinder, surface regularity index (SRI), surface asymmetry index (SAI), and projected visual acuity (PVA).

The UDVA, CDVA and topography indicators were recorded at 4±1mo after pterygium excision. Subjects then underwent ASOCT T-PTK 6±2mo after pterygium excision. The final data was collected 6±2mo after ASOCT T-PTK. The JMP 11 statistical software (SAS Institute, USA) analyzed distributions and calculated means with standard deviations. A comparison of the baseline measurements with the post-terygium excision measurements, and a comparison of the post-terygium excision measurements with the measurements after ASOCT T-PTK was made using one-way analysis of the variance (ANOVA). Outcomes were considered significant at the alpha <0.05 level. Visual acuity improvement or worsening was considered significant if there was a change by logMAR 0.3 or more.

Pterygium Excision Technique Subjects underwent the following standardized surgical technique under local retrobulbar anesthesia. The pterygium was excised using Westcott scissors down to bare sclera including the debulking of excessive subconjunctival Tenon's proliferation. Low temperature cautery was used for hemostasis. A crescent blade was used to debride superficial fibrotic tissue over the bare sclera, limbus and corneal stroma. A burr was used to polish any visible residual opacity on the cornea. Liquid nitrogen cryotherapy was used along the corneal limbus^[13]. This was followed by topical application of mitomycin C (0.02%) on a surgical sponge for 2min followed by vigorous irrigation^[14]. Finally, the bare scleral wound was closed with an amniotic membrane using fibrin glue^[15]. Patients were treated topically during the postoperative period with ofloxacin 0.3% QID for 1wk and prednisolone acetate 1% QID tapered over 2mo.

Phototherapeutic Keratectomy Technique Subjects underwent a previously described standardized T-PTK protocol under local anesthesia^[12,16]. In summary, ASOCT images were used to determine the total corneal pachymetry, the epithelial thickness at the center of the cornea and the maximum extent of the opacity following pterygium removal. With these data, the excimer laser treatment parameters were calculated for eliminating or minimizing the central corneal opacification in order to give the desired spherical equivalent outcome. Minimum residual stromal depth was set at 250 µm, and the ablation optic zone varied from 6.5 to 8.0 mm depending upon the preset protocol. The T-PTK treatment included application of topical mitomycin C (0.02%) and bandage contact lens placement at the surgery's conclusion. Topical prednisolone acetate 1% QID and ofloxacin 0.3% QID were applied to the operative eye for 3wk after the treatment. The bandage contact lens was taken out after 1wk. Figures 1-5 provide case examples of two of the subjects included in the study.

RESULTS

There were 11 eyes of 10 subjects included in the study's analysis. The mean follow-up was 7.55±5.82mo after the T-PTK procedure. The mean time for T-PTK after pterygium excision was 4.33±1.12mo. A summary of the study population's baseline demographics and preoperative pterygium characteristics are presented in Table 1. Five of the pterygia included in the study were recurrent in nature with 3 of those 5 having had more than three recurrences. In terms of concurrent comorbidities, one patient had well-controlled diabetes mellitus and one patient had a history of successful macular hole surgery.

Visual Outcomes After Pterygium Excision The pterygium excision occurred uneventfully and without notable intraoperative or postoperative complications in all 11 eyes. The UDVA and CDVA significantly improved from the

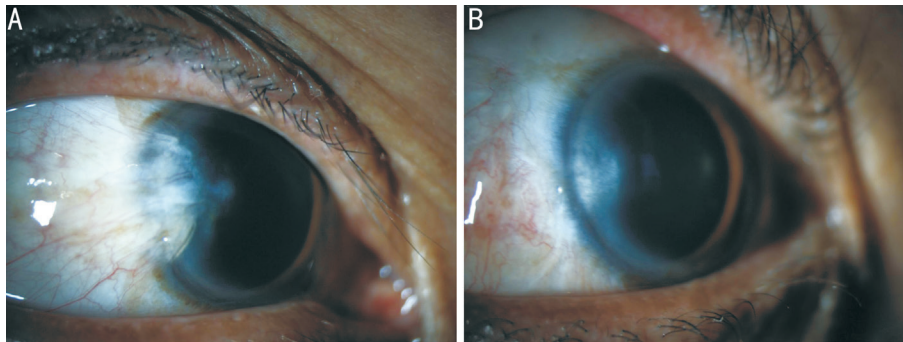


Figure 1 Case study 1: external slit lamp photographs before and after treatment by pterygium excision A: Preoperative external slit lamp photograph of a 52-year-old male with a recurrent temporal pterygium involving the visual axis. Central extension of the leading edge of the pterygium is apparent. B: Postoperative external slit lamp photograph of the same patient 4mo after pterygium excision. The temporal pterygium has been excised without recurrence, but residual corneal opacity is seen.

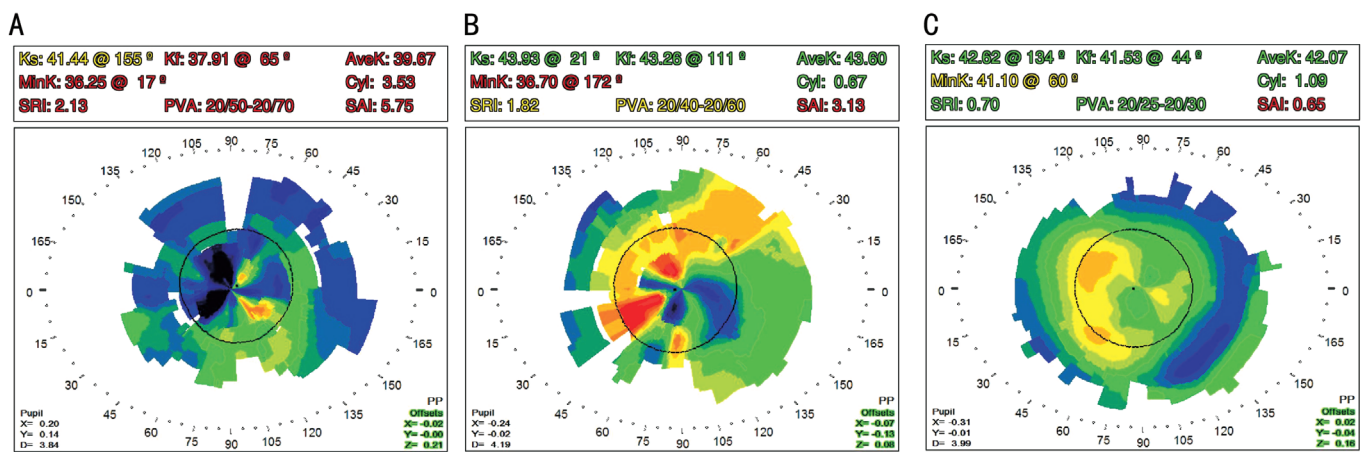


Figure 2 Case study 1: corneal topography prior to and following treatment by pterygium excision and T-PTK A: Preoperative corneal topography of the same 52-year-old subject from Figure 1. Prominent irregularity of the cornea is readily evident. The manifest refraction visual acuity at distance prior to surgery was 20/1000. B: Corneal topography of the same subject 4mo after pterygium excision. The corneal shape is improved, but centrally is still quite irregular secondary to scarring. The manifest refraction distance visual acuity improved to 20/60. C: Corneal topography of the same patient in A and B 6mo after T-PTK. Corneal irregularity has substantially improved. The manifest refraction visual acuity at distance improved to 20/25 with a refraction of +0.50 +1.00×152.

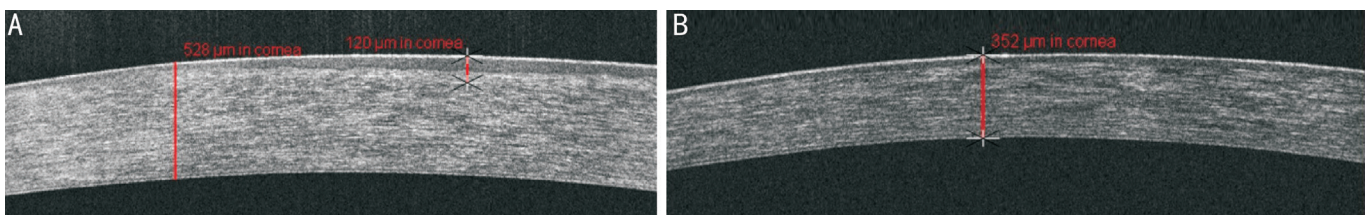


Figure 3 Case study 1: optical coherence tomography of the cornea prior to and following treatment by pterygium excision and PTK A: Optical coherence tomography 4mo after pterygium excision in the same 52-year-old patient from Figures 1 and 2. Central scarring and irregularity of Bowman's layer are observed. The maximum depth of the corneal scar measured by a manual electronic caliper (red lines) is at 120 μm with a total corneal thickness of 528 μm. Calculations were made to ablate to a depth of 140 μm using T-PTK in order to maintain refractive neutrality. B: Optical coherence tomography of the cornea in the same study subject 6mo after undergoing PTK. Following a total stromal ablation depth of 140 μm, the stromal scarring has been resolved with marked improvement in uniformity of the epithelium and regularity of Bowman's layer. Corneal pachymetry is now stable at 352 μm.

baseline level after pterygium excision ($P=0.03$ and $P=0.05$, respectively). However, no significant changes in any of the corneal topographic parameters analyzed were observed. These outcomes are summarized in Table 2.

Visual Outcomes after Transepithelial Phototherapeutic Keratectomy The subsequent T-PTK procedure after pterygium excision occurred uneventfully and without notable intraoperative or postoperative complications in

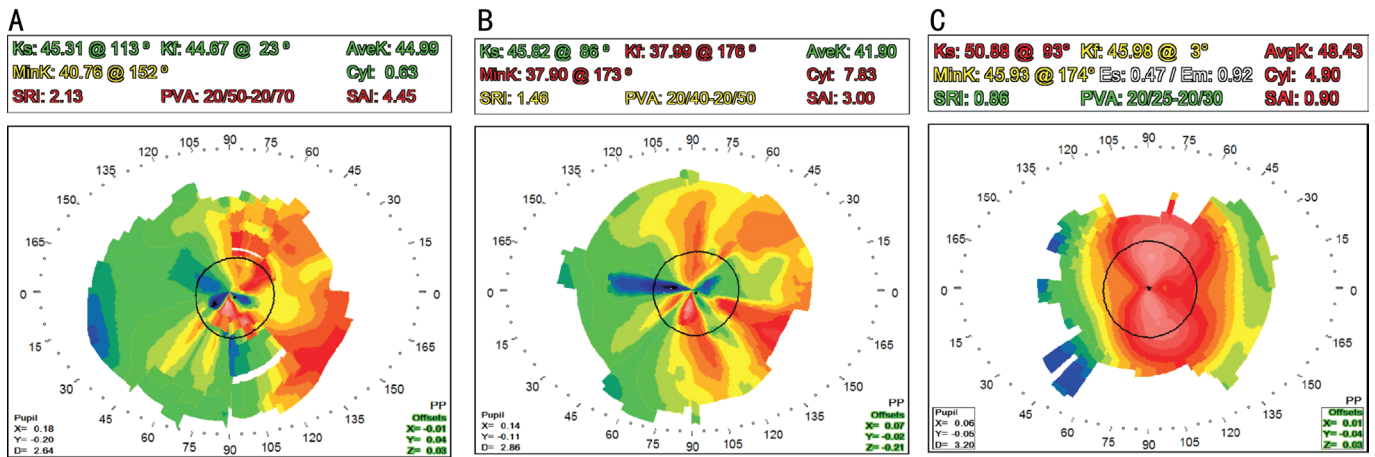


Figure 4 Case study 2: topography of the cornea prior to and following treatment by pterygium excision and T-PTK A: Corneal topography of a 56-year-old male with a recurrent nasal pterygium involving the visual axis. Substantial surface irregularity is evident. The preoperative manifest refraction visual acuity at distance was 20/80. B: Corneal topography of the same subject 4mo after pterygium excision. The corneal irregularity indices and PVA show modest improvement, and manifest refraction distance visual acuity improved minimally to 20/60. C: Topography of the cornea in the same subject as A and B 6mo after T-PTK. Corneal irregularity shows substantial improvement albeit with high regular astigmatism. The manifest refraction visual acuity at distance improved to 20/20 with a refraction of -3.75+5.50×100.

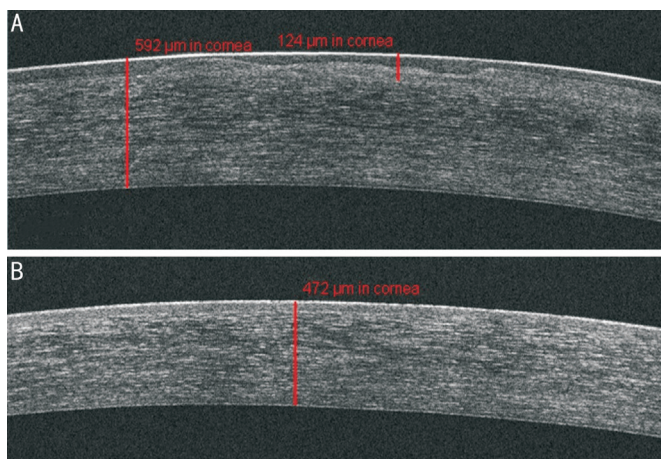


Figure 5 Case study 2: optical coherence tomography of the cornea prior to and following treatment by pterygium excision and T-PTK A: Corneal optical coherence tomography 4mo after pterygium excision in the same 56-year-old patient from Figure 4. Central scarring of the cornea and conspicuous irregularity of Bowman’s layer with cratering is apparent. Maximum depth of the corneal scar measured by a manual electronic caliper (red lines) is at 124 μm with a total corneal thickness of 592 μm. Calculations were made to perform T-PTK to a depth of 140 μm in order to maintain refractive neutrality. B: Optical coherence tomography of the cornea for the same subject 6mo after T-PTK. Following a total stromal treatment depth of 140 μm, the stromal scarring is resolved with homogeneity of the epithelium restored. Corneal pachymetry has stabilized at 472 μm.

all 11 cases. The UDVA and CDVA significantly improved from the post-ptyerygium excision findings ($P=0.004$ and $P=0.001$, respectively). Except for topographic cylinder, all topographic indices significantly improved. These outcomes are summarized in Table 3.

Table 1 Baseline demographics and pterygium characteristics of the research group $n=11$ eyes

Characteristics and demographics	Mean±SD
Age (y)	64.3±10.7 (range 52-83)
Gender (M/F)	9/1
Operative eye	72.7% right eye and 27.3% left eye
Lens status	63.6% phakic and 36.4% pseudophakic
Pterygium type, n (%)	
Primary	6 (54.5)
Recurrent	5 (45.5)
Pterygium location(s), n (%)	
Nasal	6 (54.5)
Temporal	1 (9.1)
Nasal and temporal	4 (36.4)

Final Refractive Outcomes Six months after T-PTK, spherical equivalent was $0.33±1.85$ D; 7 subjects had some degree of hyperopia while 4 of the subjects had some degree of myopia. None of the subjects had anisometropia as defined by a difference in spherical equivalent of three diopters or more between eyes. Total refractive astigmatism during the final follow-up examination was $1.18±0.84$ D. One patient underwent cataract surgery 4mo after the T-PTK treatment. No subjects lost any lines of CDVA after either the pterygium excision or T-PTK procedure. There were no complications with delayed epithelial healing, IOP elevation, pterygium or corneal scarring/haze recurrence during the study’s follow-up period, and no subjects underwent further surgery by keratoplasty, intraocular lens exchange or had an additional excimer laser treatment session during the research period.

Table 2 Visual and topographic results following pterygium excision

n=11 eyes

Outcome measures	Values at baseline means with (95%CI)	Post-terygium excision values means with (95%CI)	<i>P</i>
Uncorrected distance visual acuity (logMAR)	1.26 (0.98-1.55); range 0.54-2.5	0.82 (0.53-1.11); range 0.48-1.3	0.0340
Manifest refraction distance visual acuity (logMAR)	1.06 (0.74-1.37); range 0.4-2.5	0.62 (0.30-0.93); range 0.4-1.3	0.0513
Topographic cylinder	5.57 (3.78-7.37); range 1.99-12.1	4.44 (2.56-6.32); range 1.55-8.89	0.3738
Topographic surface asymmetry index	4.36 (3.07-5.64); range 1.40-7.34	3.46 (2.17-4.74); range 1.25-8.67	0.3136
Topographic surface regularity index	1.78 (1.52-2.04); range 0.86-2.56	1.76 (1.49-2.02); range 1.31-2.42	0.8882
Topographic projected visual acuity (logMAR)	0.44 (0.36-0.52); range 0.2-0.6	0.42 (0.34-0.50); range 0.25-0.7	0.69

Table 3 Visual and topographic results following T-PTK

n=11 eyes

Outcome measures	Post-terygium excision values means with (95%CI)	Post-PTK values means with (95%CI)	<i>P</i>
Distance visual acuity uncorrected (logMAR)	0.82 (0.67-0.97); range 0.48-1.3	0.50 (0.35-0.64); range 0.2-0.88	0.0041
Manifest refraction visual acuity at distance (logMAR)	0.62 (0.46-0.77); range 0.4-1.3	0.25 (0.09-0.40); range 0.0-0.7	0.0019
Topographic cylinder value	4.44 (3.07-5.81); range 1.55-8.89	3.56 (2.11-5.01); range 0.63-5.62	0.3651
Topographic surface asymmetry index value	3.46 (2.43-4.48) range 1.25-8.67	1.41 (0.33-2.48); range 0.43-3.0	0.0092
Topographic surface regularity index value	1.76 (1.46-2.05); range 1.31-2.42	1.03 (0.72-1.34); range 0.18-1.81	0.0022
Topographic projected visual acuity (logMAR)	0.42 (0.34-0.50); range 0.25-0.7	0.17 (0.08-0.25); range 0.0-0.4	0.0002

DISCUSSION

To the knowledge of the authors, this is the first case series to report successful use of T-PTK to address both the corneal scarring and irregular astigmatism following pterygium excision. All 11 eyes of the 10 patients studied showed improvement in visual acuity. The staged T-PTK treatment described in this study, as opposed to the previously described techniques using intraoperative excimer laser technology at the time of pterygium excision^[6-8], offers the advantage of allowing the ocular surface some healing time in order to get more accurate measurements of the central opacity that is likely to occur after the excision of an advanced pterygium involving the visual axis. Application of corneal OCT and more advanced T-PTK techniques on wavefront optimized excimer laser platforms offer additional benefits by taking advantage of the natural masking effects of the epithelium, thereby correcting irregular astigmatism with a more predictable refractive outcome. The results of this study show that, while visual outcomes improve after removal of the pterygium from the visual axis alone, the central corneal opacity left behind still results in considerable visual deficit with persistent topographic irregularities. Our study demonstrates that a staged ASOCT T-PTK approach to address the central corneal scarring after pterygium excision can further improve the visual acuity as well decrease the amount of irregular astigmatism. It is noteworthy that all topographic indices

measuring corneal surface regularity significantly improved after T-PTK except for cylinder. This suggests that the gross amount of astigmatism may not change, but the astigmatism which is correctable with glasses can be markedly improved following T-PTK.

Other surgical therapeutic options for the treatment of corneal opacities in this clinical setting include both penetrating keratoplasty and deep anterior lamellar keratoplasty. The principal advantage of T-PTK is that it avoids more invasive surgery without lifetime risk for graft rejection and the longer vision recovery times associated with keratoplasty. Our dataset shows that topographic cylinder may be comparable or even decreased compared to the anticipated surgically induced astigmatism that will occur after corneal transplantation. But keratoplasty is necessary when the corneal opacity is too dense for excimer laser pupil tracking to occur. Unsuccessful attempt or unsatisfactory outcome with T-PTK do not preclude subsequent treatment with keratoplasty.

This study has weaknesses, which include a design that is retrospective, the lack of a control group, a low number of study subjects and a follow-up window that is short. The authors also recognize that a learning curve exists with the ASOCT T-PTK planning and surgical technique described by this study. More research is needed to further corroborate the PTK method described by the authors in the patient population included in this study. In conclusion, ASOCT T-PTK can

provide outstanding results in subjects with central corneal scarring and irregular astigmatism following previous excision of a visual axis-involving pterygium.

ACKNOWLEDGEMENTS

Conflicts of Interest: Rush SW, None; Rush RB, None.

REFERENCES

- 1 Rim TH, Kang MJ, Choi M, Seo KY, Kim SS. The incidence and prevalence of pterygium in South Korea: a 10-year population-based Korean cohort study. *PLoS One* 2017;12(3):e0171954.
- 2 Hacıoğlu D, Erdöl H. Developments and current approaches in the treatment of pterygium. *Int Ophthalmol* 2017;37(4):1073-1081.
- 3 Vanathi M, Goel S, Ganger A, Agarwal T, Dada T, Khokhar S. Corneal tomography and biomechanics in primary pterygium. *Int Ophthalmol* 2018;38(2):663-671.
- 4 Kam KW, Belin MW, Young AL. Monitoring corneal densities following primary pterygium excision with adjuvant topical mitomycin-C application—an observational study of corneal scar changes. *Cornea* 2015;34(5):530-534.
- 5 Kam KW, Kwok RP, Belin MW, Young AL. Long-term density changes in corneal layers after primary pterygium excision with topical mitomycin-C. *Cornea* 2016;35(8):1093-1096.
- 6 Walkow T, Daniel J, Meyer CH, Rodrigues EB, Mennel S. Long-term results after bare sclera pterygium resection with excimer smoothing and local application of mitomycin C. *Cornea* 2005;24(4):378-381.
- 7 Talu H, Taşındı E, Ciftci F, Yildiz TF. Excimer laser phototherapeutic keratectomy for recurrent pterygium. *J Cataract Refract Surg* 1998;24(10):1326-1332.
- 8 Promesberger J, Kohli S, Busse H, Uhlig CE. Pterygium recurrence, astigmatism and visual acuity following bare-sclera excision and conjunctival autograft with or without additional phototherapeutic keratectomy. *Ophthalmic Res* 2014;51(1):52-58.
- 9 Walkow T, Anders N, Wollensak J. Corneal astigmatism after pterygium excision and subsequent phototherapeutic keratectomy with the excimer laser (193 nm). *Klin Monbl Augenheilkd* 1996;209(4):199-204.
- 10 Lim SH. Clinical applications of anterior segment optical coherence tomography. *J Ophthalmol* 2015;2015:605729.
- 11 Li Y, Yokogawa H, Tang ML, Chamberlain W, Zhang XB, Huang D. Guiding flying-spot laser transepithelial phototherapeutic keratectomy with optical coherence tomography. *J Cataract Refract Surg* 2017;43(4):525-536.
- 12 Rush SW, Matulich J, Rush RB. Long-term outcomes of optical coherence tomography-guided transepithelial phototherapeutic keratectomy for the treatment of anterior corneal scarring. *Br J Ophthalmol* 2014;98(12):1702-1706.
- 13 Fraunfelder FW. Liquid nitrogen cryotherapy of pterygia. *Ophthalmology* 2013;120(10):e70.
- 14 Martins TGS, Costa ALFA, Alves MR, Chammas R, Schor P. Mitomycin C in pterygium treatment. *Int J Ophthalmol* 2016;9(3):465-468.
- 15 Rosen R. Amniotic membrane grafts to reduce pterygium recurrence. *Cornea* 2018;37(2):189-193.
- 16 Rush SW, Han DY, Rush RB. Optical coherence tomography-guided transepithelial phototherapeutic keratectomy for the treatment of anterior corneal scarring. *Am J Ophthalmol* 2013;156(6):1088-1094.