

Ecstasy-induced optic disc swelling and consequent visual loss

Michaela Ramsauer, Stephan Thurau, Siegfried Priglinger, Efstathios Vounotrypidis

Department of Ophthalmology, Ludwig-Maximilians-University, Munich 80336, Germany

Correspondence to: Michaela Ramsauer. Department of Ophthalmology, Ludwig-Maximilians-University, Mathildenstraße 8, Munich 80336, Germany. Michaela.Ramsauer@med.uni-muenchen.de

Received: 2019-06-26 Accepted: 2019-08-27

DOI:10.18240/ijo.2020.03.24

Citation: Ramsauer M, Thurau S, Priglinger S, Vounotrypidis E. Ecstasy-induced optic disc swelling and consequent visual loss. *Int J Ophthalmol* 2020;13(3):520-522

Dear Editor,

We present the first reported case of unilateral optic disc swelling with subsequent persistent loss of vision triggered by ecstasy consumption in the case of a young man.

Ecstasy is one of the most commonly consumed recreational drugs among young adults. Its main constituent and active substance is 3,4-methylenedioxymethamphetamine (MDMA), a psychoactive amphetamine derivative^[1]. The main reasons why the illegal consumption of this drug is so popular are its mental and behavioural effects: MDMA elicits a euphoric and entactogen mood as well as pro-social behaviour. However, MDMA can have serious side effects on the central nervous and cardiovascular systems. Effects on the latter seem to be responsible for the unilateral optic disc swelling with acute and persisting vision loss described in the following case.

A 31-year old Caucasian male presented to the Department of Ophthalmology at Ludwig-Maximilians-University, Munich, with acute vision loss in his left eye. According to the patient, this symptom occurred a few hours after consuming ecstasy. He complained about blurred vision similar to fog in the relevant eye. As stated by the patient, the vision loss started with flickering that lasted for 10s. No vision changes were noticed at his right eye. A detailed patient medical history (PMH) revealed that this was the second time of ecstasy consumption. No previous ocular, cardiovascular, metabolic, infectious or neurological diseases were reported. Moreover, he was not routinely taking any medication.

Clinical examination revealed bilateral mild hyperopia of +0.25 spherical dioptres (D). Uncorrected distance visual acuity was 20/20 in the right and 20/100 in the left eye (Snellen); intraocular pressure was 16 and 18 mm Hg, respectively. The examination verified a relative afferent pupillary defect (RAPD) and an alleviated direct light reaction in the left eye. No motility obstruction or double vision was found. Fundoscopy of the left eye revealed a severe swelling of the optic disc with blurred optic disc margins and flame-shaped haemorrhages. The macula, peripheral retina, vitreous and anterior segment were unremarkable. No pathologies and, in particular, no disc at risk were found in the right eye.

The patient had slightly elevated blood pressure at 145/73 mm Hg, but a normal heart rate of 82 pulses per minute. White and red blood cell counts, electrolytes, kidney values, liver transaminases, C-reactive protein and coagulation parameters including lupus anticoagulant ranged within their normal limits. Screening for rheumatic diseases including rheumatoid factor, antinuclear antibodies, anti-neutrophil cytoplasmic antibodies and complement factor C3 and C4 was negative.

Optical coherence tomography showed the extent of optic disc swelling in the left eye (Figure 1) and confirmed a normal macula morphology.

A 30°-visual field examination revealed extensive defects of the whole visual field of the left eye with a mean deviation of -33.65 dB and a visual field index of 0 (data not shown). Therefore, Goldmann perimetry was performed and showed a small central residual visual field in the left eye (Figure 2).

A fluorescein angiography (FA) showed a hyperfluorescent optic disc with late leakage in the left eye (Figure 3). Retinal artery or vein occlusion were excluded. The pattern reversal visual evoked potentials (VEP) and the flash-VEP did not demonstrate any reproducible potentials in the left eye indicating serious optic nerve pathology (Figure 4). The Arden colour contrast test showed complete colour vision disturbance in both axes of protanopia (>100%, normal range ≤6%) and tritanopia (>100%, normal range ≤8%). None of the above exams showed any abnormalities in the right eye.

Visual acuity worsened slowly to perception of hand movements over the following few days, whereas other clinical findings did not change. Intravenous, pulse therapy with 1000 mg

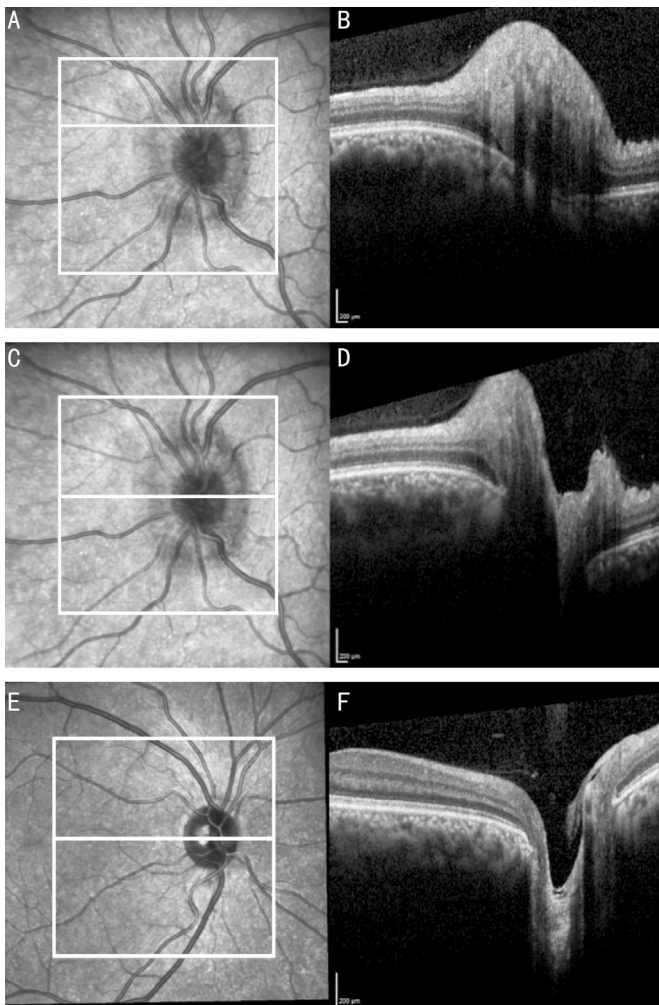


Figure 1 Optical coherence tomography of the optic disc A-D: The swelling of the optic disc in the left eye; E, F: The optic disc of the right eye shows its normal configuration.

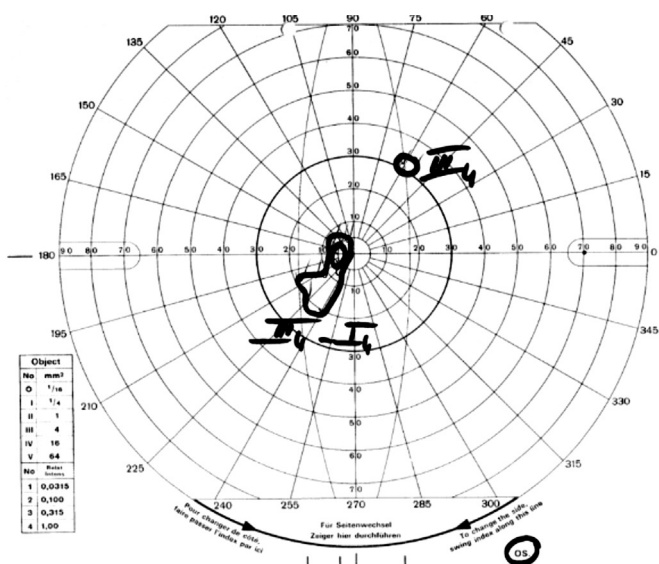


Figure 2 Goldmann perimetry of the left eye indicating a small remaining central residual visual field.

prednisolone per day, was applied for three consecutive days, but did not improve visual acuity. The cerebrospinal fluid (CSF) examination was unremarkable (normal levels of

albumin, total protein, glucose, cell count and immunoglobulin G (IgG), normal quotients CSF/serum IgG and CSF/serum albumin and normal IgG index). Neurological examination including cranial CT and MRI, plus MRI of the whole spine, was also unremarkable ruling out a demyelinating disease, such as multiple sclerosis.

The patient was treated again with intravenous pulse therapy of 1000 mg prednisolone per day, for 5d consequently with a subsequent oral tapered-dose reduction. In the follow-up examination, the optic disc swelling disappeared and the haemorrhage resolved. Visual acuity improved to 20/160 (Snellen). However, three weeks after the onset of symptoms, RAPD persisted and the first signs of optic atrophy were clinically observed in the fundus biomicroscopy. No further improvement or recurrence occurred.

Because of the direct link between vision loss and ecstasy consumption and the negative PMH with regard to ocular, cardiovascular or inflammatory central nervous system diseases, the drug abuse was considered as the most likely precipitator of the optic disc swelling.

In addition to addiction to the drug, MDMA is known for its potential to cause serious cardiovascular side effects. In the literature, MDMA is reported to cause retinal and intracerebral haemorrhage and intravascular thrombosis. These complications are assumed to be associated with MDMA-induced elevation of noradrenaline levels, which provoke hypertension and tachycardia. Consequently, the risk of clot formation and haemorrhage by vessel rupture increases^[1-5]. Furthermore, MDMA may induce vasoconstriction by amplifying the potent vasoconstrictor properties of serotonin in the brain circulation^[3]. In this context, a non-arteritic anterior ischemic optic neuropathy (NAION) induced by MDMA and its cardiovascular side effects probably explain the swollen optic disc of the young male. The flame-shaped haemorrhages, the lack of vitreous cells, the progressive vision deterioration, the absence of alterations in blood and CSF values and the inadequate treatment response support our assumption and also agree with this diagnosis.

Unfortunately, ecstasy is often consumed with other drugs and substances such as alcohol, dextromethorphan or cocaine. Such a combination might increase the risk profile of MDMA. However, the patient in the presented case denied consumption of other drugs.

In the literature, few reports describe vision problems after consumption of ecstasy. In addition to the previously mentioned retinal haemorrhage^[2], these include impairment in visual processing and visual perception^[6-7]. A Serbian article presents a patient complaining for visual deterioration and severe pain in the left eye attributable to elevated intraocular pressure after ecstasy consumption. This was thought to be

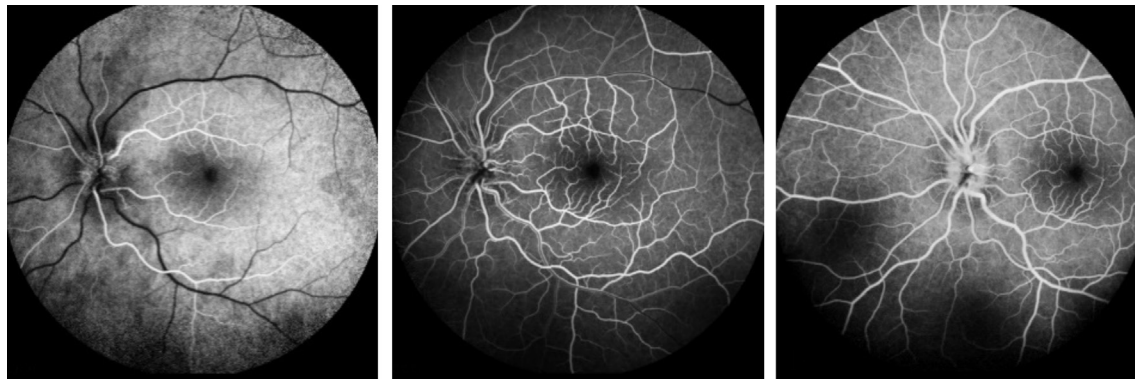


Figure 3 FA of the left eye.

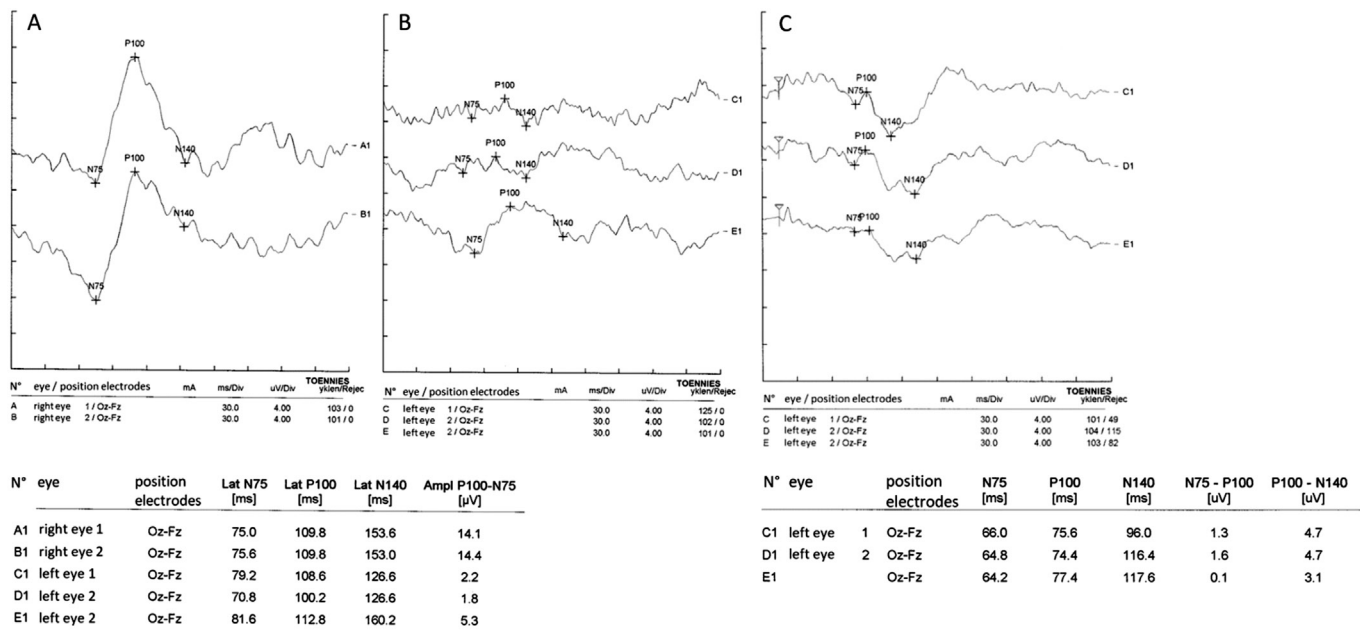


Figure 4 Pattern reversal VEP showing reproducible potentials in the right eye (A), pattern reversal VEP (B) and flash VEP (C) showing no reproducible potentials in the left eye.

induced by mydriasis in response to an increased release of monoamine neurotransmitters by MDMA in a predisposed patient with a rare unilateral iris plateau syndrome^[8].

However, MDMA is a drug that can seriously affect the cardiovascular system. In this context, its consumption may have dramatic consequences with regard to the visual system. To our knowledge, this is the first report of a case with acute persisting vision loss induced by sporadic MDMA use.

ACKNOWLEDGEMENTS

Conflicts of Interest: Ramsauer M, None; Thurau S, None; Priglinger S, None; Vounotrypidis E, None.

REFERENCES

1 Kalant H. The pharmacology and toxicology of “ecstasy” (MDMA) and related drugs. *J De L’association Med Can* 2001;165(7):917-928.
 2 Jacks AS, Hykin PG. Retinal haemorrhage caused by “ecstasy”. *Br J Ophthalmol* 1998;82(7):842-843.
 3 Hanyu S, Ikeguchi K, Imai H, Imai N, Yoshida M. Cerebral infarction

associated with 3, 4-methylenedioxymethamphetamine (‘Ecstasy’) abuse. *Eur Neurol* 1995;35(3):173.

4 Johnson J, Patel S, Saraf-Lavi E, Aziz-Sultan MA, Yavagal DR. Posterior spinal artery aneurysm rupture after ‘ecstasy’ abuse. *J Neurointerv Surg* 2015;7(7):e23.
 5 Vasan S, Olango GJ. Toxicity, Amphetamine. StatPearls. <https://www.ncbi.nlm.nih.gov/books/NBK470276/>. Accessed on June 11, 2018.
 6 Parrott AC, Downey LA, Roberts CA, Montgomery C, Bruno R, Fox HC. Recreational 3, 4-methylenedioxymethamphetamine or ‘ecstasy’: current perspective and future research prospects. *J Psychopharmacol (Oxford)* 2017;31(8):959-966.
 7 Passie T, Schneider U, Emrich HM. Persisting continuous visual perception disorder in a chronic MDMA (‘ecstasy’) user. *Aust N Z J Psychiatry* 2002;36(2):266-267.
 8 Jovanović P, Hentova-Senčanić P, Zorić L, Petrović M, Božinović MT. Unilateral iris plateau syndrome after the use of ecstasy. *Vojnosanit Pregl* 2009;66(6):487-489.