

A non-contiguous recurrence of the ciliary body melanoma—is cataract surgery a risk factor?

Biljana Kuzmanović Elabjer¹, Mladen Bušić¹, Mirjana Bjeloš¹, Daliborka Miletić¹, Nenad Vukojević²

¹University Eye Clinic, Faculty of Dental Medicine and Health Care Osijek, Faculty of Medicine Osijek, University Josip Juraj Strossmayer in Osijek, University Hospital “Sveti Duh”, Zagreb 10000, Croatia

²University Eye Clinic, University Hospital Centre Zagreb, Zagreb 10000, Croatia

Correspondence to: Mladen Bušić. University Eye Clinic, Faculty of Dental Medicine and Health Care Osijek, Faculty of Medicine Osijek, University Josip Juraj Strossmayer in Osijek, University Hospital “Sveti Duh”, Zagreb 10000, Croatia. mbusic@kbsd.hr

Received: 2018-08-03 Accepted: 2019-11-25

DOI:10.18240/ijo.2020.04.24

Citation: Kuzmanović Elabjer B, Bušić M, Bjeloš M, Miletić D, Vukojević N. A non-contiguous recurrence of the ciliary body melanoma—is cataract surgery a risk factor? *Int J Ophthalmol* 2020;13(4):681-683

Dear Editor,

We would like to present a case of non-contiguous recurrence of ciliary body melanoma following cataract surgery, detected by ultrasound biomicroscopy (UBM), three years after ruthenium-106 (¹⁰⁶Ru) brachytherapy. Ultrasound biomicroscopy is a crucial tool in analysis of localization, size, and borders of the ciliary body tumours, local invasion, and follow-up after treatment^[1]. According to the guidelines^[2], examination of treated eyes should be performed every 3-6mo following brachytherapy, actively searching for complications or tumour recurrence. Local recurrence of ciliary body melanoma treated with iodine-125 plaque or proton irradiation has been described as a ring melanoma^[3-4]. However, extensive literature search demonstrated no report of non-contiguous local recurrence of the ciliary body melanoma following cataract surgery, previously treated with ¹⁰⁶Ru plaque.

CASE REPORT

In November 2017, a 78-year-old Caucasian female underwent regular follow-up with UBM Lin 50 probe (Aviso™, Quantel Medical, Paris, France) after the uneventful ¹⁰⁶Ru CCB plaque (BEBIG GmbH, Germany) radiation of ciliary body melanoma of the left eye.

The initial UBM examination at our clinic was in November 2014, after the referral from another institution were all other medical procedures took place. At that time, the tumour was found at 6 o'clock, with the basal dimension of 3.84 mm and the largest mean prominence perpendicular to sclera, including scleral thickness, of 5.02 mm (Figure 1A). Its internal reflectivity on standardized echography was 75% and the thickness of 3.5 mm. Although the tumour clinically appeared as malignant melanoma, its high internal reflectivity indicated fine needle aspiration biopsy that was inconclusive. Detailed whole body examination found no primary tumour that would claim for metastatic disease. The ¹⁰⁶Ru plaque was removed after five days achieving the radiation dose at the tumour apex of 100 Gy.

On regular UBM follow-ups that always included examination of the 360° anterior eye segment circumference a tumor regression *i.e.* reduction in size and increase of internal reflectivity was observed, with no evidence of recurrence at the rest of eye circumference. As a post-irradiation complication cataract was formed. In January 2017 the patient underwent an uneventful cataract surgery with clear corneal incision at 90° and the side port 45° temporal to it. On check up visit in May 2017, the UBM findings were unchanged.

Six months later, UBM of residual tumour at 6 o'clock remained almost the same (Figure 1B). However, the new lesion was detected at 12-2 o'clock, with the basal dimension of 3.96 mm and the largest mean prominence perpendicular to sclera, including scleral thickness, of 4.01 mm. Its internal reflectivity on standardized echography was 62% and the thickness of 3.57 mm (Figure 2). The rest of the circumference was free of tumour, ruling out a ring melanoma.

Staging prior to enucleation proved no metastatic disease. Histopathology of the newfound tumour confirmed the malignant melanoma, 80% being epithelioid cells. No tissue change pertinent to brachytherapy was found around this melanoma indicating that this is the new, non treated tumour. Also, the surrounding tissue was free of tumourous cells, again ruling out the ring melanoma.

All procedures performed in this study were in accordance with the ethical standards of the Institutional Research Committee and with the 1964 Helsinki Declaration and its later amendments. Informed consent was obtained from the patient.

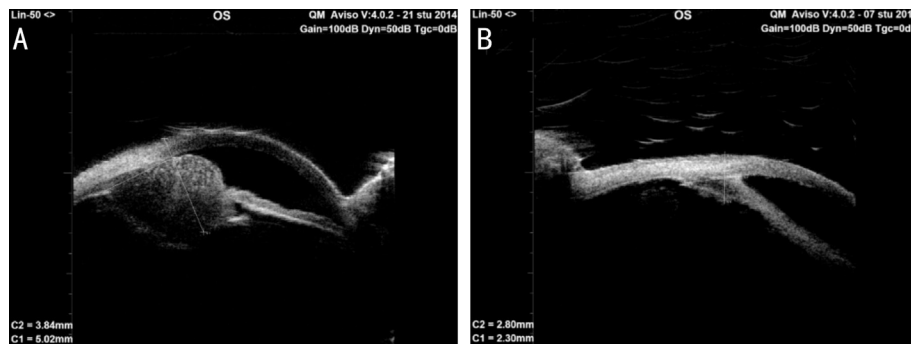


Figure 1 UBM of the ciliary body tumour at 6 o'clock A: Initial findings with the basal dimension of 3.84 mm and the largest mean prominence perpendicular to sclera, including scleral thickness of 5.02 mm; B: The same tumour 3y after ¹⁰⁶Ru brachytherapy and 10mo after cataract surgery. The basal dimension was 2.80 mm and the largest prominence perpendicular to the sclera, including scleral thickness of 2.30 mm. During the follow-up there was no evidence of recurrence at the rest of the eye circumference.

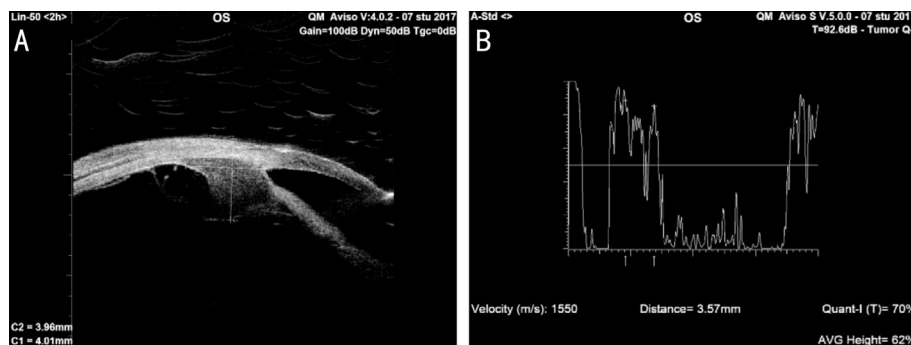


Figure 2 The new ciliary body tumour was found 10mo after cataract surgery at 12-2 o'clock A: On UBM, the basal dimension was 3.96 mm and the largest mean prominence perpendicular to sclera, including scleral thickness of 4.01 mm; B: Its internal reflectivity on standardized echography was 62% and the thickness of 3.57 mm.

DISCUSSION

Long-term follow up of patients treated for anterior uveal melanoma is mandatory since local recurrences range from 0 to 55.6%^[5]. These are associated with an increased risk of metastasis and decreased survival^[6]. UBM is the fundamental method for identifying tumour regression and treatment complications. In our practice^[1], UBM is performed in 3-6mo intervals for at least five years, always examining 360° of the eye circumference. It had crucial role in detecting the non-contiguous recurrence of ciliary body melanoma in our patient that showed up for the regular check-up visit having no complaints and no clinically visible changes on the anterior eye segment.

The non-contiguous recurrence may be attributed to the following factors.

Fine needle aspiration biopsy may cause the tumour needle tract seeding or even extraocular extension of melanoma^[7]. After smaller diameter needles have been introduced, there has been no evidence of local or systemic spread of tumour cells^[8]. In our patient transcorneal sampling at the 6 o'clock using 25 gauge needle was performed.

Cataract surgery, in our opinion, played the major role in the pathogenesis of the newfound tumour. Recurrence of

treated ciliary body melanoma were described after glaucoma surgery^[4,9]. Phacoemulsification following radiotherapy of choroidal melanoma is usually necessary^[10-11]. According to the guidelines^[2] there is no risk associated with radiation cataracts removal, but waiting of 6-12mo after brachytherapy is recommended. Cataract surgery is not known to increase the risk of metastasis of uveal melanoma previously treated with proton beam irradiation^[11].

The newfound tumour was located at 12-2 o'clock, adjacent to the corneal incisions. The authors believe that this is unlikely to be the coincidence. Full thickness wounds are known to make the extraocular spread of untreated uveal melanomas easier^[12]. We postulate that mechanical energy of the Phaco tip, both Jackhammer effect and cavitation, could have been transmitted to the still active primary tumour, causing its dissipation. The fluidics, negative pressure and surge might have been responsible for transport of tumourous cells to the corneal wounds. Microtrauma of the underlying iris and angle structures could enable entry of these cells in the bloodstream. The fact that no evidence of the tumour recurrence was found on UBM 4mo postoperatively can be explained with the tumour being too small for detection *i.e.* less than 1.1 mm in thickness^[13]. Thus, in the next six months the tumor grew close to the size of

the primary lesion, proving to be highly aggressive. Eskelin *et al*^[14] calculated the growth rate for untreated uveal melanoma to be between 34d and 220d, indicating a rational follow-up interval to detect metastatic uveal melanoma of 4-6mo. Should the patients with ciliary body melanoma previously treated with ¹⁰⁶Ru brachytherapy be monitored more closely after cataract surgery? We recommend to do so.

In conclusion, timing and location of the non-contiguous recurrence of the ciliary body melanoma previously treated with ¹⁰⁶Ru brachytherapy in our patient suggest the cataract surgery as the major culprit. Long-term close follow-up of ciliary body melanoma after brachytherapy with UBM examination that involves 360° of the anterior eye segment circumference is mandatory. More than that, in case of cataract surgery, the follow-up intervals should be much shorter than recommended. Based on the current literature evidence, the authors advocate for UBM to be clarified in the new guidelines for plaque brachytherapy of uveal melanoma as the fundamental method for identifying ciliary body tumours, their regression and complications of local treatment.

ACKNOWLEDGEMENTS

Conflicts of Interest: Kuzmanović Elabjer B, None; Bušić M, None; Bjeloš M, None; Miletić D, None; Vukojević N, None.

REFERENCES

- 1 Kuzmanović Elabjer B, Bušić M, Miletić D, Bjeloš M, Vukojević N, Bosnar D. Possible role of standardized echography complementing ultrasound biomicroscopy in tumors of the anterior eye segment: a study in a series of 13 patients. *J Ultrasound* 2018;21(3):209-215.
- 2 American Brachytherapy Society-Ophthalmic Oncology Task Force. Electronic address: paulfingert@eyecancer.com, ABS-OOTF Committee. The American Brachytherapy Society consensus guidelines for plaque brachytherapy of uveal melanoma and retinoblastoma. *Brachytherapy* 2014;13(1):1-14.
- 3 Gragoudas ES, Lane AM, Munzenrider J, Egan KM, Li WJ. Long-term risk of local failure after proton therapy for choroidal/ciliary body melanoma. *Trans Am Ophthalmol Soc* 2002;100:43-48; discussion 48-49.
- 4 Tay E, Cree IA, Hungerford J, Franks W. Recurrence of treated ciliary body melanoma following trabeculectomy. *Clin Exp Ophthalmol* 2009;37(5):503-505.
- 5 Kaliki S, Shields CL, Shields JA. Uveal melanoma: estimating prognosis. *Indian J Ophthalmol* 2015;63(2):93-102.
- 6 Ophthalmic Oncology Task Force. Local recurrence significantly increases the risk of metastatic uveal melanoma. *Ophthalmology* 2016;123(1):86-91.
- 7 Scheffler AC, Gologorsky D, Marr BP, Shields CL, Zeolite I, Abramson DH. Extraocular extension of uveal melanoma after fine-needle aspiration, vitrectomy, and open biopsy. *JAMA Ophthalmol* 2013;131(9):1220-1224.
- 8 Singh AD, Biscotti CV. Fine needle aspiration biopsy of ophthalmic tumors. *Saudi J Ophthalmol* 2012;26(2):117-123.
- 9 Sweeney AR, Keene CD, Klesert TR, Jian-Amadi A, Chen PP. Orbital extension of anterior uveal melanoma after Baerveldt tube shunt implantation. *Can J Ophthalmol* 2014;49(6):e133-e135.
- 10 Groenewald C, Konstantinidis L, Damato B. Effects of radiotherapy on uveal melanomas and adjacent tissues. *Eye (Lond)* 2013;27(2):163-171.
- 11 Gragoudas ES, Egan KM, Arrigg PG, Seddon JM, Glynn RJ, Munzenrider JE. Cataract extraction after proton beam irradiation for malignant melanoma of the eye. *Arch Ophthalmol* 1992;110(4):475-479.
- 12 Grossniklaus HE, Brown RH, Stulting RD, Blasberg RD. Iris melanoma seeding through a trabeculectomy site. *Arch Ophthalmol* 1990;108(9):1287-1290.
- 13 Weisbrod DJ, Pavlin CJ, Emara K, Mandell MA, McWhae J, Simpson ER. Small ciliary body tumors: ultrasound biomicroscopic assessment and follow-up of 42 patients. *Am J Ophthalmol* 2006;141(4):622-628.
- 14 Eskelin S, Pyrhönen S, Summanen P, Hahka-Kemppinen M, Kivelä T. Tumor doubling times in metastatic malignant melanoma of the uvea: tumor progression before and after treatment. *Ophthalmology* 2000;107(8):1443-1449.