

# Ocular hypertension and severe intraocular pressure elevation after posterior subtenon injection of triamcinolone acetonide for various diseases

Yun-Hsiang Yang<sup>1</sup>, Hua-Hsuan Kuo<sup>1</sup>, Wei-Cherng Hsu<sup>1,2</sup>, Yi-Ting Hsieh<sup>3</sup>

<sup>1</sup>Department of Ophthalmology, Taipei Tzu Chi Hospital, Buddhist Tzu Chi Medical Foundation, New Taipei 231, Taiwan, China

<sup>2</sup>School of Medicine, Tzu Chi University, Hualien 970, Taiwan, China

<sup>3</sup>Department of Ophthalmology, National Taiwan University Hospital, Taipei 10002, Taiwan, China

**Correspondence to:** Yi-Ting Hsieh. Department of Ophthalmology, National Taiwan University Hospital, 7 Zhongshan S. Rd., Zhongzheng Dist., Taipei 10002, Taiwan, China. [ythyth@gmail.com](mailto:ythyth@gmail.com)

Received: 2019-06-09 Accepted: 2019-08-18

## Abstract

• **AIM:** To evaluate and compare the incidences of ocular hypertension and severe intraocular pressure (IOP) elevation after posterior subtenon injection of triamcinolone acetonide (PSTA) for various diseases.

• **METHODS:** Totally 179 eyes that had received PSTA for diabetic macular edema ( $n=108$ ), pseudophakic cystoid macular edema ( $n=20$ ), branch retinal vein occlusion ( $n=16$ ), central retinal vein occlusion (CRVO,  $n=14$ ), choroidal neovascularization ( $n=14$ ) or noninfectious uveitis ( $n=7$ ) were retrospectively enrolled. The primary outcomes included ocular hypertension defined as an IOP $>21$  mm Hg, and severe IOP elevation defined as a rise of 10 mm Hg or more in IOP compared with baseline. Cox regression models were used to analyze the hazard ratios (HRs) among different diseases.

• **RESULTS:** After PSTA, the mean IOPs from month 1 to month 6 all significantly increased ( $P<0.05$ ). Ocular hypertension occurred in 30.7% of eyes (median time: 8wk), and severe IOP elevation occurred in 16.2% of eyes (median time: 9wk). Patients receiving PSTA for CRVO or uveitis had a significantly higher risk for ocular hypertension (HR=3.049,  $P=0.004$  for CRVO; HR=5.464,  $P=0.019$  for uveitis) and severe IOP elevation (HR=2.913,  $P=0.034$  for CRVO; HR=7.650,  $P=0.009$  for uveitis).

• **CONCLUSION:** IOP significantly increases within 6mo after PSTA, with the onset of ocular hypertension happening mostly at 2 to 3mo. Patients of CRVO or noninfectious

uveitis have a higher risk of ocular hypertension or severe IOP elevation after PSTA and should be monitored for IOP more carefully.

• **KEYWORDS:** intraocular pressure; ocular hypertension; uveitis; retinal vein occlusion; triamcinolone acetonide

**DOI:10.18240/ijo.2020.06.14**

**Citation:** Yang YH, Kuo HH, Hsu WC, Hsieh YT. Ocular hypertension and severe intraocular pressure elevation after posterior subtenon injection of triamcinolone acetonide for various diseases. *Int J Ophthalmol* 2020;13(6):946-951

## INTRODUCTION

Macular edema is a common complication in diabetic retinopathy, retinal vein occlusion (RVO), uveitis and choroidal neovascularization (CNV), and often is one of the main causes of visual disturbance in these diseases<sup>[1-4]</sup>. Although anti-vascular endothelial growth factor (VEGF) is the mainstream first-line therapy for diabetic macular edema (DME), RVO and CNV, steroids are still necessary for some cases<sup>[5-7]</sup>. In noninfectious uveitis, steroids are still one of the first-line therapies. Intravitreal injection of long-lasting dexamethasone or fluocinolone depot has been shown to be effective in treating DME, uveitis, and macular edema associated with RVO<sup>[8-12]</sup>. However, due to the high cost of steroid depot, triamcinolone acetonide is still used as an off-label alternative.

Posterior subtenon injection of triamcinolone acetonide (PSTA) has been shown to be effective for treating macular edema in DME, RVO, uveitis, CNV and pseudophakic cystoid macular edema (CME)<sup>[13-17]</sup>. One of the most important side effects of PSTA is secondary ocular hypertension. Previous studies have investigated the predisposing or protective factors for ocular hypertension after PSTA<sup>[18-24]</sup>. However, different diseases may have varying vulnerabilities to secondary ocular hypertension. In this study, we investigated and compared the incidences of secondary ocular hypertension and severe intraocular pressure (IOP) elevation after PSTA among patients with different diseases.

## SUBJECTS AND METHODS

**Ethical Approval** This research adhered to the tenets of the Declaration of Helsinki. Institutional Review Board (IRB) approval was obtained from the IRB of Taipei Tzu Chi Hospital, Buddhist Tzu Chi Medical Foundation. Informed consent was waived due to the retrospective nature of the study.

**Study Population** This study retrospectively collected data from patients who had received PSTA for DME, pseudophakic CME, branch retinal vein occlusion (BRVO), central retinal vein occlusion (CRVO), CNV or noninfectious uveitis in Taipei Tzu Chi Hospital, Buddhist Tzu Chi Medical Foundation, between January 2006 and December 2011. The exclusion criteria include: 1) an IOP>21 mm Hg at the time of PSTA or a history of glaucoma; 2) antiglaucoma medication use at the time of PSTA; 3) iris rubeosis; 4) simultaneous intravitreal or systemic steroid use during the follow-up period; 5) intravitreal silicone oil or scleral buckle; 6) follow-up time <3mo. The follow-up period ended in December 2012.

**Procedure for Posterior Subtenon Injection of Triamcinolone Acetonide** Nozik<sup>[25]</sup> has described the procedure for PSTA; we modified the procedure and have described it previously<sup>[20]</sup>. In brief, an injection of 40 mg/mL of triamcinolone acetonide was administered inferotemporally into the posterior subtenon space with a 27-gauge needle when the patient gazed superonasally.

**Outcome Events** In this study, we had two outcome events: ocular hypertension and severe IOP elevation. Ocular hypertension was defined as an IOP>21 mm Hg, and severe IOP elevation was defined as an increase of IOP by 10 mm Hg or more from baseline. One subject might achieve only one or both two outcome events, and the two events were analyzed separately. A noncontact tonometer (CT-80; Topcon Corporation, Tokyo, Japan) was used for IOP measurement. Before PSTA, the baseline IOP was measured. After PSTA, the IOPs were monitored at least every month during the first three months, and at least every three months thereafter. For eyes receiving more than one PSTA during the study period, each PSTA was treated as a new case for analysis, and a subsequent PSTA was treated as a censored event for the previous PSTA. Some eyes received more than one PSTA during the study period due to recurrent macular edema, so the course of each PSTA treatment was considered as a single record. Other possible endpoints included any intraocular surgery, loss to follow-up, a subsequent PSTA treatment, or end of study.

**Statistical Analysis** Paired *t*-tests were used to compare baseline and post-treatment IOPs. The Kaplan-Meier method was used to plot survival curves. Cox regression models were used to analyze the hazard ratios (HRs) among different diseases, and age, sex, and baseline IOP were adjusted as

**Table 1 Baseline characteristics for the 179 eyes**

Baseline characteristics	Mean (SD) or <i>n</i> (%)
Age (y)	65.4 (12.5)
Sex (female)	79 (44.1%)
IOP at baseline (mm Hg)	13.5 (3.3)
Diagnosis, <i>n</i> (%)	
DME	108 (60.3)
Pseudophakic CME	20 (11.2)
BRVO	16 (8.9)
CRVO	14 (7.8)
CNV	14 (7.8)
Noninfectious uveitis	7 (3.9)

BRVO: Branch retinal vein occlusion; CRVO: Central retinal vein occlusion; DME: Diabetic macular edema; IOP: Intraocular pressure; CME: Cystoid macular edema; CNV: Choroidal neovascularization.

covariates in the models. Stratified Cox proportional hazards models were used to analyze the associating factors for ocular hypertension and severe IOP elevation after PSTA in order to adjust for the correlations among multiple PSTAs in one eye. As for the correlation between the two eyes from the same patient, a robust sandwich variance-covariance estimation method was adopted for correction. A *P* value <0.05 was considered statistically significant. SAS 9.4 (SAS Institute Inc., Cary, NC, USA) software was used for all statistical analyses.

## RESULTS

A total of 179 eyes from 137 patients were recruited for this study. The mean age at the time of first PSTA was 65.4±12.5y (range 29-98y), and 44.1% were female. Among the 179 eyes, 108 had DME, 20 had pseudophakic CME, 16 had BRVO, 14 had CRVO, 14 had CNV, and 7 had noninfectious uveitis. Other baseline characteristics are shown in Table 1.

In eyes with DME, BRVO or CRVO, some of them have received other treatment modalities including panretinal photocoagulation (PRP), macular grid laser or anti-VEGF for macular edema and the underlying diseases as shown in Table 2.

### Ocular Hypertension & Severe IOP Elevation after PSTA

A total of 267 PSTAs were given to 179 eyes from 137 patients. For the 267 PSTAs, the mean follow-up time was 46.6±51.8wk (range 8-280wk), and the mean baseline IOP was 13.8±3.5 mm Hg (range 6-21 mm Hg). After PSTA, the mean IOP increased to 15.1±4.2 mm Hg at the first month, formed a plateau from the second to the fifth month (range 16.5-16.7 mm Hg), and then decreased gradually after the fifth month (15.8±4.8 mm Hg). The IOP values measured one to six months after PSTA were all significantly higher than the baseline value (all *P*<0.001; Figure 1). Ocular hypertension occurred in 30.7% of eyes (20.6% of injections) after PSTA. The mean event time for ocular hypertension after each PSTA

was 11.9±12.4wk (range 2 to 77wk, median 8wk). Severe IOP elevation occurred in 16.2% of eyes (10.9% of injections) after PSTA. The mean event time for severe IOP elevation after each PSTA was 14.4±11.1wk (range 2 to 46wk, median 9wk). Twenty-eight eyes (15.6%) received antiglaucoma medication for IOP control during the study period. The mean number of antiglaucoma agents was 1.71±0.77 (range: 1 to 4), and the mean duration for antiglaucoma medication use was 25.9±19.4wk (range: 5 to 82wk). Five eyes (2.8%) had persistent ocular hypertension even under medication use, and they then received operation for IOP control. Three of them (1.7%) received removal of subtenon triamcinolone acetonide particles, and two of them (1.1%) received trabeculectomy. The mean duration from PSTA to operation was 24.6±10.5wk (range: 14 to 36wk). All of these five eyes had their IOPs under control after the operation.

**Incidences in Various Diseases** Table 3 shows the percentages of ocular hypertension and severe IOP elevation and the mean and median event times for each disease. Figure 2 shows the Kaplan-Meier plots of ocular hypertension and severe IOP elevation for each disease. Eyes with uveitis had the highest proportions of ocular hypertension and severe IOP elevation (37.5% for both), and the event times of which were also the shortest (median time: 2 and 6wk, respectively). Eyes with pseudophakic CME had the lowest proportions of ocular hypertension (9.1%) and severe IOP elevation (4.6%).

Compared to eyes with DME, those with CRVO (HR=3.049, *P*=0.004), CNV (HR=2.081, *P*=0.024), or uveitis (HR=5.464, *P*=0.019) had a higher risk of ocular hypertension after PSTA after adjustment for age, sex and baseline IOP by Cox regression analysis. As for severe IOP elevation, Cox regression analysis revealed that eyes with CRVO (HR=2.913, *P*=0.034) or uveitis (HR=7.650, *P*=0.009) had a higher risk compared to those with DME (Table 4).

Forty-five eyes in this study had received multiple PSTA. Compared with their first PSTA, the HR for ocular hypertension was 0.971 (*P*=0.89) and the HR for severe IOP elevation was 0.992 (*P*=0.98) for their second or later injections. Neither was statistically significant.

**DISCUSSION**

There have been several studies investigating the issue of secondary ocular hypertension after PSTA<sup>[18-24,26-29]</sup>. However, most of previous studies were of small scale or had short follow-up periods. In this study, we looked at 267 injections from 179 eyes, with a mean follow-up time of 46.6wk. To our knowledge, this is the largest-scale study with the longest follow-up period to date. Furthermore, this is the first study to compare the different reactions in IOP to PSTA among various diseases; patients with all common indications for PSTA

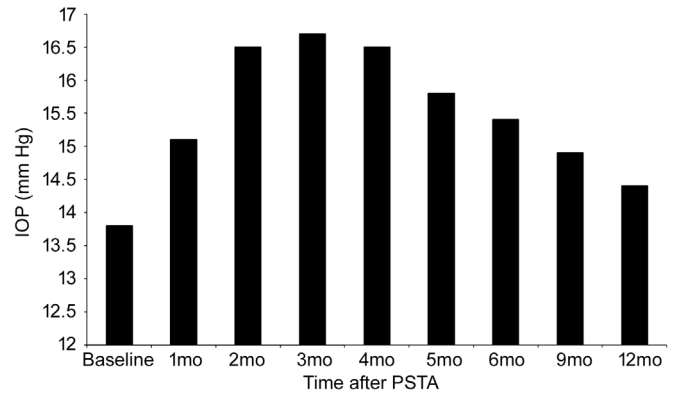


Figure 1 IOP distribution at baseline and after PSTA.

Table 2 Other treatment modalities for macular edema

Treatment	DME (108 eyes)	BRVO (16 eyes)	CRVO (14 eyes)
PRP before PSTA	53	3	2
PRP after PSTA	30	0	2
Macular grid before PSTA	45	7	0
Macular grid after PSTA	4	3	1
Anti-VEGF before PSTA	12	1	1
Anti-VEGF after-PSTA	22	4	5

BRVO: Branch retinal vein occlusion; CRVO: Central retinal vein occlusion; DME: Diabetic macular edema; PRP: Panretinal photocoagulation; VEGF: Vascular endothelial growth factor; PSTA: Posterior subtenon injection of triamcinolone acetonide.

including DME, RVO, CNV, pseudophakic CME, and uveitis were recruited in this study.

Previous studies have demonstrated that the proportion of patients who developed secondary ocular hypertension or IOP elevation after PSTA ranged from 11.4% to 46%<sup>[18-24,26-29]</sup>. The criteria for ocular hypertension or IOP elevation, however, varied among these studies. In this study, we used two parameters for analysis: ocular hypertension was defined as an IOP>21 mm Hg, and severe IOP elevation was defined as an increase of IOP by 10 mm Hg or more from baseline. Both criteria were clinically important for particular care. The present study showed that ocular hypertension and severe IOP elevation occurred in 30.7% and 16.2% of eyes, respectively, after PSTA during the follow-up period, and the median event times for ocular hypertension and severe IOP elevation after each PSTA were 8 and 9wk, respectively. The IOP values measured 1 to 6mo after PSTA were all significantly higher than the baseline value. This indicates that the onsets of secondary ocular hypertension or severe IOP elevation happened most frequently at 2 to 3mo after PSTA, and careful IOP monitoring during the first six months after PSTA injection was important.

Among all diseases, we found that eyes with noninfectious uveitis had the highest incidence (37.5%) of secondary ocular hypertension and severe IOP elevation after PSTA, with the

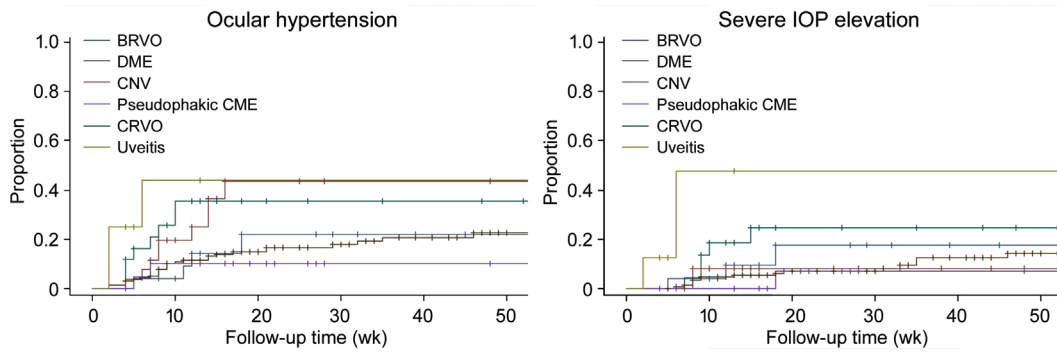


Figure 2 Kaplan-Meier plots for ocular hypertension and severe IOP elevation after PSTA in eyes with various diseases.

Table 3 The percentage, mean time, and median time of the events of ocular hypertension and severe IOP elevation after PSTA

Diagnosis	Ocular hypertension			Severe IOP elevation		
	Case, n (%)	Mean time±SD (wk)	Median time (wk)	Case, n (%)	Mean time±SD (wk)	Median time (wk)
DME	29 (18.0)	15.3±15.9	9	15 (9.3)	19.0±13.3	13
PCME	2 (9.1)	6.0±1.4	6	1 (4.6)	18.0±0	18
BRVO	4 (16.0)	11.5±5.3	11.5	3 (12.0)	11.7±6.5	12
CRVO	8 (32.0)	6.5±2.6	6	5 (20.0)	10.0±3.0	9
CNV	9 (34.6)	9.9±4.2	8	2 (7.7)	8.0±0	8
Uveitis	3 (37.5)	3.3±2.3	2	3 (37.5)	4.9±2.3	6

BRVO: Branch retinal vein occlusion; CRVO: Central retinal vein occlusion; CNV: Choroidal neovascularization; DME: Diabetic macular edema; PCME: Pseudophakic cystoid macular edema; PSTA: Posterior subtenon injection of triamcinolone acetate.

Table 4 Cox regression analysis for the events of ocular hypertension and severe IOP elevation after PSTA

Diagnosis	Ocular hypertension			Severe IOP elevation		
	Hazard ratio	95%CI	P	Hazard ratio	95%CI	P
DME	1 (reference)			1 (reference)		
PCME	1.020	0.209-4.982	0.98	0.625	0.078-4.991	0.66
BRVO	1.724	0.589-5.046	0.32	1.908	0.607-6.000	0.27
CRVO	3.049	1.433-6.486	0.004	2.913	1.084-7.827	0.034
CNV	2.081	1.103-3.927	0.024	0.951	0.199-4.549	0.95
Uveitis	5.464	1.330-22.444	0.019	7.650	1.659-35.282	0.009

BRVO: Branch retinal vein occlusion; CI: Confidence interval; CRVO: Central retinal vein occlusion; CNV: Choroidal neovascularization; DME: Diabetic macular edema; PCME: Pseudophakic cystoid macular edema; PSTA: Posterior subtenon injection of triamcinolone acetate; IOP: Intraocular pressure.

shortest onset time (2 to 6wk). Previous studies also showed the percentage of IOP elevation ranging from 21% to 44% after PSTA in cases of uveitis<sup>[26-27,29]</sup>. It is reasonable that cases of uveitis are more prone to IOP elevation, because inflammation in the anterior chamber will also result in structural and synechial damage to the trabecular meshwork. Although all eyes in the present study had not had a history of glaucoma prior to PSTA, their trabecular meshwork might have been partially damaged and therefore more sensitive to the IOP-elevating effects of steroids. Therefore, those receiving PSTA for uveitis must receive more intensive follow-up for IOP.

It has also been found that eyes with CRVO had a higher risk of secondary ocular hypertension and IOP elevation after PSTA compared with eyes with DME. As has been known,

eyes with CRVO may develop neovascular glaucoma during the natural course of the disease. In this study, cases with neovascular glaucoma were excluded at enrollment. However, it is possible that some patients with CRVO had subclinical angle rubeosis, and their anterior chamber angles might have been occluded partially; these patients may have had normal IOPs at baseline, but have been prone to IOP elevation after PSTA. As for BRVO, the incidence of secondary ocular hypertension was much lower than that of CRVO. It is likely related to the relatively low incidence of angle rubeosis BRVO when compared with CRVO.

The incidence and risk factors for ocular hypertension in DME have been thoroughly investigated<sup>[13,19-20]</sup>. Anti-VEGF might reduce the risk of ocular hypertension in cases of proliferative

diabetic retinopathy<sup>[20]</sup>. Nowadays PSTA is mostly used as a second-line or supplementary treatment for DME. Therefore, the risk for ocular hypertension is likely lower under the use of anti-VEGF<sup>[20]</sup>. In this study, we also found that patients with pseudophakic CME had the least incidence of ocular hypertension or severe IOP elevation. One previous study containing 17 cases of pseudophakic CME receiving PSTA also found that no one had ocular hypertension after PSTA<sup>[17]</sup>. Therefore, we think that PSTA is a rather safe treatment for pseudophakic CME under the consideration of steroid-induced ocular hypertension.

Although most cases of ocular hypertension could be controlled with medical treatment, some might still have their IOPs uncontrolled even under the treatment of full antiglaucomatic agents. Our previous case series study<sup>[30]</sup> showed that these cases mostly still had visible triamcinolone acetonide plaques in their subtenon spaces, and excision of subtenon triamcinolone acetonide plaques provided IOP normalization within 1-5d. In this study, only five eyes (2.8%) had persistent ocular hypertension even under medication use; three of them (1.7%) received removal of subtenon triamcinolone acetonide particles, and two of them (1.1%) received trabeculectomy. All of these five eyes had their IOPs under control after the operation. Therefore, we think that PSTA is a rather safe procedure. As long as careful monitoring of IOP can be performed after PSTA, only very rare cases would need filtering surgery.

The major limitation of this study is its retrospective design. There were no consistent treatment protocols for the study cases, such as the timing of treatment or the interval for repeated treatment. However, this reflects the real-world situation. We excluded cases with pre-existing glaucoma in order to decrease bias. In addition, although we had 173 eyes and 267 injections in this PSTA, most of them were cases with DME; cases with RVO, CNV or uveitis were relatively few. However, we still had statistically significant results even with such few cases. The advantage of this study is that the mean follow-up time for each injection in this study was 46.6wk, which was longer than the follow-up time in most previous studies; that allowed for late-onset ocular hypertension to be revealed.

In conclusion, we found that IOP elevated significantly from 1 to 6mo after PSTA for macular edema. Ocular hypertension and severe IOP elevation occurred mostly at 2 to 3mo after PSTA, although they could happen as soon as 2wk or as late as more than 1y later. Eyes with noninfectious uveitis or CRVO had higher risks of secondary glaucoma after PSTA. More intensive monitoring for IOP in these cases should be taken.

#### ACKNOWLEDGEMENTS

**Authors' contributions:** Design of study: Hsieh YT;

conduct of study: Yang YH, Kuo HH, Hsu WC, Hsieh YT; data collection: Yang YH, Kuo HH, Hsu WC; analysis and interpretation of data: Yang YH, Kuo HH, Hsieh YT; statistical analysis: Hsieh YT; writing the article: Yang YH; and critical revision of the article: Hsu WC, Hsieh YT.

**Conflicts of Interest:** Yang YH, None; Kuo HH, None; Hsu WC, None; Hsieh YT, None.

#### REFERENCES

- 1 Das A, McGuire PG, Rangasamy S. Diabetic macular edema: pathophysiology and novel therapeutic targets. *Ophthalmology* 2015;122(7):1375-1394.
- 2 Fardeau C, Champion E, Massamba N, LeHoang P. Uveitic macular edema. *Eye (Lond)* 2016;30(10):1277-1292.
- 3 Schmidt-Erfurth U, Waldstein SM, Deak GG, Kundi M, Simader C. Pigment epithelial detachment followed by retinal cystoid degeneration leads to vision loss in treatment of neovascular age-related macular degeneration. *Ophthalmology* 2015;122(4):822-832.
- 4 Yeh S, Kim SJ, Ho AC, Schoenberger SD, Bakri SJ, Ehlers JP, Thorne JE. Therapies for macular edema associated with central retinal vein occlusion: a report by the American Academy of Ophthalmology. *Ophthalmology* 2015;122(4):769-778.
- 5 Jeon S, Lee WK. Effect of intravitreal triamcinolone in diabetic macular edema unresponsive to intravitreal bevacizumab. *Retina* 2014;34(8):1606-1611.
- 6 Capuano V, Serra R, Oubraham H, Zambrowski O, Amana D, Zerbib J, Souied EH, Querques G. Dexamethasone intravitreal implant for choroidal neovascularization during pregnancy. *Retin Cases Brief Rep* 2019;13(4):300-307.
- 7 Alshahrani ST, Dolz-Marco R, Gallego-Pinazo R, Diaz-Llopis M, Arevalo JF; KKESH International Collaborative Retina Study Group. Intravitreal dexamethasone implant for the treatment of refractory macular edema in retinal vascular diseases: results of the KKESH International Collaborative Retina Study Group. *Retina* 2016;36(1):131-136.
- 8 Pearson PA, Comstock TL, Ip M, Callanan D, Morse LS, Ashton P, Levy B, Mann ES, Elliott D. Fluocinolone acetonide intravitreal implant for diabetic macular edema: a 3-year multicenter, randomized, controlled clinical trial. *Ophthalmology* 2011;118(8):1580-1587.
- 9 Boyer DS, Yoon YH, Belfort R Jr, Bandello F, Maturi RK, Augustin AJ, Li XY, Cui H, Hashad Y, Whitcup SM. Three-year, randomized, sham-controlled trial of dexamethasone intravitreal implant in patients with diabetic macular edema. *Ophthalmology* 2014;121(10):1904-1914.
- 10 Jain N, Stinnett SS, Jaffe GJ. Prospective study of a fluocinolone acetonide implant for chronic macular edema from central retinal vein occlusion: thirty-six-month results. *Ophthalmology* 2012;119(1):132-137.
- 11 Haller JA, Bandello F, Belfort R Jr, Blumenkranz MS, Gillies M, Heier J, Loewenstein A, Yoon YH, Jacques ML, Jiao J, Li XY, Whitcup SM, OZURDEX GENEVA Study Group. Randomized, sham-controlled trial of dexamethasone intravitreal implant in patients with macular

- edema due to retinal vein occlusion. *Ophthalmology* 2010;117(6):1134-1146.e3.
- 12 Arcinue CA, Cerón OM, Foster CS. A comparison between the fluocinolone acetonide (Retisert) and dexamethasone (Ozurdex) intravitreal implants in uveitis. *J Ocul Pharmacol Ther* 2013;29(5):501-507.
- 13 Cellini M, Pazzaglia A, Zamparini E, Leonetti P, Campos EC. Intravitreal vs. subtenon triamcinolone acetonide for the treatment of diabetic cystoid macular edema. *BMC Ophthalmol* 2008;8:5.
- 14 Helm CJ, Holland GN. The effects of posterior subtenon injection of triamcinolone acetonide in patients with intermediate uveitis. *Am J Ophthalmol* 1995;120(1):55-64.
- 15 Ozdek S, Deren YT, Gurelik G, Hasanreisoglu B. Posterior subtenon triamcinolone, intravitreal triamcinolone and grid laser photocoagulation for the treatment of macular edema in branch retinal vein occlusion. *Ophthalmic Res* 2008;40(1):26-31.
- 16 Ozkiris A. Intravitreal triamcinolone acetonide injection for the treatment of posterior uveitis. *Ocul Immunol Inflamm* 2006;14(4):233-238.
- 17 Tsai MJ, Yang CM, Hsieh YT. Posterior subtenon injection of triamcinolone acetonide for pseudophakic cystoid macular oedema. *Acta Ophthalmol* 2018;96(7):e891-e893.
- 18 Hirano Y, Ito T, Nozaki M, Yasukawa T, Sakurai E, Yoshida M, Ogura Y. Intraocular pressure elevation following triamcinolone acetonide administration as related to administration routes. *Jpn J Ophthalmol* 2009;53(5):519-522.
- 19 Hirooka K, Shiraga F, Tanaka S, Baba T, Mandai H. Risk factors for elevated intraocular pressure after trans-tenon retrobulbar injections of triamcinolone. *Jpn J Ophthalmol* 2006;50(3):235-238.
- 20 Hsieh YT, Yang CM, Chang SH. Bevacizumab and panretinal photocoagulation protect against ocular hypertension after posterior subtenon injection of triamcinolone acetonide for diabetic macular edema. *Taiwan Yi Zhi* 2017;116(8):599-605.
- 21 Inatani M, Iwao K, Kawaji T, Hirano Y, Ogura Y, Hirooka K, Shiraga F, Nakanishi Y, Yamamoto H, Negi A, Shimonagano Y, Sakamoto T, Shima C, Matsumura M, Tanihara H. Intraocular pressure elevation after injection of triamcinolone acetonide: a multicenter retrospective case-control study. *Am J Ophthalmol* 2008;145(4):676-681.
- 22 Iwao K, Inatani M, Kawaji T, Koga T, Mawatari Y, Tanihara H. Frequency and risk factors for intraocular pressure elevation after posterior sub-Tenon capsule triamcinolone acetonide injection. *J Glaucoma* 2007;16(2):251-256.
- 23 Kawamura R, Inoue M, Shinoda H, Shinoda K, Itoh Y, Ishida S, Tsubota K. Incidence of increased intraocular pressure after subtenon injection of triamcinolone acetonide. *J Ocul Pharmacol Ther* 2011;27(3):299-304.
- 24 Yamamoto Y, Komatsu T, Koura Y, Nishino K, Fukushima A, Ueno H. Intraocular pressure elevation after intravitreal or posterior sub-Tenon triamcinolone acetonide injection. *Can J Ophthalmol* 2008;43(1):42-47.
- 25 Nozik RA. Periocular injection of steroids. *Trans Am Acad Ophthalmol Otolaryngol* 1972;76(3):695-705.
- 26 Lafranco Dafflon M, Tran VT, Guex-Crosier Y, Herbort CP. Posterior sub-Tenon's steroid injections for the treatment of posterior ocular inflammation: indications, efficacy and side effects. *Graefes Arch Clin Exp Ophthalmol* 1999;237(4):289-295.
- 27 Bui Quoc E, Bodaghi B, Adam R, Burtin T, Cassoux N, Dreifuss S, Fardeau C, LeHoang P. Intraocular pressure elevation after subtenon injection of triamcinolone acetonide during uveitis. *J Fr Ophthalmol* 2002;25(10):1048-1056.
- 28 Levin DS, Han DP, Dev S, Wirostko WJ, Mieler WF, Connor TB, George V, Eastwood D. Subtenon's depot corticosteroid injections in patients with a history of corticosteroid-induced intraocular pressure elevation. *Am J Ophthalmol* 2002;133(2):196-202.
- 29 Jea SY, Byon IS, Oum BS. Triamcinolone-induced intraocular pressure elevation: intravitreal injection for macular edema and posterior subtenon injection for uveitis. *Korean J Ophthalmol* 2006;20(2):99-103.
- 30 Chan LW, Hsu WC, Hsieh YT. Subtenon triamcinolone acetonide removal for uncontrolled ocular hypertension after posterior subtenon injection of triamcinolone acetonide. *J Glaucoma* 2016;25(3):e268-e272.