

# One-year follow-up evaluation of combined phacovitrectomy for idiopathic epiretinal membrane

Feng Dong, Chen–Ying Yu, Ning Zhu, Ding–Hua Lou

Department of Ophthalmology, the First Affiliated Hospital of Zhejiang University, Hangzhou 310003, Zhejiang Province, China

**Correspondence to:** Ding-Hua Lou. Department of Ophthalmology, the First Affiliated Hospital of Zhejiang University, No.79 Qingchun Road, Hangzhou 310003, Zhejiang Province, China. 1186017@zju.edu.cn

Received: 2019-05-28 Accepted: 2020-03-02

## Abstract

• **AIM:** To evaluate the therapeutic effect of combined phacovitrectomy with membrane peeling and intraocular lens (IOL) implantation in patients with severe idiopathic epiretinal membrane (iERM) and concurrent cataract.

• **METHODS:** A total of 34 eyes from 34 patients who underwent phacovitrectomy and epiretinal membrane (ERM) peeling at the First Affiliated Hospital of Zhejiang University between 2015 and 2017. The best-corrected visual acuity (BCVA) and central foveal thickness (CFT) were measured preoperatively and at 1, 3, 6mo and 1y postoperatively. Temporal changes and bivariate correlations of these parameters were analyzed.

• **RESULTS:** Mean logMAR BCVA improved and CFT decreased significantly ( $P < 0.001$ ) until 6mo after surgery. Correlation analysis revealed a positive correlation between preoperative and postoperative logMAR BCVA ( $r = 0.716$ ,  $P < 0.001$  at 1mo,  $r = 0.417$ ,  $P = 0.014$  at 3mo,  $r = 0.359$ ,  $P = 0.037$  at 6mo, and  $r = 0.369$ ,  $P = 0.032$  at 12mo post-op respectively), but preoperative CFT was neither associated with postoperative CFT nor with postoperative logMAR BCVA. There was a positive correlation between CFT and logMAR BCVA at 1mo ( $r = 0.346$ ,  $P = 0.045$ ), 6mo ( $r = 0.347$ ,  $P = 0.045$ ), and 12mo ( $r = 0.342$ ,  $P = 0.048$ ) post-operatively. The intra- and postoperative complications were relatively mild, and the incidences were generally low.

• **CONCLUSION:** For severe iERM patients with significant visual symptoms, combined phacovitrectomy with membrane peeling and IOL implantation is safe and effective in improving BCVA and decreasing CFT. Early surgery in selected patients may help preserving better visual function.

• **KEYWORDS:** idiopathic epiretinal membrane; phacovitrectomy; visual acuity; central foveal thickness; optical coherence tomography

**DOI:** 10.18240/ijo.2020.06.15

**Citation:** Dong F, Yu CY, Zhu N, Lou DH. One-year follow-up evaluation of combined phacovitrectomy for idiopathic epiretinal membrane. *Int J Ophthalmol* 2020;13(6):952-959

## INTRODUCTION

An epiretinal membrane (ERM) is a transparent, avascular, fibrocellular membrane on the inner retinal surface that can cause decreased visual acuity and metamorphopsia. Idiopathic ERM (iERM) is the most common type of ERM, which is significantly associated with aging and posterior vitreous detachment (PVD). Epidemiologic studies reported that the prevalence of iERM increased in population older than 50y and ranged from 1.02% to 28.9% among different ethnic groups<sup>[1]</sup>. The standard procedure for symptomatic ERM is pars plana vitrectomy (PPV) plus ERM peeling, but the time point when surgery should be performed is still controversial. In the past, it was suggested that surgery could be delayed until metamorphopsia and loss of visual acuity were present. However, with the development of spectral domain optical coherence tomography (SD-OCT), iERM was found to be disrupting the integrity of photoreceptor that was associated with visual prognosis<sup>[2]</sup>, so it is now recommended to carry out the surgery at an early stage with minimal symptoms before permanent retinal tissue damage has occurred.

As mentioned above, iERM usually happens in elderly patients who are likely to have age-related cataract at the same time, and PPV may accelerate the progression of cataract. To avoid the need for subsequent cataract surgery, phacovitrectomy is an option in phakic eyes that could bring benefits, such as improving intraoperative fundus view and enabling rapid visual rehabilitation.

In this study, we retrospectively evaluated the anatomical and visual outcomes of combined phacovitrectomy with membrane peeling and intraocular lens (IOL) implantation in patients who had iERM and concurrent cataract, hoping that we could

**Table 1 Summary of the BCVA and CFT at follow-up visits**

Visit	Preop.	1mo postop.	3mo postop.	6mo postop.	12mo postop.
BCVA	0.84±0.34 <sup>a</sup>	0.52±0.20 <sup>a</sup>	0.45±0.19 <sup>a</sup>	0.43±0.20	0.43±0.20
CFT (μm)	542±103 <sup>a</sup>	445±90 <sup>a</sup>	407±88 <sup>a</sup>	386±86	383±84

BCVA: Best-corrected visual acuity; CFT: Central foveal thickness. <sup>a</sup>*P*<0.05 when compared with measurement from the next visit.

provide informative evidence for future clinical decision-making.

## SUBJECTS AND METHODS

**Ethical Approval** The study spanned over the period January 2015-June 2017 and was carried out at the Department of Ophthalmology, the First Affiliated Hospital of Zhejiang University. It was designed as a retrospective case series study. All the patients enrolled had signed the informed consent form before implementation of the trial, and the study was carried out in accordance with Declaration of Helsinki and approved by Ethics Committee of the hospital (No.2018-445).

The inclusion criteria were as follows: 1) Clinically diagnosed with iERM and concurrent age-related cataract; 2) Age ≥50y; 3) Central foveal thickness (CFT) >400 μm. Eyes with secondary ERM (due to uveitis, trauma, ocular surgery, or laser treatment) were excluded, and patients who had other ocular diseases, such as pathological myopia, age-related macular degeneration, glaucoma, diabetic retinopathy, and retinal vein occlusion, were not enrolled into the study.

All patients underwent combined 3-port 23G phacovitrectomy with membrane peeling and IOL implantation, of which the membrane indicated ERM and internal limiting membrane (ILM), and the surgery was performed by one experienced surgeon. The cataract extraction was performed through a microincision of about 2.2 mm with implantation of Akreos MI60 (BAUSCH&LOMB®, USA) for all patients. The ILM was identified with indocyanine green to facilitate complete peeling. The vitreous cavity of most eyes was filled with sterile balanced salt solution, or in select cases who were found to have peripheral retinal tear or degeneration or retinal injury during membrane peeling with C3F8 (5 eyes, 15%) and sterile air (4 eyes, 12%).

All patients were examined preoperatively and postoperatively at 1, 3, 6mo, and 1y after the surgery. At each visit, the best-corrected visual acuity (BCVA) was measured and converted to logMAR format, CFT was observed on the image produced by SD-OCT, and postoperative complication was recorded if there was any.

**Statistical Analysis** Statistical analysis was performed using SPSS software. Numeral values were expressed as mean±standard deviation (SD). Temporal changes of BCVA and CFT were evaluated using repeated measures ANOVA, while bivariate correlations among these parameters were

analyzed using the Pearson correlation coefficient. A *P* value<0.05 was considered statistically significant.

## RESULTS

A total of 34 eyes (20 right eyes and 14 left eyes) from 34 patients (14 men and 20 women) were included. The mean age was 64±6y (52-76y).

After combined phacovitrectomy and membrane peeling, mean logMAR BCVA improved significantly from 0.84 preoperatively to 0.52 at 1mo (*P*<0.001) and 0.45 at 3mo (*P*<0.001) postoperatively. Accordingly, mean CFT decreased significantly from 542 μm preoperatively to 445 μm at 1mo (*P*<0.001) and 407 μm at 3mo (*P*<0.001) after surgery. However, the improvement of both BCVA and CFT ground to a halt by 6mo postop., and the measurements at 12mo postop. showed no significant difference when compared with those at 6mo postop. (Table 1, Figure 1). At the final visit, 12 eyes (35%) reached logMAR BCVA≤0.3 (corresponding to ≥20/40 Snellen fraction), and 24 eyes (71%) gained three lines or more on the logMAR chart. Although 18 eyes (53%) reached CFT<400 μm finally, none of them could attain normal configuration or thickness of the central macula.

There was no correlation between preoperative CFT and postoperative CFT at any follow-up visit (*P*≥0.05), but there was a positive correlation between preoperative CFT and final CFT change (*r*=0.714, *P*<0.001). On the other hand, preoperative logMAR BCVA was positively correlated with postoperative logMAR BCVA (*r*=0.716, *P*<0.001 at 1mo, *r*=0.417, *P*=0.014 at 3mo, *r*=0.359, *P*=0.037 at 6mo, and *r*=0.369, *P*=0.032 at 12mo after surgery respectively) and final logMAR BCVA change (*r*=0.826, *P*<0.001). Furthermore, final CFT change was positively correlated with final logMAR BCVA change (*r*=0.367, *P*=0.033). After removing the cataract which might act as a confounding factor in the analysis, we found that there was a positive correlation between CFT and logMAR BCVA at 1mo (*r*=0.346, *P*=0.045), 6mo (*r*=0.347, *P*=0.045), and 12mo (*r*=0.342, *P*=0.048) postoperatively. However, the final logMAR BCVA (at 12mo postop.) was neither correlated with preoperative CFT (*r*=0.219, *P*=0.214) nor with final CFT change (*r*=-0.054, *P*=0.761; Figure 2).

Regarding the ocular symptom of metamorphopsia, all the patients complained about it before surgery, and the number of eyes that experienced aggravation was 5 in 1mo postop., 2 in 6mo postop. and 1 in 12mo postop., while there were 27, 12 and 9 eyes that experienced no changes, and there were

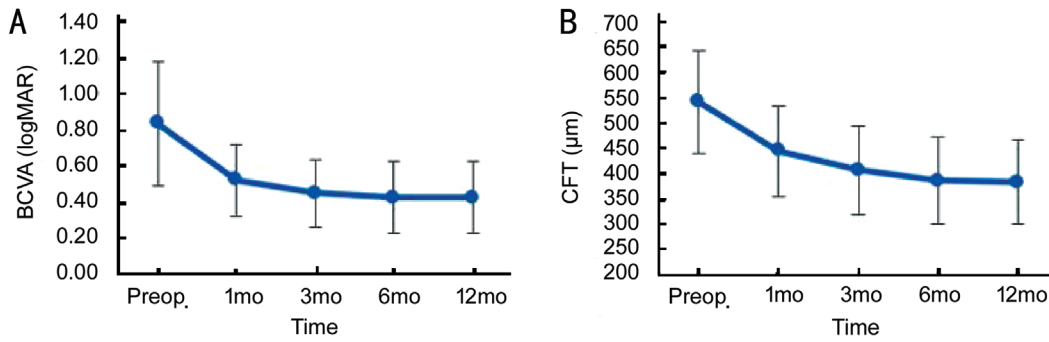


Figure 1 Improvement of the BCVA (A) and CFT (B).

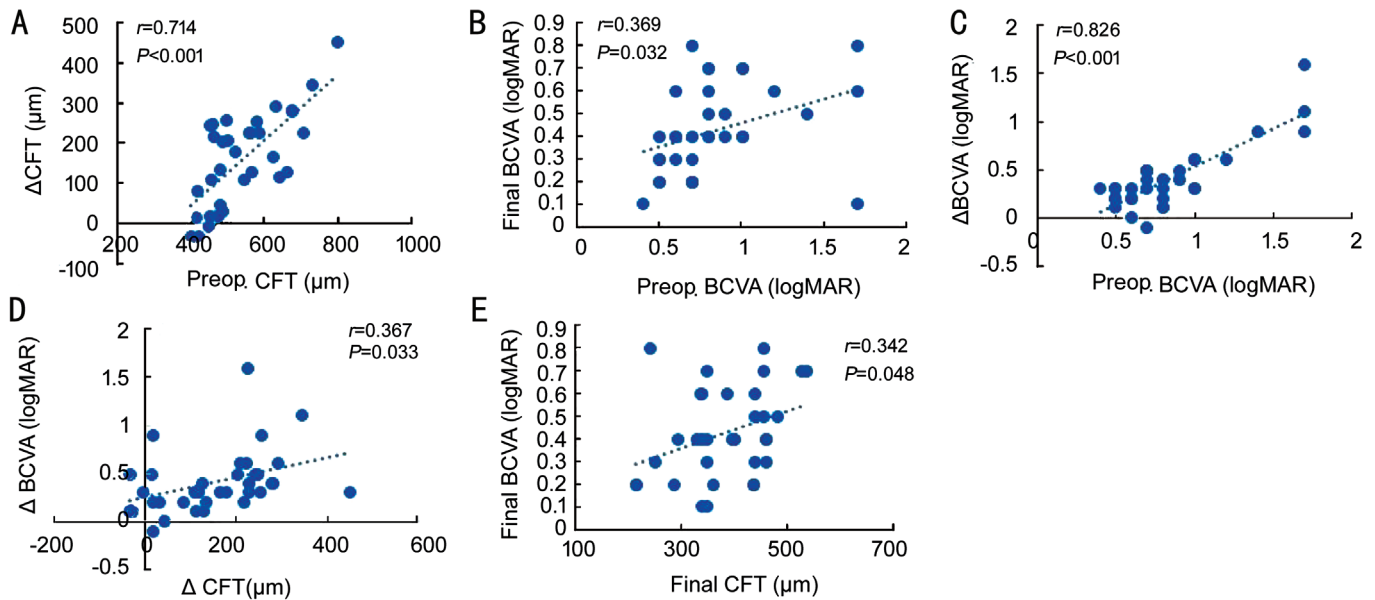


Figure 2 Correlation between preop. CFT and  $\Delta$ CFT (A), preop. BCVA and final BCVA (B), preop. BCVA and  $\Delta$ BCVA (C),  $\Delta$ CFT and  $\Delta$ BCVA (D), final CFT and final BCVA (E), all of which have shown statistical significance.

2, 20 and 24 eyes whose symptoms were improved at the corresponding postoperative time points respectively.

Besides CFT, we also evaluated the integrity of ellipsoid band as one of the anatomical outcome parameters. The preoperative number of eyes whose ellipsoid band were intact were 22, which increased to 27 eyes at 12mo postop. visit.

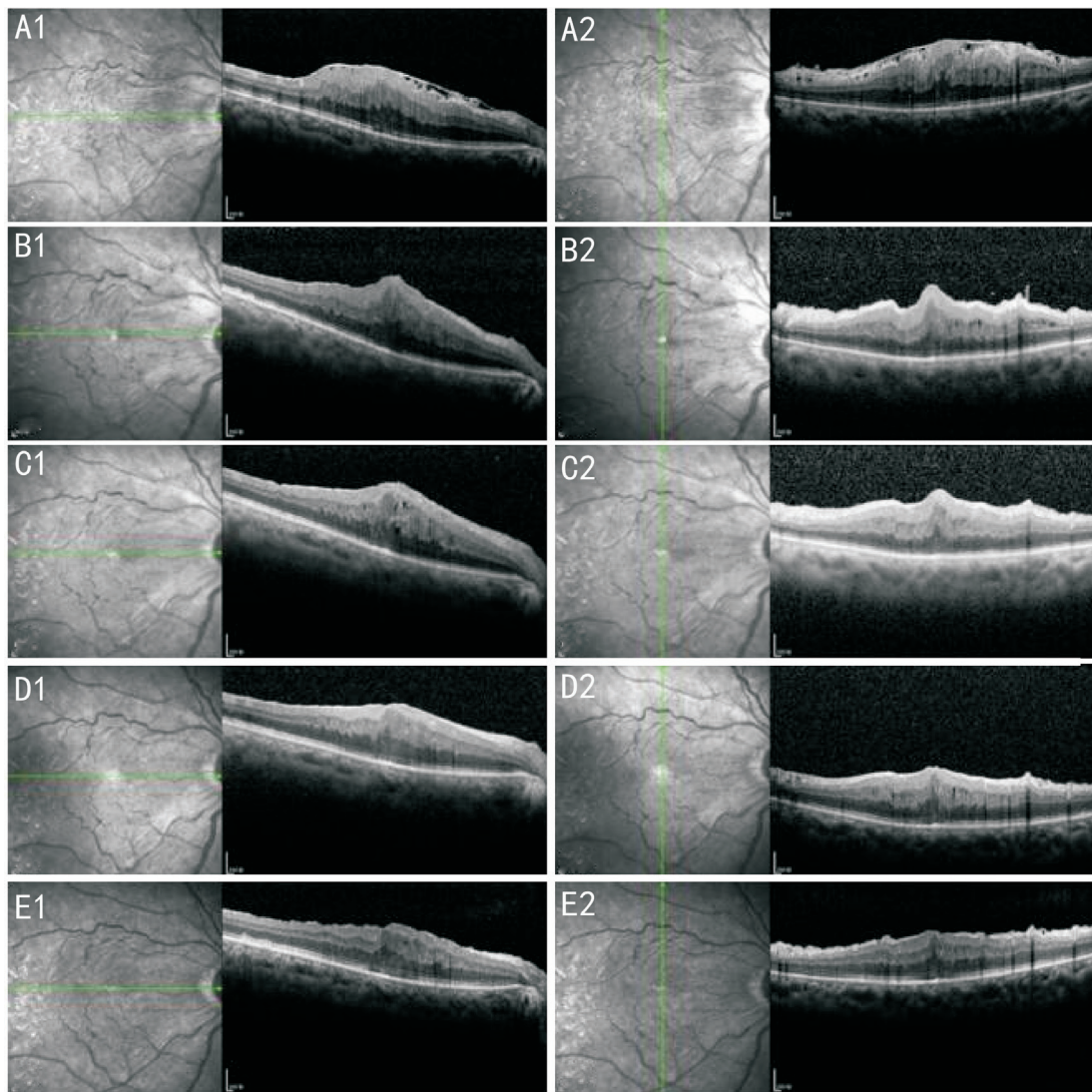
According to the classification scheme proposed by Govetto *et al*<sup>[3]</sup>, the eyes included in our study all had Stage 3 and Stage 4 ERMs initially. After membrane peeling, the 10 eyes that had preoperative Stage 4 ERMs improved to Stage 3 (8 eyes) and Stage 2 (1 eye) except for one eye that still remained at Stage 4. The 24 eyes that had preoperative Stage 4 ERMs mostly remained at Stage 3 (22 eyes), while only 2 eyes improved to Stage 2. In terms of postoperative BCVA, the 3 eyes that had resolved to Stage 2 obtained the best BCVAs (logMAR 0.2 for two eyes and logMAR 0.1 for one eye) among others.

In terms of intraoperative complication, 8 eyes (24%) experienced transient retinal dot hemorrhage during the surgery. Elevated intraocular pressure (IOP) and hypotony

were respectively observed in 3 eyes (9%) within three days postoperatively. Among these, one eye had hypotony (8 mm Hg), while the other two eyes had IOP elevation to 25 and 29 mm Hg respectively, which all returned to normal in one or two days without special treatment. At follow-up visits, cystoid macular edema (CME) was noticed in 4 eyes (12%), while ERM was found to recur in 1 eye (3%). Among the 4 eyes with postoperative CME in our study, 3 eyes had newly developed CME after operation, while one eye presented with preoperative CME that aggravated after operation, and we didn't offer any special treatment other than eyedrops and observation to the 4 patients. Until the last follow-up visit, CME had completely resolved in all 4 eyes except for one in which residual CME could be observed (Figures 3-5).

**DISCUSSION**

Aging and the development of incomplete PVD are the most important risk factors of iERM, and it has been widely acknowledged that an anomalous PVD plays a crucial role in the formation of iERM<sup>[4]</sup>. The age-related accumulation of advanced glycation end products in the cortical vitreous



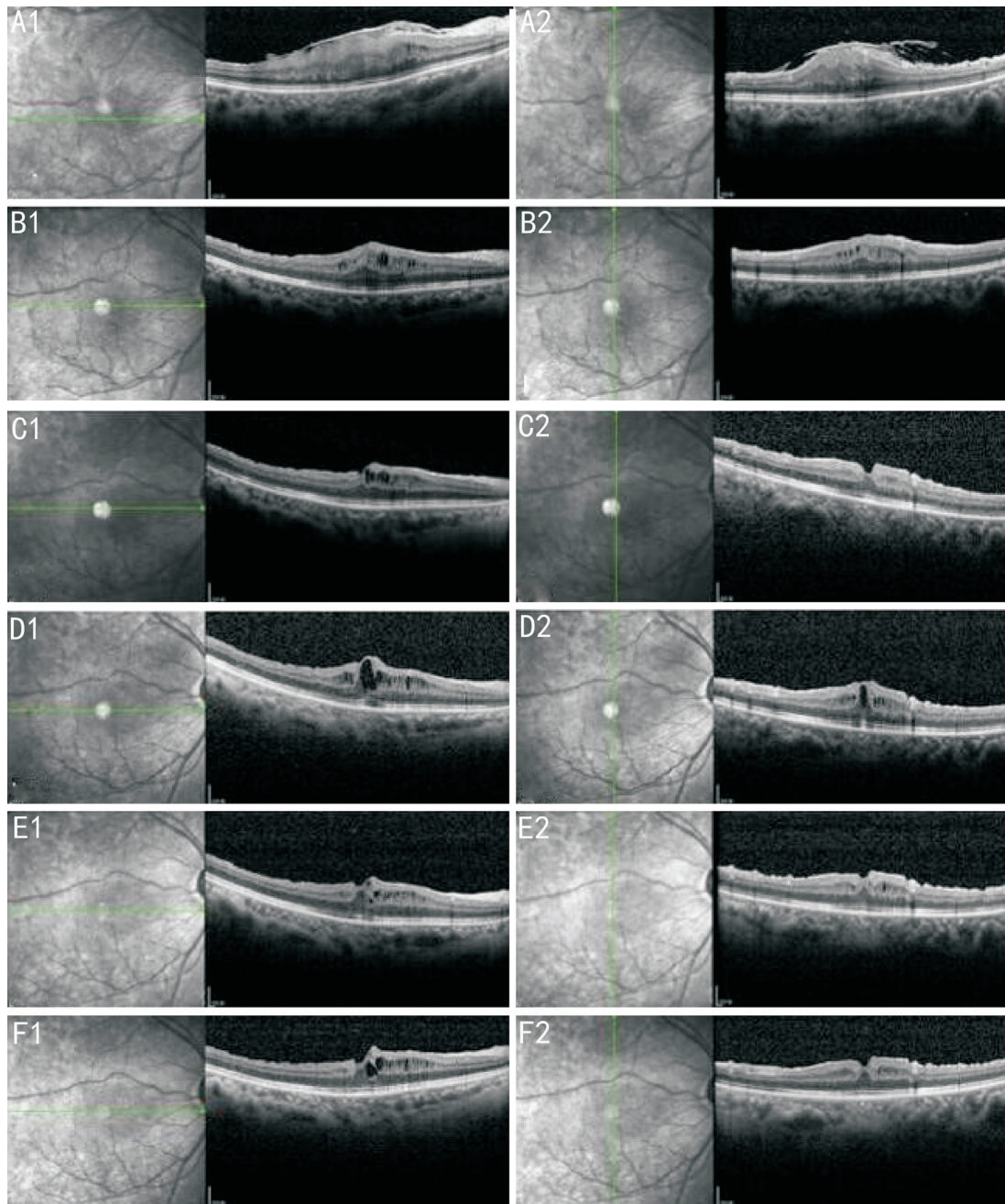
**Figure 3 Typical temporal changes of macula following membrane peeling surgery** A-E: The OCT images of macula at preop., 1, 3, 6, and 12mo postop. according to the temporal order.

fibrils could induce liquefaction of the vitreous body and increase rigidity of the vitreoretinal collagens<sup>[5]</sup>, thus creating vitreoschisis that allows hyalocytes to proliferate on posterior cortical vitreous remnants on the retinal surface<sup>[6]</sup>. Subsequently, these cells may differentiate into myofibroblasts and produce new collagens, finally promoting fibrotic process and causing visual disturbance<sup>[7]</sup>.

The clinical presentation of iERM can develop from completely asymptomatic to profoundly symptomatic with metamorphopsia, micropsia or macropsia, photopsia, decreased visual acuity, and loss of central vision, as the membrane thickens and contracts, distorting the retina beneath it. The classification of iERM used to be based on clinical examination findings, and it frequently included cellophane macular reflex as the early form and preretinal macular fibrosis as the late form<sup>[8]</sup>. However, with the advancement of SD-OCT technology, more elaborate classification schemes were proposed for the purpose of guiding the timing of surgical

intervention<sup>[9-11]</sup>. CFT indicates the distance between the inner surface of retina and the inner surface of retinal pigment epithelium (RPE) at the central fovea, and it is a measurable index that is closely associated with the progression of iERM. According to previous reports, CFT was considered normal if its value was below 320  $\mu\text{m}$  when measured with Heidelberg Spectralis OCT<sup>[12]</sup>. In daily clinical practice, we noted that iERM patients with CFT>400  $\mu\text{m}$  usually presented with significant visual symptoms, therefore we made it as one of the inclusion criteria, hoping to provide evidence for the treatment guidelines of iERM in the future.

PPV and ERM peeling have been used in iERM patients with visual symptoms as a standard procedure that has been repeatedly proved to be effective in reducing CFT and restoring vision<sup>[13-14]</sup>. Combining ERM peeling with cataract extraction is becoming increasingly popular, since most iERM patients experience rapid progression of cataracts after vitrectomy. Yiu *et al*<sup>[15]</sup> found that after combined phacovitrectomy, the

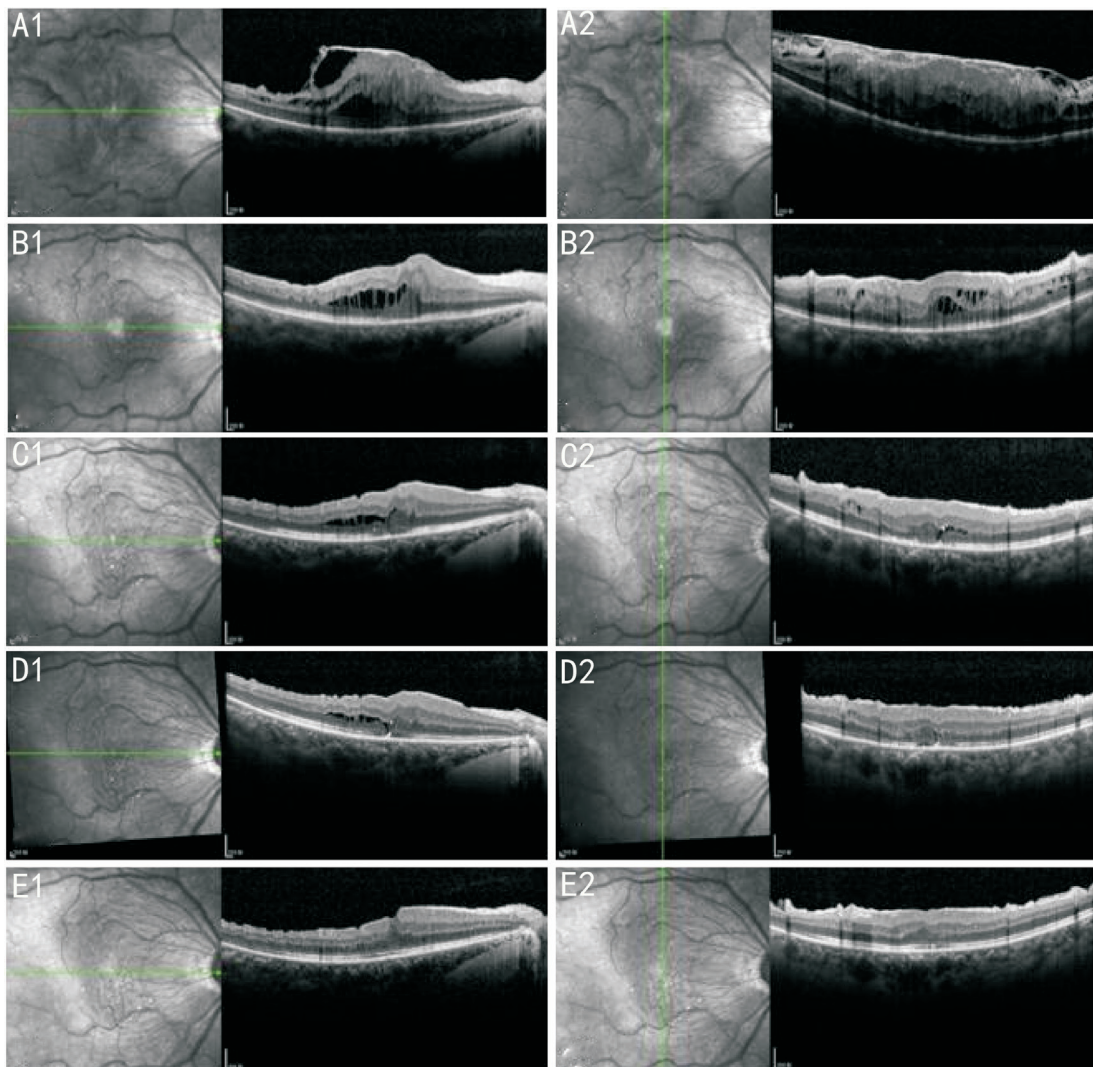


**Figure 4** Development of CME and its gradual remission following membrane peeling surgery A-F: The OCT images of macula at preop., 1, 3, 6, 12, and 24mo postop. according to the temporal order.

mean BCVA improved significantly from 0.67 logMAR preoperatively to 0.33 logMAR at 12mo postoperatively, while mean CFT improved significantly from 416  $\mu\text{m}$  to 336  $\mu\text{m}$  during the same period. Similarly, the surgical outcomes presented in our series were also excellent, with improvement of logMAR BCVA from 0.84 to 0.43 and CFT from 542  $\mu\text{m}$  to 383  $\mu\text{m}$ . Furthermore, repeated measures analysis revealed that BCVA and CFT became stable at about 6mo postoperatively, indicating a relatively slow but steady recovery process for patients undergoing phacovitrectomy.

Prediction of the visual outcome is essential for weighing the risks against the benefits of surgery, so we were intending to look for some predictive factors for postoperative visual

acuity when performing the correlation analysis, but only to find that patients with poorer preoperative BCVA tended to have poorer postoperative BCVA though the improvement of visual acuity might seem tremendous. In these patients, iERM might be present for a long period of time, causing a severe functional disturbance that was irreversible even after ERM peeling, and this result was consistent with previous reports<sup>[16]</sup>. However, preoperative CFT was not associated with postoperative BCVA, thus could not be used as a predictive factor. Concomitant cataract would exert a confounding effect on the assessment of preoperative BCVA, since iERM usually occurred in elderly patients. After eliminating the confounding factor by phacovitrectomy, we discovered a correlation that



**Figure 5** Aggravation of pre-existing CME immediately following membrane peeling surgery and its gradual remission afterwards A-E: The OCT images of macula at preop., 1, 3, 6, and 12mo postop. according to the temporal order.

was statistically significant between BCVA and CFT of each visit at 1, 6, and 12mo postop., indicating that besides CFT, there could be more subtle retinal changes that might be the real cause for visual acuity decrease, such as inner segment/outer segment (IS/OS) integrity<sup>[17-18]</sup>. In our study, we calculated the number of eyes with intact ellipsoid band preoperatively and postoperatively, and the results implied that membrane peeling surgery might enhance the recovery of ellipsoid band integrity. However, more cases were needed to warrant further correlation analysis between ellipsoid band integrity and visual outcomes.

Surgery used to be reserved for iERM patients with prominent visual symptoms, since ERM may remain stable for a period of time or even spontaneously detach from the inner retinal surface in rare cases. However, the progression of ERM may cause irreversible photoreceptor disruption and compromise postoperative visual acuity, because the process of retinal restoration leading to good vision is dependent on the rehabilitation of all retinal layers<sup>[19]</sup>. We adopted a new

classification scheme proposed by Govetto *et al*<sup>[3]</sup> when grading the severity of ERMs. The descriptive results showing the eyes that had ERM resolved to Stage 2 obtained better BCVAs might indicate that inner retinal edema could compromise postoperative BCVA. Besides, it seemed easier for eyes to improve or remain at Stage 3 after membrane peeling, but the improvement to Stage 2 was relatively difficult, suggesting that inner retinal edema was hard to resolve once it occurred, thus destroying the structure of all the retinal layers.

Given the marked improvement in surgical instrumentation and techniques, early phacovitrectomy for iERM has shown promising results with better visual outcome and quicker visual recovery in clinical studies<sup>[20]</sup>, and its complication rates such as CME, IOP elevation and ERM recurrence were equally low when compared with ERM peeling alone or 2-step sequential surgery<sup>[15,21]</sup>. As a result, for elderly patients with iERM who present with early symptoms like metamorphopsia or aniseikonia, phacovitrectomy can be considered as a treatment option.

Generally speaking, postoperative CFT gradually decreases after membrane peeling without significant CME (Figure 3). However, there are still a few patients who develop CME that usually resolves with fluctuation, and their CFTs may not be stable until two years postop. (Figure 4). In our study, we found new CME in 3 cases (9.1%), which was similar to the results of about 10% reported by Frisina *et al*<sup>[22]</sup>. Due to the small sample size, we only identified one patient with preoperative CME, whose condition aggravated immediately after membrane peeling and then slowly resolved, but his final BCVA was severely compromised (Figure 5). Likewise, previous studies had repeatedly indicated that preoperative intraretinal cysts were associated with reduced postoperative visual acuity, leading to smaller benefit from surgery<sup>[22-23]</sup>.

Numerous studies had evaluated the effects of ILM peeling combined with removal of iERM, and a recent Meta-analysis done by Azuma *et al*<sup>[24]</sup> concluded that additional ILM peeling in vitrectomy for iERM could result in a significantly lower ERM recurrence rate, but it does not significantly influence postoperative BCVA and CFT. The preoperative central fovea was relatively thick in our cases, and the ERM tightly adhered to ILM which was usually broken during ERM peeling. In order to prevent ERM recurrence, we peeled the ILM in all cases with indocyanine green staining to ensure complete separation of all fibrocellular tissues from the macula.

In conclusion, combined phacovitrectomy with membrane (ERM and ILM) peeling and IOL implantation was a safe and effective procedure in iERM patients, producing satisfying visual and anatomical outcomes with low rates of complication. Patients with better preoperative BCVA were prone to have better postoperative BCVA, and this correlation had implied the advantage of early surgery. But the relatively small sample size was the main limitation of our study, and more measuring indices should be introduced into the trial design to comprehensively evaluate the surgical outcome and its predictive factors.

#### ACKNOWLEDGEMENTS

**Conflicts of Interest:** Dong F, None; Yu CY, None; Zhu N, None; Lou DH, None.

#### REFERENCES

- 1 Bu SC, Kuijer R, Li XR, Hooymans JM, Los LI. Idiopathic epiretinal membrane. *Retina* 2014;34(12):2317-2335.
- 2 Kim HJ, Kang JW, Chung H, Kim HC. Correlation of foveal photoreceptor integrity with visual outcome in idiopathic epiretinal membrane. *Curr Eye Res* 2014;39(6):626-633.
- 3 Govetto A, Lalane RA 3rd, Sarraf D, Figueroa MS, Hubschman JP. Insights into epiretinal membranes: presence of ectopic inner foveal layers and a new optical coherence tomography staging scheme. *Am J Ophthalmol* 2017;175:99-113.

- 4 Sebag J. Anomalous posterior vitreous detachment: a unifying concept in vitreo-retinal disease. *Graefes Arch Clin Exp Ophthalmol* 2004;42(8):690-698.
- 5 Glenn JV, Stitt AW. The role of advanced glycation end products in retinal ageing and disease. *Biochim Biophys Acta* 2009;1790(10):1109-1116.
- 6 Gupta P, Yee KM, Garcia P, Rosen RB, Parikh J, Hageman GS, Sadun AA, Sebag J. Vitreoschisis in macular diseases. *Br J Ophthalmol* 2011;95(3):376-380.
- 7 Kohno RI, Hata Y, Kawahara S, Kita T, Arita R, Mochizuki Y, Aiello LP, Ishibashi T. Possible contribution of hyalocytes to idiopathic epiretinal membrane formation and its contraction. *Br J Ophthalmol* 2009;93(8):1020-1026.
- 8 Mitchell P, Smith W, Chey T, Wang JJ, Chang A. Prevalence and associations of epiretinal membranes. The blue mountains eye study, Australia. *Ophthalmology* 1997;104(6):1033-1040.
- 9 Hwang JU, Sohn J, Moon BG, Joe SG, Lee JY, Kim JG, Yoon YH. Assessment of macular function for idiopathic epiretinal membranes classified by spectral-domain optical coherence tomography. *Invest Ophthalmol Vis Sci* 2012;53(7):3562-3569.
- 10 Konidaris V, Androudi S, Alexandridis A, Dastiridou A, Brazitikos P. Optical coherence tomography-guided classification of epiretinal membranes. *Int Ophthalmol* 2015;35(4):495-501.
- 11 Stevenson W, Prospero Ponce CM, Agarwal DR, Gelman R, Christoforidis JB. Epiretinal membrane: optical coherence tomography-based diagnosis and classification. *Clin Ophthalmol* 2016;10:527-534.
- 12 Chalam KV, Bressler SB, Edwards AR, *et al*. Retinal thickness in people with diabetes and minimal or no diabetic retinopathy: Heidelberg spectralis optical coherence tomography. *Invest Ophthalmol Vis Sci* 2012;53(13):8154.
- 13 Pournaras CJ, Emarah A, Petropoulos IK. Idiopathic macular epiretinal membrane surgery and ILM peeling: anatomical and functional outcomes. *Semin Ophthalmol* 2011;26(2):42-46.
- 14 Dawson SR, Shunmugam M, Williamson TH. Visual acuity outcomes following surgery for idiopathic epiretinal membrane: an analysis of data from 2001 to 2011. *Eye (Lond)* 2014;28(2):219-224.
- 15 Yiu G, Marra KV, Wagley S, Krishnan S, Sandhu H, Kovacs K, Kuperwaser M, Arroyo JG. Surgical outcomes after epiretinal membrane peeling combined with cataract surgery. *Br J Ophthalmol* 2013;97(9):1197-1201.
- 16 Scheerlinck LM, van der Valk R, van Leeuwen R. Predictive factors for postoperative visual acuity in idiopathic epiretinal membrane: a systematic review. *Acta Ophthalmol* 2015;93(3):203-212.
- 17 Inoue M, Morita S, Watanabe Y, Kaneko T, Yamane S, Kobayashi S, Arakawa A, Kadonosono K. Preoperative inner segment/outer segment junction in spectral-domain optical coherence tomography as a prognostic factor in epiretinal membrane surgery. *Retina* 2011;31(7):1366-1372.

- 18 Cobos E, Arias L, Ruiz-Moreno J, Rubio M, Garcia-Bru P, Caminal J, Catala-Mora J, Arruga J. Preoperative study of the inner segment/outer segment junction of photoreceptors by spectral-domain optical coherence tomography as a prognostic factor in patients with epiretinal membranes. *Clin Ophthalmol* 2013;7:1467-1470.
- 19 Hartmann KI, Schuster AK, Bartsch DU, Kim JS, Chhablani J, Freeman WR. Restoration of retinal layers after epiretinal membrane peeling. *Retina* 2014;34(4):647-654.
- 20 Rahman R, Stephenson J. Early surgery for epiretinal membrane preserves more vision for patients. *Eye (Lond)* 2014;28(4):410-414.
- 21 Hamoudi H, Correll Christensen U, La Cour M. Epiretinal membrane surgery: an analysis of 2-step sequential- or combined phacovitrectomy surgery on refraction and macular anatomy in a prospective trial. *Acta Ophthalmol* 2018;96(3):243-250.
- 22 Frisina R, Pinackatt SJ, Sartore M, *et al.* Cystoid macular edema after pars plana vitrectomy for idiopathic epiretinal membrane. *Graefes Arch Clin Exp Ophthalmol* 2015;253(1):47-56.
- 23 Leisser C, Hirschschall N, Hackl C, Döllner B, Varsits R, Ullrich M, Kefer K, Karl R, Findl O. Risk factors for postoperative intraretinal cystoid changes after peeling of idiopathic epiretinal membranes among patients randomized for balanced salt solution and air-tamponade. *Acta Ophthalmol* 2018;96(4):e439-e444.
- 24 Azuma K, Ueta T, Eguchi S, Aihara M. Effects of internal limiting membrane peeling combined with removal of idiopathic epiretinal membrane: a systematic review of literature and Meta-analysis. *Retina* 2017;37(10):1813-1819.