

Managements of vertical gas breakthrough in femtosecond laser assisted LASIK

Cheng-Hua Wei, Li-Xin Mei, Yao Ge, Peng-Fei Zhang

Department of Ophthalmology, the First Affiliated Hospital of Wannan Medical College, Wuhu 241000, Anhui Province, China

Correspondence to: Li-Xin Mei, Department of Ophthalmology, the First Affiliated Hospital of Wannan Medical College, Wuhu 241000, Anhui Province, China. 2200936293@qq.com

Received: 2019-10-21 Accepted: 2020-02-12

DOI:10.18240/ijo.2020.09.25

Citation: Wei CH, Mei LX, Ge Y, Zhang PF. Managements of vertical gas breakthrough in femtosecond laser assisted LASIK. *Int J Ophthalmol* 2020;13(9):1503-1504

Dear Editor,

Femtosecond laser (FSL) assisted laser *in situ* keratomileusis (LASIK) has been popularized because of its greater accuracy and predictability. But FSL also have some unique complications especially some gas bubble related complications^[1]. Vertical gas breakthrough (VGB) is a rare and serious complication during flap creation. Some surgeons had reported that VGB was treated with microkeratome^[2] or photorefractive keratectomy^[3]. To our knowledge, FSL-LASIK has not been reported as a remedy fort VGB (from PubMed). We present a VGB case who was successfully salvaged using FSL-LASIK.

CASE PRESENTATION

A 19-year-old man without any medical or ocular histories required FSL-LASIK. The corneas were unremarkable on slitlamp examination. The manifest refracton (MR) was -6.00 DS+0.50 DC×90 in the right eye and -5.75 DS in the left eye. The corneal curvature was 43.00@89 and 41.75@179 in the right eye. The curvature of left eye was 42.75@153 and 42.00@63. The corrected distant vision acuity (CDVA) were 20/20 in both eyes. Preoperative ultrasound pachymetry was 552 μm in the right eye and 550 μm in the left eye. Keratoconus was excluded by the examination of Oculyzer.

The flap was created by FS-200 FSL. The presetting parameters of right eye were as follow: flap thickness, 95 μm; flap diameter, 8.5 mm; canal length offset, -0.1 mm; pulse energy in bed and side cut, 0.80 mJ. A gas bubble appeared between the cornea and the applanation cone at the beginning

of bed cutting (Figure 1). The operation was aborted temporary after the side cut completed. The left eye had the FSL-LASIK with the similar parameters. There was no adverse event in the left eye.

The reoperation of FSL-LASIK in the right eye was performed immediately after the left eye surgery finished (Figure 2). The presetting parameters during flap creating were as follow: flap thickness, 95 μm; flap diameter, 8.0 mm; canal length offset, 0.3 mm; pulse energy in bed and side cut, 0.80 mJ. The flap was created and lifted successfully. After excimer laser ablation, the flap repositioning required carefully alignment because of two side cuts.

The patients were prescribed levofloxacin eye drops (Santen Pharmaceutical Co., Ltd, Osaka, Japan) 4 times daily for 1wk and fluorometholone eye drops (Santen Pharmaceutical Co., Ltd, Osaka, Japan) 4 times daily tapered for 4wk. On the first postoperative day, the uncorrected distant vision acuity (UCVA) was 20/25 in the right eye and 20/20 in the left eye.

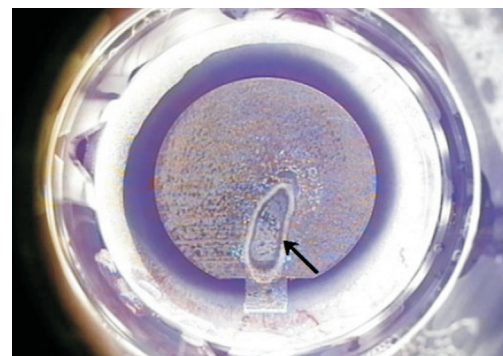


Figure 1 A long oval gas bubble in the superior part of corneal bed (black arrow).

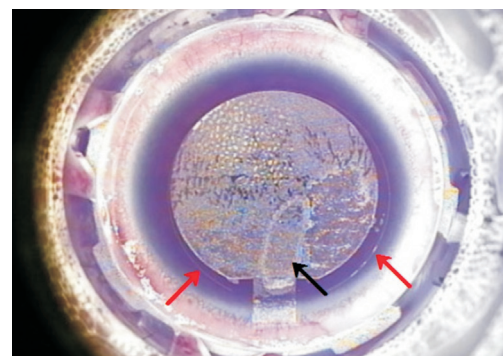


Figure 2 The margin of the first cut (red arrow) and button hole (black arrow).

The epithelium was edema in the inferior part of right cornea. The edema vanished on the third postoperative day and the UCVA was 20/20. The UCVA was 20/20 two months after surgery and the MR was +0.25 DC×47. There were no other adverse events.

DISCUSSION

Seider *et al*^[4] had reported 4 cases of VGB. Three of them were performed LASIK with difficulty, while 1 case's surgery was aborted because of flap tear. Chang and Lau^[2] has reported 3 VGB that were remedied by microkeratome assisted LASIK. He thought that VGB was associated with corneal abrasions. Ribeiro and Krueger^[3] had reported 1 case of binocular VGB who was treated with mitomycin-C assisted photorefractive keratectomy. To our knowledge, FSL-LASIK has not been reported as a remedy of VGB so far.

Because the patient wanted to recover eye sight to pass physical examination, we performed FSL-LASIK as a remedy immediately after the original operation. However, because of the two side cuts, it was more troublesome to align and reposition the flap.

Ribeiro and Krueger^[3] has reported a case of bilateral VGB with anterior basement membrane dystrophy. But the case we reported has no corneal lesions. Before the first operation, they were supposed to have an intact anterior elastic layer. Some scholar also experienced VGB when they perform femtosecond assisted cataract surgery on a clear cornea patient. Moreover, the anterior elastic layers of the case should have been damaged after they underwent VGB, but VGB did not happen again during reoperation. Therefore, we think that the damage of the anterior elastic layer may not be the necessary cause of VGB. Some scholars believed that VGB was related to thin corneal flap^[5]. To remain more corneal stroma, we created thin corneal flaps. It may be the cause of VGB due to

the gas bubble could not diffuse through the canal, but through the thin corneal flap to the applanation cone.

In summary, FSL-LASIK was performed successfully as a remedy in the VGB case. No adverse event occurred in the second flap creation. The predicted values of UCVA, CDVA and refraction were all achieved postoperatively. FSL-LASIK could be a remedy of VGB in the patient without obvious corneal lesion. More studies about the cause and management of VGB are needed.

ACKNOWLEDGEMENTS

Foundations: Supported by the National Natural Science Fund of China (No.81700867); the Wannan Medical College Training Fund Project of Key Scientific Research Project (No. WK2017ZF05).

Conflicts of Interest: Wei CH, None; Mei LX, None; Ge Y, None; Zhang PF, None.

REFERENCES

- 1 Wei CH, Dai QY, Mei LX, Ge Y, Zhang PF, Song E. Paired eye-control study of unilateral opaque bubble layer in femtosecond laser assisted laser *in situ* keratomileusis. *Int J Ophthalmol* 2019;12(4):654-659.
- 2 Chang JS, Lau S. Intraoperative flap re-cut after vertical gas breakthrough during femtosecond laser keratectomy. *J Cataract Refract Surg* 2010;36(1):173-177.
- 3 Ribeiro GC, Krueger RR. Management of bilateral gas-bubble breakthrough during femtosecond LASIK in the presence of anterior basement membrane dystrophy. *J Cataract Refract Surg* 2014;40(10):1736-1739.
- 4 Seider MI, Ide T, Kymionis GD, Culbertson WW, O'Brien TP, Yoo SH. Epithelial breakthrough during IntraLase flap creation for laser *in situ* keratomileusis. *J Cataract Refract Surg* 2008;34(5):859-863.
- 5 Srinivasan S, Herzig S. Sub-epithelial gas breakthrough during femtosecond laser flap creation for LASIK. *Br J Ophthalmol* 2007;91(10):1373.