

Fourier-domain optical coherence tomography-guided phototherapeutic keratectomy for the treatment of anterior corneal scarring

Yu-Li Yang¹, Qian Jian², Bo Liu¹, Ke Wang¹, Yu-Juan Chen¹, Lian Tan¹, Mei-Jun Pu¹, Yong Liu¹

¹Southwest Hospital/Southwest Eye Hospital, Third Military Medical University (Army Medical University), Chongqing 400038, China

²Chongqing Aier Mega Eye Hospital, Aier Eye Hospital Group, Chongqing 400060, China

Co-first authors: Yu-Li Yang and Qian Jian

Correspondence to: Yong Liu. Southwest Hospital/Southwest Eye Hospital, Third Military Medical University (Army Medical University), Chongqing 400038, China. liuyy99@163.com

Received: 2019-08-05 Accepted: 2019-10-25

Abstract

• **AIM:** To evaluate the safety, visual and anatomic outcomes of fourier-domain optical coherence tomography (FD-OCT)-guided excimer laser phototherapeutic keratectomy (PTK) combined with photorefractive keratectomy (PRK) surgery in treating anterior corneal scarring.

• **METHODS:** Clinical data of 23 eyes of 21 patients with anterior corneal scarring underwent FD-OCT-guided PTK and PRK from Dec. 2014 to Jul. 2016 were reviewed. Patients were assessed for preoperative and postoperative uncorrected visual acuity (UCVA), best spectacle-corrected visual acuity (BSCVA), contrast sensitivity (CS), FD-OCT, corneal topography and colour figures of anterior segments.

• **RESULTS:** The preoperative corneal pathologic conditions included viral keratitis (7 patients, 7 eyes), band keratopathy (2 patients, 4 eyes), corneal dystrophy (4 patients, 4 eyes), traumatic corneal disease (2 patients, 2 eyes) and corneal chemical injury (6 patients, 6 eyes). Mean follow-up time was 10.65 (range, 3-19)mo. UCVA (in logMAR) improved from a mean of 0.79 (95%CI, 0.28-1.29) preoperatively to a mean of 0.45 (95%CI, 0.29-0.62) postoperatively ($P=0.021$). BSCVA (in logMAR) improved from 0.57 (95%CI, 0.27-0.88) preoperatively to a mean of 0.28 (95%CI, 0.15-0.41) postoperatively ($P=0.001$). Corneal topographic indices postoperatively showed significant improvement in corneal cylinder ($P=0.009$), the surface regularity index ($P=0.007$) and surface asymmetry index

($P=0.00$). Postoperative spherical equivalent averaged -0.53 diopters (-1.49 to 0.42). No complications were associated with the treatment.

• **CONCLUSION:** FD-OCT-guided PTK combined with PRK is safe and effective for the treatment of anterior corneal scarring by eliminating or reducing corneal opacities.

• **KEYWORDS:** corneal scar; phototherapeutic keratectomy; fourier-domain optical coherence tomography; corneal opacity; corneal topographic indices

DOI:10.18240/ijo.2020.11.06

Citation: Yang YL, Jian Q, Liu B, Wang K, Chen YJ, Tan L, Pu MJ, Liu Y. Fourier-domain optical coherence tomography-guided phototherapeutic keratectomy for the treatment of anterior corneal scarring. *Int J Ophthalmol* 2020;13(11):1720-1726

INTRODUCTION

In the past, superficial corneal opacities were commonly treated with superficial ablation or lamellar corneal transplantation^[1-2]. Given the greater risks and costs associated with these conventional therapies, phototherapeutic keratectomy (PTK) may provide a safer, cost effective and more efficacious modality in patients with anterior corneal lesions^[3]. Besides, PTK could smooth irregular corneal surfaces caused by corneal disease to improve vision^[4-5]. However, some difficulties with PTK are postoperative hyperopic shift and preoperative prediction of the depth of opacities to determine the optimal ablation depth, as well as determination of the refractive errors caused by the procedure. Fortunately, dramatic advances in optical coherence tomography (OCT) technology have been made recently, enabling the acquisition of higher resolution imaging of the corneal structure. Now, the application of fourier-domain optical coherence tomography (FD-OCT) with 1310-nm wavelength can accurately evaluate the depth of the corneal lesion, and postoperative hyperopic errors can also be neutralized by simultaneous photorefractive keratectomy (PRK) surgery^[6-7]. Refer to relevant literatures, no precise correspondence on the amount of corneal tissue removed and the hyperopic shift were recognized. Therefore, the key point of this retrospective clinical study was to clarify

the correspondence between the corneal tissue removed by PTK and hyperopic shift degrees.

SUBJECTS AND METHODS

Ethical Approval The Army University Institutional Review Boards approved this single-center trial. All research components adhered to the tenets of the Declaration of Helsinki and were conducted in accordance with human-subject research regulations and standards. All subjects were at least 18 year old, and all provided written informed consent.

Study Population This study involved 21 patients 23 eyes underwent FD-OCT-guided PTK combined with PRK (11 males and 10 females) between December 2014 and July 2016 at Southwest Eye Hospital, Chongqing, China. The inclusion criteria were patients suffering from visual compromise due to anterior corneal opacities within one-third depth of the corneal thickness. The exclusion criteria were severe dry eye, active keratoconjunctivitis, active uveitis, glaucoma, and systemic autoimmune diseases. The mean age of the patients was 35.4±6.5y (range, 18-65y). Mean follow-up time was 10.65mo (range, 3-19mo). The preoperative corneal pathologic conditions included viral keratitis (7 patients 7 eyes), band keratopathy (2 patients 4 eyes), corneal dystrophy (4 patients 4 eyes), traumatic corneal disease (2 patients 2 eyes) and corneal chemical burn (6 patients 6 eyes; Table 1).

Preoperative Examinations All patients were given a complete preoperative ophthalmologic examination, including slit-lamp microscope, intraocular pressure, FD-OCT (Optovue RTVue-100 Fourier-Domain optical coherence tomography system, OPTOVUE Co., USA), corneal topography (Allergo Topolyzer, Wavelight Co., USA), color photos of anterior segments, the preoperative and postoperative logMAR values of uncorrected visual acuity (UCVA) and best spectacle-corrected visual acuity (BSCVA), preoperative and postoperative contrast sensitivity (CS; fact optec 6500, Stereo Optical Co., Inc., Chicago, Illinois, USA) was measured with the BSCVA at spatial frequencies of 1.5, 3, 6, 12 and 18 cycles per degree in photopic conditions.

In order to facilitate statistical analysis, we converted all the tested CS values to log base 10 values. All patients were scanned with FD-OCT at the central 6 mm of the cornea before surgeries. Totally 8 radial lines centered the apex of the cornea were measured and the following parameters were obtained: 1) maximum depth of the pathology; 2) the corneal thickness corresponding to the maximum depth of the opacity; 3) the epithelial thickness corresponding to the maximum depth of the opacity.

PTK Combined with PRK Treatment Protocols According to the particular corneal conditions, the surgical technique varies greatly among different surgeons. So, all the photoablations were performed by a single surgeon using

Table 1 Preoperative characteristics of patients with corneal opacities who underwent photoablation

Parameters	Epidemiological data
No. of patients and eyes	21 patients, 23 eyes
Gender	
Male	11 patients, 12 eyes
Female	10 patients, 11 eyes
Age (y)	35.4±6.5 (range, 9-65)
Corneal pathology	
Viral keratitis	7 patients, 7 eyes
Corneal dystrophy	4 patients, 4 eyes
Band keratopathy	2 patients, 4 eyes
Traumatic corneal disease	2 patients, 2 eyes
Corneal chemical burn	6 patients, 6 eyes
Follow-up time (mo)	10.65±5.10 (range, 3-19)

the Allegretto Wavelight Eye-Q 400 Hz platform (Alcon, Fort Worth, Texas, USA). The treatment profiles included three steps: First, corneal epithelium was removed manually or mechanically with a large optic zone (usually 8 mm); Second, the preoperative FD-OCT-measured-depth-of-treatment was ablated by PTK with an optic zone of 7 mm; Last, after accounting for the patient's preoperative spherical equivalent (SE) and the hyperopic refractive errors caused by PTK ablation, PRK with an optic zone of 6.5 mm was performed to achieve the desired refractive results (an SE near plano). It must be noticed that, the corneal epithelial thickness (which contribute little to refractive outcomes) should not be contained within the total ablation depth. In addition, because of the corneal surface irregularity, blocking liquid (carboxymethylcellulose solution 0.5%; Allergan Inc., California, USA) should be used to fill the crater during the treatment. In order to avoid the generation of haze, an 8.0 mm diameter circular cotton pad soaked with mitomycin C 0.002% was applied to the corneal surface and removed after 20s after all the photoablation was completed. Following that, the eyes were irrigated with 20 mL balanced salt solution (BSS) and a bandage contact lens were used until complete re-epithelialization. The postoperative follow-up time was 1, 7d, 1, 3, 6 and 12mo.

Statistical Analysis Statistical analysis was accomplished with IBM SPSS statistics (ver.19, USA). One-way analysis of variance was used to compare the preoperative to the postoperative values of UCVA (logMAR), BSCVA (logMAR), topographic cylinder in diopters, topographic surface asymmetry index (SAI), topographic surface regularity index (SRI). Nonparametric tests (Friedman test and Dunn test for multiple comparisons) were applied to compare CS values at different spatial frequencies. The results are presented as median, mean±SD. Probabilities of less than 5% were considered statistically significant.

Table 2 Visual outcomes and refractive changes in keratometric indices, spherical equivalent, astigmatism

Parameters	Preoperative values (mean, 95%CI)	Postoperative values (mean, 95%CI)	P
UCVA (logMAR)	0.79 (0.28-1.29)	0.45 (0.29-0.62)	0.021
BSCVA (logMAR)	0.57 (0.27-0.88)	0.28 (0.15-0.41)	0.001
Keratometric astigmatism (D)	2.35 (0.70-3.99)	1.32 (0.13-2.51)	0.009
SAI	1.57 (1.05-2.07)	0.98 (0.46-1.51)	0.000
SRI	3.08 (1.48-4.67)	1.74 (0.52-2.97)	0.007
Ks (D)	46.58 (43.03-50.12)	47.72 (44.52-50.92)	0.257
AveK (D)	45.33 (42.05-48.61)	46.42 (43.28-49.56)	0.258
SE (D)		-0.53 (-1.49-0.42)	

UCVA: Uncorrected visual acuity; BSCVA: Best spectacle-corrected visual acuity; SAI: Surface asymmetry index ; SRI: Surface regularity index; Ks: Topographic K-reading values; AveK: Topographic average K-reading values; SE: Spherical equivalent.

RESULTS

Totally 23 eyes of 21 patients (11 males, 10 females) were treated. The mean age of the patients was 35.4±6.5y (range, 18-65y), of that 52% were male and 48% were female. Mean follow-up time was 10.65mo (range, 3-19mo). The indexes related to visual quality and the corneal surface regularity were measured. All patients improved corneal clarity after the photoablation. UCVA (in logMAR) improved from 0.79 (95%CI, 0.28-1.29) to 0.45 (95%CI, 0.29-0.62; P=0.021). BSCVA (in logMAR) improved from 0.57 (95%CI, 0.27-0.88) preoperatively to 0.28 (95%CI, 0.15-0.41) postoperatively (P=0.001). Nearly all the patients gained improvement of at least 2 logMAR line of UCVA and BSCVA. Only one patient developed haze half a month after surgery and recovered totally after prompt medical treatment. The corneal topography-measured cylinder and morphologic indices significantly improved. Topographic cylinder decreased from 2.35 diopters (D) (95%CI, 0.70-3.99) to 1.32 D (95%CI, 0.13-2.51; P=0.009). Topographic SAI improved from 1.57 (95%CI, 1.05-2.07) to 0.98 (95%CI, 0.46-1.51; P=0.000). Topographic SRI improved from 3.08 (95%CI, 1.48-4.67) to 1.74 (95%CI, 0.52-2.97; P=0.007). Topographic K-reading values of steep axis increased from 46.58 D (95%CI, 43.03-50.12) to 47.72 D (95%CI, 44.52-50.92; P=0.257). Topographic average K-reading values increased from 45.33 D (95%CI, 42.05-48.61) to 46.42 D (95%CI, 43.28-49.56; P=0.258). The mean postoperative SE was -0.53 (95%CI, -1.49-0.42) diopters from the desired refractive error (Table 2; Figure 1).

Case Example #1: Lattice Corneal Dystrophy A 23-year-old male presented with gradually decreasing visual acuity for nearly 10y. Photophobia and eye pain often recurred. His UCVA was counting fingers (CF) Snellen OD. His BSCVA was 20/200 Snellen OD. The patient’s preoperative FD-OCT demonstrated corneal scarring of right eye. We measured 8 radial lines through the center of the apex of the cornea. The maximum opacity depth was 149 µm, the maximum crater

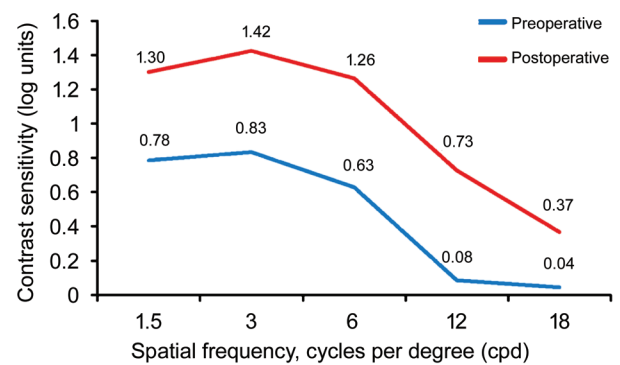


Figure 1 Comparison of pre-/postoperative CS value in photopic conditions Graph demonstrating the CS in median values (log units) at spatial frequencies of 1.5, 3.0, 6.0, 12.0, and 18.0 cpd after treatment in photopic conditions during the entire follow-up period.

depth was 131 µm and a baseline epithelial thickness was 50 µm (Figure 2A). To remove the scarring as completely as possible and get to the bottom of the corneal crater as deeply as possible, the initial PTK ablation profile was set at the depth of 150 µm with an optic zone of 7 mm. As the removal of corneal epithelium did not contribute to the refractive outcome, only 100 µm of corneal tissue would lead to postoperative hyperopic shift. PTK ablation may induce 1.0 D of hyperopia per 20 µm according to previous literature^[8], photoablation of 100 µm corneal tissue may induce 4.0 D of hyperopia in the patient. The preoperative SE of the patient was -2.25 DS. Therefore, the second ablation profile was set at hyperopic correction of 1.75 D with an optic zone of 6.5 mm. After the dual laser photoablation, the residual central corneal depth was measured at 460 µm after the 100 µm ablation (565 µm preoperative; 100 µm PTK ablation; anticipated residual corneal depth was 465 µm), and the change in the stromal thickness was as expected for this laser setting (Figure 2A).

As to the corneal surface irregularity, we measured the topographic indices including topographic cylinder, topographic SAI, and topographic SRI. Compared to preoperative

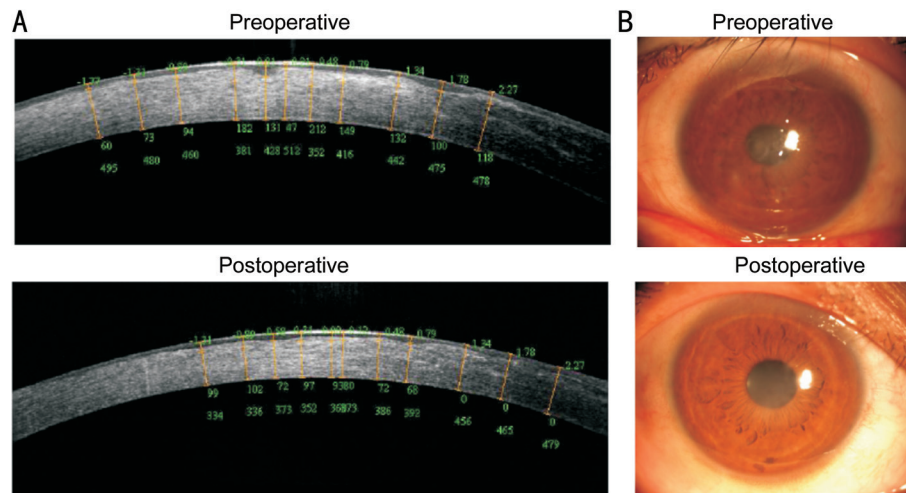


Figure 2 Comparison of pre-/postoperative examination results in case example #1 A: Corneal FD-OCT demonstrates the preoperative corneal scar of the patient in example #1. The maximum opacity depth was 149 μm , the maximum crater depth was 131 μm and a baseline epithelial thickness was 50 μm . Corneal FD-OCT demonstrated the postoperative corneal scar of the patient removed as totally as possible. The residual central corneal depth was measured at 460 μm and anticipated residual corneal depth after dual photoablation was 465 μm . B: Slit-lamp photographs in a 23-year-old patient with lattice corneal dystrophy preoperatively and 1y after dual photoablation. The corneal opacities reduced significantly.

topographic indices, the postoperative values improved greatly. Topographic cylinder decreased from 2.3 to 0.44 D, SAI improved from 2.98 to 1.51, SRI improved from 2.50 to 0.95. The preoperative slit-lamp photograph showed gray and white grid corneal stromal opacities. The postoperative photograph demonstrated the corneal scarring was significantly reduced one year after the treatment (Figure 2B). The slit-lamp photographs of the cornea before and after dual photoablation are shown in Figure 2B. His postoperative UCVA was 20/50 Snellen OD and BSCVA was 20/30 Snellen OD. His postoperative SE was -0.50 D.

Case Example #2: Band Keratopathy A 65-year-old male complained with blurred vision of left eye after cataract surgery 6mo ago. His UCVA was 20/40 Snellen OS. His BSCVA was 20/30 Snellen. The preoperative FD-OCT showed corneal opacities of left eye. The maximum scarring depth was 96 μm with no crater formation and a baseline epithelial thickness was 60 μm . In order to remove the corneal opacities as deeply as possible, the first PTK ablation profile was set at the depth of 100 μm with an optic zone of 7 mm. Subtracting the thickness of the epithelium, only 40 μm corneal stroma were removed. According to previous literature, if the ablation depth of the corneal stroma is less than 85 μm , it may not result in significant hyperopia^[9]. And his historical refraction prior to the photoablation was +0.25 D. Therefore, after the initial ablation, there is no need to correct the refractive errors. The residual central corneal depth was 453 μm after the 40 μm ablation (487 μm preoperative; 40 μm PTK ablation; anticipated residual corneal depth was 447 μm ; Figure 3A).

The postoperative photograph demonstrated the corneal opacities was removed totally 6mo after the treatment (Figure 3A). His postoperative UCVA was 20/30 Snellen and BSCVA was 20/30 Snellen. The CS values converted into log units and his postoperative CS values showed significant improvement compared to preoperative ones at low and medium spatial frequencies (1.5, 3, 6, 12 cpd) in photopic condition (Figure 3C).

DISCUSSION

Currently, there is still no consensus on the best treatment option for anterior corneal scarring. The ideal photoablation protocol should aim not only to remove the corneal opacities but also to improve the irregularities of the cornea. Compared to corneal transplantation or superficial ablation, PTK, with its advantages of being less invasive and more accurate, has been used with increasing frequency in treatment of anterior corneal pathology^[10-11]. In 1995, PTK was Food and Drug Administration (FDA)-approved for the treatment of anterior corneal pathology which result in decreased acuity or pain^[12]. It must be noticed that the corneal pathology should be in the anterior one-third of the cornea, and that at least 250 μm of stroma bed should be left after photoablation. The common indications for PTK include band keratopathy, recurrent corneal erosions, anterior corneal dystrophies (lattice, macular, and Reis-Buckler's dystrophy) and corneal degenerations. At present, the indications are extended to anterior corneal scars from various etiologies^[4,13-17]. In our study, the inclusion criteria included viral keratitis, band keratopathy, corneal dystrophy, traumatic corneal disease and corneal chemical burn.

According to FDA guidelines, the corneal lesions ablated

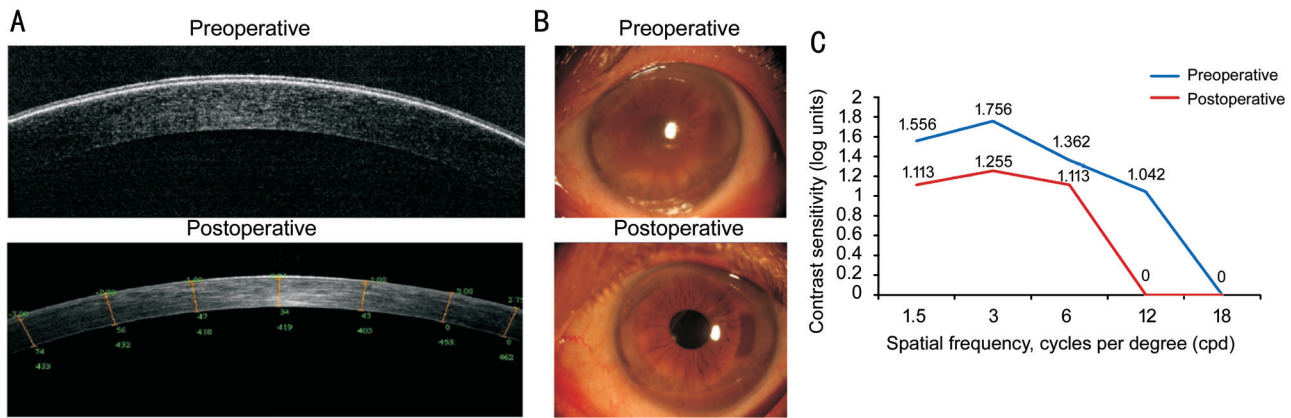


Figure 3 Comparison of pre-/postoperative examination results in case example #2 A: Corneal FD-OCT demonstrated the preoperative corneal opacities of the patient in Example #2. The maximum opacity depth was 96 μm and a baseline epithelial thickness was 60 μm . Corneal FD-OCT demonstrated the postoperative corneal scar ablated totally. The residual central corneal depth was 453 μm and anticipated residual corneal depth after ablation was 447 μm . B: Slit-lamp photographs in a 65-year-old patient with band keratopathy preoperatively and 6mo after photoablation. The cornea became transparent postoperatively. C: Postoperative CS values showed significant improvement compared to preoperative ones at low and medium spatial frequencies (1.5, 3, 6, 12 cpd) in photopic condition.

by PTK procedure should be within the anterior one-third of the corneal thickness. In our series, the maximum depth of corneal lesions in 8 patients was more than one-third of the total corneal thickness, the depth of the corneal tissue removed was within borderline thickness. Nominal ablation depth was 100-149 μm . After dual photoablation, all the patients showed a gain of at least 2 logMAR line of UCVA and BSCVA, although a little bit opacity remained. In photopic conditions, the postoperative CS values improved statistically significant at different spatial frequencies, compared to the preoperative results. The CS in mesopic conditions haven't been measured, because most of the patients with poor visual acuities preoperatively were unable to cope with the measurement. The satisfactory outcomes of visual function may be attributed to increased corneal transparency and improved irregularities of the corneal surface.

As to the corneal opacity, in the past, the depth of the corneal opacity can only be estimated by the surgeon under slit-lamp microscope before PTK surgery, and the prediction of maximum ablation depth is poor. So, after PTK surgery, the postoperative anatomic and visual outcomes were not satisfying. The recent advances in OCT technology has shown that OCT can assist in the determination of the accurate depth of the tissue ablation and prediction of the hyperopic shift caused by PTK procedure^[18-20]. There is a report in the literature describing OCT-guided PTK in a series of 22 patients with anterior corneal scarring^[21]. BSCVA (in logMAR) improved from a mean of 0.82 preoperatively to a mean of 0.40 postoperatively. And postoperative SE averaged 0.78 diopters. A recent report has shown that OCT-guided PTK in 9 eyes of 8 patients^[19]. Mean UCVA was 20/41 (range 20/25-

20/80) postoperatively compared to 20/103 (range 20/30-20-400) preoperatively. Mean CDVA was 20/29 (range 20/15-20/60) postoperatively compared to 20/45 (range 20/30-20/80) preoperatively. Postoperative SE averaged $+1.38 \pm 2.37$ D. According to the previous literatures, OCT-guided PTK ablation protocol is an effective and economic technology to improve the visual function of the patients with anterior corneal scarring.

It is known that hyperopic shift is a side effect of PTK procedure^[22-23]. Our study provides a model based on 1310 nm FD-OCT measurements which improve the predictability of refractive outcomes following dual photoablation. This model included two procedures: first, the preoperative FD-OCT measured-depth-of-treatment was ablated by PTK; second, after accounting for the patient's preoperative SE and the hyperopic refractive errors caused by PTK ablation, PRK was performed to bring the patient to the desired refractive outcome. In our study, the postoperative SE averaged -0.53 D (-1.49 - 0.42). The good refractive results were guaranteed by two factors: first, accurate measurement of the depth of the corneal opacities by OCT; second, careful calculations during the dual myopic/hyperopic excimer laser ablation profile. Mori *et al*^[24] were the first to develop an OCT-guided PTK simulation profile and got good outcomes. Kim *et al*^[25] reported satisfactory visual outcomes using FD-OCT guided PTK for the photoablation of corneal dystrophy. Cleary *et al*^[19] reported 9 eyes of 8 patients treated with PTK guided by FD-OCT, manifest refraction SE was $+1.38 \pm 2.37$ D. Rush *et al*^[21] reported 22 patients treated with PRK under the guidance of OCT, the postoperative SE was 0.78 D (0.49 - 1.07). Although the above small case series confirmed the accurate refractive

prediction of OCT-guided PTK or PRK treatment, there are few reports of OCT-guided PTK combined with PRK treatment.

And it was noticed that the visual function of patients with corneal ablation depth of more than 100 μm recovered more slowly than those who ablated less. In general, the visual function for those ablated more improved 3mo after treatment. According to our experience, the process of visual recovery is mainly dependent on the process of corneal wound healing, which improves the regularity of the corneal surface. Wound healing starts from epithelial cells proliferation and migration within the first 12-48h^[26-27]. Large corneal epithelial defects will be healed within 3-5d. Anchoring fibrils form to help the epithelium adhere to the corneal stroma and continue to increase over several weeks after the photoablation^[28].

As to the irregularity of the corneal surface, several literatures reported patients treated with OCT-guided transepithelial PTK or PRK for anterior corneal scarring could improve the regularity of corneal surface. Comparison of preoperative and postoperative corneal topographic morphologic indices showed significant improvement in most parameters^[19,21]. In our series, the postoperative corneal topography-measured cylinder and morphologic indices significantly improved. Topographic cylinder decreased from 2.35 to 1.32 D. Topographic SAI improved from 1.57 (1.05-2.07) to 0.98 (0.46-1.51). Topographic SRI improved from 3.08 (1.48-4.67) to 1.74 (0.52-2.97). It is noticed that when the laser is ablated directly on an irregular cornea, surface craters and peaks are ablated at the same rate, so the irregularity would not be improved. A blocking liquid (carboxymethylcellulose solution 0.5%) fills into the craters, preventing ablation there but allowing ablation of peaks, thus improving corneal regularity^[29]. And if the blocking liquid could not be used appropriately, large amounts of irregular astigmatism are developed after photoablation.

Because the numerous variables were involved in different corneal diseases, surgical procedures, blocking liquid and refractive surgery platforms, it is difficult to compare the results among several studies in which OCT-guided PTK combined with PRK were performed for the treatment of corneal pathology. In conclusion, the OCT-guided PTK combined with PRK profiles reported in this study can result in satisfactory anatomic and visual outcomes in patients with anterior corneal scars.

ACKNOWLEDGEMENTS

Foundations: Supported by Grants from National Natural Science Foundation of China (No.81900830); National Key Research & Development Intensification Key Project (No.2016YFC1101103; No.2018YFA0107302); Basic Science and Frontier Technology Project in Chongqing Science and Technology Commission (No.cstc2016jcyjA0297).

Conflicts of Interest: Yang YL, None; Jian Q, None; Liu B, None; Wang K, None; Chen YJ, None; Tan L, None; Pu MJ, None; Liu Y, None.

REFERENCES

- 1 Lyall DA, Tarafdar S, Gilhooly MJ, Roberts F, Ramaesh K. Long term visual outcomes, graft survival and complications of deep anterior lamellar keratoplasty in patients with herpes simplex related corneal scarring. *Br J Ophthalmol* 2012;96(9):1200-1203.
- 2 Nagpal R, Maharana PK, Roop P, Murthy SI, Rapuano CJ, Titiyal JS, Vajpayee RB, Sharma N. Phototherapeutic keratectomy. *Surv Ophthalmol* 2020;65(1):79-108.
- 3 Fagerholm P. Phototherapeutic keratectomy: 12y of experience. *Acta Ophthalmol Scand* 2003;81(1):19-32.
- 4 Jun I, Jung JW, Choi YJ, Kim TI, Seo KY, Kim EK. Long-term clinical outcomes of phototherapeutic keratectomy in corneas with granular corneal dystrophy type 2 exacerbated after LASIK. *J Refract Surg* 2018;34(2):132-139.
- 5 Dogru M, Katakami C, Yamanaka A. Refractive changes after excimer laser phototherapeutic keratectomy. *J Cataract Refract Surg* 2001;27(5):686-692.
- 6 Rush SW, Rush RB. Optical coherence tomography-guided transepithelial phototherapeutic keratectomy for central corneal opacity in the pediatric population. *J Ophthalmol* 2018;2018:3923617.
- 7 Siebelmann S, Horstmann J, Scholz P, Bachmann B, Matthaei M, Hermann M, Cursiefen C. Intraoperative changes in corneal structure during excimer laser phototherapeutic keratectomy (PTK) assessed by intraoperative optical coherence tomography. *Graefes Arch Clin Exp Ophthalmol* 2018;256(3):575-581.
- 8 Salze JJ. *Corneal laser surgery*. UK: Mosby-Year Book Inc; 1995:213.
- 9 Stark WJ, Chamon W, Kamp MT, Enger CL, Rencs EV, Gottsh JD. Clinical follow-up of 193-nm ArF excimer laser photokeratectomy. *Ophthalmology* 1992;99(5):805-812.
- 10 Lewis DR, Price MO, Feng MT, Price FW Jr. Recurrence of granular corneal dystrophy type 1 after phototherapeutic keratectomy, lamellar keratoplasty, and penetrating keratoplasty in a single population. *Cornea* 2017;36(10):1227-1232.
- 11 Hafner A, Langenbucher A, Seitz B. Long-term results of phototherapeutic keratectomy with 193-nm excimer laser for macular corneal dystrophy. *Am J Ophthalmol* 2005;140(3):392-396.
- 12 Rapuano CJ. Excimer laser phototherapeutic keratectomy. *Int Ophthalmol Clin* 1996;36(4):127-136.
- 13 Lee J, Kim JH, Lee D, Chang JW, Shin JY, Seo JW, Seo MH, Moon NJ. Long-term clinical outcome of femtosecond laser-assisted lamellar keratectomy with phototherapeutic keratectomy in anterior corneal stromal dystrophy. *Br J Ophthalmol* 2018;102(1):31-36.
- 14 Ghanem VC, Passos ML, Piccinini AL, Ghanem RC. Focal phototherapeutic keratectomy for the treatment of apical leucoma syndrome. *Arq Bras Oftalmol* 2018;81(4):344-347.
- 15 Lee WS, Lam CK, Manche EE. Phototherapeutic keratectomy for epithelial basement membrane dystrophy. *Clin Ophthalmol* 2017;11:15-22.

- 16 Wilson SE, Marino GK, Medeiros CS, Santhiago MR. Phototherapeutic keratectomy: science and art. *J Refract Surg* 2017;33(3):203-210.
- 17 Kepez Yildiz B, Urvasizoglu S, Yildirim Y, Agca A, K Besek N, Fazil K, Eris E, Aygit ED, Taskapili M, Demirok A. Changes in higher-order aberrations after phototherapeutic keratectomy for subepithelial corneal infiltrates after epidemic keratoconjunctivitis. *Cornea* 2017;36(10):1233-1236.
- 18 Li Y, Yokogawa H, Tang ML, Chamberlain W, Zhang XB, Huang D. Guiding flying-spot laser transepithelial phototherapeutic keratectomy with optical coherence tomography. *J Cataract Refract Surg* 2017;43(4):525-536.
- 19 Cleary C, Li Y, Tang ML, Samy El Gendy NM, Huang D. Predicting transepithelial phototherapeutic keratectomy outcomes using Fourier domain optical coherence tomography. *Cornea* 2014;33(3):280-287.
- 20 Ventura BV, Moraes HV Jr, Kara-Junior N, Santhiago MR. Role of optical coherence tomography on corneal surface laser ablation. *J Ophthalmol* 2012;2012:676740.
- 21 Rush SW, Han DY, Rush RB. Optical coherence tomography-guided transepithelial phototherapeutic keratectomy for the treatment of anterior corneal scarring. *Am J Ophthalmol* 2013;156(6):1088-1094.
- 22 Rapuano CJ. Excimer laser phototherapeutic keratectomy in eyes with anterior corneal dystrophies: short-term clinical outcomes with and without an antihyperopia treatment and poor effectiveness of ultrasound biomicroscopic evaluation. *Cornea* 2005;24(1):20-31.
- 23 Sharma N, Prakash G, Sinha R, Tandon R, Titiyal JS, Vajpayee RB. Indications and outcomes of phototherapeutic keratectomy in the developing world. *Cornea* 2008;27(1):44-49.
- 24 Mori H, Miura M, Iwasaki T, Goto H, Sakurai Y, Watanabe Y, Yasuno Y. Three-dimensional optical coherence tomography-guided phototherapeutic keratectomy for granular corneal dystrophy. *Cornea* 2009;28(8):944-947.
- 25 Kim TI, Hong JP, Ha BJ, Stulting RD, Kim EK. Determination of treatment strategies for granular corneal dystrophy type 2 using Fourier-domain optical coherence tomography. *Br J Ophthalmol* 2010;94(3):341-345.
- 26 Fountain TR, de la Cruz Z, Green WR, Stark WJ, Azar DT. Reassembly of corneal epithelial adhesion structures after excimer laser keratectomy in humans. *Arch Ophthalmol* 1994;112(7):967-972.
- 27 van Setten GB, Koch JW, Tervo K, Lang GK, Tervo T, Naumann GO, Kolkmeier J, Virtanen I, Tarkkanen A. Expression of tenascin and fibronectin in the rabbit cornea after excimer laser surgery. *Graefes Arch Clin Exp Ophthalmol* 1992;230(2):178-183.
- 28 SundarRaj N, Geiss MJ 3rd, Fantes F, Hanna K, Anderson SC, Thompson KP, Thoft RA, Waring GO 3rd. Healing of excimer laser ablated monkey corneas. An immunohistochemical evaluation. *Arch Ophthalmol* 1990;108(11):1604-1610.
- 29 Rush SW, Matulich J, Rush RB. Long-term outcomes of optical coherence tomography-guided transepithelial phototherapeutic keratectomy for the treatment of anterior corneal scarring. *Br J Ophthalmol* 2014;98(12):1702-1706.