

Surgical correction of recurrent epiblepharon in Chinese children using modified skin re-draping epicanthoplasty

Shou-Long Hu¹, Wen-Qing Shi², Ting Su^{3,4}, Qian-Min Ge², Qiu-Yu Li², Biao Li², Rong-Bin Liang², Pei-Wen Zhu², Yi Shao²

¹National Center for Children's Health, MOE Key Laboratory of Major Diseases in Children, Department of Ophthalmology, Beijing Children's Hospital, Capital Medical University, Beijing 100045, China

²Department of Ophthalmology, the First Affiliated Hospital of Nanchang University, Jiangxi Province Clinical Ophthalmology Institute, Nanchang 330006, Jiangxi Province, China

³Eye Institute of Xiamen University, Fujian Provincial Key Laboratory of Ophthalmology and Visual Science, School of Medicine, Xiamen University, Xiamen 361102, Fujian Province, China

⁴Department of Ophthalmology, Massachusetts Eye and Ear, Harvard Medical School, Boston 02114, USA

Correspondence to: Yi Shao. Department of Ophthalmology, the First Affiliated Hospital of Nanchang University, Jiangxi Province Clinical Ophthalmology Institute, 17 Yongwaizheng Street, Donghu, Nanchang 330006, Jiangxi Province, China. freebee99@163.com

Received: 2020-01-16 Accepted: 2020-04-03

Abstract

• **AIM:** To evaluate the clinical efficacy of the modified skin re-draping epicanthoplasty procedure for correction of recurrent lower lid epiblepharon in Chinese children.

• **METHODS:** From 2016 to 2018, 18 children (10 males and 8 females, average age 6.2±1.7y; 30 eyes) with recurrent epiblepharon who attended Beijing Children's Hospital were included in the study. All the children had undergone lower eyelid surgery for epiblepharon. Surgical design included using an additional incision along the upper palpebral margin, to avoid vertical scarring on the upper lid. The re-draping method was used to correct recurrent epiblepharon. Follow-up ranged from 3 to 24mo. Postoperative surgical outcomes, complications, and subjective satisfaction were evaluated.

• **RESULTS:** Complete correction of cilia touching the cornea was observed in all patients during an average follow-up of 7.1mo. No "dog ears" or obvious scars were formed after surgery. All parents were satisfied with the

cosmetic results and none complained. Mean astigmatism decreased from 2.39±0.79 diopter (D) preoperatively to 2.19±0.79 D at 6mo after surgery; however, the difference was not significant. Best-corrected visual acuity improved, although the change in mean visual acuity was not significant. No recurrence occurred during the follow-up period.

• **CONCLUSION:** This surgical modified skin re-draping technique is effective and highly satisfactory for correction of recurrent epiblepharon. The approach is characterized by a simple design, a straightforward procedure, inconspicuous scarring, and good postoperative appearance.

• **KEYWORDS:** recurrent epiblepharon; modified skin re-draping epicanthoplasty; Chinese children

DOI:10.18240/ijo.2021.02.06

Citation: Hu SL, Shi WQ, Su T, Ge QM, Li QY, Li B, Liang RB, Zhu PW, Shao Y. Surgical correction of recurrent epiblepharon in Chinese children using modified skin re-draping epicanthoplasty. *Int J Ophthalmol* 2021;14(2):217-222

INTRODUCTION

Congenital epiblepharon is one of the common eyelid anomaly among orient children^[1-3]. In this condition, a skin fold that stretches from the upper eyelid to lower eyelid covering the inner angle of the eye, vertically tilts the lower eyelid, pushing the eyelash against the globe, potentially causing corneal injury. In the oriental population, the incidence of epiblepharon is 46% among newborn babies. As children grow, around 2% report persistent symptoms, and surgical correction should be performed for cases who have significant corneal injury from the lashes^[4-5]. Previously described surgical methods, including "bracing sutures" and skin excision procedures (most commonly the modified Hotz procedure, which involves excision of the skin and orbicularis muscle with tarsal fixation), have high rates of poor correction and recurrence. Previous reports demonstrate recurrence rates of approximately 10% when patients are treated using bracing sutures, while around 9% of patients are poorly corrected using the modified Hotz procedure^[6-8]. One possible cause of these relatively high rates of poor outcomes may be the

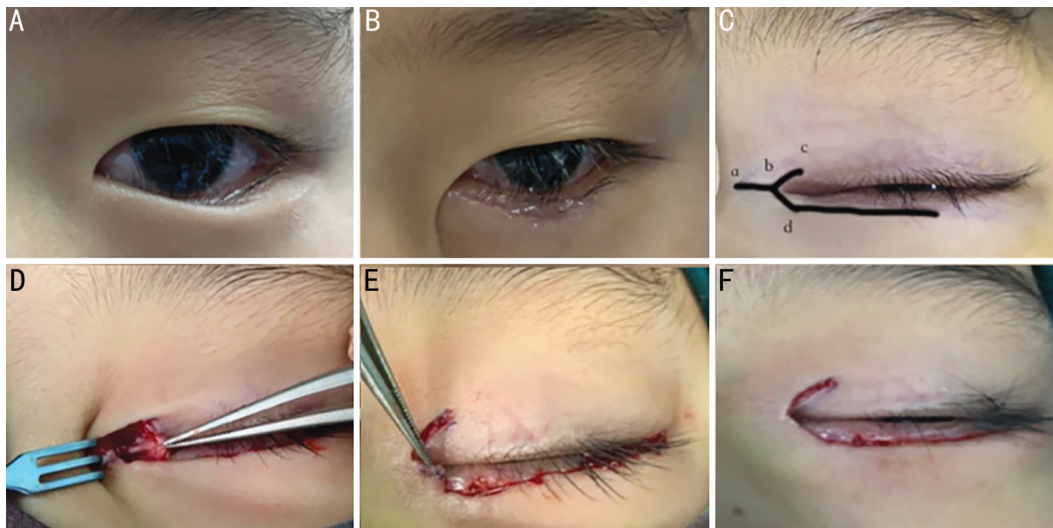


Figure 1 Operation design and procedure A: Preoperative touching of the cornea by cilia. B: Prominent scarring was exposed when the skin was tracked downwards. C: Incision design: Point a was the projected position of point b on the skin surface. Point b was marked 2 mm medial from the lacrimal lake. By pulling the nose skin in the medial direction, point c was the end of supraciliary line along the ciliary margins, extending from point b, which was 3 mm above the upper ciliary margins and the length of bc was approximately 5 mm. Point d was marked around the lacrimal punctum in the lower eyelid. D: The pretarsal orbicularis muscle was excised to expose the medial epicanthus tendon after the skin incision. E: The abnormal skin tension from the medial canthus transfers to a subciliary incision. The abc flap tracked downwards spontaneously. F: Status after removal of the dense fibrous tissue and abnormal orbicularis oculi muscle above the medial canthal tendon was completed. The eye lash and the scar were immediately corrected. There was significant improvement of deformation of the lower eyelid compared with the preoperative status.

presence of epicanthal folds (EFs) in the oriental population^[9]. A more fundamental solution is to choose epicanthoplasty as the correction method for epiblepharon, as it can remove the tangential cause; namely, the medial EF. Nevertheless, no research has previously considered medial epicanthoplasty as a correction procedure for lower lid recurrent epiblepharon. Here, we describe a surgical technique to correct recurrent epiblepharon and its clinical results. This approach offers advantages, including a simple skin incision, straightforward procedure, and reduced scarring in the medial epicanthal area.

SUBJECTS AND METHODS

Ethical Approval This study was approved by the Medical Ethics Committee of the First Affiliated Hospital of Nanchang University (CDYFY-LL-2016026). The procedures were in accordance with the principles of the Declaration of Helsinki. All participants volunteered to cooperate and their guardians signed informed consent forms, with awareness of the study purposes and potential risks.

Patients and Methods In this study, corrective surgery, using the modified skin re-draping method, was performed on 18 Chinese children (30 eyes) with recurrent epiblepharon from January 2016 to December 2018 in First Affiliated Hospital of Nanchang University. The patients ranged in age from 4 to 10y (mean=6.2±1.7y). The patient group consisted of 10 males and 8 females. Prior surgery for epiblepharon had been conducted using “bracing sutures” or “skin excision” procedures. The

time of recurrence following prior surgery ranged from 3 to 24mo; 10 cases recurred 6mo after surgery, 5 at 12mo, and 3 at 24mo after surgery. Most patients had undergone one prior procedure, while one patient had undergone the same procedure (“bracing sutures”) twice. Three cases had received an excision skin procedure. The follow-up period ranged from 3 to 24mo.

Surgical Procedure All patients with recurrent epiblepharon were operated by the author (Hu SL) using the modified skin re-draping technique. All procedures were performed under general anesthesia. The incision design was as Figure 1: point b was marked 1.5 mm medial to the lacrimal lake, while the medial semilunar skin was pulled in the medial direction. Point a was the point of the new medial epicanthus, which was the projected position of point b on the skin surface, when in the natural state of tension. Point d was marked around the lacrimal punctum, on the subciliary line, 1.5 mm below the lower lid margin. The incision line passed through points a, b, and d, which was 1.5 mm below the lower lid margin, through the whole eyelid length, or the medial two thirds, according to the severity of epiblepharon. One supraciliary line along the ciliary margins was marked, extending from point b; the end of this line was point c, which was 3 mm above the upper ciliary margins and the length of bc was approximately 5 mm^[10-11]. Before skin incision, to reduce bleeding, a mixture of 2% lidocaine and 1:100 000 epinephrine was injected at the incision site. The

skin flap was raised using blunt dissection, to avoid damaging the lacrimal canaliculus. The core procedure was removal of the abnormal orbicularis oculi muscle beneath the EF after exploration of the medial canthal tendon (Figure 1E). Using this method, abnormal tension in the EF was immediately decreased and the skin flap was retracted in the inferolateral direction and the epiblepharon was completely corrected almost spontaneously (Figure 1F).

When dissection was conducted between the tarsal plate and the skin-muscle flap, to expose the tarsal plate and release the scar (abnormal adhesions between the skin and tarsal plate) from the prior surgery, thermal cauterization was applied to the bleeding points.

Point a was sutured to point b on the medial canthal tendon. Then, the excess area of the skin flap was trimmed and the subciliary incision closed using 7-0 nylon sutures. For patients with severe EF, on the upper eyelid, a “dog-ear” may be required correction. For severe patients, one or two additional cilia rotating sutures were placed on the end of the tarsal plate, particularly at the medial part of the incision.

After the operation, all patients received ofloxacin eye ointment twice daily for 7-10d, until the suture was completely removed.

Postoperative Evaluation Surgical methods were assessed according to cosmetic results and postoperative complications. All postoperative follow-up assessments were performed in an outpatient setting, in which the position of the cilia and epiblepharon recurrence were monitored by slit lamp examination. The curvature of the lid margin, inner canthus, and postoperative scar were observed and patients carefully monitored for surgical complications during the follow-up period. Cosmetic results were assessed according to the subjective satisfaction of the parents at the last follow-up.

Best-corrected visual acuity and refraction were analyzed at 6mo after the operation. Astigmatism was defined as with-the-rule (WTR) if the cylinder axis was within 20° of 180°, and as against-the-rule (ATR) if the cylinder axis was within 20° of 90°. Statistical analyses were conducted using SPSS 26.0 for Windows (SPSS, Chicago, IL, USA).

RESULTS

There were 15 (83.3%) patients who have a best-corrected visual acuity of 20/20, 3 patients between 20/40 to 20/80. There were 2 (11%) patients with amblyopia after full correction of the refractive error, whose best-corrected visual acuity were between 20/60 and 20/80 from meridional amblyopia. All bilateral cases improved within a few months after the operation, without patching. We compared best-corrected visual acuity before and after surgery and found that it improved; however, the change was not significant different during the follow-up period.

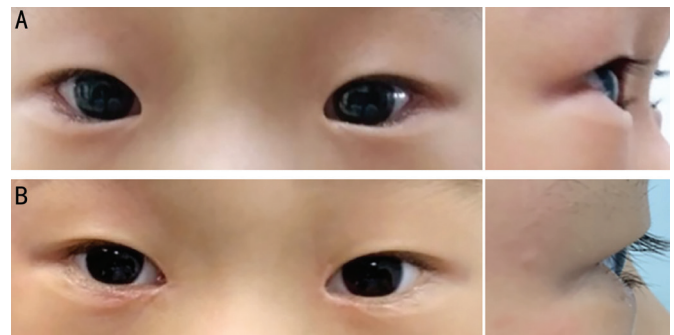

Figure 2 A comparative photograph of a five-year-old boy who underwent the described procedure A: Pre-operation; B: 4mo post-operation.

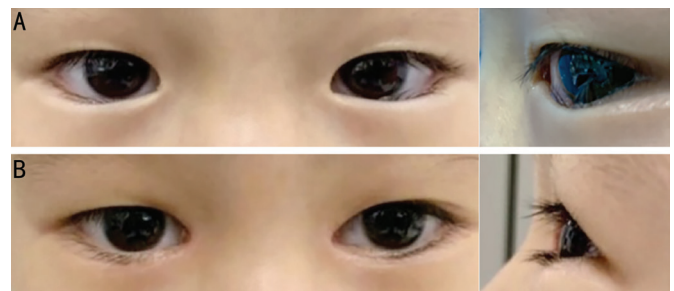

Figure 3 A comparative photograph of a seven-year-old boy who underwent the described procedure A: Pre-operation; B: 4mo post-operation.

Analysis of refraction at the first visit showed a mean spherical error of 0.21 ± 2.15 diopter (D) for the right eye and 0.25 ± 2.21 D for the left eye. Astigmatism of ≥ 2.0 D was found in 28 of the 36 (77.8%) eyes, and was largely WTR (32 eyes or 88.9%) and only oblique in 4 eyes (11.1%). The mean astigmatism before the operation in the right and left eyes was 2.37 ± 0.69 and 2.41 ± 0.91 D respectively, and the mean astigmatism decreased from 2.39 ± 0.79 D preoperatively to 2.19 ± 0.79 D at 6mo after surgery; however, the difference was not significant. There was no significant shifts in the axes after the operation.

All patients showed favorable results during the follow-up period. There were no patients with the complications of ectropion or lid retraction. The inner canthus of the upper and lower eyelids showed excellent linearity and was smoothly curved (Figure 2) and the lower lid became smooth and flattened. Scars from the previous sutures disappeared and there was almost no scar in the medial canthal region following surgery (Figures 2B, 3B). No recurrence occurred during the follow-up period of 3 to 24mo. Only a few parents were displeased with the cosmetic results because their children grew older. There were four patients with suture abscesses and one patient with wound dehiscence.

DISCUSSION

Epiblepharon is a fold of skin, which stretches the eyelid and pushes the lashes against the eyeball, and is particularly common among Asian people. Usually, the medial part of the

Table 1 Surgical correction of epiblepharon in children

First author	Year	Operation method	Effect of the operation
Hayasaka S ^[13]	1989	Lid-bracing sutures	77% of patients becomes free of symptoms, recurrences developed in 23% patients
Jung JH ^[14]	2011	Skin redraping epicanthoplasty	Recurrence and surgical complications were not observed in any patient
Kwon MJ ^[15]	2005	Epiblepharon repair along with epicanthoplasty	Relieving cilia-cornea touch
Kwon MJ ^[15]	2005	Root Z-epicanthoplasty	Provides moderate degree epicanthal correction and does not leave noticeable scar
Jeong HC ^[16]	2016	The minimal skin & orbicularis oculi muscle resection with full thickness rotating suture technique	95.9% of patients had no recurrence
Hwang SW ^[17]	2008	Splitting the lid margin combined with the excision of redundant skin and muscle	Ensures easier eversion of the cilia in epiblepharon repair, without disturbing the posterior lamella or causing unfavourable results

lower eyelid are involved bilaterally. Epiblepharon has been treated with many surgical procedures in recent years (Table 1). Traditional operations, including full thickness eyelid sutures, or excision of the skin and orbicularis muscle, have been the first choice to treat epiblepharon by ophthalmologists. The former correct the defect through creating a scar between the lower eyelid retractor, orbicularis and the skin. This procedure is simple and fast; however, it is associated with high recurrence rates of up to 29%. The latter is the most commonly favorable operation for Chinese ophthalmologists. The chance of recurrence can also be increase if too little skin is removed. A disadvantage of the Hotz procedure is that it cannot correct the medial part of the cilia because of the location of the tarsus, hence the medial cilia can return to an inverted orientation^[12]. Moreover, the medial canthal region tends to look unnatural after surgery using either of these two procedures.

Given the high rates of recurrence associated with traditional surgical methods, we consider that the key to achieving satisfactory results in Asian individuals with epiblepharon is understanding of the true nature of the epicanthus. It is necessary to analyze what causes the high rates of recurrence preoperatively, including the anatomical characteristics of the medial canthal area, to properly perform the surgical technique. Earlier opinions of the anatomical character of the medial canthal fold is that the skin tissue is not sufficient in the vertical direction and redundant in the horizontal, pushing the eyelid to roll upwards. Recent research indicates that the EF is not just a skin fold, but rather an anatomical defect of the preseptal part of the orbicularis oculi muscle over the tendon^[18]. In addition to anatomical studies, researchers have reported clinical evidence from botulinum injection of preseptal orbicularis muscle^[19]. This vertical abnormal tightening of the orbicularis creates a sharp ridge similar to the original web shape, the tension rotates the lash, which can then contact the eye ball. This anatomical finding is proven by our procedure, where, just by cutting the dense connective tissue between the skin

and orbicularis oculi muscle in the medial canthal area, the epiblepharon can be almost entirely corrected.

Epicanthoplasty combined with a lower lid entropion operation has been an innovative method for the treatment of congenital entropion in Asians^[20]; however, these combined techniques are not popular among Chinese ophthalmologists because of their disadvantages, which include difficult design and resulting prominent scars. Therefore, epicanthoplasty is usually performed by cosmetic surgeons.

Epicanthoplasty using the skin redraping method was previously described to correct EFs for cosmetic concerns^[21]. This method is simple and straightforward. The second advantage of this approach is that it can be performed for any type of EF^[21]. Recently, surgeons have adopted skin re-draping epicanthoplasty in combination treatment for epiblepharon, such as for children with epiblepharon and recurrence of an EF or inversus epiblepharon^[14,22-24]; however, there are no reports of using of this procedure to treat recurrent epiblepharon.

Here, we describe modification of this surgical technique to correct recurrent epiblepharon and its clinical results, which offers several advantages, including a simple design skin incision, ease of operation, and almost no scar in the medial epicanthal area.

When using this method, it is important to attend to the following issues: 1) We performed the procedure using a modified transverse straight incision, using the upper palpebral margin incision method, to allow the upper lid to close naturally, rather than spending more time closing an upper eyelid incision. Moreover, this approach avoids scar formation in the visible regions of the canthus. 2) The tension-free skin re-draping method. Using this method, exploration of the medial canthal tendon and removal of the abnormal orbicularis oculi muscle beneath the EF above the medial canthal tendon is crucial. This step alone immediately eliminates the abnormal tension in the EF and simultaneously corrects the epiblepharon. The skin flap was retracted in the inferolateral

direction for re-draping (Figure 1F). In our study, there was no recurrence, and the core reason for this is that we resolved the key anatomical reason for the epiblepharon. 3) The rotation can be adjusted by sutures which are placed onto the tarsus. In most cases, with management of the abnormal orbicularis muscle, the rotation recovers spontaneously. If more rotation is needed, one or two sutures can be placed on the more inferior part of the tarsus. 4) Prior scarring and eyelid deformation were resolved by the tension release. As is established, medial canthal scarring is primarily induced by high wound tension. Correction of the tension and detachment between the skin, orbicularis, and eyelid retractor, leads to spontaneous disappearance of the prior scar and deformation of the lower eyelid (Figure 2B).

Astigmatism is reported to be highly correlated with eyelid morphology^[25], corneal spherocylinder^[26]. The changing of transient corneal topography induced by eyelid after reading^[27], supports the hypothesis that the corneal contour can be influenced by the mechanical force of the eyelid. Likewise, the mechanical force created by abnormal eyelid tension may alter the corneal curvature in patients with epiblepharon^[28]. A few researchers have reported the relationship between epiblepharon and astigmatism^[28-29].

Our results are very similar to those of Lee and associates^[28], where 52% had astigmatism of ≥ 1 D, with >90% of WTR type. Furthermore, the findings reported here are similar to the previous research^[30], which found that higher numbers of eyelash touching the cornea were associated with more severe astigmatism. In our study, more than 45% patients had astigmatism of ≥ 1.5 D. As the patients included in our study had recurrent epiblepharon, they had more severe touching of the cornea before the initial surgery, which likely explains the higher degree of astigmatism among our patients. Hence epiblepharon surgery may reduce corneal astigmatism. However, in our study, there is no significant change in astigmatism postoperatively, we postulate that the first surgery reduced the astigmatism, while the second surgery only has an additional minor influence; hence, no significant difference was detected. Future research are required to understand the pathogenesis of corneal morphology changing and how it proceeds over time.

In conclusion, the modified skin re-draping epicanthoplasty procedure we describe is simple to design and easy to perform. This procedure provides the additional benefit of a bright and smoothly contour of the eyelid by correction of the epiblepharon, and is associated with minimal scar formation.

ACKNOWLEDGEMENTS

Foundations: Supported by National Natural Science Foundation of China (No.81660158; No.81400372); Natural Science Key Project of Jiangxi Province (No.20161ACB21017).

Conflicts of Interest: Hu SL, None; Shi WQ, None; Su T, None; Ge QM, None; Li QY, None; Li B, None; Liang RB, None; Zhu PW, None; Shao Y, None.

REFERENCES

- 1 Sung Y, Lew H. Epiblepharon correction in Korean children based on the epicanthal pathology. *Graefes Arch Clin Exp Ophthalmol* 2019;257(4):821-826.
- 2 Shin DH, Woo KI, Kim YD. Relationship between lower eyelid epiblepharon and epicanthus in Korean children. *PLoS One* 2017;12(11):e0187690.
- 3 Yan YN, Chen T, Wei WB, Li DM. Epiblepharon in Chinese children: relationships with body mass index and surgical treatment. *J AAPOS* 2016;20(2):148-152.
- 4 Noda S, Hayasaka S, Setogawa T. Epiblepharon with inverted eyelashes in Japanese children. I. Incidence and symptoms. *Br J Ophthalmol* 1989;73(2):126-127.
- 5 Kim JS, Jin SW, Hur MC, Kwon YH, Ryu WY, Jeong WJ, Ahn HB. The clinical characteristics and surgical outcomes of epiblepharon in Korean children: a 9-year experience. *J Ophthalmol* 2014;2014:156501.
- 6 Kim MS, Sa HS, Lee JY. Surgical correction of epiblepharon using an epicanthal weakening procedure with lash rotating sutures. *Br J Ophthalmol* 2014;98(1):120-123.
- 7 Sundar G, Young SM, Tara S, Tan AM, Amrith S. Epiblepharon in east Asian patients: the Singapore experience. *Ophthalmology* 2010;117(1):184-189.
- 8 Ni JX, Shao CQ, Wang KY, Chen X, Zhou SJ, Lin HM. Modified hotz procedure combined with modified Z-epicanthoplasty versus modified hotz procedure alone for epiblepharon repair. *Ophthalmic Plast Reconstr Surg* 2017;33(2):120-123.
- 9 Saonanon P. The new focus on epicanthoplasty for Asian eyelids. *Curr Opin Ophthalmol* 2016;27(5):457-464.
- 10 Liu LQ, Li S, Fan JC, Gan C, Tian J, Jiao H, Feng SY. Inverted 'V-Y' advancement medial epicanthoplasty. *J Plast Reconstr Aesthet Surg* 2012;65(1):43-47.
- 11 Oh J, Lee K. Medial lower lid epiblepharon repair solely by skin-redraping medial epicanthoplasty. *Br J Ophthalmol* 2014;98(10):1437-1441.
- 12 Nakauchi K, Mimura. Fish tail resection for treating congenital entropion in Asians. *Clin Ophthalmol* 2012:831.
- 13 Hayasaka S, Noda S, Setogawa T. Epiblepharon with inverted eyelashes in Japanese children. II. Surgical repairs. *Br J Ophthalmol* 1989;73(2):128-130.
- 14 Jung JH, Kim HK, Choi HY. Epiblepharon correction combined with skin redraping epicanthoplasty in children. *J Craniofacial Surg* 2011;22(3):1024-1026.
- 15 Kwon MJ, Woo KI, Chang HR. Surgical correction for upper lid epiblepharon and epicanthal fold in children. *J Korean Ophthalmol Soc* 2005;46(9):1441-1446.

- 16 Jeong HC, Sohn EJ, Kwon YH, Ahn H. Surgical outcome of minimal resection with full thickness rotating suture technique for lower lid epiblepharon. *J Korean Ophthalmol Soc* 2016;57(9):1348-1353.
- 17 Hwang SW, Khwarg SI, Kim JH, Kim NJ, Choung HK. Lid margin split in the surgical correction of epiblepharon. *Acta Ophthalmol* 2008;86(1):87-90.
- 18 Kakizaki H, Ichinose A, Nakano T, Asamoto K, Ikeda H. Anatomy of the epicanthal fold. *Plast Reconstr Surg* 2012;130(3):494e-495e.
- 19 Nguyen A, Kwon B. Reconsideration of the epicanthus: evolution of the eyelid and the devolutional concept of Asian blepharoplasty. *Semin Plast Surg* 2015;29(3):171-183.
- 20 Kashima T, Katori N, Yamada T, Imagawa Y, Nakauchi K. Epicanthoplasty simultaneous with epiblepharoplasty in cases of epiblepharon with epicanthus. *Nippon Ganka Gakkai Zasshi* 2010;114(2):105-109.
- 21 Oh YW, Seul CH, Yoo WM. Medial epicanthoplasty using the skin redraping method. *Plast Reconstr Surg* 2007;119(2):703-710.
- 22 Chung YJ, Han KE, Park BY. Restoration of complicated epicanthus: modified reverse skin redraping with mini-epicanthoplasty for rescue in unsatisfied epicanthoplasty patients. *Ann Plast Surg* 2017;78(6):613-617.
- 23 Kwon BS, Kong JS, Kim YW, Kang SR. Corrective epicanthoplasty in patients with unnatural results of prior epicanthoplasty. *Ann Plast Surg* 2014;73(1):12-15.
- 24 Jin YB, Lyu DZ, Chen H, Ma G, Qiu YJ, Zou Y, Tremp M, Lin XX. Invisible scar medial epicanthoplasty: a novel approach. *J Plast Reconstr Aesthetic Surg* 2017;70(7):952-958.
- 25 Read SA, Collins MJ, Carney LG. The influence of eyelid morphology on normal corneal shape. *Invest Ophthalmol Vis Sci* 2007;48(1):112.
- 26 Garcia ML, Huang D, Crowe S, Traboulsi EI. Relationship between the axis and degree of high astigmatism and obliquity of palpebral fissure. *JAAPOS* 2003;7(1):14-22.
- 27 Collins MJ, Kloevekorn-Norgall K, Buehren T, Voetz SC, Lingelbach B. Regression of lid-induced corneal topography changes after reading. *Optom Vis Sci* 2005;82(9):843-849.
- 28 Lee DH, Jung JH, Ahn JH. Changes in corneal curvature after epiblepharon surgery in children. *J Craniofacial Surg* 2018;29(2): e191-e195.
- 29 Kim NM, Jung JH, Choi HY. The effect of epiblepharon surgery on visual acuity and with-the-rule astigmatism in children. *Korean J Ophthalmol* 2010;24(6):325.
- 30 Khwarg SI, Lee YJ. Epiblepharon of the lower eyelid: classification and association with astigmatism. *Korean J Ophthalmol* 1997;11(2):111.