

Utilizing dexamethasone intravitreal implant to control postoperative inflammation in refractory uveitis undergoing cataract surgery

Yong-Tao Li, Xue-Xue Cui, Xiao-Tong Yang, Bing Li, Xin-Jun Ren, Xiao-Rong Li, Xiao-Min Zhang

Tianjin Key Laboratory of Retinal Functions and Diseases, Eye Institute and School of Optometry, Tianjin Medical University Eye Hospital, Tianjin 300384, China

Correspondence to: Xiao-Min Zhang. Tianjin Key Laboratory of Retinal Functions and Diseases, Eye Institute and School of Optometry, Tianjin Medical University Eye Hospital, 251 Fukang Road, Tianjin 300384, China. Xzhang08@tmu.edu.cn

Received: 2020-04-16 Accepted: 2020-06-30

Abstract

• **AIM:** To report the effectiveness of intravitreal implantation of dexamethasone implant (Ozurdex) after phacoemulsification and intraocular lens implantation in refractory uveitis patients.

• **METHODS:** This single-center retrospective study conducted for refractory pan-uveitis patients who underwent cataract surgery combined with intravitreal Ozurdex implantation. The main outcome measurements were best-corrected visual acuity (BCVA), central retinal thickness (CRT), grade of anterior chamber cell (AAC), intraocular pressure (IOP), and systemic/ocular adverse events.

• **RESULTS:** Ten eyes of 7 patients were included. BCVA showed significant improvement at 1mo ($P=0.004$), 3mo ($P=0.0004$), and 6mo ($P=0.001$) post operation. There were no statistically significant differences in the postoperative CRT among follow-up groups ($P>0.05$). No significant differences were observed in the baseline IOP when compared to 1, 3, and 6mo (all $P>0.05$) post operation. One patient developed a transient elevated IOP post injection. Two eyes (20%) developed posterior capsular opacifications and underwent neodymium-doped yttrium aluminum garnet (Nd:YAG) laser capsulotomy. In six patients (8 eyes, 71.4%), the systemic steroid usage was reduced to below 10 mg/d. The patients experienced a mean of 1.4 ± 0.52 recurrences of inflammation in the 6mo before operation and 0.7 ± 0.48 in the 6mon post operation. The mean recurrence time was 13 ± 0.58 wk (range 12-14wk) post operation. In five of seven patients (7 out of 10 eyes), inflammation relapse was developed postoperatively. Only one patient (2 eyes) needed

increased amounts of oral corticosteroids. Intraocular inflammation recurrence in the remaining patients was controlled by topical steroids.

• **CONCLUSION:** Ozurdex is considered a safe and effective approach to control postoperative inflammation in cataract surgery for patients with refractory uveitis in our study. After the disappearance of Ozurdex's anti-inflammatory effects over time, in most cases the recurrent inflammation can be controlled by topical steroids.

• **KEYWORDS:** phacoemulsification; intraocular lens implantation; dexamethasone intravitreal implant (Ozurdex); refractory uveitis

DOI:10.18240/ijo.2021.02.21

Citation: Li YT, Cui XX, Yang XT, Li B, Ren XJ, Li XR, Zhang XM. Utilizing dexamethasone intravitreal implant to control postoperative inflammation in refractory uveitis undergoing cataract surgery. *Int J Ophthalmol* 2021;14(2):317-322

INTRODUCTION

Uveitis is a serious and potentially blinding disease throughout the world, which may induce irreversible ocular damage, impairment of visual acuity, and reduction in ocular-related life^[1-3]. Moreover, uveitis mostly occurs in individuals in their working-age, creating negative effects on the economy and the society^[4]. Currently, systemic therapies with steroids, immunosuppressants, and biologics are the main choices for treating pan or posterior non-infectious uveitis (NIU), which have severe systemic side effects and are not always effective^[5-6]. Cataract formation is a frequent complication in patients with uveitis caused by chronic inflammation and usage of steroids. Approximately 35% of uveitis patients develop cataract^[7]. Safe and effective surgery is necessary for these patients, but how to avoid the recurrence or aggravation of postoperative inflammation remains the most serious challenge for surgeons^[8].

Dexamethasone intravitreal implant (0.7 mg; Ozurdex, Allergan Inc, California, USA) is a biodegradable drug delivery system that has the capability of sustained release for

up to 26wk^[9]. Currently, Ozurdex is approved by the Food and Drug Administration (FDA) for treating noninfectious posterior uveitis. Several studies have demonstrated its efficacy, safety and tolerance in treating noninfectious uveitis^[10-15]. Based on previous studies, many scholars have continued to evaluate the anti-inflammatory effects and safety of Ozurdex in refractory uveitis, but studies in patients with refractory uveitis—who need to accept cataract surgery—are still rare^[13,16-19].

In this study, we evaluated the effectiveness of phacoemulsification and intraocular lens implantation combined with Ozurdex implantation for treating complicated cataracts in refractory uveitis patients.

SUBJECTS AND METHODS

Ethical Approval This single-center retrospective study was carried out in accordance with the tenets set forth by the Declaration of Helsinki. Approval for this study was obtained from the Ethics Review Committee of Tianjin Medical University Eye Hospital [No.2016KY(L)-08]. Written informed consents were obtained from all enrolled patients.

Study Design and Patient Enrollment Patients with refractory NIU who underwent phacoemulsification and intraocular lens implantation along with intraoperative intravitreal dexamethasone implant injection at the Tianjin Medical University Eye Hospital (China) between May 2018 and March 2019 were enrolled. All patients underwent conventional systemic immunosuppressive treatment and failed to achieve complete remission of inflammation. All patients received a detailed clinical examination to exclude risk factors for infection.

Treatment and Follow-up All patients underwent surgery and evaluation was performed by one skilled surgeon. Surgery was performed if cataract affected the patient's normal daily life. Before surgery, the ocular inflammation in all patients had been suppressed to their lowest grade [anterior chamber cell (ACC)=1+] and was maintained for at least 1mo. Intraocular inflammation was assessed according to the Standardization of Uveitis Nomenclature (SUN) Working Group grading schemes^[20]. All patients underwent cataract phacoemulsification through a 2.8 mm transparent corneal incision and a foldable hydrophobic intraocular lens was implanted. At the end of cataract surgery, all patients received a single intravitreal injection of 0.7 mg dexamethasone (Ozurdex) *via* the pars plana. If the intraocular inflammation was controlled, the amounts of oral steroids and immunosuppressants was slowly decreased at 1wk post operation.

Patients received a comprehensive ophthalmic examination at baseline and each follow-up visit. Ophthalmic examination data was collected at baseline and at 1, 3, and 6mo post operation. Ophthalmic examination included measurement and examination of best-corrected visual acuity (BCVA),

intraocular pressure (IOP), slit-lamp biomicroscopy, fundus, optical coherence tomography (OCT), and ultrasound B-scan.

Recurrences and Rescue Treatment Inflammation recurrences were defined as an increase in the ACC and/or vitreous haze (VH) by two or more grades when compared to the prior clinical examination. If recurrence of inflammation was found, topical steroids were firstly administrated, and oral steroids were added if the inflammation was still uncontrolled.

Outcome Measures Outcome measures included intraocular inflammation, BCVA, IOP, central retinal thickness (CRT), and prednisone dose-sparing. Any adverse postoperative ocular or systemic events were recorded.

Statistical Analysis BCVA was assessed using the Snellen chart value converted to the logarithm of the minimum angle of resolution (logMAR). Counting fingers was assigned a value of 1.6 logMAR, hand motion was assigned 2.0 logMAR, and no light perception was assigned a value of 3.0 logMAR^[21]. Continuous variables were expressed as means and standard deviations (SD) and non-continuous variables as medians. Statistical analysis was performed using SPSS statistical software version 21.0 (IBM). Wilcoxon signed-rank test and paired *t*-test were used to compare the changes in BCVA, IOP and CRT. *P* values of less than 0.05 were defined as statistically significant.

RESULTS

A total of seven patients with refractory uveitis (10 eyes, 57.1% are male) who underwent phacoemulsification and intraocular lens implantation combined with dexamethasone implant injection were included. Of these, three patients underwent bilateral surgeries with a minimum interval of one week. The mean age of these patients was 51.4±21.6y (range, 22-76y). The mean duration of postoperative follow-up was 10.4±1.2mo (range, 7.5-17mo). Demographic and clinical characteristics of the patients are shown in Table 1.

Visual Outcomes The mean BCVA was 1.14±0.67 logMAR at baseline. Compared to baseline, the BCVA showed significant improvement at 1, 3, and 6mo post operation (Table 2). There were no significant differences between each follow-up visit (*P*>0.05). Four of the ten eyes (40%) achieved 0.3 logMAR or better, and seven of the ten eyes (70%) achieved 0.5 logMAR or better.

Safety Analyses There were no intraoperative complications and no postoperative endophthalmitis, retinal detachment, implant migration or vitreous hemorrhage.

The mean IOP at baseline and each postoperative follow-up visit are presented in Table 3. No significant differences in baseline IOP were observed when compared to 1mo (*P*=0.46), 3mo (*P*=0.90), and 6mo (*P*=0.65) post operation. Only one patient developed transient elevated IOP post-injection which was well-controlled by topical anti-glaucoma medication. No patient required anti-glaucoma surgery.

Table 1 Demographic and clinical characteristics of patients

Patient/eye	Gender	Age ^a (y)	Diagnosis	Duration of systemic immunosuppressive treatment (mo)	Preop. grades of ACC ^b		Postop. grades of ACC ^c		Type of cataract
1 (bilateral)	F	76	VKH	2	OD: +	OS: +	OD: +	OS: ±	Nuclear
2 (bilateral)	M	22	VKH	22	OD: +	OS: +	OD: +	OS: ±	PSC
3 (OD)	M	24	Idiopathic panuveitis	7.5		+		+	PSC
4 (bilateral)	F	71	Idiopathic panuveitis	2.5	OD: +	OS: +	OD: +	OS: ±	Nuclear
5 (OD)	F	54	Sclerouveitis	17.5		+		+	Cortical
6 (OS)	M	65	Sympathetic ophthalmia	6		+		±	Cortical
7 (OD)	M	48	VKH	12.5		+		±	Nuclear

^aAge at Ozurdex implantation; ^bOne day pre-operation; ^cOne week post-operation. VKH: Vogt-Koyanagi-Harada syndrome; PSC: Posterior subcapsular.

Table 2 The mean BCVA at baseline and each postoperative follow-up visit

Parameters	Baseline	Postop. follow-up visit		
		1mo	3mo	6mo
BCVA (logMAR)	1.14±0.67	0.67±0.62	0.52±0.46	0.57±0.47
<i>P</i>		0.004	0.0004	0.001

Table 3 The mean IOP at baseline and each postoperative follow-up visit

Parameters	Baseline	Postop. follow-up visit		
		1mo	3mo	6mo
Mean IOP (mm Hg)	12.37±3.33	12.22±4.47	13.16±4.28	11.71±2.26
<i>P</i>		0.46	0.90	0.65

Two eyes (20%) developed posterior capsular opacifications, wherein both underwent neodymium-doped yttrium aluminum garnet (Nd:YAG) laser capsulotomy at 1 and 5mo post operation, respectively. Both eyes thoroughly restored BCVA after YAG treatment.

Central Retinal Thickness The mean±SD CRT was 312.10±172.65 μm at 1mo, 306.60±110.66 μm at 3mo, and 334.30±187.62 μm at 6mo post operation. There were no statistically significant differences among three follow-up groups (*P*>0.05).

Steroid and Immunosuppressant Dose-sparing Table 4 shows the use of systemic steroids and immunosuppressants at baseline and postoperatively. The amounts of systemic steroids and immunosuppressants taken by all patients was decreased at 6mo post operation. Six patients (8 eyes) had reduced the amount of systemic prednisone usage to below 10 mg/d. Three patients (5 eyes) stopped systemic steroid therapy.

Recurrences The patients experienced a mean of 1.4±0.52 recurrences of inflammation in the 6mo before operation and decreased to 0.7±0.48 in the 6mo post operation. Five of seven patients (7 out of 10 eyes) developed inflammation relapse postoperatively. The mean recurrence time was 13±0.58wk (range, 12-14wk). To prevent recurrence, two patients (3 eyes) accepted preventive topical corticosteroid therapy at 12wk and showed no relapse. Only one patient (2 eyes) needed increased

amount of oral corticosteroids, and intraocular inflammation recurrence in the remaining patients was controlled by topical steroids.

Sample Case Report A 24-year-old male patient presented with a 2-year history of right eye recurrent pain and redness with progressive vision loss. Before visiting our clinic, the patient had received steroid pulse and oral steroid therapy for more than one year, followed by 6mo of no treatment. Due to relapse, he had been initially given 70 mg of prednisone per day and topical steroid for 20d before coming to our clinic for further treatment.

On presentation, his BCVA was 1.7 (logMAR) in the right eye and 0.1 (logMAR) in the left eye. The ACC grade of the right eye was 1+. The iris of the right eye presented both anterior and posterior synechia (Figure 1A). The right lens was cloudy under the posterior capsule, and the fundus could not be seen. B ultrasound showed severe opacity of the vitreous. There were no other abnormal findings in the left eye. No other system-related diseases or immune test abnormalities were found. Based on the above, he was diagnosed with right eye noninfectious idiopathic panuveitis and started on oral prednisone combined with cyclosporin A (CSA). During the treatment, the patient's transaminase increased, and he stopped drug adherence for more than ten days. After that, his right eye inflammation relapsed again with ACC increasing to 3+. We then treated the patient with prednisone plus hepatoprotective medication. After 3mo of treatment, the patient's ACC was maintained at 1+. Considering that cataract severely affects the patient's daily life and poor liver function, we performed phacoemulsification and intraocular lens implantation. At the end of surgery, we administered intravitreal injection of Ozurdex. One week post operation, his right eye BCVA improved from 1.7 (logMAR) to 0.6 (logMAR). The intraocular inflammation did not relapse, and the ACC was 1+ (Figure 1B). Then, the dose of oral steroids and CSA were slowly decreased.

A recurrence of inflammation was found, and BCVA decreased to 1 (logMAR) at 13wk post operation. The OCT results

Table 4 Treatment at baseline and 6mo postoperatively

Patient	Treatment	
	Baseline	6mo postop.
1	Prednisone 30 mg/d, topical steroids	Topical steroids
2	Prednisone 40 mg/d, CSA 175 mg/d, MTX 15 mg/w, topical steroids	Prednisone 15 mg/d, CSA 125mg/d, topical steroids
3	Prednisone 20 mg/d, CSA 100 mg/d, topical steroids	Prednisone 7.5 mg/d, topical steroids
4	Prednisone 30 mg/d, topical steroids	Topical steroids
5	Prednisone 20 mg/d, MTX 7.5 mg/w, topical steroids	Topical steroids
6	Prednisone 30 mg/d, CSA 150 mg/d, topical steroids	Prednisone 7.5 mg/d, CSA 50 mg/d, topical steroids
7	Prednisone 15 mg/d, MMF 1000 mg/d, topical steroids	Prednisone 2.5 mg/d, MMF 500 mg/d, topical steroids

MMF: Mycophenolate mofetil; MTX: Methotrexate; CSA: Cyclosporine A.

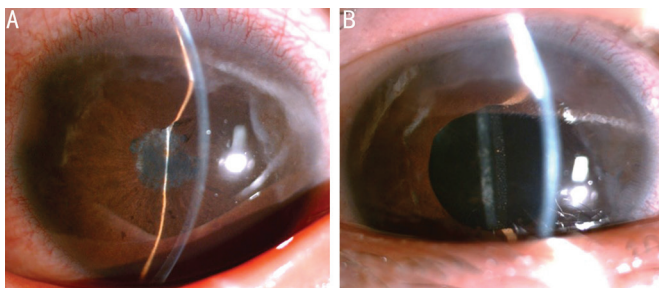


Figure 1 Anterior segment photography of right eye A: Baseline; B: 1wk post operation.

showed aggravated cystoid macular edema (CME). The patient received prednisolone acetate eye drops six times per day and tapered very slowly without increasing the dose of oral drugs. The intraocular inflammation was suppressed, and there were no other recurrences within 6mo post operation. The BCVA in the right eye gradually recovered to 0.6 (logMAR). Similar findings were also observed in CME (Figure 2).

DISCUSSION

Cataract surgery is challenging in uveitic eyes due to potential postoperative complications such as severe inflammation and macular edema^[8,22-23]. To our knowledge, this is the first study to evaluate the effect of intravitreal dexamethasone implant in controlling postoperative inflammation in refractory uveitis with active inflammation. Our results showed that in refractory cases of uveitis, Ozurdex implantation administered at the end of cataract operation is a safe and effective method to protect against aggravation of inflammation.

With modern cataract surgical techniques, improved understanding of the disease process and optimized immunosuppressive therapy for control of inflammation, postoperative complications of cataract surgery in uveitic eyes has been minimized in the past decades. To achieve favorable outcomes, most surgeons recommend that intraocular inflammation should be quiescent for at least 3mo before cataract surgery^[8,11,24-25]. However, in some refractory cases, the inflammation may be hard to control even with long-term high doses of immunosuppressive therapy, and the usage of systemic steroids and immunosuppressants may be limited due to side effects in patients with poor systemic conditions.

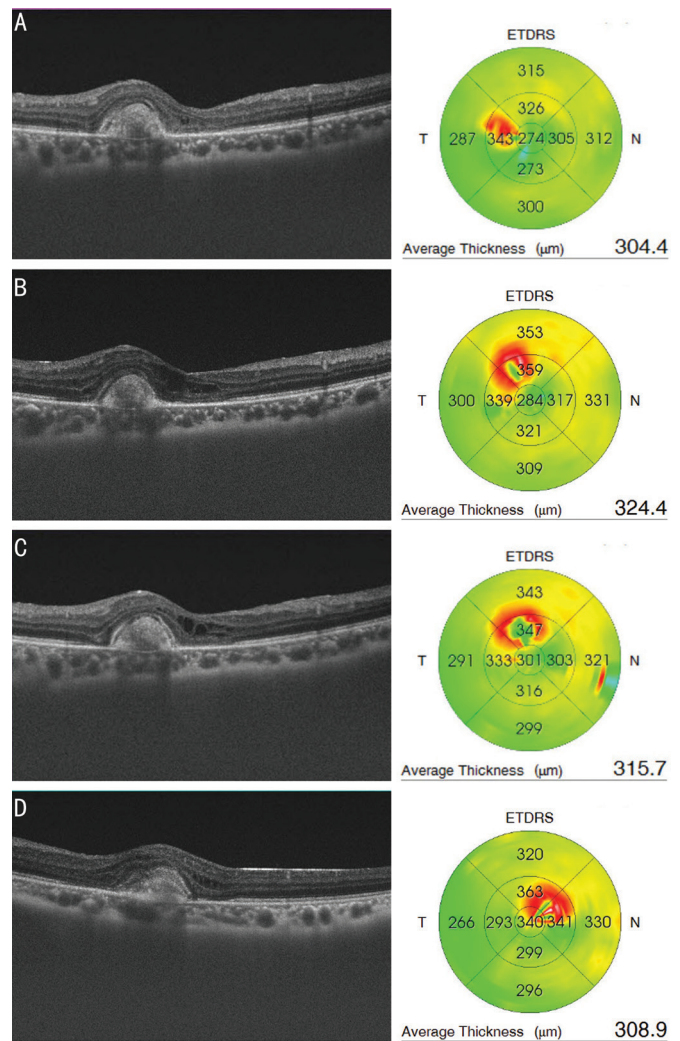


Figure 2 OCT picture of right eye at each visit A: 1wk post operation; B: 13wk post operation; C: 5mo post operation; D: 6mo post operation.

Therefore, for these patients at high risk of inflammation recurrence or aggravation, intensive local steroid prophylaxis is necessary during the postoperative period of cataract surgery. Conventionally, if there are no contraindications to local steroid application, periocular or intraocular injection of steroids, such as triamcinolone acetonide (TA), may be given for uveitic patients accepting cataract surgery. Results from the literature support that an intravitreal injection of 4 mg of TA at the conclusion of cataract surgery improves the outcome of

the operation^[26]. Compared to TA, intravitreal dexamethasone implant is safer regarding the side effect of IOP elevation^[27]. Several recent studies also confirmed the favorable effect of intraoperative dexamethasone implant in preventing postoperative inflammation in uveitic cataract^[28-30]. In patients with quiescent uveitis for at least 3mo before the surgery, Gupta *et al*^[29] demonstrated that intravitreal dexamethasone implant was effective in managing the postoperative inflammation and showed advantages over traditional immunosuppressive methods with better visual outcomes and fewer complications. Meanwhile, our study showed that in patients whose ocular inflammation could not be completely controlled, intravitreal dexamethasone implant was effective to minimize postoperative inflammation.

Our results showed that Ozurdex can reduce the mean number of recurrences post operation when compared to preoperative status. Most of the patients in our study showed relapse at around 14wk after surgery. We believed that this was due to a reduction in systemic anti-inflammatory medications and a sharp drop in the intraocular concentration of dexamethasone. The pharmacokinetic results of Ozurdex showed that the concentration of dexamethasone in the retina remained high during the first 2mo after injection, followed by a sharp drop, and only a very low concentration was maintained at 3mo^[31]. Therefore, it is imperative to closely monitor the recurrence of inflammation during this period of time and provide timely medication to avoid further aggravation of inflammation. By considering the consistency of the recurrence time, we presume that the use of prophylactic topical steroids before 3mo post operation reduces the recurrence in patients. Interestingly, two patients in our study had prophylactic topical steroids at 12wk after surgery, and they did not show any relapse. More research should be conducted on this in the future. Another interesting point was that after the relapse of the disease, most of the patients did not need any increased systemic medication. The use of topical steroids could control inflammation, but this was not effective before cataract surgery. Anderson has reported that after topical application of non-steroidal anti-inflammatory drugs (NSAIDs), higher drug concentration was found in aphakic rabbit eyes than those with normal eyes^[32]. Despite the lack of direct evidence, we hypothesized higher vitreous-retina drug concentration could be achieved with topical steroid therapy in aphakic patients.

Macular edema is one of the most common causes of low vision in patients with uveitis who have undergone cataract surgery. Dexamethasone implants have been reported to be effective against refractory macular edema with posterior uveitis^[16]. Gupta *et al*^[29] have demonstrated that Ozurdex reduces the probability of postoperative CME in patients with uveitis. In our study, there were no statistically significant

difference in the postoperative CRT among follow-up groups. Although ocular hypertension is considered to be one of the main side effects of Ozurdex implant, the degree of IOP increase is generally mild and easy to control^[33-35]. In our study, the IOP in only one eye showed slight elevation and was well-controlled by topical anti-glaucoma medications. Two eyes (20%) in our study developed posterior capsular opacifications. Both were managed by Nd:YAG laser capsulotomy at 1 and 5mo post operation, respectively, and thoroughly restored BCVA. No other ocular/systemic side-effects occurred during our study. In conclusion, Ozurdex is safe and effective in controlling postoperative inflammation in cataract surgery for uveitic eyes with active inflammation in our study. The inflammation reoccurred about 3mo after surgery and could be controlled by using topical steroids in most cases. The limitation of our study was the inclusion of a small case series, and a study with larger cohorts of patients and longer follow-up period is required to further confirm these results in the future.

ACKNOWLEDGEMENTS

Foundations: Supported by National Natural Science Foundation of China (No.81870651; No.81671642).

Conflicts of Interest: Li YT, None; Cui XX, None; Yang XT, None; Li B, None; Ren XJ, None; Li XR, None; Zhang XM, None.

REFERENCES

- 1 Krishna U, Ajanaku D, Denniston AK, Gkika T. Uveitis: a sight-threatening disease which can impact all systems. *Postgrad Med J* 2017;93(1106):766-773.
- 2 Suttorp-Schulten MS, Rothova A. The possible impact of uveitis in blindness: a literature survey. *Br J Ophthalmol* 1996;80(9):844-848.
- 3 Fabiani C, Vitale A, Orlando I, Capozzoli M, Fusco F, Rana F, Franceschini R, Sota J, Frediani B, Galeazzi M, Marco Tosi G, Cantarini L. Impact of uveitis on quality of life: a prospective study from a tertiary referral rheumatology-ophthalmology collaborative uveitis center in Italy. *Isr Med Assoc J* 2017;19(8):478-483.
- 4 de Smet MD, Taylor SR, Bodaghi B, Miserochchi E, Murray PI, Pleyer U, Zierhut M, Barisani-Asenbauer T, LeHoang P, Lightman S. Understanding uveitis: the impact of research on visual outcomes. *Prog Retin Eye Res* 2011;30(6):452-470.
- 5 Mikhail M, Sallam A. Novel intraocular therapy in non-infectious uveitis of the posterior segment of the eye. *Med Hypothesis Discov Innov Ophthalmol* 2013;2(4):113-120.
- 6 Tugal-Tutkun I, Onal S, Altan-Yaycioglu R, Huseyin Altunbas H, Urgancioglu M. Uveitis in Behçet disease: an analysis of 880 patients. *Am J Ophthalmol* 2004;138(3):373-380.
- 7 Jones NP. The Manchester uveitis clinic: the first 3000 patients, 2: uveitis manifestations, complications, medical and surgical management. *Ocul Immunol Inflamm* 2015;23(2):127-134.
- 8 Harapriya A, Anthony E. Managing cataract surgery in patients with uveitis. *Community Eye Health* 2019;31(104):82-83.

- 9 Chang-Lin JE, Burke JA, Peng Q, Lin T, Orilla WC, Ghosn CR, Zhang KM, Kuppermann BD, Robinson MR, Whitcup SM, Welty DF. Pharmacokinetics of a sustained-release dexamethasone intravitreal implant in vitrectomized and nonvitrectomized eyes. *Invest Ophthalmol Vis Sci* 2011;52(7):4605-4609.
- 10 Alba-Linero C, Sala-Puigdollers A, Romero B, Llorenç V, Adan A, Zarranz-Ventura J. Long-term intravitreal dexamethasone implant outcomes in uveitis. *Ocul Immunol Inflamm* 2020;28(2):228-237.
- 11 Zarranz-Ventura J, Sala-Puigdollers A, Velazquez-Villoria D, Figueras-Roca M, Copete S, Distefano L, Boixadera A, García-Arumi J, Adan A, Hospital Clínic—Hospital Vall de Hebron Intravitreal Dexamethasone Implant study group. Long-term probability of intraocular pressure elevation with the intravitreal dexamethasone implant in the real-world. *PLoS One* 2019;14(1):e0209997.
- 12 Zarranz-Ventura J, Carreño E, Johnston RL, Mohammed Q, Ross AH, Barker C, Fonollosa A, Artaraz J, Pelegrin L, Adan A, Lee RW, Dick AD, Sallam A. Multicenter study of intravitreal dexamethasone implant in noninfectious uveitis: indications, outcomes, and reinjection frequency. *Am J Ophthalmol* 2014;158(6):1136-1145.e5.
- 13 Ratra D, Barh A, Banerjee M, Ratra V, Biswas J. Safety and efficacy of intravitreal dexamethasone implant for refractory uveitic macular edema in adults and children. *Ocul Immunol Inflamm* 2018;26(7):1034-1040.
- 14 Coşkun E, Celemler P, Kimyon G, Öner V, Kisacik B, Erbagci I, Onat AM. Intravitreal dexamethasone implant for treatment of refractory behçet posterior uveitis: one-year follow-up results. *Ocul Immunol Inflamm* 2015;23(6):437-443.
- 15 Rajesh B, Zarranz-Ventura J, Fung AT, Busch C, Sahoo NK, Rodriguez-Valdes PJ, Sarao V, Mishra SK, Saatci AO, Udaondo Mirete P, Querques G, Farah ME, Lanzetta P, Arevalo JF, Kodjikian L, Chhablani J, for International Ozurdex Study Group. Safety of 6000 intravitreal dexamethasone implants. *Br J Ophthalmol* 2020;104(1):39-46.
- 16 Teja S, Sawatzky L, Wiens T, Maberley D, Ma P. Ozurdex for refractory macular edema secondary to diabetes, vein occlusion, uveitis and pseudophakia. *Can J Ophthalmol* 2019;54(5):540-547.
- 17 Pohlmann D, Winterhalter S, Pleyer U. Intravitreal dexamethasone for the treatment of CMO associated with refractory sclerouveitis. *Ocul Immunol Inflamm* 2018;26(1):160-165.
- 18 Pang JP, Son G, Yoon YH, Kim JG, Lee JY. Combined vitrectomy with intravitreal dexamethasone implant for refractory macular edema secondary to diabetic retinopathy, retinal vein occlusion, and noninfectious posterior uveitis. *Retina* 2020;40(1):56-65.
- 19 Fabiani C, Emmi G, Lopalco G, Vannozzi L, Bacherini D, Guerriero S, Franceschini R, Frediani B, Iannone F, Marco Tosi G, Rigante D, Cantarini L. Intravitreal dexamethasone implant as an adjunct weapon for severe and refractory uveitis in behçet's disease. *Isr Med Assoc J* 2017;19(7):415-419.
- 20 Jabs DA, Nussenblatt RB, Rosenbaum JT, Standardization of Uveitis Nomenclature (SUN) Working Group. Standardization of uveitis nomenclature for reporting clinical data. Results of the First International Workshop. *Am J Ophthalmol* 2005;140(3):509-516.
- 21 Arroyo JG, Postel EA, Stone T, McCuen BW, Egan KM. A matched study of primary scleral buckle placement during repair of posterior segment open globe injuries. *Br J Ophthalmol* 2003;87(1):75-78.
- 22 Ozates S, Berker N, Cakar Ozdal P, Ozdamar Erol Y. Phacoemulsification in patients with uveitis: long-term outcomes. *BMC Ophthalmol* 2020;20(1):109.
- 23 Llop SM, Papaliodis GN. Cataract surgery complications in uveitis patients: a review article. *Semin Ophthalmol* 2018;33(1):64-69.
- 24 Alfawaz A, Alrashidi S, Kalantan H, Al-Mezaine H, Abu AM. Cataract surgery under systemic infliximab therapy in patients with refractory uveitis associated with Behçet disease. *Ann Saudi Med* 2014;34(4):328-333.
- 25 Baheti U, Siddique SS, Foster CS. Cataract surgery in patients with history of uveitis. *Saudi J Ophthalmol* 2012;26(1):55-60.
- 26 Roesel M, Tappeiner C, Heinz C, Koch JM, Heiligenhaus A. Comparison between intravitreal and orbital floor triamcinolone acetonide after phacoemulsification in patients with endogenous uveitis. *Am J Ophthalmol* 2009;147(3):406-412.
- 27 Mishra SK, Gupta A, Patyal S, Kumar S, Raji K, Singh A, Sharma V. Intravitreal dexamethasone implant versus triamcinolone acetonide for macular oedema of central retinal vein occlusion: quantifying efficacy and safety. *Int J Retina Vitreous* 2018;4:13.
- 28 Gupta A, Ram J, Gupta A, Gupta V. Intraoperative dexamethasone implant in uveitis patients with cataract undergoing phacoemulsification. *Ocul Immunol Inflamm* 2013;21(6):462-467.
- 29 Gupta G, Ram J, Gupta V, Singh R, Bansal R, Gupta PC, Gupta A. Efficacy of intravitreal dexamethasone implant in patients of uveitis undergoing cataract surgery. *Ocul Immunol Inflamm* 2019;27(8):1330-1338.
- 30 Sze AM, Luk FO, Yip TP, Lee GK, Chan CK. Use of intravitreal dexamethasone implant in patients with cataract and macular edema undergoing phacoemulsification. *Eur J Ophthalmol* 2015;25(2):168-172.
- 31 Chang-Lin JE, Attar M, Acheampong AA, Robinson MR, Whitcup SM, Kuppermann BD, Welty D. Pharmacokinetics and pharmacodynamics of a sustained-release dexamethasone intravitreal implant. *Invest Ophthalmol Vis Sci* 2011;52(1):80-86.
- 32 Anderson JA, Chen CC, Vita JB, Shackleton M. Disposition of topical flurbiprofen in normal and aphakic rabbit eyes. *Arch Ophthalmol* 1982;100(4):642-645.
- 33 Bahadorani S, Krambeer C, Wannamaker K, Tie W, Jansen M, Espitia J, Sohn JH, Singer MA. The effects of repeated Ozurdex injections on ocular hypertension. *Clin Ophthalmol* 2018;12:639-642.
- 34 Fassbender Adeniran JM, Jusufbegovic D, Schaal S. Common and rare ocular side-effects of the dexamethasone implant. *Ocul Immunol Inflamm* 2017;25(6):834-840.
- 35 Malclès A, Dot C, Voirin N, Vié AL, Agard É, Bellocq D, Denis P, Kodjikian L. Safety of intravitreal dexamethasone implant (Ozurdex): the SAFODEX study. incidence and risk factors of ocular hypertension. *Retina* 2017;37(7):1352-1359.