

# Acute corneal graft rejection following photorefractive keratectomy for post-penetrating keratoplasty high astigmatism

Leopoldo Spadea, Maria Ilaria Giannico, Marta Armentano, Ludovico Alisi, Santino Pistella

Department of Sense Organs, Eye Clinic, University “La Sapienza”, Rome 00185, Italy

**Correspondence to:** Leopoldo Spadea. Head Eye Clinic, Policlinico Umberto I, “Sapienza” University of Rome Via Benozzo Gozzoli 34, Rome 00142, Italy. leopoldo.spadea@uniroma1.it

Received: 2020-04-26 Accepted: 2020-07-02

**DOI:10.18240/ijo.2021.03.24**

**Citation:** Spadea L, Giannico MI, Armentano M, Alisi L, Pistella S. Acute corneal graft rejection following photorefractive keratectomy for post-penetrating keratoplasty high astigmatism. *Int J Ophthalmol* 2021;14(3):476-477

## Dear Editor,

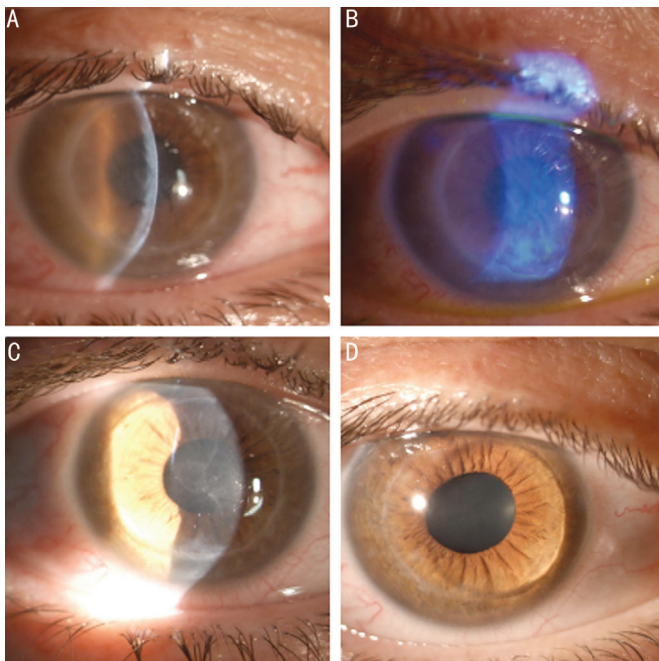
We present an unusual case of acute graft rejection after photorefractive keratectomy (PRK), performed to correct high residual astigmatism after penetrating keratoplasty (PKP) for keratoconus. The primary measures of success for PKP are visual acuity, refractive outcomes, and graft survival. These measures reflect the two major post-operative PKP-related complications: debilitating astigmatism and graft rejection<sup>[1]</sup>. PRK showed good refractive outcomes in the treatment of post-PKP myopia and astigmatism<sup>[2]</sup>. The description of corneal graft rejection after PRK in literature is limited to a small number of short series<sup>[2-3]</sup>.

In September 2019, a 46-years-old woman came to our eye clinic complaining of unsatisfactory vision in the right eye for high myopic astigmatism. She underwent bilateral PKP for advanced keratoconus, in the right eye in 1997 and in the left eye in 1999. The patient was intolerant to contact lens and binocular vision was not adequately corrected with spectacles. The patient was not taking any systemic or local therapy. Corneal grafts in both eyes were clear at the time of examination. Uncorrected distance visual acuity (UDVA) was 20/400 and 20/200 and corrected distance visual acuity (CDVA) was 20/32 (-1.50/-11×110) and 20/20 (-0.50/-5×145) in right and left eyes, respectively. The refractive error was stable for the past 5mo and there was no sign of keratoconus recurrence.

In the right eye the topographic corneal astigmatism was 12.09 D×35 and the central corneal thickness was 498 μm. Her specular microscopy showed an endothelial cell density of 1460 cells/mm<sup>2</sup> and 1380 cells/mm<sup>2</sup> in right and left eyes, respectively. Five days before the PRK the patient was prescribed with prednisolone 15 mg daily and lansoprazole 30 mg daily.

Informed consent was signed by the patient and a one-step customized trans-epithelial no-touch treatment was executed in the right eye using iRes excimer laser (iVIS Technology, Taranto, Italy). The study was conducted in accordance with the Declaration of Helsinki. The targeted refractive zone was set to 2.74 mm with a large transition zone up to 9.19 mm. The maximum depth ablation was 121 μm. Approximately halfway during the laser procedure, the procedure was stopped due to an internal safety check, and it was necessary to repeat the laser calibration. This procedure approximately took 7min. This unexpected event had never happened before. During the break, the speculum was removed and a bandage was applied. Then the corneal surface was gently dried with a sterile sponge until a homogeneous dry surface was achieved. The laser ablation was finally completed, restarting exactly from the point where it was stopped. At the end of the laser procedure, the cornea was clear, and a bandage contact lens and local therapy were applied. Postoperative treatment included 15 mg of oral prednisone per day, ofloxacin eye drops 3 times a day and artificial tears 6 times a day.

The patient was examined on each day. The corneal healing during the first four days was regular but five days after surgery the patient complained tearing, foreign body sensation and blurred vision. The corneal graft showed diffuse edema, deep folds of the Descemet layer and some endothelial cellular precipitates (Figure 1A) The corneal re-epithelialization was not complete in a 1.5 mm inferior area (Figure 1B). The detected clinical features were compatible with the diagnosis of immune corneal graft rejection as highlighted by corneal edema and keratic precipitates on the donor cornea but not on the recipient. Immediately, 4 mg of dexamethasone were administered through subtenon injection and the oral steroid dose was increased to 25 mg per day, dexamethasone 2 mg/mL eye



**Figure 1** Slit-lamp images of corneal graft after PRK A, B: 5d after PRK: diffuse corneal edema and Descemet deep folds affect the graft for acute immune rejection are visible. Blue light filter highlights a not complete re-epithelialization in a 1.5 mm inferior area of the graft. C, D: 2wk and 3mo after PRK, respectively; graft rejection is resolved, and it appears clear.

drops 6 times a day were prescribed, and antibiotic topical therapy was continued for two weeks postoperatively. Three days later corneal transparency progressively improved. Two weeks after surgery the edema was completely resolved, the cornea appeared clear, and the bandage contact lens was removed. Antibiotic topical therapy was discontinued and 0.1% fluorometholone eye drops 3 times a day were started until the last follow-up (Figure 1C).

The graft remained clear during the 3mo of follow-up (Figure 1D). The final topographic corneal astigmatism was significantly reduced (6.0 D $\times$ 40), the central corneal thickness was 387  $\mu$ m and the endothelial cell count at 3mo was 1350 cells/mm<sup>2</sup>. The UDVA was 20/32 and the CDVA 20/25 (-1/+2 $\times$ 50). The patient reported a significant improvement in her quality of life, and she was consistently satisfied with the visual outcome.

Allograft corneal rejection represents the most feared complication after PKP. It occurs when the recipient's immune system recognizes the grafted tissue as "not-self".

This complex mechanism can be activated by inflammatory trigger conditions like suture removal or mechanical trauma secondary to the laser surgery laser treatment<sup>[1]</sup>. Bilgihan *et al*<sup>[2]</sup> previously described two endothelial graft rejection episodes after PRK 5mo and 10d postoperatively. PRK was performed between 17mo and 9y after the PKP and at least 5mo after the sutures' removal. Sorkin *et al*<sup>[3]</sup> reported a single case of endothelial graft rejection 20mo following wavefront-guided PRK for high astigmatism. In this paper no patient underwent ocular surgery in the 3mo before PRK, and all the subjects had their sutures removed at least 6mo before PRK.

To the best of our knowledge, this is the first case report of acute immune graft rejection occurring only a few days after an accidental interrupted PRK procedure, but quickly resolved without clinical sequelae. Even if reported for sake of completeness we do not know if the interruption of the laser ablation and the subsequent longer surgical time may be correlate with the acute immune graft rejection.

Although being reported as an effective procedure to correct residual high astigmatism post-PKP, surgeons should be aware of possible rare complications of PRK. In fact, after PRK, the risk of corneal graft rejection may be increased, especially in presence of intra or postoperative complications. Patients should be warned of this rare but possible postoperative complication. It is mandatory after laser refractive procedure to follow the PKP patients closely to promptly recognize and treat any sign of acute immune rejection. Earlier the treatment, greater are the chances of success.

#### ACKNOWLEDGEMENTS

**Conflicts of Interest:** Spadea L, None; Giannico MI, None; Armentano M, None; Alisi L, None; Pistella S, None.

#### REFERENCES

- 1 Rahman I, Carley F, Hillarby C, Brahma A, Tullo AB. Penetrating keratoplasty: indications, outcomes, and complications. *Eye (Lond)* 2009;23(6):1288-1294.
- 2 Bilgihan K, Özdek ŞC, Akata F, Hasanreisoglu B. Photorefractive keratectomy for post-penetrating keratoplasty myopia and astigmatism. *J Cataract Refract Surg* 2000;26(11):1590-1595.
- 3 Sorkin N, Kreimei M, Einan-Lifshitz A, Mednick Z, Belkin A, Chan CC, Slomovic AR, Rootman DS. Wavefront-guided photorefractive keratectomy in the treatment of high astigmatism following keratoplasty. *Cornea* 2019;38(3):285-289.