

# Comprehensive evaluation of intravitreal conbercept versus half-dose photodynamic therapy for chronic central serous chorioretinopathy

Jian-Bo Mao<sup>1</sup>, Cai-Yun Zhang<sup>1</sup>, Chen-Yi Liu<sup>2</sup>, Yun Zhang<sup>1</sup>, Jing-Jing Lin<sup>1</sup>, Zhao-Kai Xu<sup>1</sup>, Yi-Qi Chen<sup>1</sup>, Yuan-Yuan Fan<sup>1</sup>, Shi-Xin Zhao<sup>1</sup>, Li-Jun Shen<sup>1</sup>

<sup>1</sup>Eye Hospital and School of Ophthalmology and Optometry, Wenzhou Medical University, Wenzhou 325027, Zhejiang Province, China

<sup>2</sup>Chicago College of Optometry, Midwestern University, Downers Grove, IL 60515, USA

**Co-first authors:** Jian-Bo Mao, Cai-Yun Zhang, and Chen-Yi Liu

**Correspondence to:** Li-Jun Shen. Eye Hospital and School of Ophthalmology and Optometry, Wenzhou Medical University, 270 Xueyuan West Road, Wenzhou 325027, Zhejiang Province, China. slj@mail.eye.ac.cn

Received: 2020-07-18 Accepted: 2020-11-23

## Abstract

• **AIM:** To compare the safety and efficacy of conbercept intravitreal injection and half-dose photodynamic therapy (PDT) in treating chronic central serous chorioretinopathy (CSC).

• **METHODS:** This study was retrospective. Thirty-seven patients (37 eyes) with chronic CSC received conbercept injections while 57 patients (57 eyes) were treated with half-dose PDT. All subjects were followed in 6mo. Outcome measures included change in best-corrected visual acuity (BCVA), central macular thickness (CMT), subfoveal choroidal thickness (SFCT), and resolution of subretinal fluid (SRF).

• **RESULTS:** There was no adverse event observed in either treatment group. At the 6-month follow-up, 26 eyes (70.3%) in the conbercept group and 54 eyes (94.7%) in the half-dose PDT group ( $P<0.05$ ) reached full resolution of SRF. The mean logarithm of the minimum angle of resolution (logMAR) BCVA significantly improved ( $P<0.001$ ) in both treatment groups with better outcome at early phase in the half-dose PDT group (2wk, 1, and 2mo,  $P<0.05$ ). All subjects experienced significant CMT improvement ( $P<0.001$ ) with no statistical difference between the two groups ( $P>0.05$ ). The SFCT also improved in all subjects ( $P<0.001$ ) with better outcome in the half-dose PDT group ( $P<0.05$ ).

• **CONCLUSION:** Both intravitreal conbercept and half-dose PDT are safe to use in treating chronic CSC. By 6mo,

both treatment groups are efficacious in improving BCVA, reducing CMT and SFCT, and resolving SRF in eyes with chronic CSC. Half-dose PDT may show better outcome at initial phase of treatment in chronic CSC. Longer follow-up period is necessary to study for long-term effect and safety.

• **KEYWORDS:** central serous chorioretinopathy; conbercept; photodynamic therapy; subfoveal choroidal thickness

**DOI:10.18240/ijo.2021.05.12**

**Citation:** Mao JB, Zhang CY, Liu CY, Zhang Y, Lin JJ, Xu ZK, Chen YQ, Fan YY, Zhao SX, Shen LJ. Comprehensive evaluation of intravitreal conbercept versus half-dose photodynamic therapy for chronic central serous chorioretinopathy. *Int J Ophthalmol* 2021;14(5):719-724

## INTRODUCTION

Central serous chorioretinopathy (CSC) is a self-limiting condition characterized by localized serous detachment of the neurosensory retina as a result of hyperpermeability of the choroidal vasculature. Typical changes in the retinal pigment epithelium (RPE) can be also present<sup>[1-3]</sup>. In some refractory cases, treatment may be warranted to subside progression or fasten recovery. Photodynamic therapy (PDT), laser photocoagulation, subthreshold micropulse laser, intravitreal anti-vascular endothelial growth factor (VEGF) and antagonists of mineralocorticoid receptors and glucocorticoid receptors may be applied in treating this disease<sup>[3]</sup>.

Numerous studies have shown positive therapeutic effect of PDT in treating chronic CSC<sup>[4-6]</sup>. With PDT, a rapid resolution of subretinal fluid (SRF) and reduction in subfoveal choroidal thickness (SFCT) can be achieved by reducing choroidal exudation and choriocapillaris blood flow. Later, some complications have been recognized with the use of full-dose PDT such as choroidal capillary nonperfusion, secondary choroidal neovascularization and RPE atrophy<sup>[5]</sup>. It was then proposed that PDT parameters could be modified in half-dose or half-fluence PDT to improve safety while maintaining its therapeutic effectiveness<sup>[7]</sup>.

Intravitreal VEGF is the other treatment option for chronic CSC, owing to its anti-permeability properties<sup>[8-10]</sup>. The safety and efficacy of intravitreal bevacizumab and PDT has been studied and compared in several studies. Varying conclusions have been drawn. Semeraro *et al*<sup>[11]</sup> indicated no significant difference in the therapeutic effect between the two over a 9-month follow-up period. Bae *et al*<sup>[12]</sup>, on the other hand, reported on an overall superiority in low-fluence PDT. Unlike monoclonal antibodies, conbercept is a recombinant protein which composed of VEGF receptor-1 and receptor-2 with the Fc segment of human immunoglobulin G1. It has been demonstrated effective in treating wet age-related macular degeneration, choroidal neovascularization and macular edema but not fully investigated in CSC<sup>[13]</sup>. The preliminary results in our prior research has shown potential therapeutic effects of conbercept in treating chronic CSC<sup>[14]</sup>. This study aimed to explore the safety and efficacy of conbercept in treating chronic CSC with the comparison to half-dose PDT in a period of 6mo.

## SUBJECTS AND METHODS

**Ethical Approval** This study was conducted following the principles of the Declaration of Helsinki and got approval by the Ethics Committee at the Eye Hospital of Wenzhou Medical University (No.2019-030-K-29). Informed consent was obtained from all subjects.

**Subjects** The clinical data of chronic CSC patients who received intravitreal conbercept and half-dose PDT from January 2015 to August 2018 was retrospectively reviewed and enrolled following the criteria measures. Inclusion criteria included: 1) Male or non-pregnant women aged over 18; 2) Presence of symptoms for longer than 6mo; 3) Presence of subfoveal SRF on optical coherence tomography (OCT; Spectralis, Heidelberg, Germany); 4) Presence of characteristics of chronic CSC on fundus fluorescein angiography (FFA) and indocyanine green angiography (ICGA): diffuse fluorescent leakage with dilation of the choriocapillaris; 5) Follow-up for at least 6mo post treatment. Exclusion criteria included presence of: 1) Detection of choroidal neovascularization at first or follow-up visit by FFA and ICGA; 2) Other concomitant diseases like age-related macular degeneration, polypoidal choroidal vasculopathy or serious systemic disease; 3) History of interventional treatment such as usage of other anti-VEGF agent, laser photocoagulation or ocular surgery; 4) Previous treatment of steroid before the onset of symptoms. If chronic CSC patients meet these criteria with binocular involvement, the eye with poorer vision was selected in this study.

**Treatment** Subjects were grouped based on the treatment methods. In the half-dose PDT group, patients were treated with half-dose verteporfin infusion ( $3 \text{ mg/m}^2$ ) over 10min following light application with a dose of  $50 \text{ J/cm}^2$  (83s) on

hyper-permeable lesion captured on FFA and ICGA with an extra  $500 \mu\text{m}$  in diameter. In the conbercept group,  $0.5 \text{ mg}/0.05 \text{ mL}$  of conbercept was injected into the vitreous cavity in a sterile operation room. This group was treated following the “1+*pro re nata* (1+PRN)” treatment regimens. Thus, reinjection could be administered as needed after initially injection. Reinjection of conbercept was performed based on the following criteria: 1) best-corrected visual acuity (BCVA) loss of 0.2 logarithm of the minimum angle of resolution (logMAR) or more; 2) persistence of SRF one month after the last injection<sup>[12,15]</sup>. And half-dose PDT was not repeated within six months considering its action time. If SRF persisted six months after the initial treatment, or signs of aggravation were present, the opposite treatment modality can be applied for ethical considerations. That is, half-dose PDT was available for the conbercept group, conbercept injection for the half-dose PDT group.

**Outcome Measures and Follow-up Visits** At each visit, a comprehensive ocular exam was conducted which included visual acuity testing, refraction, anterior segment examination, intraocular pressure measurements, dilated fundus exam, enhanced depth imaging-OCT (EDI-OCT). The patients were followed up at 2wk, 1, 2, 3 and 6mo after treatment, and then every 3 to 6mo once the condition has become stable. Any ocular or systemic complications were documented. Changes in BCVA, central macular thickness (CMT), SFCT and SRF were collected and analyzed. The BCVA was expressed in the mean logMAR. CMT was measured from the RPE to the inner limiting membrane (ILM). SFCT was measured from the RPE to the inner surface of sclera at the fovea. All measurements represented the average of three replicates completed by a trained ophthalmologist (Mao JB).

**Statistical Analysis** Statistical analysis were carried out using SPSS Statistics software version 19.0 (SPSS, Inc., Chicago, IL, USA). Continuous data were described by means±standard deviations. The comparison of outcome measures was conducted by repeated measures analysis of variance. Categorical variables were analyzed with Chi-squared test, and continuous variables were compared by independent sample *t*-test and one-way analysis of variance. A  $P < 0.05$  was considered statistically significant.

## RESULTS

Ninety-four eyes in ninety-four patients with chronic CSC met the inclusion criteria. Thirty-seven patients (37 eyes) received conbercept intravitreal injection and another fifty-seven patients (57 eyes) received half-dose PDT. In addition, thirty-five healthy individuals (35 eyes) with matched age and sex were included as normal control group. The general demographics and clinical characteristics were summarized in Table 1. The mean number of required conbercept injections was  $1.78 \pm 0.75$  (range, 1-4) in 6mo. There was no statistical

**Table 1 Baseline demographic and clinical characteristics**

Characteristics	Normal (n=35)	Conbercept (n=37)	Half-dose PDT (n=57)	P
Mean age (y)	48.11±4.66	51.30±9.14	49.49±9.26	0.261 <sup>a</sup>
Male/female	23/12	28/9	45/12	0.361 <sup>b</sup>
Duration of symptoms	-	9.03±1.69	8.58±1.65	0.218 <sup>c</sup>
BCVA (logMAR)	-	0.45±0.21	0.41±0.29	0.500 <sup>c</sup>
CMT (µm)	206.97±18.70	338.11±129.17	350.88±134.47	<0.001 <sup>a</sup>
SFCT (µm)	216.29±34.53	394.81±87.66	370.65±85.01	<0.001 <sup>a</sup>

BCVA: Best-corrected visual acuity; logMAR: Logarithm of minimum angle of resolution; CMT: Central macular thickness; SFCT: Subfoveal choroidal thickness; PDT: Photodynamic therapy. <sup>a</sup>One-way analysis of variance; <sup>b</sup>Chi-squared test; <sup>c</sup>Independent sample *t*-test.

**Table 2 Changes of BCVA, CMT and SFCT in the two treatment groups**

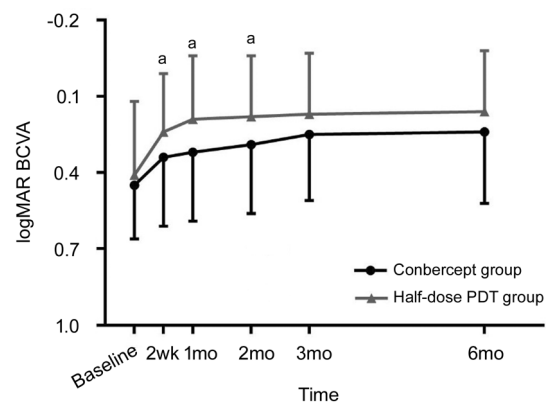
Time	Conbercept group (n=37)			Half-dose PDT group (n=57)			P between the 2 groups		
	BCVA	SFCT	CMT	BCVA	SFCT	CMT	BCVA	SFCT	CMT
Baseline	0.45±0.21	394.81±87.66	338.11±129.17	0.41±0.29	370.65±85.01	350.88±134.47	0.500	0.187	0.649
2wk	0.34±0.27	386.29±84.31	269.62±116.98	0.24±0.23	342.97±82.40	241.98±83.03	0.046	0.045	0.217
1mo	0.32±0.27	383.71±83.92	225.14±91.62	0.19±0.24	325.68±76.54	208.28±61.47	0.024	0.006	0.236
2mo	0.29±0.27	377.68±83.17	197.11±72.15	0.18±0.24	320.94±75.52	194.54±50.53	0.042	0.007	0.807
3mo	0.25±0.26	373.39±81.99	194.35±71.90	0.17±0.24	323.00±75.90	190.58±46.07	0.143	0.015	0.724
6mo	0.24±0.28	371.48±83.99	203.54±84.87	0.16±0.24	322.45±76.09	192.16±45.44	0.120	0.019	0.440
F	26.632	15.291	27.369	34.469	21.272	61.648			
P	<0.001	<0.001	<0.001	<0.001	<0.001	<0.001			

difference in age, gender, duration of symptoms, BCVA, CMT and SFCT at baseline between the two treatment groups (all  $P>0.05$ ). And neither the conbercept group nor half-dose PDT group received ophthalmological treatments previously. There was statistical significance in CMT and SFCT between normal control group and two treatment groups.

**Safety** There were no severe ocular or systemic complications during the study period. Mild visual and ocular complications may be present, such as blurriness, conjunctival injection and superficial punctate keratitis. But all were temporary and recovered soon after procedures.

**Best-Corrected Visual Acuity** Figure 1 and Table 2 show results of BCVA in logMAR. Compared to baseline, the mean logMAR BCVA improved significantly in both groups at each follow-up ( $F=26.632$ ,  $P<0.001$  in the conbercept group and  $F=34.469$ ,  $P<0.001$  in the half-dose PDT group). BCVA of the half-dose PDT group was significantly better at 2wk, 1 and 2mo ( $t=2.02$ , 2.29, and 2.07, respectively;  $P=0.046$ , 0.024 and 0.042, respectively). At 3 and 6mo, the BCVA had no significant difference between the two groups ( $t=1.48$  and 1.62, respectively;  $P=0.143$  and 0.120 respectively).

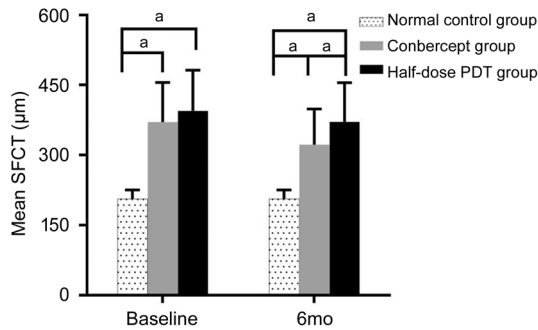
**Subfoveal Choroidal Thickness** The mean SFCT in the conbercept group and half-dose PDT group was shown in Table 2. The difference was statistically significant before and after treatment in both groups ( $F=15.291$ ,  $P<0.001$  in the conbercept group;  $F=21.272$ ,  $P<0.001$  in the half-dose PDT group). Compared to the normal control group, the choroidal



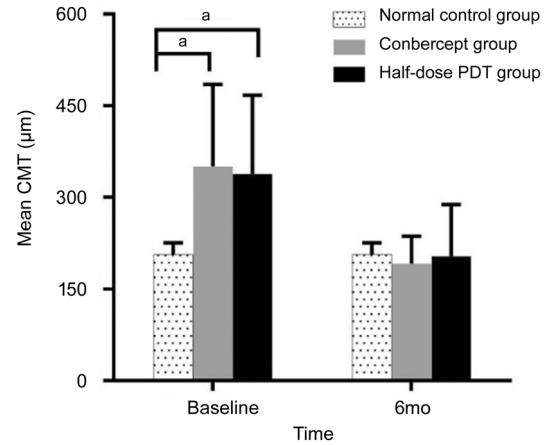
**Figure 1 logMAR BCVA** <sup>a</sup>Statistically significant difference between the groups.

thickness was thicker in the two treatment despite change after treatment as displayed in Figure 2. As shown in Figure 3, the half-dose PDT group had significant better outcome compared to the conbercept group at any follow-up period ( $t=2.05$ , 2.85, 2.81, 2.51, and 2.41, respectively;  $P=0.045$ , 0.006, 0.007, 0.015, and 0.019, respectively).

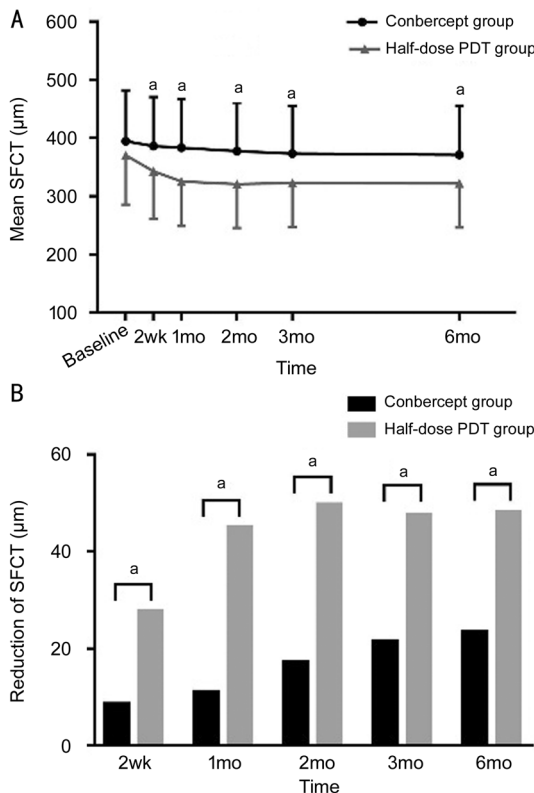
**Central Macular Thickness** Table 2 shows results of the mean CMT in the two treatment groups. In the conbercept group, CMT reduction was 68.49±70.77, 112.97±115.92, 141.00±121.57, 143.76±125.10, and 134.57±135.88 µm at 2wk, 1, 2, 3 and 6mo after initial treatment. In the half-dose PDT group, CMT reduction was 108.89±105.98, 144.42±131.67, 156.86±132.93, 160.82±135.75, and 159.16±134.23 µm at 2wk, 1, 2, 3, and 6mo.



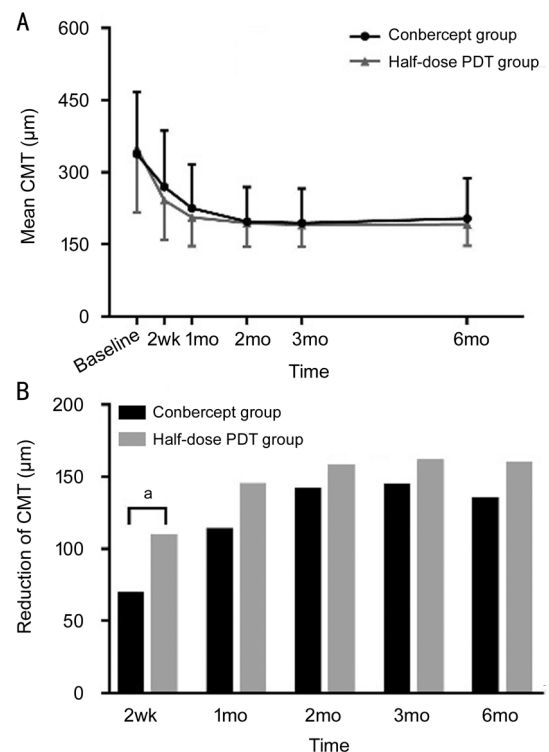
**Figure 2 Mean SFCT before and after treatment** <sup>a</sup>Statistically significant difference between the groups.



**Figure 4 Mean CMT before and after treatment** <sup>a</sup>Statistically significant difference between the groups.



**Figure 3 SFCT: conbercept vs half-dose PDT** A: SFCT change from baseline in the two groups at each visit; B: SFCT reduction in the two groups at each visit. <sup>a</sup>Statistically significant difference between the groups.



**Figure 5 CMT: conbercept vs half-dose PDT** A: CMT change from baseline in the two groups at each visit; B: CMT reduction in the two groups at each visit. <sup>a</sup>Statistically significant difference between the groups.

As shown in Figure 4, compared to the normal control group, the CMT in the two treatment groups were both significantly higher at baseline and reduced significantly at each follow-up. At 6mo after initial treatment, there was no statistical difference among the three groups. Between the two treatment groups, the mean CMT did not significantly differ at any follow-up period ( $t=1.25, 1.19, 0.25, 0.36,$  and  $0.78,$  respectively;  $P=0.217, 0.236, 0.807, 0.724,$  and  $0.440,$  respectively; Figure 5A). The CMT reduction was greater in the half-dose PDT group although the difference was only statistically significant at the 2-week follow-up ( $t=2.22, 1.19, 0.58, 0.61$  and  $0.86,$  respectively;  $P=0.029, 0.239, 0.561, 0.541,$  and  $0.390,$  respectively; Figure 5B).

**Subretinal Fluid** In the conbercept group, full resolution of SRF was achieved in 10.8% (4/37) eyes at 2wk, 29.7% (11/37) eyes at 1mo, 54.1% (20/37) eyes at 2mo, 67.6% (25/37) eyes at 3mo and 70.3% (26/37) eyes at 6mo. In the half-dose PDT group, full resolution of SRF was achieved in 33.3% (19/57) eyes at 2wk, 59.6% (34/57) eyes at 1mo, 78.9% (45/57) eyes at 2mo, 87.7% (50/57) eyes at 3mo and 94.7% (54/57) eyes at 6mo. Overall, the half-dose PDT group had more complete resolution than the conbercept group at each follow-up ( $\chi^2=6.158, 8.048, 6.517, 5.650,$  and  $5.224,$  respectively;  $P=0.013, 0.005, 0.011, 0.017,$  and  $0.022,$  respectively). Comparing Figures 5B and 6, it can be seen that the change



in SRF resembled that in CMT ( $t=2.51, 1.86, 0.89, 0.79,$  and  $1.14,$  respectively;  $P=0.014, 0.066, 0.377, 0.432,$  and  $0.257,$  respectively).

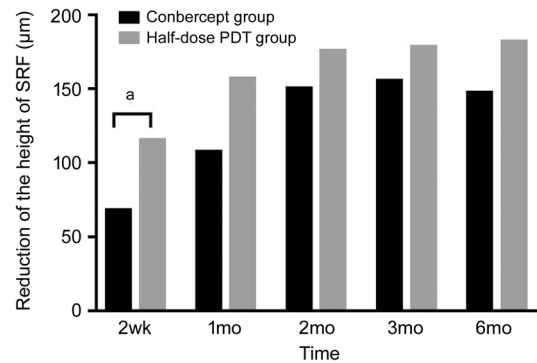
## DISCUSSION

To date, the exact pathogenesis of CSC has not been well identified. The clinical treatment strategy is still to be unified. Several plausible assumptions have been proposed, including choroidal hyper-permeability, congestion of choroidal vessels, increased choroidal thickness, and impairment of the barrier effect of RPE which leads to accumulation of fluid under the retina<sup>[1-2]</sup>. A number of studies have shown the effect of half-dose PDT and other anti-VEGF agents such as bevacizumab or ranibizumab in treating chronic CSC<sup>[4-12,16]</sup>. The therapeutic effectiveness of intravitreal injection of conbercept, especially in comparison to PDT, is yet unclear.

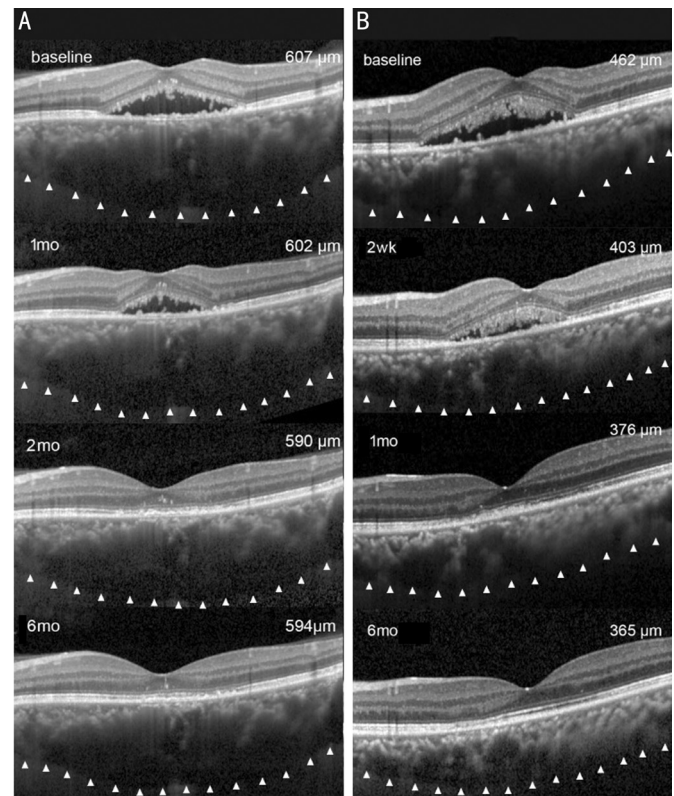
In this study, both treatment methods were safe and can be efficacious in the treatment of chronic CSC with slight difference. The success rate of conbercept and half-dose PDT at the end of 6-month follow-up was 70.3% and 94.7%, which was consistent with those ranging from 40% to 80% and 83% to 100% reported in the previous studies<sup>[4-12]</sup>. Our study found more complete SRF resolution achieved with the half-dose PDT and an overall more rapid anatomic restoration and clinical healing.

While both methods are effective in vision improvement, visual acuity recovery was faster with the half-dose PDT during the first 2mo. The vision recovery rate and degree were similar in the two groups in later stage. The potential explanation for this is the faster SRF absorption with PDT, given that SRF is one of the primary reasons for vision loss in CSC<sup>[17-18]</sup>. Similarly, Bae *et al*<sup>[12]</sup> observed a faster improvement in visual acuity with low-fluence PDT in comparison to ranibizumab within the first 3mo with following sustained superiority without a significant difference. On the contrast, Semeraro *et al*<sup>[11]</sup> reported similar results between intravitreal bevacizumab injection and low-fluence PDT after 9mo of follow-up, however without a comparison during early phase.

It is important to note that the choroidal thickness after both treatments was still thicker than that of the normal eyes. Typical examples were shown in Figure 7. It has been reported that the choroidal thickness was positively correlated with the choroidal vascular hyper-permeability, which can be a potential reason for the recurrence of CSC<sup>[18-20]</sup>. Thus, the choroidal thickness after treatment may be an indicator to the future recurrence of CSC<sup>[21]</sup>. While there was no significant difference between the intravitreal bevacizumab group and half-fluence PDT group in one study above, our study found that half-dose PDT led to a greater degree of reduction in choroidal thickness. The reason may be due to the differences in population and PDT parameters. Different from the half-fluence PDT, the



**Figure 6** SRF reduction in the two groups at each visit <sup>a</sup>Statistically significant difference between the groups.



**Figure 7** SFCT changes after treatment A: A 54-year-old female patient with chronic CSC in the left eye underwent intravitreal injections of conbercept. The SFCT was 607 µm at baseline, 602 µm at 1mo, 590 µm at 2mo and 594 µm at 6mo. B: A 40-year-old male patient with chronic CSC in the left eye underwent half-dose PDT. The SFCT was 462 µm at baseline, reduced to 403 µm at 2wk, 376 µm at 1mo and 365 µm at 6mo.

half-dose PDT may induce a faster SRF reabsorption and a longer-lasting effect<sup>[7]</sup>. In our study, there was no statistically significant difference in the recurrence rate between the two groups. Only 2 eyes (5.4%) in the conbercept group and 1 eye (1.8%) in the half-dose group suffered a relapse after complete resolution of SRF. This is likely due to the short follow-up period. A longer follow-up period is necessary to fully investigate the correlation between recurrence rate and treatment modalities.

This study was retrospective and has its limitation in a small sample size, a relatively short follow-up period and lack of randomization. The short follow-up has an effect on recurrence rate and complication analysis between study arms. Further prospective studies with a large sample and a longer study period are expected to confirm the comparison results between the two treatment methods.

In conclusion, our study demonstrated that both conbercept intravitreal injection and half-dose PDT can improve visual acuity and macular structure in chronic CSC patients. While the therapeutic effect of half-dose PDT was superior at initial phase of treatment, it was indicated that both therapeutic approaches can be safe, effective and feasible in treating chronic CSC.

#### ACKNOWLEDGEMENTS

**Foundations:** Supported by Wenzhou Municipal Science and Technology Bureau (No.Y20180728); Wenzhou Municipal Science and Technology Bureau (No.Y20190635); Wenzhou Municipal Science and Technology Bureau (No.2019Y0592).

**Conflicts of Interest:** Mao JB, None; Zhang CY, None; Liu CY, None; Zhang Y, None; Lin JJ, None; Xu ZK, None; Chen YQ, None; Fan YY, None; Zhao SX, None; Shen LJ, None.

#### REFERENCES

- Gass JD. Pathogenesis of disciform detachment of the neuroepithelium. *Am J Ophthalmol* 1967;63(3):Suppl: 1-Suppl: 139.
- Iacono P, Toto L, Costanzo E, Varano M, Parravano MC. Pharmacotherapy of central serous chorioretinopathy: a review of the current treatments. *Curr Pharm Des* 2018;24(41):4864-4873.
- van Rijssen TJ, van Dijk EHC, Yzer S, *et al.* Central serous chorioretinopathy: towards an evidence-based treatment guideline. *Prog Retin Eye Res* 2019;73:100770.
- Cardillo Piccolino F, Eandi CM, Ventre L, Rigault de la Longrais RC, Grignolo FM. Photodynamic therapy for chronic central serous chorioretinopathy. *Retina* 2003;23(6):752-763.
- Gupta B, Mohamed MD. Photodynamic therapy for variant central serous chorioretinopathy: efficacy and side effects. *Ophthalmologica* 2011;225(4):207-210.
- Chan WM, Lai TY, Lai RY, Tang EW, Liu DT, Lam DS. Safety enhanced photodynamic therapy for chronic central serous chorioretinopathy: one-year results of a prospective study. *Retina* 2008;28(1):85-93.
- Nicoló M, Eandi CM, Alovisi C, Grignolo FM, Traverso CE, Musetti D, Cardillo Piccolino F. Half-fluence versus half-dose photodynamic therapy in chronic central serous chorioretinopathy. *Am J Ophthalmol* 2014;157(5):1033-1037.
- Torres-Soriano ME, García-Aguirre G, Kon-Jara V, Ustariz-González O, Abraham-Marín M, Ober MD, Quiroz-Mercado H. A pilot study of intravitreal bevacizumab for the treatment of central serous chorioretinopathy (case reports). *Graefes Arch Clin Exp Ophthalmol* 2008;246(9):1235-1239.
- Lim SJ, Roh MI, Kwon OW. Intravitreal bevacizumab injection for central serous chorioretinopathy. *Retina* 2010;30(1):100-106.
- Lim JW, Kim MU. The efficacy of intravitreal bevacizumab for idiopathic central serous chorioretinopathy. *Graefes Arch Clin Exp Ophthalmol* 2011;249(7):969-974.
- Semeraro F, Romano MR, Danzi, Morescalchi F, Costagliola C. Intravitreal bevacizumab versus low-fluence photodynamic therapy for treatment of chronic central serous chorioretinopathy. *Jpn J Ophthalmol* 2012;56(6):608-612.
- Bae SH, Heo J, Kim C, Kim TW, Shin JY, Lee JY, Song SJ, Park TK, Moon SW, Chung H. Low-fluence photodynamic therapy versus ranibizumab for chronic central serous chorioretinopathy: one-year results of a randomized trial. *Ophthalmology* 2014;121(2):558-565.
- Nguyen TT, Guymer R. Conbercept (KH-902) for the treatment of neovascular age-related macular degeneration. *Expert Rev Clin Pharmacol* 2015;8(5):541-548.
- Mao JB, Zhang CY, Liu CY, Shen LJ, Lao JM, Shao YR, Chen YQ, Tao JW. The efficacy of intravitreal conbercept for chronic central serous chorioretinopathy. *J Ophthalmol* 2019;2019:7409426.
- Lai KB, Li Y, Zhou LJ, Zhong XJ, Huang CX, Xu FB, Lu L, Ge J, Jin CJ. Comparison of the effects of photodynamic therapy, intravitreal ranibizumab and combination for polypoidal choroidal vasculopathy under 1+PRN regimen. *BMC Ophthalmol* 2018;18(1):144.
- Doyle J, Gupta B, Tahir I. Long term outcomes for patients treated with half-fluence photodynamic therapy for chronic central serous chorioretinopathy: a case series. *Int J Ophthalmol* 2018;11(2):333-336.
- Piccolino FC, de la Longrais RR, Ravera G, Eandi CM, Ventre L, Abdollahi A, Manea M. The foveal photoreceptor layer and visual acuity loss in central serous chorioretinopathy. *Am J Ophthalmol* 2005;139(1):87-99.
- Yu J, Ye XF, Li L, Chang Q, Jiang CH. Relationship between photoreceptor layer changes before half-dose photodynamic therapy and functional and anatomic outcomes in central serous chorioretinopathy. *Eye (Lond)* 2021;35(3):1002-1010.
- Jirarattanasopa P, Ooto S, Tsujikawa A, Yamashiro K, Hangai M, Hirata M, Matsumoto A, Yoshimura N. Assessment of macular choroidal thickness by optical coherence tomography and angiographic changes in central serous chorioretinopathy. *Ophthalmology* 2012;119(8):1666-1678.
- Iovino C, Au A, Chhablani J, *et al.* Choroidal anatomical alterations following photodynamic therapy for chronic central serous chorioretinopathy: a multicenter study. *Am J Ophthalmol* 2020;217:104-113.
- Kim DY, Joe SG, Yang HS, Lee JY, Kim JG, Yoon YH. Subfoveal choroidal thickness changes in treated idiopathic central serous chorioretinopathy and their association with recurrence. *Retina* 2015;35(9):1867-1874.